passmedicine PART 2

RESPIRATORY

2024

A 60-year-old male is admitted to hospital under the medical team with breathlessness. The patient is able to give a history of rapid onset breathlessness this afternoon, with no associated chest pain. He has recently started an an ACE inhibitor for hypertension. On examination, there are bilateral crepitations to the mid-zones. There are no added heart sounds. The patient is tachypnoeic and saturations are 90% on room air. Urinalysis is negative. A chest X-Ray demonstrates acute pulmonary oedema. An ECG shows sinus rhythm with a rate of 95. Blood results show:

Na^+	135 mmol/l
K^+	5.1 mmol/l
Urea	12.6 mmol/l
Creatinine	188 µmol/l

Which investigation will confirm the most likely underlying diagnosis?

- Magnetic Resonance (MR) Renal Angiography
- Computed Tomography (CT) Pulmonary Angiography
- Coronary Angiography
- Echocardiography
- High Resolution Computed Tomography (HRCT)

Submit answer

Reference ranges

Score: **0%**

1 -

All contents of this site are © 2024 Passmedicine Limited

Back to top

A 60-year-old male is admitted to hospital under the medical team with breathlessness. The patient is able to give a history of rapid onset breathlessness this afternoon, with no associated chest pain. He has recently started an an ACE inhibitor for hypertension. On examination, there are bilateral crepitations to the mid-zones. There are no added heart sounds. The patient is tachypnoeic and saturations are 90% on room air. Urinalysis is negative. A chest X-Ray demonstrates acute pulmonary oedema. An ECG shows sinus rhythm with a rate of 95. Blood results show:

Na^+	135 mmol/l
K^+	5.1 mmol/l
Urea	12.6 mmol/l
Creatinine	188 μmol/l

Which investigation will confirm the most likely underlying diagnosis?

- Magnetic Resonance (MR) Renal Angiography 70%
- Computed Tomography (CT) Pulmonary Angiography 7%
- Coronary Angiography 1%
- Echocardiography 14%
- High Resolution Computed Tomography (HRCT) 7%

This patient gives a history of flash pulmonary oedema. The clue in the question as to the cause is the recent initiation of an ACE inhibitor. In patients with undiagnosed renal artery stenosis, initiation of ACE inhibitor therapy is a recognised cause of flash pulmonary oedema.

Although a echocardiography would be part of the initial work-up, it would not reveal the underlying diagnosis. From the history, and based on the unremarkable ECG, cardiogenic pulmonary oedema is unlikely to be the cause in this scenario.

Discuss (4) Improve

Next question

Chest x-ray: pulmonary oedema

Features of pulmonary oedema on a chest x-ray may include:

- interstitial oedema
- bat's wing appearance
- upper lobe diversion (increased blood flow to the superior parts of the lung)
- Kerley B lines
- pleural effusion
- cardiomegaly may be seen if there is cardiogenic cause

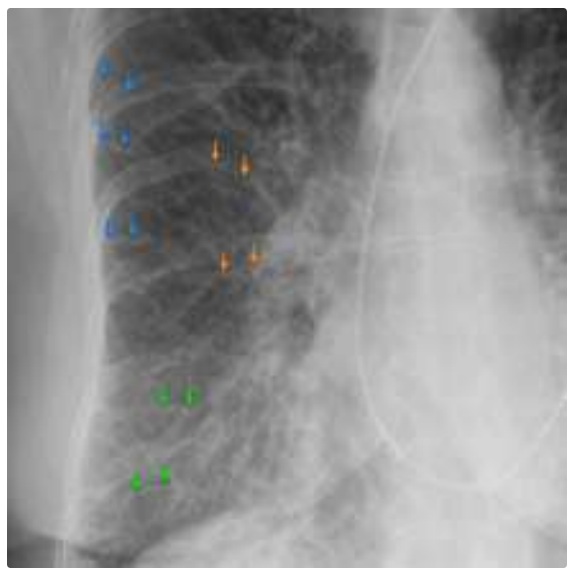

123

Next question

Textbooks

High-yield textbook

Extended textbook

Links

Radiology Masterclass 3 2

[Cardiomegaly and heart failure]

British Institute of Radiology 1 1

[Unofficial guide to radiology]

Suggest link Report broken link

Media

Pulmonary oedema

Osmosis - YouTube 2 0

Report broken media

Score: **24%**

1 ✗
2 ✗
3 ✗
4 ✗
5 ✗
6 ✗
7 ✗
8 ✗
9 ✓
10 ✓
11 ✗
12 ✗
13 ✗

14	✓
15	✗
16	✓
17	✗
18	✗
19	✗
20	✗
21	✓
22	✓
23	✗
24	✗
25	✗

All contents of this site are © 2024 Passmedicine Limited

A 76-year-old man presents with dyspnoea. A chest x-ray is performed:

© Image used on license from Radiopaedia

What is the main finding on the film?

- Right upper lobe consolidation
- Right sided pneumothorax
- Pulmonary oedema
- Right middle + lower lobe consolidation
- Bronchiectasis

Submit answer

Reference ranges

Score: **0%**

1 -
2 -

All contents of this site are © 2024 Passmedicine Limited

Back to top

A 76-year-old man presents with dyspnoea. A chest x-ray is performed:

© Image used on license from Radiopaedia

What is the main finding on the film?

Right upper lobe consolidation	3%
Right sided pneumothorax	8%
Pulmonary oedema	6%
Right middle + lower lobe consolidation	81%
Bronchiectasis	2%

The presence of consolidation above the horizontal fissure and the obscured right heart border suggest the presence of right middle lobe consolidation. There is some loss of definition (silhouette sign) of the medial aspect of the right hemidiaphragm suggesting some right lower lobe consolidation as well.

A chest drain is also seen on the right hand side. This had been inserted to drain an associated pleural effusion.

Chest x-ray: white lung lesions

There are numerous causes of white shadowing in the lungs including:

- consolidation
- pleural effusion
- collapse
- pneumonectomy
- specific lesions e.g. tumours
- fluid e.g. pulmonary oedema

If there is a 'white-out' of a hemithorax it is useful to assess the position of the trachea - is it central, pulled or pushed from the side of opacification.

Trachea pulled toward the white-out	Trachea central	Trachea pushed away from the white-out
Pneumonectomy Complete lung collapse e.g. endobronchial intubation Pulmonary hypoplasia	Consolidation Pulmonary oedema (usually bilateral) Mesothelioma	Pleural effusion Diaphragmatic hernia Large thoracic mass

© Image used on license from Radiopaedia

Lung collapse - note how the trachea is pulled towards the side of the white-out

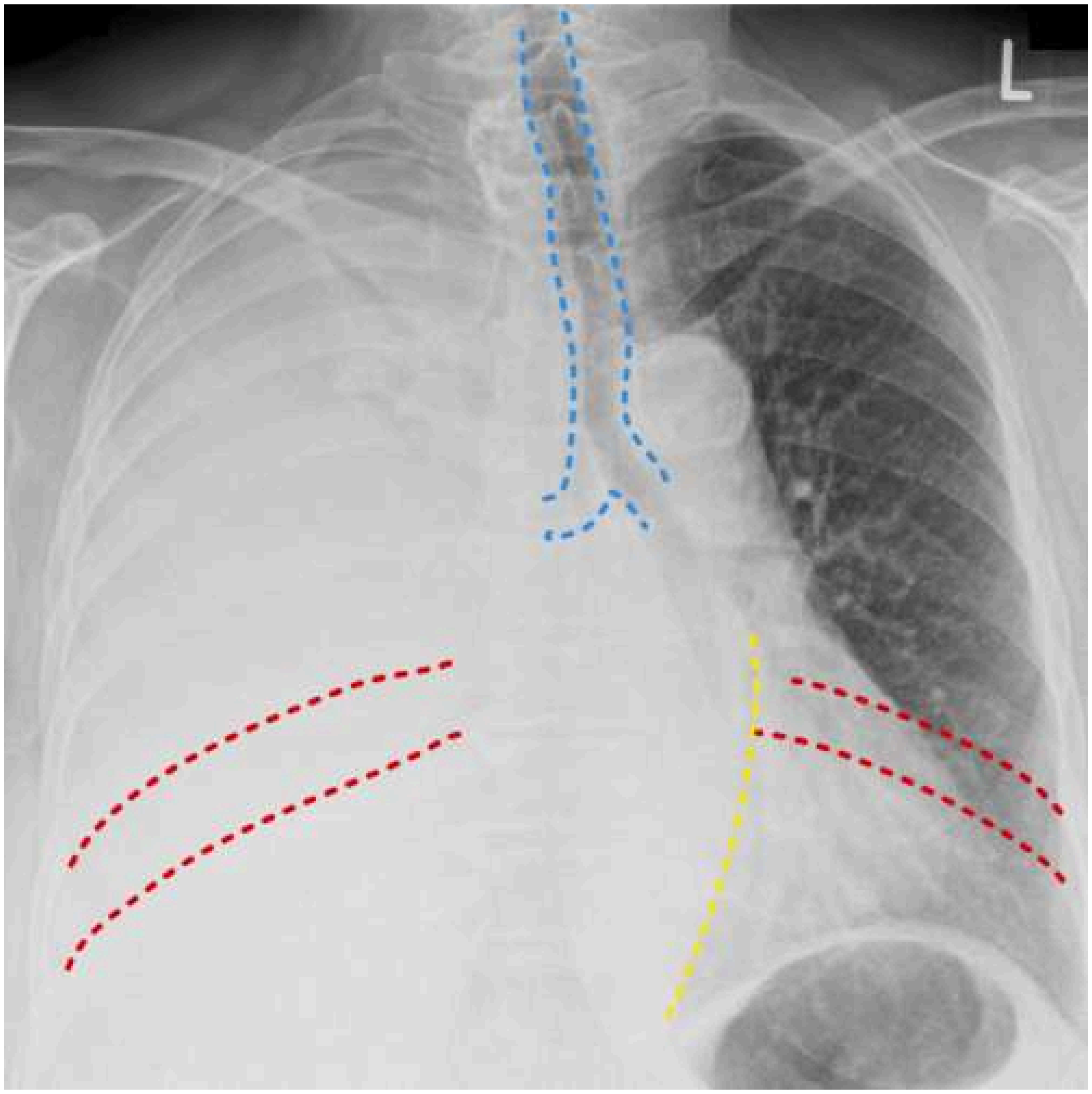

© Image used on license from Radiopaedia

Pleural effusion - note how the trachea (blue) is pushed away the side of the white-out. The other signs of a positive mass effect include leftward bowing of the azygo-oesophageal recess (yellow) and splaying of the ribs on the right (red)

For more information check out the link to the superb Radiology Masterclass website.

AI + Q 123

Next question >

B I A

Textbooks

High-yield textbook

Extended textbook

Links

Wiki Radiography 13 4

Example of right upper lobe consolidation

Radiology Masterclass 42 6

Fantastic radiology teaching website

Suggest link Report broken link

Score: **24%**

1	✗
2	✗
3	✗
4	✗
5	✗
6	✗
7	✗
8	✗
9	✓
10	✓
11	✗
12	✗
13	✗
14	✓
15	✗
16	✓
17	✗
18	✗
19	✗
20	✗
21	✓
22	✓
23	✗
24	✗
25	✗

All contents of this site are © 2024 Passmedicine Limited

Back to top

A 75-year-old male presents to his GP with three weeks of shortness of breath. He developed a cold a few weeks prior and has remained short of breath since. He was bringing up green sputum but the cough is now dry. He has no pains in his chest and no fevers. He is now retired but remains a keen gardener with an allotment of vegetables and tubers. He previously worked as an aerospace engineer making and fixing electronic parts. He is unsure of any asbestos exposure.

On examination, he has clubbing and appears cachectic. There are bilateral apical crepitations and he appears breathless with activity. Oxygen saturation on air is 94% and respiratory rate is 28/min.

What is the likeliest diagnosis?

Na^+	138 mmol/l
K^+	4.2 mmol/l
Urea	4.3 mmol/l
Creatinine	78 µmol/l

Hb	135 g/l
Platelets	$450 * 10^9/l$
WBC	$14 * 10^9/l$
C-reactive protein	12 mmol/l
Chest x-ray	reticular shadowing prominent at the apices

- Aspergillosis
- Asbestosis
- Berylliosis
- Hypersensitivity pneumonitis
- Idiopathic pulmonary fibrosis

Submit answer

Reference ranges

Score: **0%**

1 -
2 -
3 -

All contents of this site are © 2024 Passmedicine Limited

A 75-year-old male presents to his GP with three weeks of shortness of breath. He developed a cold a few weeks prior and has remained short of breath since. He was bringing up green sputum but the cough is now dry. He has no pains in his chest and no fevers. He is now retired but remains a keen gardener with an allotment of vegetables and tubers. He previously worked as an aerospace engineer making and fixing electronic parts. He is unsure of any asbestos exposure.

On examination, he has clubbing and appears cachectic. There are bilateral apical crepitations and he appears breathless with activity. Oxygen saturation on air is 94% and respiratory rate is 28/min.

What is the likeliest diagnosis?

Na^+	138 mmol/l
K^+	4.2 mmol/l
Urea	4.3 mmol/l
Creatinine	78 µmol/l

Hb	135 g/l
Platelets	$450 * 10^9$/l
WBC	$14 * 10^9$/l
C-reactive protein	12 mmol/l
Chest x-ray	reticular shadowing prominent at the apices

- Aspergillosis 7%
- Asbestosis 12%
- Berylliosis 36%
- Hypersensitivity pneumonitis 40%
- Idiopathic pulmonary fibrosis 6%

Aeronautical engineers -> risk of berylliosis

Important for me Less important

This gentleman has shortness of breath and reticular changes consistent with a form of interstitial lung disease (formerly pulmonary fibrosis). The cause is reliant on the history. Asbestosis is usually a lower lobe fibrosing process. Aspergillosis typically occurs in weakened immunosuppressed individuals. Hypersensitivity pneumonitis classically occurs in those exposed to moulds and hay which is possible in a gardener but not common. Berylliosis is linked to beryllium heavily used in the aeronautical industry.

Discuss (8) Improve

Next question

Berylliosis

Berylliosis is one of the occupational lung diseases caused by inhalation of the fumes of molten beryllium.

Features
- lung fibrosis
- bilateral hilar lymphadenopathy

Occupational risk factors
- aerospace industry
- manufacture of fluorescent light bulbs/golf-club heads

123

Next question

Textbooks

High-yield textbook

Extended textbook

Score: **24%**

1	✗
2	✗
3	✗
4	✗
5	✗
6	✗
7	✗
8	✗
9	✓
10	✓
11	✗
12	✗
13	✗
14	✓
15	✗
16	✓
17	✗
18	✗
19	✗
20	✗
21	✓
22	✓
23	✗
24	✗
25	✗

All contents of this site are © 2024 Passmedicine Limited

A 35-year-old female banker from Scotland presents with breathlessness on exertion. She is a non smoker and has two budgies at home. She had severe pneumonia 5 years ago and required intubation on intensive care for 5 days. She recovered but has reported ongoing dyspnoea and on examination has an inspiratory wheeze. This has not improved despite her GP starting inhaled steroids for asthma. Her chest X-ray was unremarkable, peak flow was reduced and eosinophil count was normal. What is the most likely diagnosis?

- Cystic fibrosis
- Severe asthma
- Posterior subglottic stenosis
- Chronic obstructive pulmonary disease
- Allergic bronchopulmonary aspergillosis

Submit answer

Reference ranges

Score: **0%**

1 -
2 -
3 -
4 -

All contents of this site are © 2024 Passmedicine Limited

A 35-year-old female banker from Scotland presents with breathlessness on exertion. She is a non smoker and has two budgies at home. She had severe pneumonia 5 years ago and required intubation on intensive care for 5 days. She recovered but has reported ongoing dyspnoea and on examination has an inspiratory wheeze. This has not improved despite her GP starting inhaled steroids for asthma. Her chest X-ray was unremarkable, peak flow was reduced and eosinophil count was normal. What is the most likely diagnosis?

- Cystic fibrosis 5%
- Severe asthma 5%
- Posterior subglottic stenosis 53%
- Chronic obstructive pulmonary disease 5%
- Allergic bronchopulmonary aspergillosis 33%

Subglottic stenosis can occur from birth, idiopathically and in patients who have been intubated. It worth considering in patient with lung function tests that show an obstructive picture and as a differential diagnosis in the 'difficult asthma clinic'.

This patients lack of response to inhaled steroids and predominance of inspiratory rather expiratory wheeze may asthma less likely. A patient with cystic fibrosis would probably have an abnormal CXR by the age of 35 and the normal eosinophil count makes ABPA less likely. COPD is unusual in non smokers but plausible if their is a family history of early onset dyspnoea (ie alpha-1-antitrypsin deficiency).

Discuss (10) | Improve

Next question

Subglottic stenosis

Subglottic stenosis may be defined as a narrowing of the airway below the vocal cords (subglottis) and above the trachea. It may be congenital or acquired.

Next question

Textbooks

High-yield textbook

Extended textbook

Score: **24%**

1	✗
2	✗
3	✗
4	✗
5	✗
6	✗
7	✗
8	✗
9	✓
10	✓
11	✗
12	✗
13	✗
14	✓
15	✗

16 ✓
17 ✗
18 ✗
19 ✗
20 ✗
21 ✓
22 ✓
23 ✗
24 ✗
25 ✗

All contents of this site are © 2024 Passmedicine Limited

Back to top

A 64-year-old man presents to the respiratory clinic for review. He has been diagnosed with idiopathic pulmonary fibrosis which has not responded to a course of oral corticosteroids. He is finding it difficult to manage the stairs more than once per day and is finding it difficult to get out of the house. On examination his blood pressure is 138/88 mmHg, his pulse is 80 beats per minute and regular. There are inspiratory crackles on auscultation of the chest consistent with pulmonary fibrosis, and his O2 saturation is 92% at rest. His FVC is 65% of predicted. Which of the following is the next most appropriate intervention?

- Cyclophosphamide
- Infliximab
- Methotrexate
- Nintedanib
- Rituximab

Submit answer

Reference ranges

Score: **0%**

1 -
2 -
3 -
4 -
5 -

All contents of this site are © 2024 Passmedicine Limited

A 64-year-old man presents to the respiratory clinic for review. He has been diagnosed with idiopathic pulmonary fibrosis which has not responded to a course of oral corticosteroids. He is finding it difficult to manage the stairs more than once per day and is finding it difficult to get out of the house. On examination his blood pressure is 138/88 mmHg, his pulse is 80 beats per minute and regular. There are inspiratory crackles on auscultation of the chest consistent with pulmonary fibrosis, and his O2 saturation is 92% at rest. His FVC is 65% of predicted. Which of the following is the next most appropriate intervention?

Cyclophosphamide	7%
Infliximab	3%
Methotrexate	4%
Nintedanib	82%
Rituximab	4%

Nintedanib is a small molecule tyrosine kinase inhibitor including the receptors platelet-derived growth factor receptor (PDGFR) and , fibroblast growth factor receptor (FGFR) 1-3, and VEGFR 1-3. It is licensed for the treatment of idiopathic pulmonary fibrosis, and is endorsed by NICE guidelines when:

a) The person has a forced vital capacity (FVC) between 50% and 80% of predicted
b) The company provides nintedanib with the discount agreed in the patient access scheme and
c) Treatment is stopped if the disease progresses (a confirmed decline in percent predicted FVC of 10% or more) in any 12month period.

https://www.nice.org.uk/guidance/ta379/chapter/1-recommendations

Cyclophosphamide, rituximab and infliximab all have limited efficacy in the treatment of idiopathic pulmonary fibrosis and are therefore not recommended. Methotrexate is used primarily in the treatment of rheumatoid arthritis and may itself cause pulmonary fibrosis.

Discuss (4) | Improve

Next question >

Idiopathic pulmonary fibrosis

Idiopathic pulmonary fibrosis (IPF, previously termed cryptogenic fibrosing alveolitis) is a chronic lung condition characterised by progressive fibrosis of the interstitium of the lungs. Whilst there are many causes of lung fibrosis (e.g. medications, connective tissue disease, asbestos) the term IPF is reserved when no underlying cause exists.

IPF is typically seen in patients aged 50-70 years and is twice as common in men.

Features

- progressive exertional dyspnoea
- bibasal fine end-inspiratory crepitations on auscultation
- dry cough
- clubbing

Diagnosis

- spirometry: classically a restrictive picture (FEV1 normal/decreased, FVC decreased, FEV1/FVC increased)
- impaired gas exchange: reduced transfer factor (TLCO)
- imaging: bilateral interstitial shadowing (typically small, irregular, peripheral opacities - 'ground-glass' - later progressing to 'honeycombing') may be seen on a chest x-ray but high-resolution CT scanning is the investigation of choice and required to make a diagnosis of IPF
- ANA positive in 30%, rheumatoid factor positive in 10% but this does not necessarily mean that the fibrosis is secondary to a connective tissue disease. Titres are usually low

Management

- pulmonary rehabilitation
- very few medications have been shown to give any benefit in IPF. There is some evidence that pirfenidone (an antifibrotic agent) may be useful in selected patients (see NICE guidelines)
- many patients will require supplementary oxygen and eventually a lung transplant

Prognosis

- poor, average life expectancy is around 3-4 years

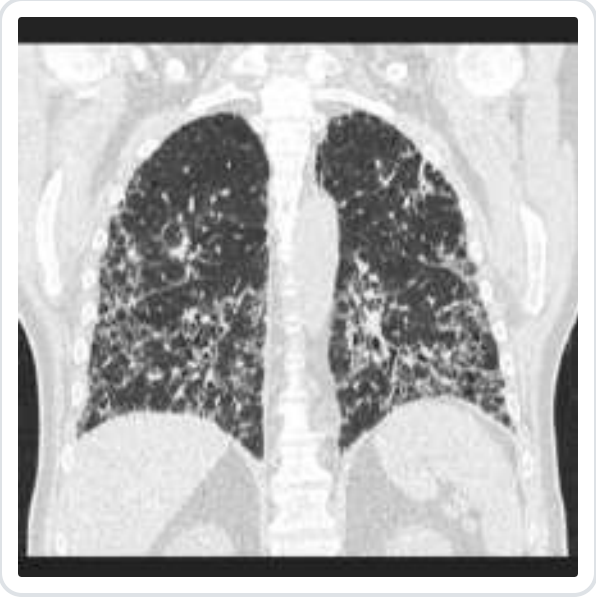

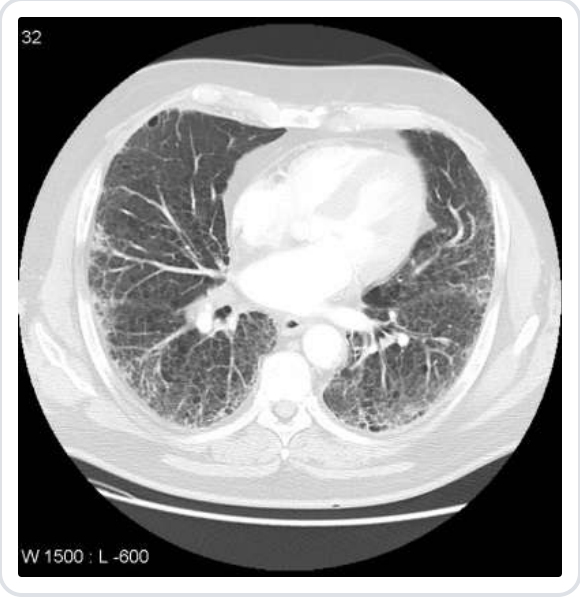

123

Next question

Textbooks

High-yield textbook

Extended textbook

Links

Royal College of Physicians 13 10

Update in diagnosis and management of interstitial lung disease

NICE 11 6

2013 Idiopathic pulmonary fibrosis guidelines

Suggest link

Report broken link

Media

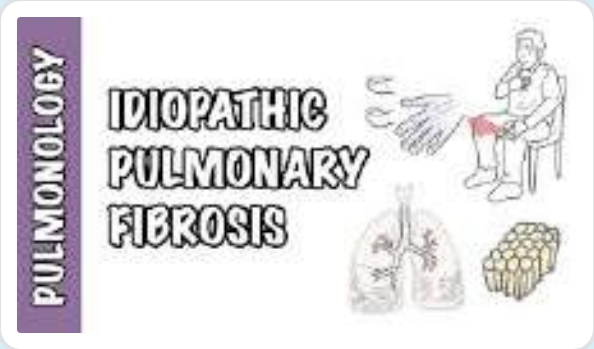

[Idiopathic pulmonary fibrosis]

Armando Hasudungan - YouTube 6 0

[Interstitial Lung Disease (ILD) - Classification, pathophysiology, signs and symptoms]

Armando Hasudungan - YouTube 5 0

[Idiopathic pulmonary fibrosis]

Osmosis - YouTube 4 0

Report broken media

Score: **24%**

1 ✗
2 ✗
3 ✗
4 ✗
5 ✗
6 ✗
7 ✗
8 ✗
9 ✓
10 ✓

11	✗
12	✗
13	✗
14	✓
15	✗
16	✓
17	✗
18	✗
19	✗
20	✗
21	✓
22	✓
23	✗
24	✗
25	✗

All contents of this site are © 2024 Passmedicine Limited

A 9-year-old is referred to the Children's Ward with pyrexia and cough:

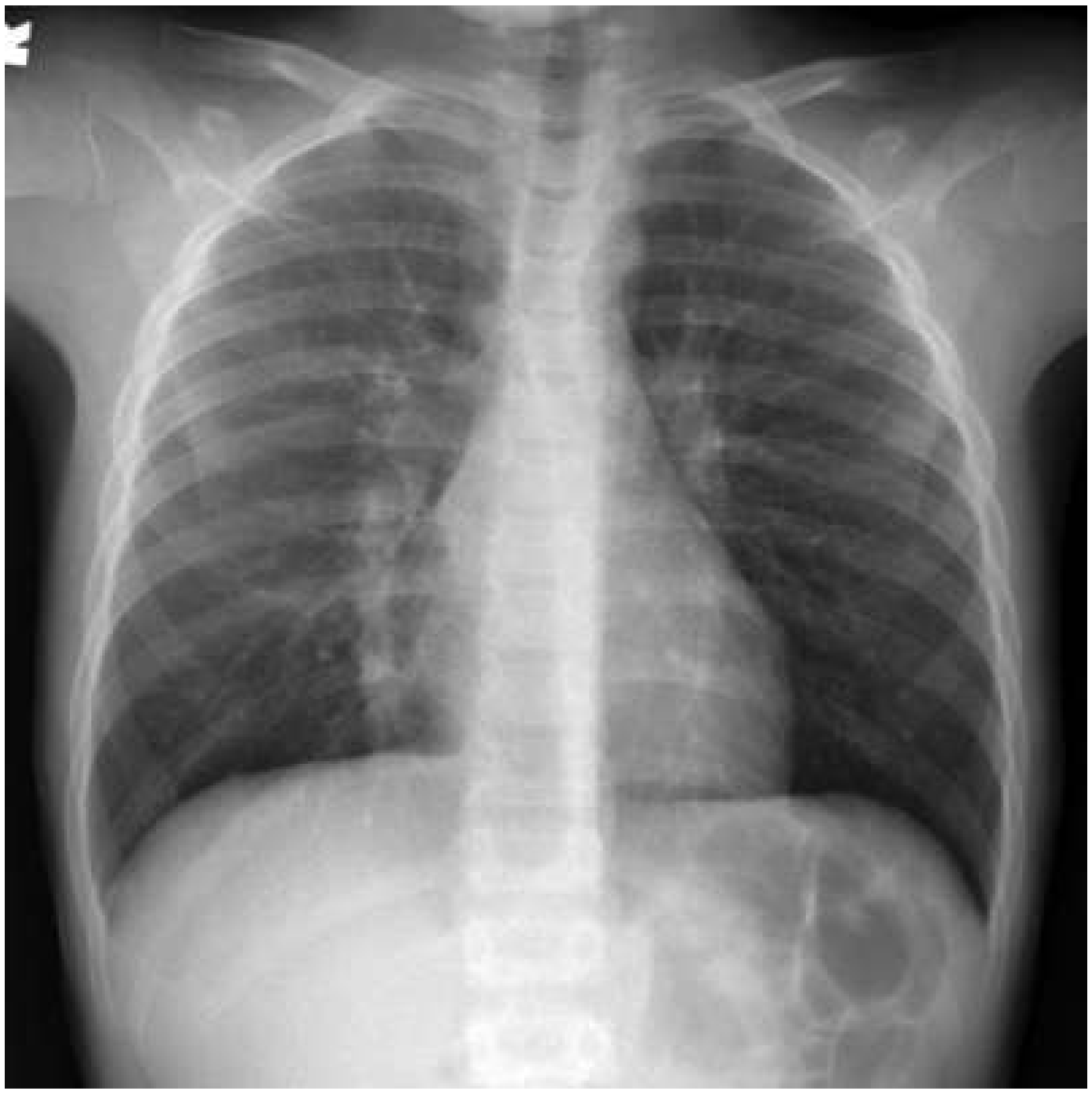

© Image used on license from Radiopaedia

What does the x-ray show?

- Right middle lobe consolidation
- Perihilar lymphadenopathy
- No abnormality
- Left lingual consolidation
- Right upper lobe consolidation

Submit answer

Reference ranges

Score: **0%**

1	-
2	-
3	-
4	-
5	-
6	-

All contents of this site are © 2024 Passmedicine Limited

A 9-year-old is referred to the Children's Ward with pyrexia and cough:

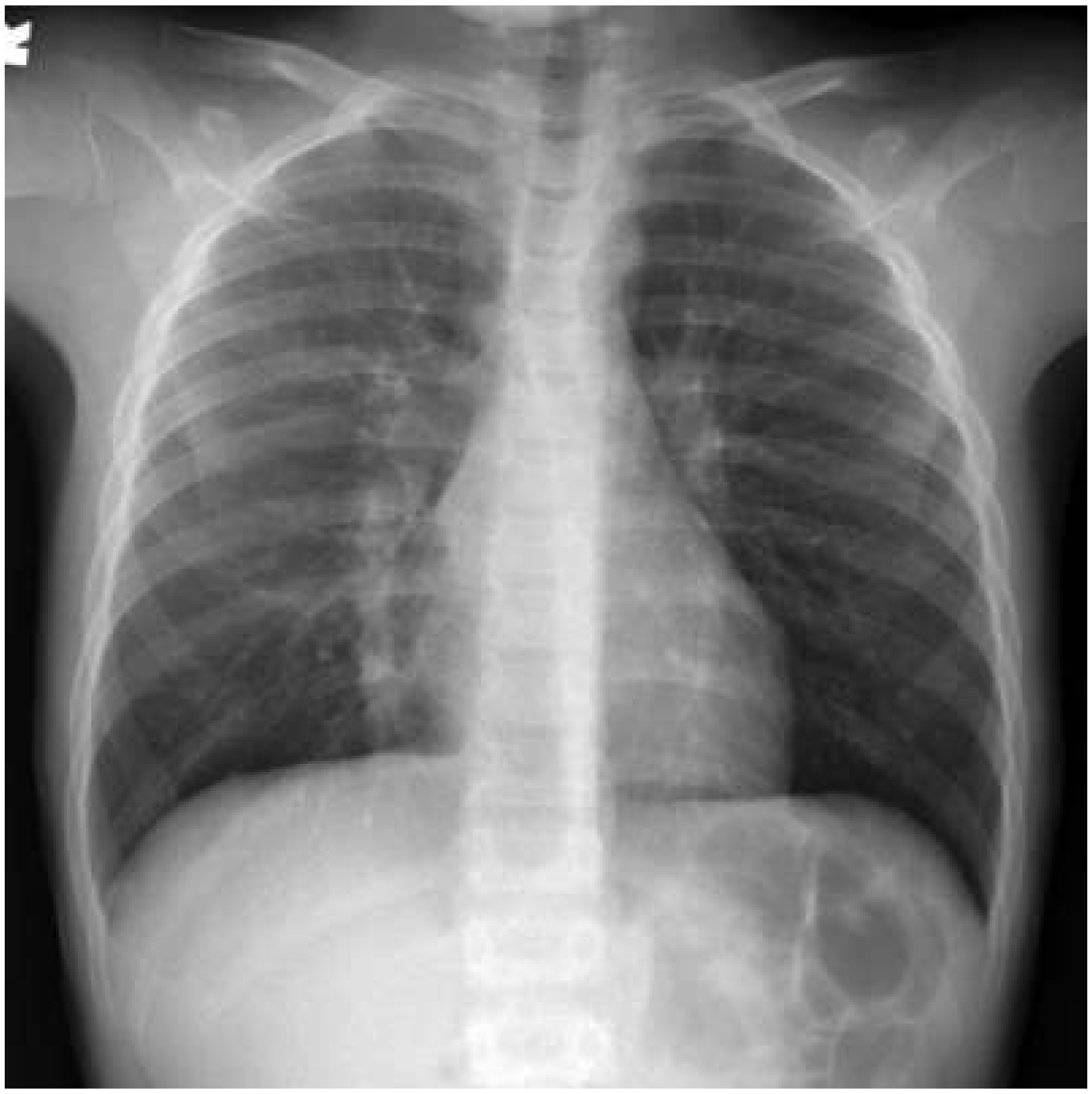

© Image used on license from Radiopaedia

What does the x-ray show?

- Right middle lobe consolidation 25%
- Perihilar lymphadenopathy 41%
- No abnormality 21%
- Left lingual consolidation 6%
- Right upper lobe consolidation 6%

The correct answer is **Right middle lobe consolidation**. This is because the x-ray image shows an area of increased opacity in the right middle zone of the lung, which corresponds to the location of the right middle lobe. The loss of the right heart border is a common finding in right middle lobe consolidation. Consolidation refers to a region of lung tissue filled with liquid instead of air,

often due to infection such as pneumonia. The child's symptoms of pyrexia and cough also support this diagnosis.

The option **Perihilar lymphadenopathy** is incorrect because it refers to enlargement of lymph nodes around the hilum, a region where blood vessels and nerves enter or exit an organ. In this case, it would be seen as enlarged shadows near the centre (mediastinum) of the chest x-ray. However, there are no such findings in this image.

The option **No abnormality** is incorrect as there is clearly an area of increased opacity in the right middle lobe indicating a pathological process.

Left lingual consolidation is also incorrect. The lingula is a part of the left upper lobe that corresponds anatomically to the right middle lobe. However, there are no signs on this x-ray that suggest any abnormalities in this area.

Lastly, **Right upper lobe consolidation** would typically show increased opacity in the upper part of the right lung field on an x-ray image. However, in this case, it's clear from the image that there's an increase in density more centrally located which corresponds with a right middle lobe consolidation rather than upper.

Discuss (4) | Improve

Next question >

Chest x-ray: white lung lesions

There are numerous causes of white shadowing in the lungs including:

- consolidation
- pleural effusion
- collapse
- pneumonectomy
- specific lesions e.g. tumours
- fluid e.g. pulmonary oedema

If there is a 'white-out' of a hemithorax it is useful to assess the position of the trachea - is it central, pulled or pushed from the side of opacification.

Trachea pulled toward the white-out	Trachea central	Trachea pushed away from the white-out
Pneumonectomy Complete lung collapse e.g. endobronchial intubation Pulmonary hypoplasia	Consolidation Pulmonary oedema (usually bilateral) Mesothelioma	Pleural effusion Diaphragmatic hernia Large thoracic mass

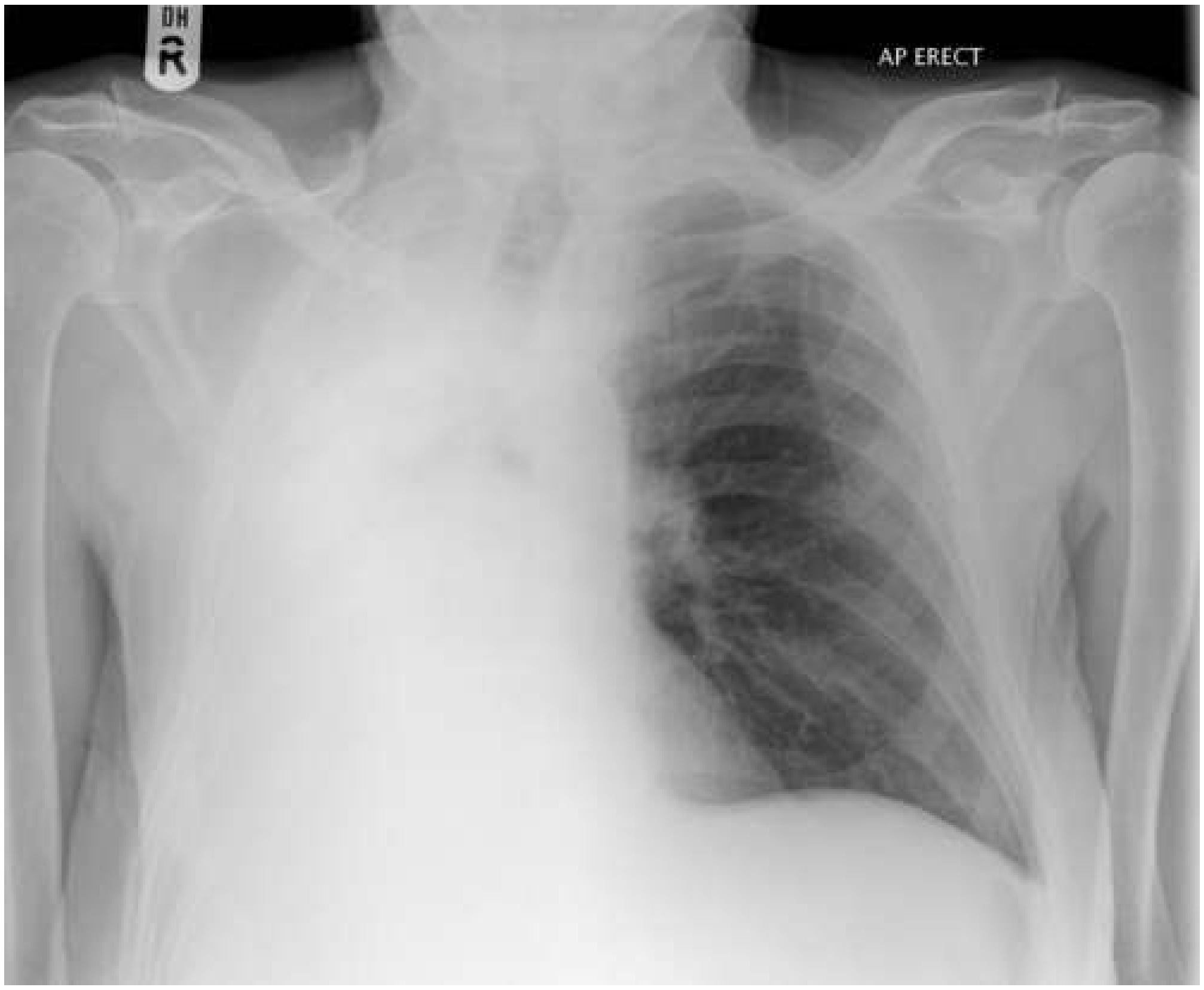

© Image used on license from Radiopaedia

Lung collapse - note how the trachea is pulled towards the side of the white-out

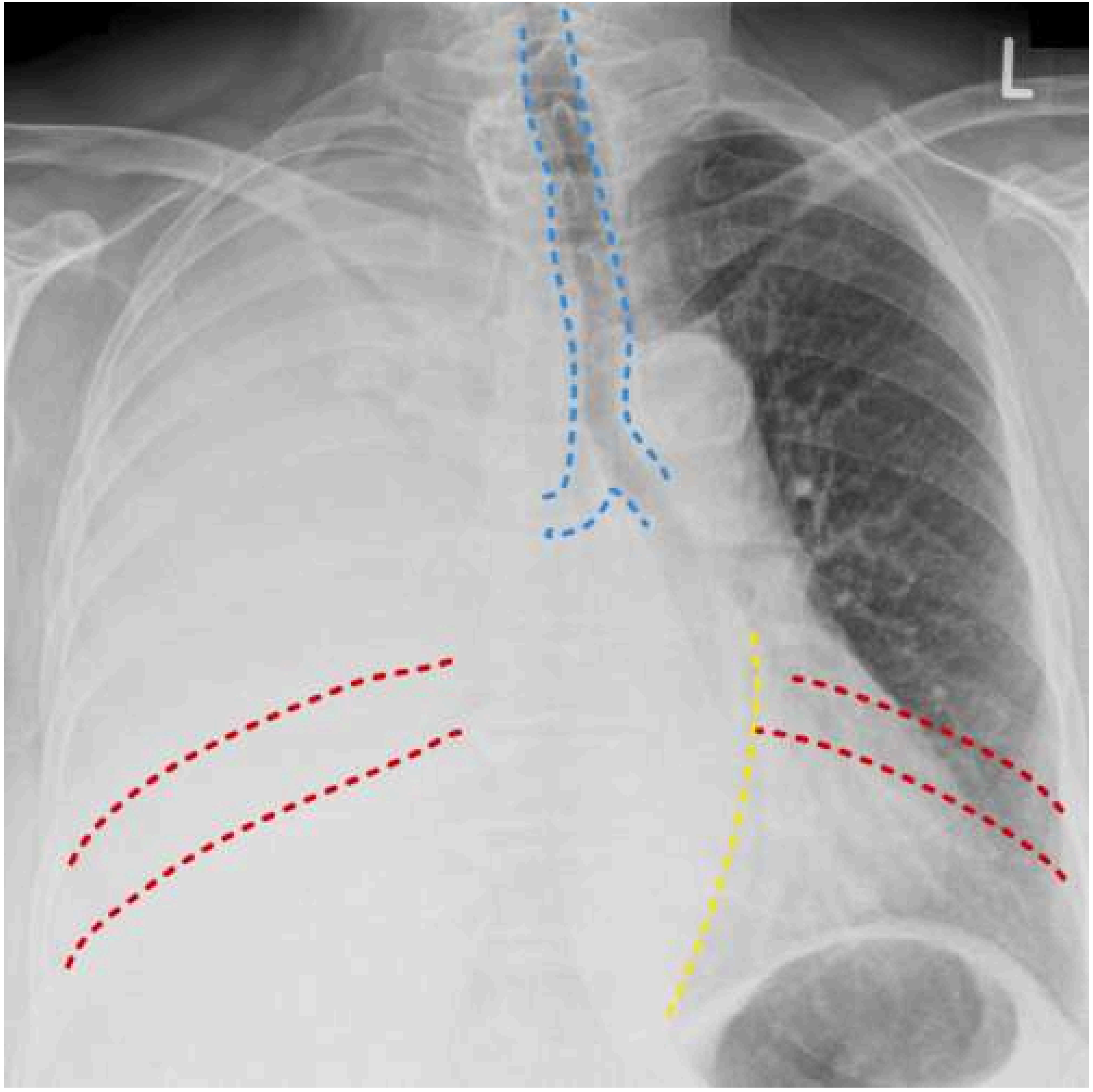

© Image used on license from Radiopaedia

Pleural effusion - note how the trachea (blue) is pushed away the side of the white-out. The other signs of a positive mass effect include leftward bowing of the azygo-oesophageal recess (yellow) and splaying of the ribs on the right (red)

For more information check out the link to the superb Radiology Masterclass website.

123

Next question

Textbooks

High-yield textbook

Extended textbook

Links

Wiki Radiography 13 4

Example of right upper lobe consolidation

Radiology Masterclass 42 6

Fantastic radiology teaching website

Suggest link

Report broken link

Score: **24%**

1	✗
2	✗
3	✗
4	✗
5	✗
6	✗
7	✗
8	✗
9	✓
10	✓
11	✗
12	✗
13	✗
14	✓
15	✗
16	✓

17	✗
18	✗
19	✗
20	✗
21	✓
22	✓
23	✗
24	✗
25	✗

All contents of this site are © 2024 Passmedicine Limited

Back to top

A 75-year-old man is admitted to hospital with haemoptysis and dyspnoea. He is a life-long smoker and a coin lesion is seen in the right middle zone on chest x-ray. He also complains of pain in his left forearm. An x-ray is requested:

© Image used on license from Radiopaedia

What is the most likely cause of the patients arm pain?

- PTHrP-induced subperiosteal bone resorption and osteopaenia
- Pathological fracture of the radial head
- Long-standing osteoarthritic changes
- Hypertrophic pulmonary osteoarthropathy
- Metastatic lung cancer

Submit answer

Reference ranges

Score: **0%**

1	-
2	-
3	-
4	-
5	-
6	-
7	-

All contents of this site are © 2024 Passmedicine Limited

Back to top

A 75-year-old man is admitted to hospital with haemoptysis and dyspnoea. He is a life-long smoker and a coin lesion is seen in the right middle zone on chest x-ray. He also complains of pain in his left forearm. An x-ray is requested:

© Image used on license from Radiopaedia

What is the most likely cause of the patients arm pain?

- PTHrP-induced subperiosteal bone resorption and osteopaenia 29%
- Pathological fracture of the radial head 2%
- Long-standing osteoarthritic changes 1%
- Hypertrophic pulmonary osteoarthropathy 68%
- Metastatic lung cancer 1%

The x-ray shows the periosteal reaction on the shafts of the ulnar and radius. This is typical of hypertrophic pulmonary osteoarthropathy.

Discuss (2) Improve

Next question

Lung cancer: paraneoplastic features

Small cell

- ADH
- ACTH - not typical, hypertension, hyperglycaemia, hypokalaemia, alkalosis and muscle weakness are more common than buffalo hump etc
- Lambert-Eaton syndrome

Squamous cell

- parathyroid hormone-related protein (PTH-rp) secretion causing hypercalcaemia
- clubbing
- hypertrophic pulmonary osteoarthropathy (HPOA)
- hyperthyroidism due to ectopic TSH

Adenocarcinoma

- gynaecomastia
- hypertrophic pulmonary osteoarthropathy (HPOA)

© Image used on license from Radiopaedia

Hypertrophic pulmonary osteoarthropathy is a proliferative periostisis involving that typically involves the long bones. It is often painful.

*whilst it is traditionally taught that HPOA is most common with squamous cell carcinoma some studies indicate that adenocarcinoma is the most common cause e.g. https://www.ncbi.nlm.nih.gov/pmc/articles/PMC4049689/

AI + Q 123

Next question >

Textbooks

High-yield textbook

Extended textbook

Links

Mayo Clinic 8 8

Paraneoplastic Syndromes: An Approach to Diagnosis and Treatment

Suggest link Report broken link

Media

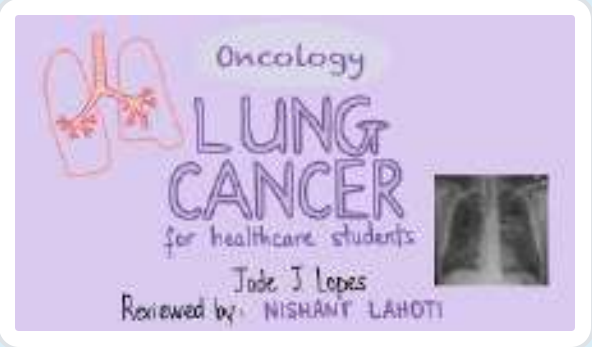

Lung cancer

MedFlix - YouTube 6 0

Lung Cancer: An Overview

Oncology for Medical Students - YouTube 3 0

Hypercalcemia in malignancy

Armando Hasudungan - YouTube 3 1

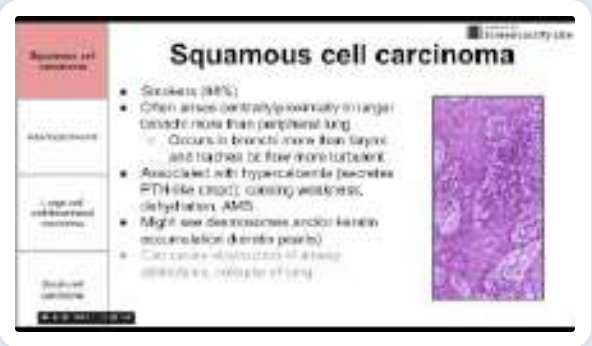

Cancers of the lung

MedLecturesMadeEasy - YouTube 2 2

Report broken media

Score: **24%**

1	✗
2	✗
3	✗
4	✗
5	✗
6	✗
7	✗
8	✗
9	✓
10	✓
11	✗
12	✗
13	✗
14	✓
15	✗
16	✓
17	✗
18	✗
19	✗
20	✗
21	✓
22	✓
23	✗
24	✗
25	✗

All contents of this site are © 2024 Passmedicine Limited

A 23-year-old man presents with dyspnoea and haemoptysis to the Emergency Department. He initially thought his symptoms were due to a chest infection but a course of amoxicillin from his GP has not helped. He now feels short of breath on mild exertion and has coughed up fresh blood on a number of occasions today.

On examination his oxygen saturations are 92% on air. On examination he has crackles predominately in the upper and lower zones of the left lung. Temperature is 37.7ºC.

Hb	13.1 g/dL
WCC	11.3 *10^9/l
Sodium	137 mmol/l
Potassium	4.2 mmol/l
Urea	6.4 mmol/l
Creatinine	123 µmol/l
CRP	188 mg/L

Urine dip: blood +++, leucocytes +

A chest x-ray is requested:

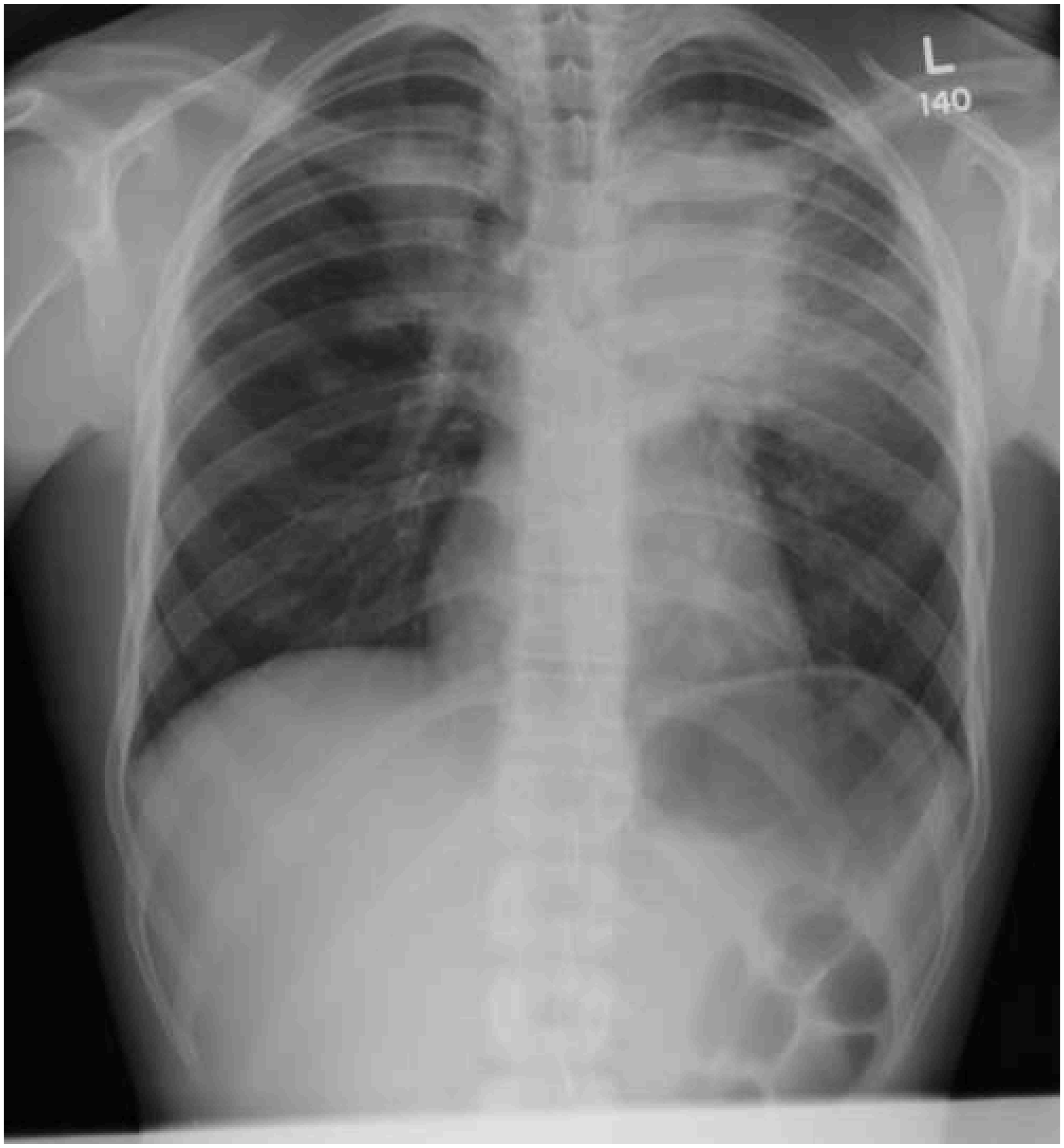

© Image used on license from Radiopaedia

Later tests during his admission show the following;

c-ANCA	Positive
p-ANCA	Positive
Anti-GBM	Negative

What is the most likely diagnosis?

- Granulomatosis with polyangiitis
- Cryptogenic organizing pneumonia
- Churg-Strauss syndrome
- Tuberculosis

Goodpasture's disease

Submit answer

Reference ranges

Score: **0%**

1 -
2 -
3 -
4 -
5 -
6 -
7 -
8 -

All contents of this site are © 2024 Passmedicine Limited

A 23-year-old man presents with dyspnoea and haemoptysis to the Emergency Department. He initially thought his symptoms were due to a chest infection but a course of amoxicillin from his GP has not helped. He now feels short of breath on mild exertion and has coughed up fresh blood on a number of occasions today.

On examination his oxygen saturations are 92% on air. On examination he has crackles predominately in the upper and lower zones of the left lung. Temperature is 37.7ºC.

Hb	13.1 g/dL
WCC	11.3 *10^9/l
Sodium	137 mmol/l
Potassium	4.2 mmol/l
Urea	6.4 mmol/l
Creatinine	123 µmol/l
CRP	188 mg/L

Urine dip: blood +++, leucocytes +

A chest x-ray is requested:

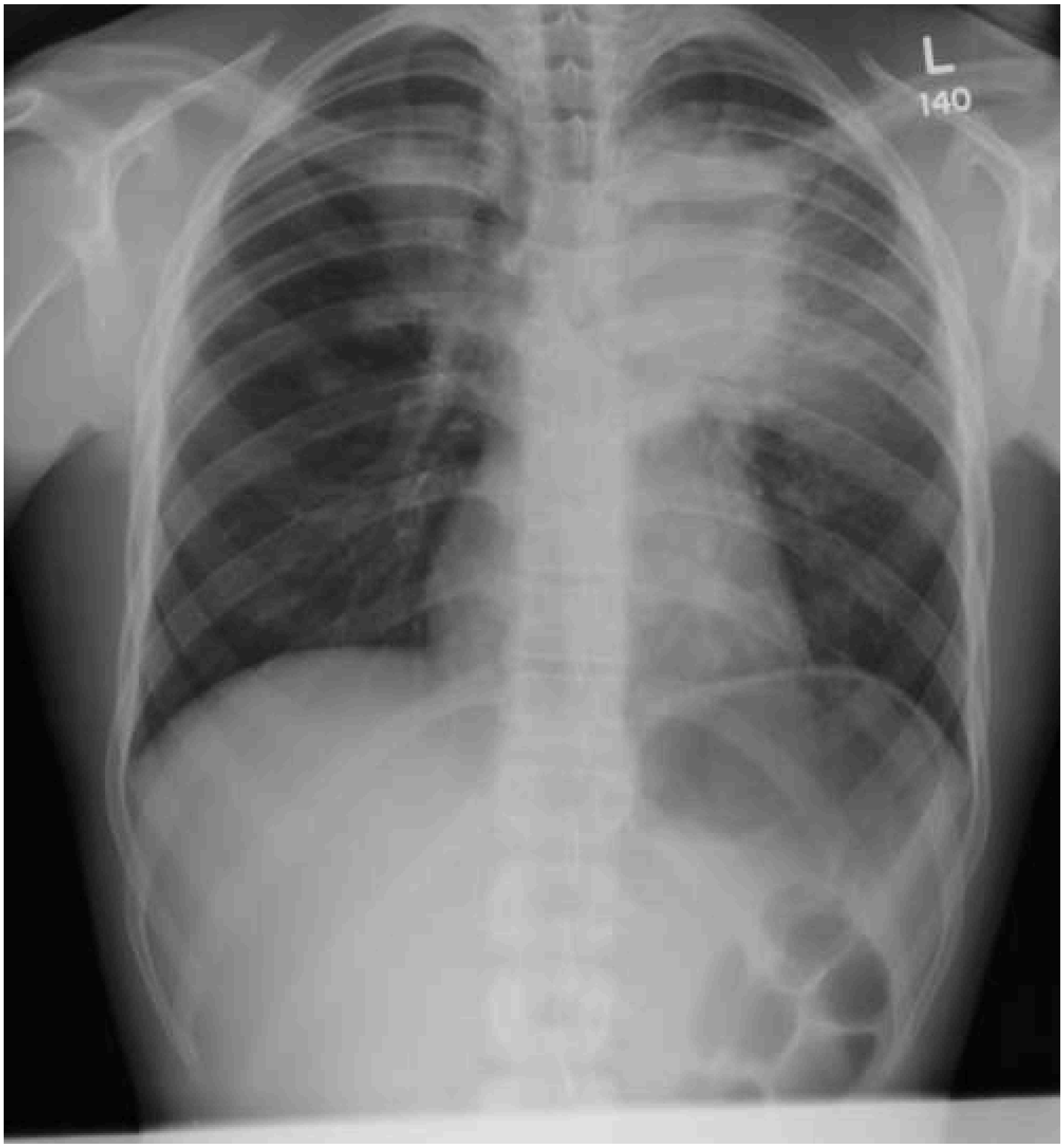

© Image used on license from Radiopaedia

Later tests during his admission show the following;

c-ANCA	Positive
p-ANCA	Positive
Anti-GBM	Negative

What is the most likely diagnosis?

- Granulomatosis with polyangiitis 78%
- Cryptogenic organizing pneumonia 5%
- Churg-Strauss syndrome 9%
- Tuberculosis 1%

Goodpasture's disease 7%

This patient has both the pulmonary and renal manifestations (raised creatinine, heamaturia) of granulomatosis with polyangiitis.

Discuss (6) Improve

Next question

Granulomatosis with polyangiitis

Granulomatosis with polyangiitis is now the preferred term for Wegener's granulomatosis. It is an autoimmune condition associated with a necrotizing granulomatous vasculitis, affecting both the upper and lower respiratory tract as well as the kidneys.

Features

- upper respiratory tract: epistaxis, sinusitis, nasal crusting
- lower respiratory tract: dyspnoea, haemoptysis
- rapidly progressive glomerulonephritis ('pauci-immune', 80% of patients)
- saddle-shape nose deformity
- also: vasculitic rash, eye involvement (e.g. proptosis), cranial nerve lesions

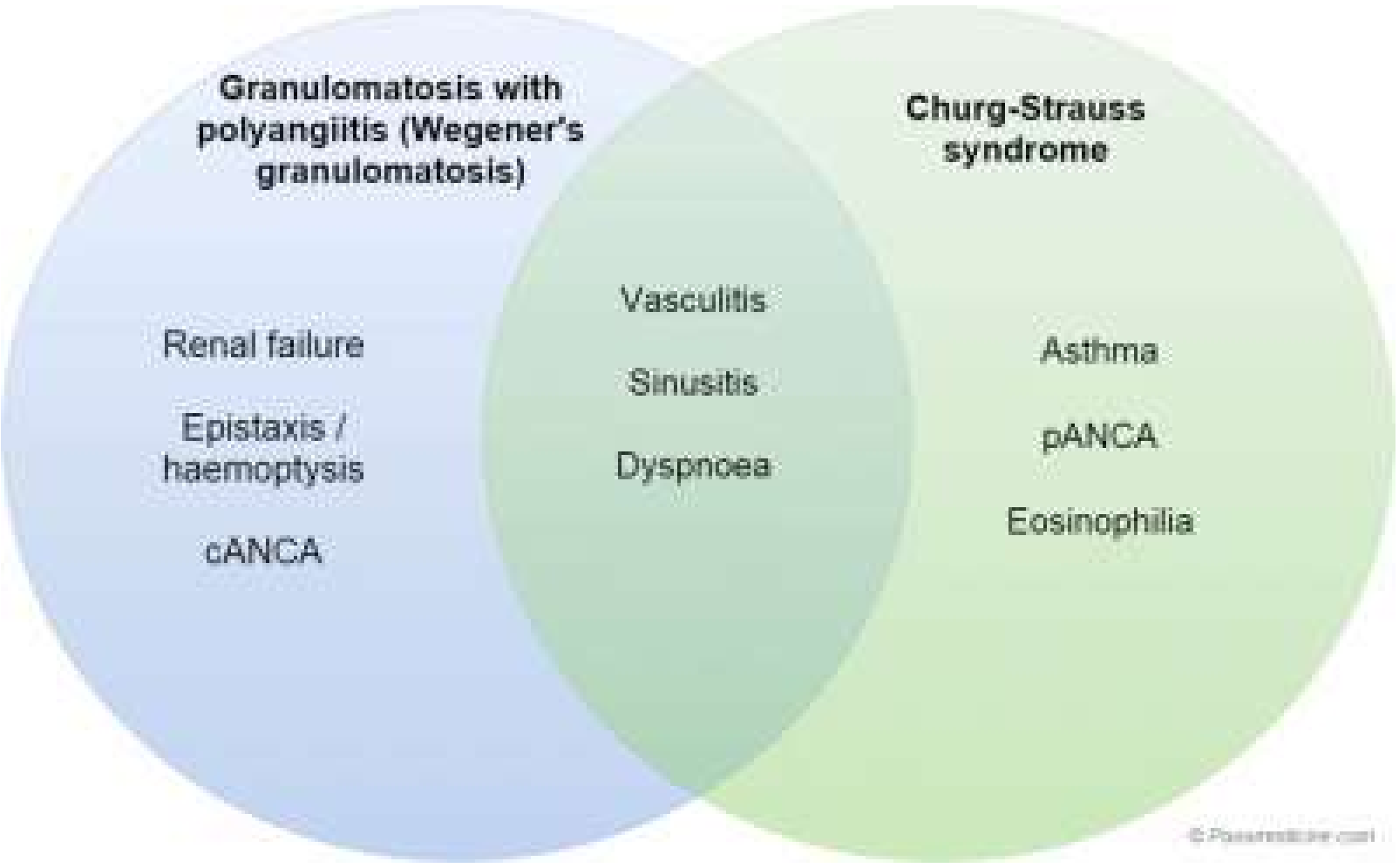

Comparison of granulomatosis with polyangiitis and Churg-Strauss syndrome

Investigations

- cANCA positive in > 90%, pANCA positive in 25%

- chest x-ray: wide variety of presentations, including cavitating lesions
- renal biopsy: epithelial crescents in Bowman's capsule

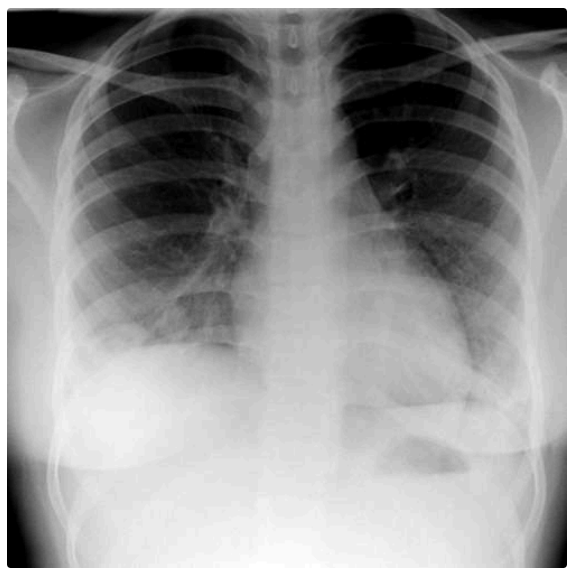

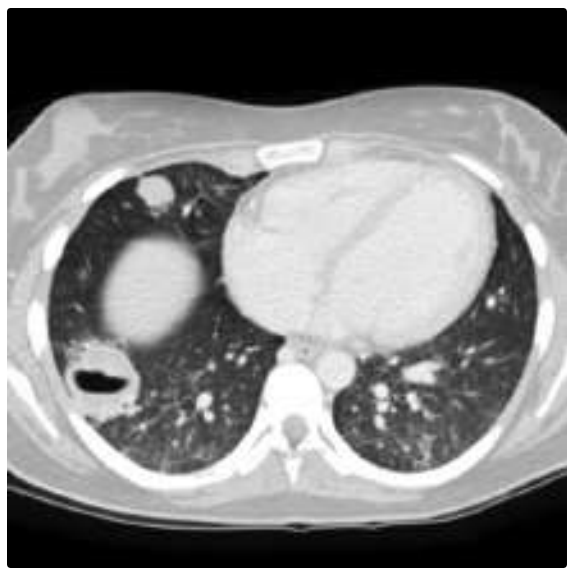

Management
- steroids
- cyclophosphamide (90% response)
- plasma exchange
- median survival = 8-9 years

+ Q 123

Next question

Textbooks

High-yield textbook

Extended textbook

Media

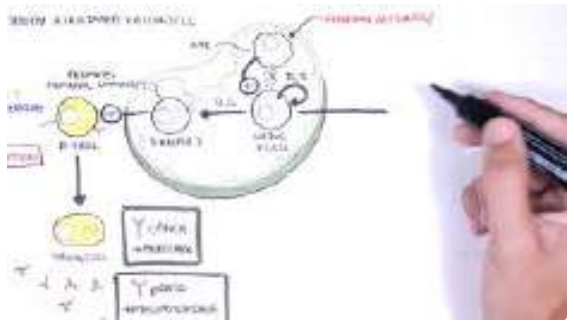

ANCA (Anti-Neutrophil Cytoplasmic Antibody) Associated Vasculitis - Causes, Pathophysiology, Types

Armando Hasudungan - YouTube 5 1

Granulomatosis with polyangiitis

Armando Hasudungan - YouTube 5 2

Report broken media

Score: **24%**

1	✗
2	✗
3	✗
4	✗
5	✗
6	✗
7	✗
8	✗
9	✓
10	✓
11	✗
12	✗
13	✗
14	✓
15	✗
16	✓
17	✗
18	✗
19	✗
20	✗
21	✓

22	✓
23	✗
24	✗
25	✗

All contents of this site are © 2024 Passmedicine Limited

A 67-year-old gentleman comes for review following a two-week-wait referral to the respiratory clinic. He is a current smoker with a 60 pack-year history. He has been suffering from a worsening cough and haemoptysis for the last month and has had a weight loss of 3kg over one month. On examination he looks cachectic, his fingers are clubbed and tar-stained. His wrists are tender. His chest shows reduced expansion on the right side with reduced breath sounds and dullness. What is the wrist tenderness likely to indicate?

- Osteoarthritis
- Osteoporosis
- Osteopenia
- Paraneoplastic rheumatoid-like disease
- Hypertrophic pulmonary osteoarthropathy

Submit answer

Reference ranges

Score: **0%**

1 -
2 -
3 -
4 -
5 -
6 -
7 -
8 -

9	-

All contents of this site are © 2024 Passmedicine Limited

A 67-year-old gentleman comes for review following a two-week-wait referral to the respiratory clinic. He is a current smoker with a 60 pack-year history. He has been suffering from a worsening cough and haemoptysis for the last month and has had a weight loss of 3kg over one month. On examination he looks cachectic, his fingers are clubbed and tar-stained. His wrists are tender. His chest shows reduced expansion on the right side with reduced breath sounds and dullness. What is the wrist tenderness likely to indicate?

Osteoarthritis	1%
Osteoporosis	0%
Osteopenia	2%
Paraneoplastic rheumatoid-like disease	6%
Hypertrophic pulmonary osteoarthropathy	91%

The correct answer is hypertrophic pulmonary osteoarthropathy. This is a patient who is very likely to have lung cancer. He has a heavy smoking history, haemoptysis and weight loss with worrying examination features. Wrist tenderness is likely to be secondary to this in the form of a paraneoplastic hypertrophic pulmonary osteoarthropathy due to squamous cell lung cancer. This is suggested by the clubbing, caused in a similar way. Wrist tenderness is unlikely to occur with osteoarthritis, osteopenia and osteoporosis. Paraneoplastic rheumatoid-like disease is more likely to be asymmetrical and affect the lower limbs.

Discuss (1) Improve

Next question

Lung cancer: paraneoplastic features

Small cell

- ADH
- ACTH - not typical, hypertension, hyperglycaemia, hypokalaemia, alkalosis and muscle weakness are more common than buffalo hump etc

- Lambert-Eaton syndrome

Squamous cell

- parathyroid hormone-related protein (PTH-rp) secretion causing hypercalcaemia
- clubbing
- hypertrophic pulmonary osteoarthropathy (HPOA)
- hyperthyroidism due to ectopic TSH

Adenocarcinoma

- gynaecomastia
- hypertrophic pulmonary osteoarthropathy (HPOA)

© Image used on license from Radiopaedia

Hypertrophic pulmonary osteoarthropathy is a proliferative periostisis involving that typically involves the long bones. It is often painful.

*whilst it is traditionally taught that HPOA is most common with squamous cell carcinoma some studies indicate that adenocarcinoma is the most common cause e.g. https://www.ncbi.nlm.nih.gov/pmc/articles/PMC4049689/

AI + Q 123

Next question

Textbooks

High-yield textbook

Extended textbook

Links

Mayo Clinic 8 8

Paraneoplastic Syndromes: An Approach to Diagnosis and Treatment

Suggest link Report broken link

Media

Lung cancer

MedFlix - YouTube 6 0

Lung Cancer: An Overview

Oncology for Medical Students - YouTube

3 0



[Hypercalcemia in malignancy]

Armando Hasudungan - YouTube 3 1

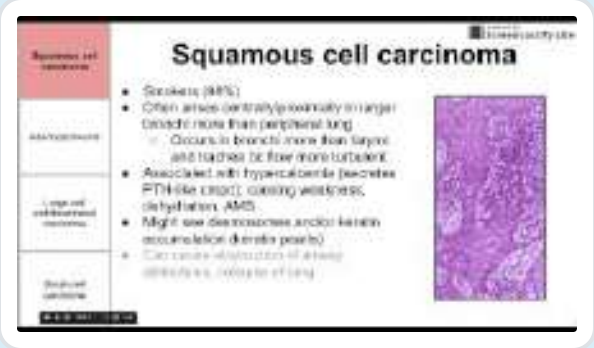

[Cancers of the lung]

MedLecturesMadeEasy - YouTube 2 2

Report broken media

Score: **24%**

1	✗
2	✗
3	✗
4	✗
5	✗
6	✗
7	✗
8	✗
9	✓
10	✓
11	✗
12	✗
13	✗
14	✓
15	✗

16	✓
17	✗
18	✗
19	✗
20	✗
21	✓
22	✓
23	✗
24	✗
25	✗

All contents of this site are © 2024 Passmedicine Limited

Back to top

A 44-year-old man attends with a one-week history of fever and cough. A systematic enquiry was otherwise unremarkable. On examination, you note right-sided coarse crepitations. The examination was otherwise unremarkable.

Blood results are as follows:

Hb	115 g/L	Male: (135-180) Female: (115 - 160)
Platelets	524 * 10^9/L	(150 - 400)
WBC	18.2 * 10^9/L	(4.0 - 11.0)
Neuts	14.8 * 10^9/L	(2.0 - 7.0)
Lymphs	3.0 * 10^9/L	(1.0 - 3.5)
Mono	0.2 * 10^9/L	(0.2 - 0.8)
Eosin	0.2 * 10^9/L	(0.0 - 0.4)

Na^+	132 mmol/L	(135 - 145)
K^+	4.8 mmol/L	(3.5 - 5.0)
Urea	24.2 mmol/L	(2.0 - 7.0)
Creatinine	381 µmol/L	(55 - 120)
CRP	22 mg/L	(< 5)
ANCA PR3	8.2 IU/ml = Positive	(< 2)

Total serum IgE	246 KU/l	(5 - 120)
Aspergillus specific IgG or IgE	Positive	

A CT chest is performed:

CT chest	Hazy consolidation or ground-glass infiltrates in the right lower lobe lung parenchyma suggestive of an intra-alveolar haemorrhage

What is the most likely diagnosis?

- Allergic bronchopulmonary aspergillosis (ABPA)

- Churg-Strauss syndrome
- Goodpasture's disease
- Hypereosinophilic syndrome
- Wegener's granulomatosis

Submit answer

Reference ranges

Score: **0%**

1	-
2	-
3	-
4	-
5	-
6	-
7	-
8	-
9	-
10	-

All contents of this site are © 2024 Passmedicine Limited

Back to top

A 44-year-old man attends with a one-week history of fever and cough. A systematic enquiry was otherwise unremarkable. On examination, you note right-sided coarse crepitations. The examination was otherwise unremarkable.

Blood results are as follows:

Hb	115 g/L	Male: (135-180) Female: (115 - 160)
Platelets	524 * 10^9/L	(150 - 400)
WBC	18.2 * 10^9/L	(4.0 - 11.0)
Neuts	14.8 * 10^9/L	(2.0 - 7.0)
Lymphs	3.0 * 10^9/L	(1.0 - 3.5)
Mono	0.2 * 10^9/L	(0.2 - 0.8)
Eosin	0.2 * 10^9/L	(0.0 - 0.4)

Na^+	132 mmol/L	(135 - 145)
K^+	4.8 mmol/L	(3.5 - 5.0)
Urea	24.2 mmol/L	(2.0 - 7.0)
Creatinine	381 µmol/L	(55 - 120)
CRP	22 mg/L	(< 5)
ANCA PR3	8.2 IU/ml = Positive	(< 2)

Total serum IgE	246 KU/l	(5 - 120)
Aspergillus specific IgG or IgE	Positive	

A CT chest is performed:

CT chest	Hazy consolidation or ground-glass infiltrates in the right lower lobe lung parenchyma suggestive of an intra-alveolar haemorrhage

What is the most likely diagnosis?

Allergic bronchopulmonary aspergillosis (ABPA) 26%

Churg-Strauss syndrome 14%

Goodpasture's disease 13%

Hypereosinophilic syndrome 1%

Wegener's granulomatosis 45%

Consider granulomatosis with polyangiitis when a patient presents with ENT, respiratory and kidney involvement

Important for me Less important

Wegener's granulomatosis is correct. This condition is characterised by necrotizing granulomatous inflammation of the upper and/or lower respiratory tract, and vasculitis of small-to-medium-sized vessels. The presence of a pulmonary haemorrhage and renal failure, combined with a strongly positive ANCA makes this the most likely diagnosis.

Allergic bronchopulmonary aspergillosis (ABPA) is incorrect. Although the patient has a positive aspergillus-specific antibody result and raised total serum IgE, the clinical features, in this case, do not support a diagnosis of ABPA. ABPA presents with shortness of breath, cough, and wheezing. As *Aspergillus fumigatus* spores are common in the environment and almost everyone is exposed to them, low levels of antibodies to *A. fumigatus* are found in many patients and are often not clinically significant.

Churg-Strauss syndrome is incorrect. Churg-Strauss syndrome, also known as allergic granulomatous angiitis, is a rare disease characterised by the triad of asthma, pulmonary infiltrates, and hypereosinophilia. Although this remains within the differential diagnosis, the acute onset, presence of renal failure, and strongly positive ANCA with a PR3 subtype favours the diagnosis of Wegener's granulomatosis. Churg-Strauss syndrome is classically associated with the MPO subtype of ANCA.

Goodpasture's disease is incorrect. Pulmonary haemorrhage and renal failure are classical features of this condition. However, this condition is associated with anti-GBM antibodies rather than ANCA, making this a less likely diagnosis.

Hypereosinophilic syndrome is incorrect. Hypereosinophilic syndrome (HES) is a diagnosis of exclusion and should be made only after reactive and clonal eosinophilia have been excluded. The absence of eosinophilia makes this a less likely diagnosis.

Discuss (3) Improve

Next question >

Granulomatosis with polyangiitis

Granulomatosis with polyangiitis is now the preferred term for Wegener's granulomatosis. It is an autoimmune condition associated with a necrotizing granulomatous vasculitis, affecting both the upper and lower respiratory tract as well as the kidneys.

Features

- upper respiratory tract: epistaxis, sinusitis, nasal crusting
- lower respiratory tract: dyspnoea, haemoptysis
- rapidly progressive glomerulonephritis ('pauci-immune', 80% of patients)
- saddle-shape nose deformity
- also: vasculitic rash, eye involvement (e.g. proptosis), cranial nerve lesions

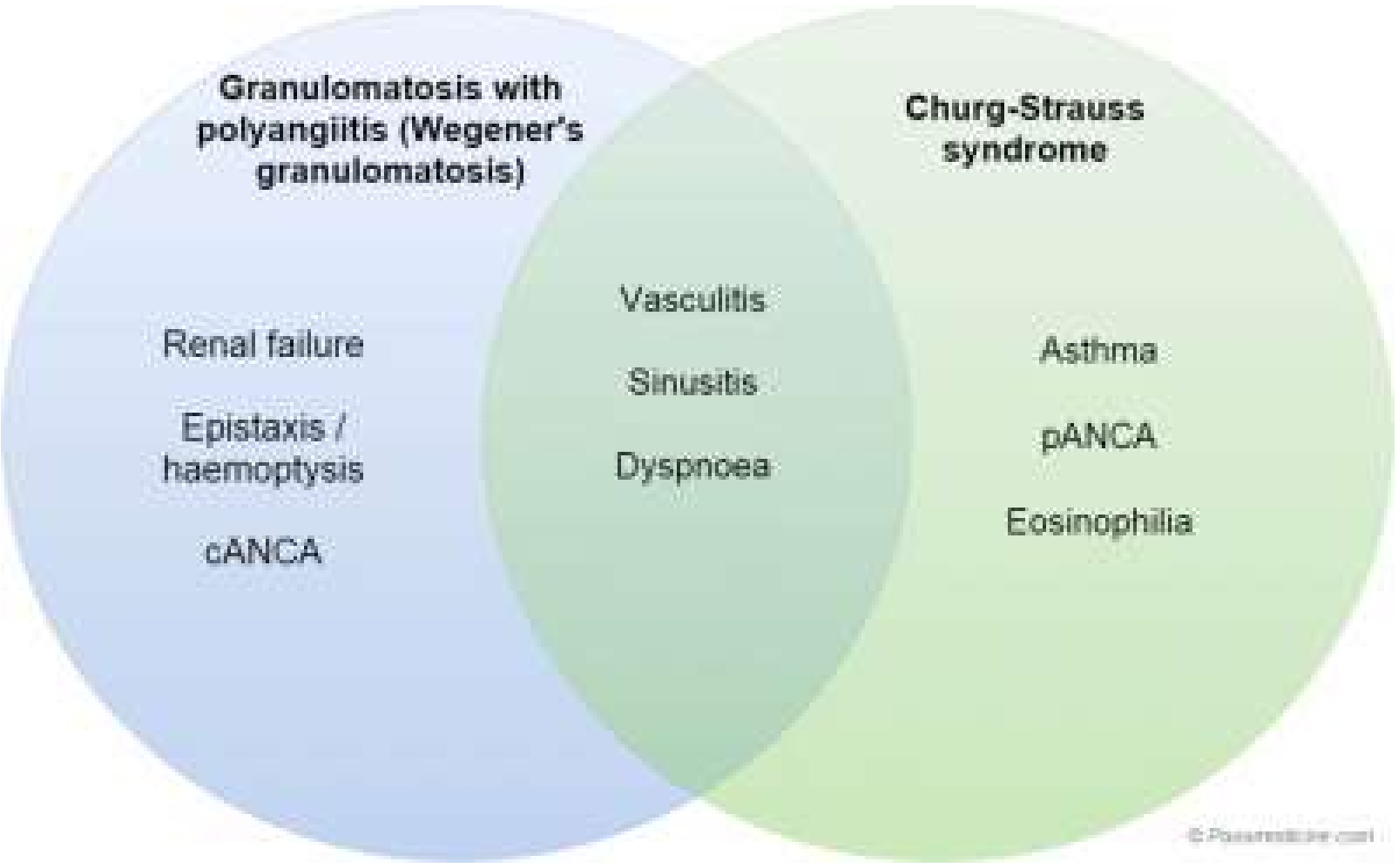

Comparison of granulomatosis with polyangiitis and Churg-Strauss syndrome

Investigations

- cANCA positive in > 90%, pANCA positive in 25%
- chest x-ray: wide variety of presentations, including cavitating lesions
- renal biopsy: epithelial crescents in Bowman's capsule

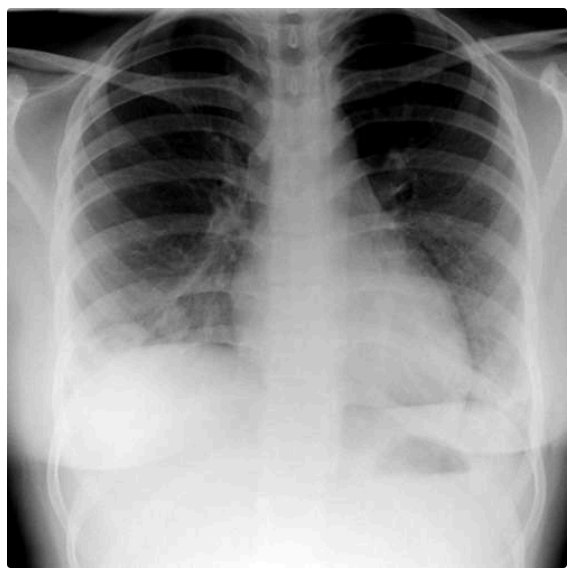

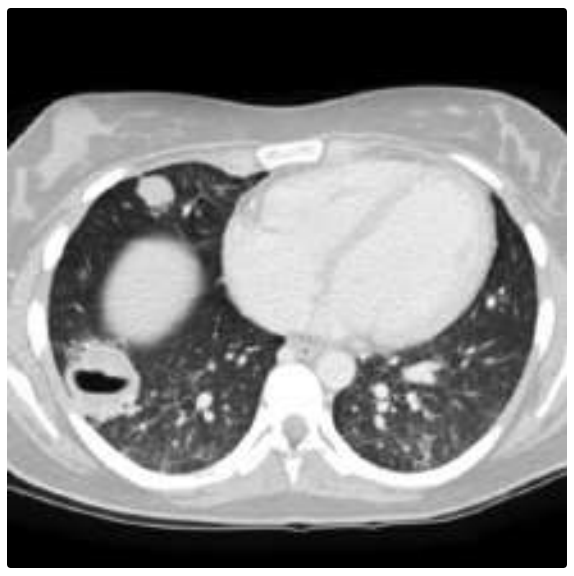

Management

- steroids
- cyclophosphamide (90% response)
- plasma exchange
- median survival = 8-9 years

123

Next question

Textbooks

High-yield textbook

Extended textbook

Media

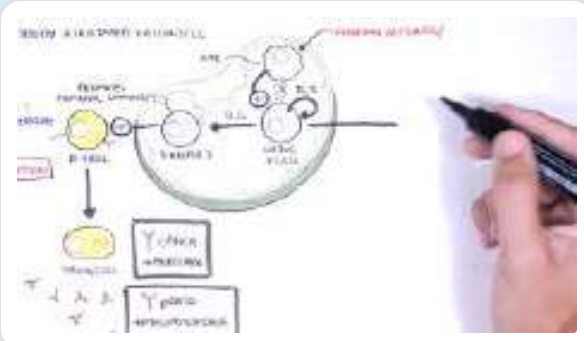

ANCA (Anti-Neutrophil Cytoplasmic Antibody) Associated Vasculitis - Causes, Pathophysiology, Types

Armando Hasudungan - YouTube

5 1

Granulomatosis with polyangiitis

Armando Hasudungan - YouTube

5 2

Report broken media

Score: **24%**

1	✗
2	✗
3	✗
4	✗
5	✗
6	✗
7	✗
8	✗
9	✓
10	✓
11	✗
12	✗
13	✗
14	✓
15	✗
16	✓
17	✗
18	✗
19	✗
20	✗
21	✓
22	✓
23	✗
24	✗

25 ✕

All contents of this site are © 2024 Passmedicine Limited

A 53-year-old man is admitted to the Emergency Department complaining of a 'chest infection'. His symptoms have not improved despite a course of antibiotics from his GP. The admission chest x-ray is shown below:

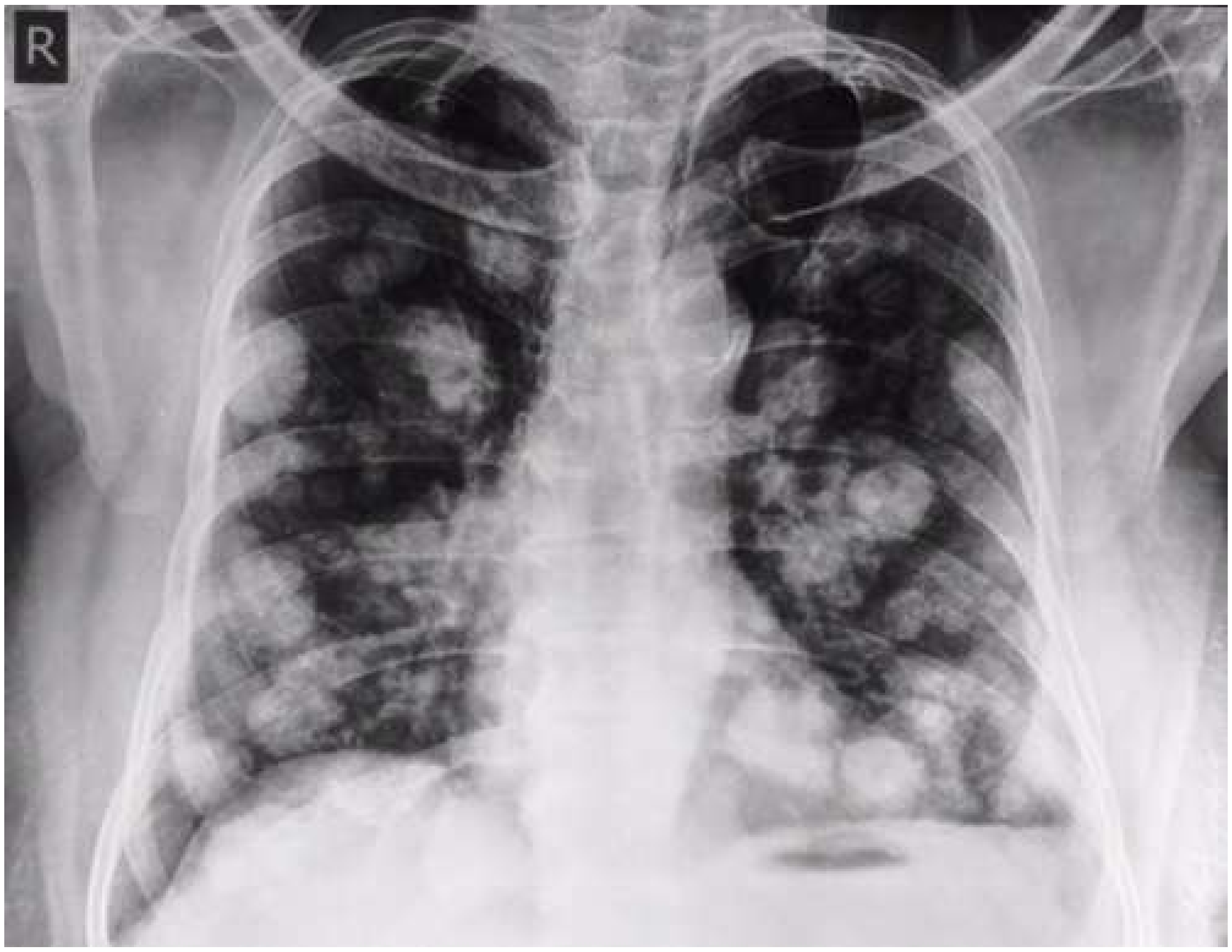

© Image used on license from Radiopaedia

What is the most appropriate next-line investigation?

- High resolution CT thorax
- CT abdomen
- Testicular ultrasound
- Bronchoscopy
- Sputum culture

Submit answer

Reference ranges

Score: **0%**

1 -
2 -
3 -
4 -
5 -
6 -
7 -
8 -
9 -
10 -
11 -

All contents of this site are © 2024 Passmedicine Limited

A 53-year-old man is admitted to the Emergency Department complaining of a 'chest infection'. His symptoms have not improved despite a course of antibiotics from his GP. The admission chest x-ray is shown below:

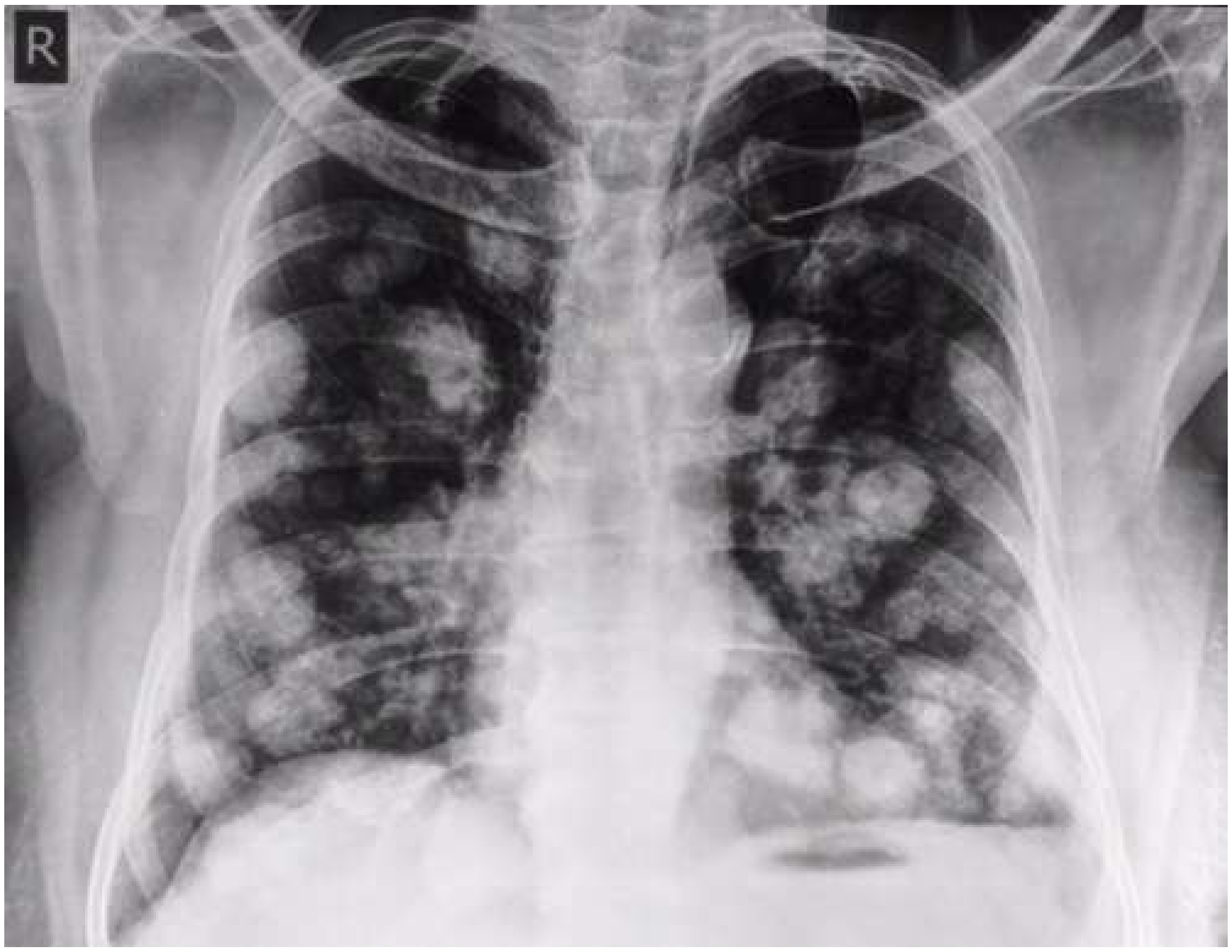

© Image used on license from Radiopaedia

What is the most appropriate next-line investigation?

High resolution CT thorax	34%
CT abdomen	43%
Testicular ultrasound	14%
Bronchoscopy	6%
Sputum culture	3%

The chest x-ray shows cannonball metastases which are most commonly caused by renal cell cancer. A CT abdomen is the most appropriate test to investigate this possibility.

Other tests should of course be considered including a prostate specific antigen.

Discuss (5) Improve

Next question

Chest x-ray: lung metastases

Lung metastases are seen with a wide variety of cancers including:

- breast cancer
- colorectal cancer
- renal cell cancer
- bladder cancer
- prostate cancer

Multiple, round well-defined lung secondaries are often referred to as 'cannonball metastases'. They are most commonly seen with renal cell cancer but may also occur secondary to choriocarcinoma and prostate cancer.

Calcification in lung metastases is uncommon except in the case of chondrosarcoma or osteosarcoma.

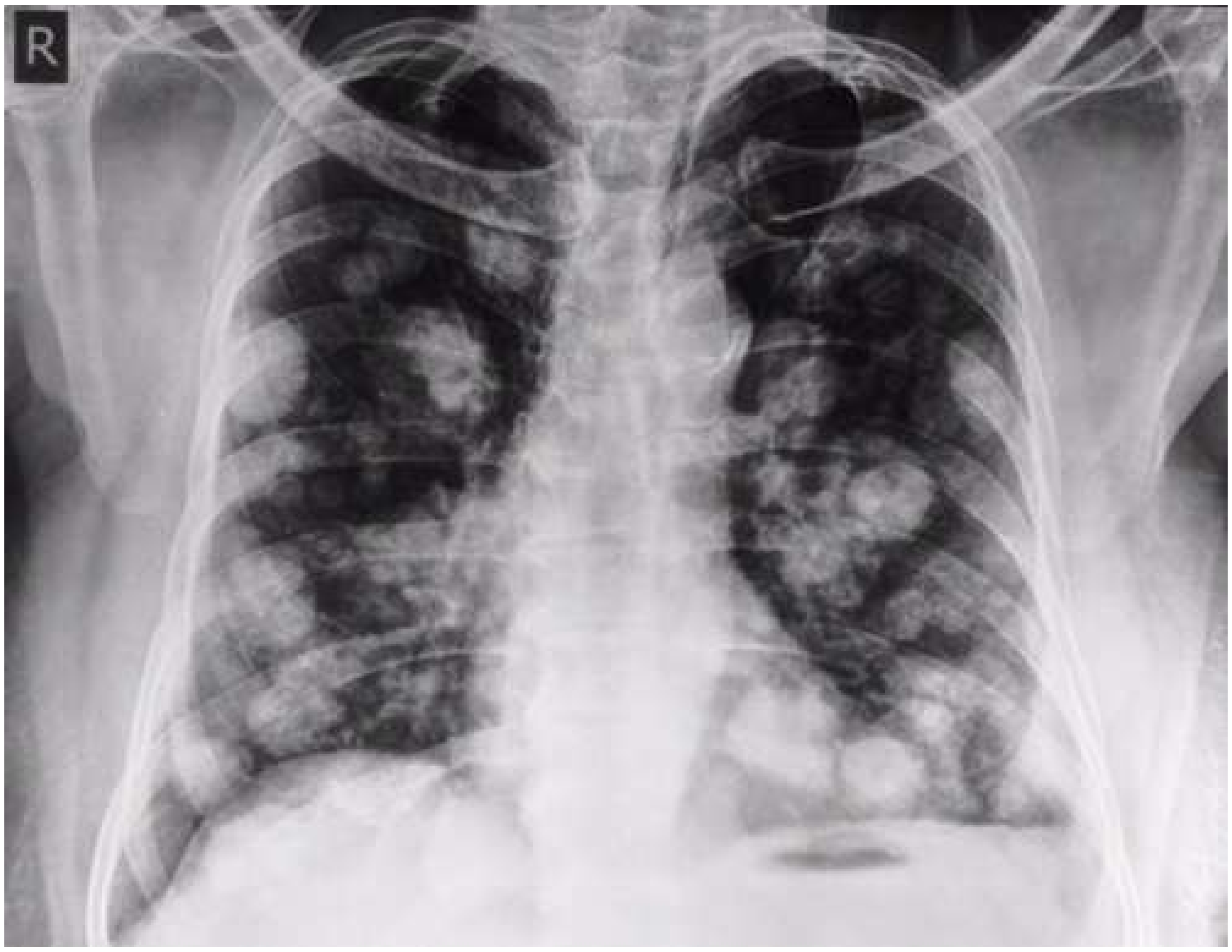

© Image used on license from Radiopaedia

Chest x-ray showing **cannonball metastases** secondary to renal cell cancer. Multiple well defined nodules are noted distributed in both lung fields

123

Next question

Textbooks

High-yield textbook

Extended textbook

Score: **24%**

1	✗
2	✗
3	✗
4	✗
5	✗
6	✗
7	✗
8	✗
9	✓
10	✓
11	✗
12	✗

13	✗
14	✓
15	✗
16	✓
17	✗
18	✗
19	✗
20	✗
21	✓
22	✓
23	✗
24	✗
25	✗

All contents of this site are © 2024 Passmedicine Limited

Back to top

A 52-year-old man presents with a 5 day history of cough, feeling hot and facial pains. He is generally fit and well although does currently take sertraline for anxiety and depression. He describes a cough productive of pale yellow sputum. He also describes difficulty breathing through his nose and pain in his face, particularly when coughing on leaning forward.

On examination he is alert, pulse rate is 84/min, temperature is 37.3º and respiratory rate is 16/min. His blood pressure is 122/74 mmHg. Chest auscultation is unremarkable. He is tender over the maxilla.

What is the most appropriate next step in management?

- Check serum urea for CURB-65 scoring
- Oral amoxicillin + review in 3-4 days if not improving
- Advise paracetamol for symptoms + review in 3-4 days if not improving
- Arrange a chest x-ray
- Oral clarithromycin + review in 3-4 days if not improving

Submit answer

Reference ranges

Score: **0%**

1 -
2 -
3 -
4 -
5 -

6	-
7	-
8	-
9	-
10	-
11	-
12	-

All contents of this site are © 2024 Passmedicine Limited

A 52-year-old man presents with a 5 day history of cough, feeling hot and facial pains. He is generally fit and well although does currently take sertraline for anxiety and depression. He describes a cough productive of pale yellow sputum. He also describes difficulty breathing through his nose and pain in his face, particularly when coughing on leaning forward.

On examination he is alert, pulse rate is 84/min, temperature is 37.3° and respiratory rate is 16/min. His blood pressure is 122/74 mmHg. Chest auscultation is unremarkable. He is tender over the maxilla.

What is the most appropriate next step in management?

Check serum urea for CURB-65 scoring	4%
Oral amoxicillin + review in 3-4 days if not improving	34%
Advise paracetamol for symptoms + review in 3-4 days if not improving	42%
Arrange a chest x-ray	15%
Oral clarithromycin + review in 3-4 days if not improving	5%

This patient has a viral upper respiratory tract infection. His examination findings are essential normal other than some facial pain associated with rhinosinusitis. He requires supportive treatment only as per NICE guidelines.

Discuss (6) Improve

Next question

Respiratory tract infections: NICE guidelines

NICE issued guidance in 2008 on the management of respiratory tract infection, focusing on the prescribing of antibiotics for self-limiting respiratory tract infections in adults and children in primary care

A no antibiotic prescribing or delayed antibiotic prescribing approach is generally recommended for patients with acute otitis media, acute sore throat/acute pharyngitis/acute tonsillitis, common cold, acute rhinosinusitis or acute cough/acute bronchitis.

However, an immediate antibiotic prescribing approach may be considered for:
- children younger than 2 years with bilateral acute otitis media
- children with otorrhoea who have acute otitis media
- patients with acute sore throat/acute pharyngitis/acute tonsillitis when 3 or more Centor criteria are present

The Centor criteria* are as follows:
- presence of tonsillar exudate
- tender anterior cervical lymphadenopathy or lymphadenitis
- history of fever
- absence of cough

If the patient is deemed at risk of developing complications, an immediate antibiotic prescribing policy is recommended
- are systemically very unwell
- have symptoms and signs suggestive of serious illness and/or complications (particularly pneumonia, mastoiditis, peritonsillar abscess, peritonsillar cellulitis, intraorbital or intracranial complications)
- are at high risk of serious complications because of pre-existing comorbidity. This includes patients with significant heart, lung, renal, liver or neuromuscular disease, immunosuppression, cystic fibrosis, and young children who were born prematurely
- are older than 65 years with acute cough and two or more of the following, or older than 80 years with acute cough and one or more of the following:
- - hospitalisation in previous year
- - type 1 or type 2 diabetes
- - history of congestive heart failure
- - current use of oral glucocorticoids

The guidelines also suggest that patients should be advised how long respiratory tract infections may last:
- acute otitis media: 4 days
- acute sore throat/acute pharyngitis/acute tonsillitis: 1 week
- common cold: 1 1/2 weeks
- acute rhinosinusitis: 2 1/2 weeks
- acute cough/acute bronchitis: 3 weeks

*if 3 or more of the criteria are present there is a 40-60% chance the sore throat is caused by

Group A beta-haemolytic *Streptococcus*

123

Next question

Textbooks

High-yield textbook

Extended textbook

Links

NICE

7 6

2008 Respiratory tract infection guidelines

Suggest link

Report broken link

Score: **24%**

1 ✗
2 ✗
3 ✗
4 ✗
5 ✗
6 ✗
7 ✗

8	✗
9	✓
10	✓
11	✗
12	✗
13	✗
14	✓
15	✗
16	✓
17	✗
18	✗
19	✗
20	✗
21	✓
22	✓
23	✗
24	✗
25	✗

All contents of this site are © 2024 Passmedicine Limited

A 63-year-old man with a new diagnosis of idiopathic pulmonary fibrosis is reviewed is respiratory clinic following initial baseline investigations. He has been suffering from progressive shortness of breath for nine months with a non-productive cough. His GP has tried to give him inhalers and antibiotics but this has not helped. He has a past medical history of hypertension, depression and gout. He is concerned about his new diagnosis, especially about his prognosis. What test is most useful in determining prognosis?

- Forced vital capacity
- 6-minute walking test
- High resolution CT of the chest
- Carbon monoxide transfer factor
- FEV1/FVC ratio

Submit answer

Reference ranges

Score: **0%**

1 -
2 -
3 -
4 -
5 -
6 -
7 -
8 -
9 -

10	-
11	-
12	-
13	-

All contents of this site are © 2024 Passmedicine Limited
Back to top

A 63-year-old man with a new diagnosis of idiopathic pulmonary fibrosis is reviewed is respiratory clinic following initial baseline investigations. He has been suffering from progressive shortness of breath for nine months with a non-productive cough. His GP has tried to give him inhalers and antibiotics but this has not helped. He has a past medical history of hypertension, depression and gout. He is concerned about his new diagnosis, especially about his prognosis. What test is most useful in determining prognosis?

Forced vital capacity	38%
6-minute walking test	21%
High resolution CT of the chest	12%
Carbon monoxide transfer factor	19%
FEV1/FVC ratio	10%

The correct answer is carbon monoxide transfer factor. The 6-minute walking test is not useful for prognosis, whilst CT is more useful in determining aetiology. The FEV1/FVC ratio would confirm a restrictive pattern consistent with fibrosis, but this would not help defining prognosis. Serial measurements of forced vital capacity can be helpful in understanding the disease course and establishing progression, but at the first appointment this is unlikely to be helpful.

Discuss (12) Improve

Next question

Idiopathic pulmonary fibrosis

Idiopathic pulmonary fibrosis (IPF, previously termed cryptogenic fibrosing alveolitis) is a chronic lung condition characterised by progressive fibrosis of the interstitium of the lungs. Whilst there are many causes of lung fibrosis (e.g. medications, connective tissue disease, asbestos) the term IPF is reserved when no underlying cause exists.

IPF is typically seen in patients aged 50-70 years and is twice as common in men.

Features
- progressive exertional dyspnoea
- bibasal fine end-inspiratory crepitations on auscultation
- dry cough
- clubbing

Diagnosis
- spirometry: classically a restrictive picture (FEV1 normal/decreased, FVC decreased, FEV1/FVC increased)
- impaired gas exchange: reduced transfer factor (TLCO)
- imaging: bilateral interstitial shadowing (typically small, irregular, peripheral opacities - 'ground-glass' - later progressing to 'honeycombing') may be seen on a chest x-ray but high-resolution CT scanning is the investigation of choice and required to make a diagnosis of IPF
- ANA positive in 30%, rheumatoid factor positive in 10% but this does not necessarily mean that the fibrosis is secondary to a connective tissue disease. Titres are usually low

Management
- pulmonary rehabilitation
- very few medications have been shown to give any benefit in IPF. There is some evidence that pirfenidone (an antifibrotic agent) may be useful in selected patients (see NICE guidelines)
- many patients will require supplementary oxygen and eventually a lung transplant

Prognosis
- poor, average life expectancy is around 3-4 years

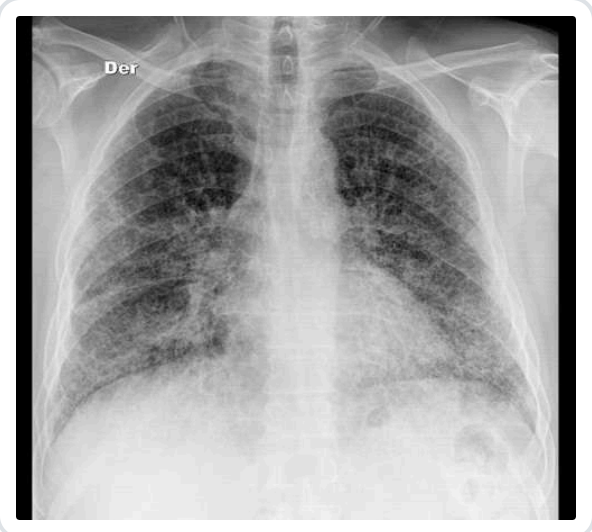

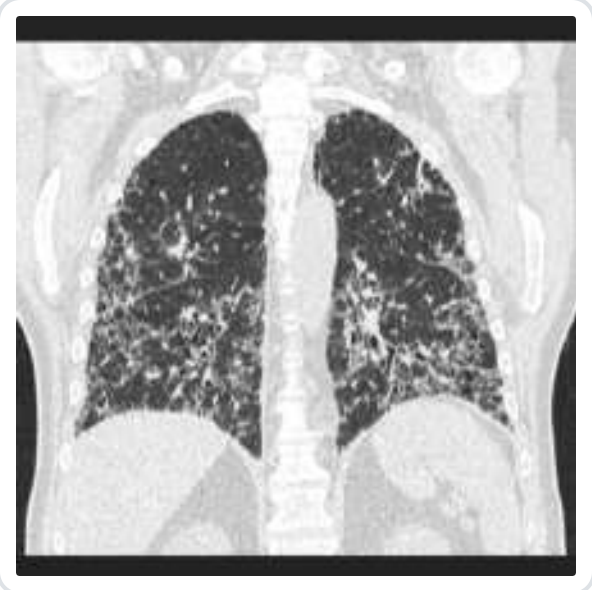

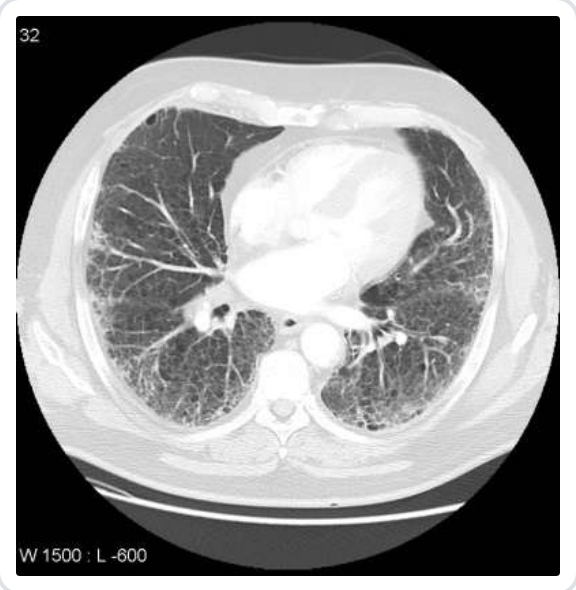

123

Next question

Textbooks

High-yield textbook

Extended textbook

Links

Royal College of Physicians 13 10

Update in diagnosis and management of interstitial lung disease

NICE 11 6

2013 Idiopathic pulmonary fibrosis guidelines

Suggest link

Report broken link

Media

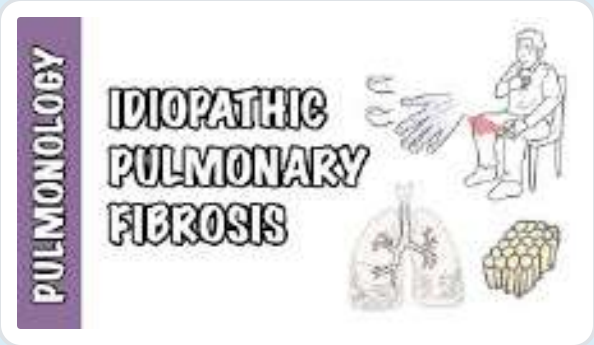

Idiopathic pulmonary fibrosis

Armando Hasudungan - YouTube 6 0

Interstitial Lung Disease (ILD) - Classification, pathophysiology, signs and symptoms

Armando Hasudungan - YouTube 5 0

Idiopathic pulmonary fibrosis

Osmosis - YouTube

4 0

Report broken media

Score: **24%**

1	✗
2	✗
3	✗
4	✗
5	✗
6	✗
7	✗
8	✗
9	✓
10	✓
11	✗
12	✗
13	✗
14	✓
15	✗
16	✓
17	✗
18	✗
19	✗
20	✗
21	✓
22	✓
23	✗
24	✗

25 ✕

All contents of this site are © 2024 Passmedicine Limited

Back to top

A 63-year-old retired car mechanic is referred to the respiratory clinic by his GP due to progressive dyspnoea and low oxygen saturations. The GP had performed an ECG and BNP level, both of which were within normal limits.

The dyspnoea had been getting progressively worse for the past 2 years and is now limiting his daily activities. He also describes a dry cough which is worse after walking. There is no history of chest pain, On examination there is no clubbing, pulse is 84/min, respiratory rate 18/min and oxygen saturations are 91% on room air.

An x-ray is requested:

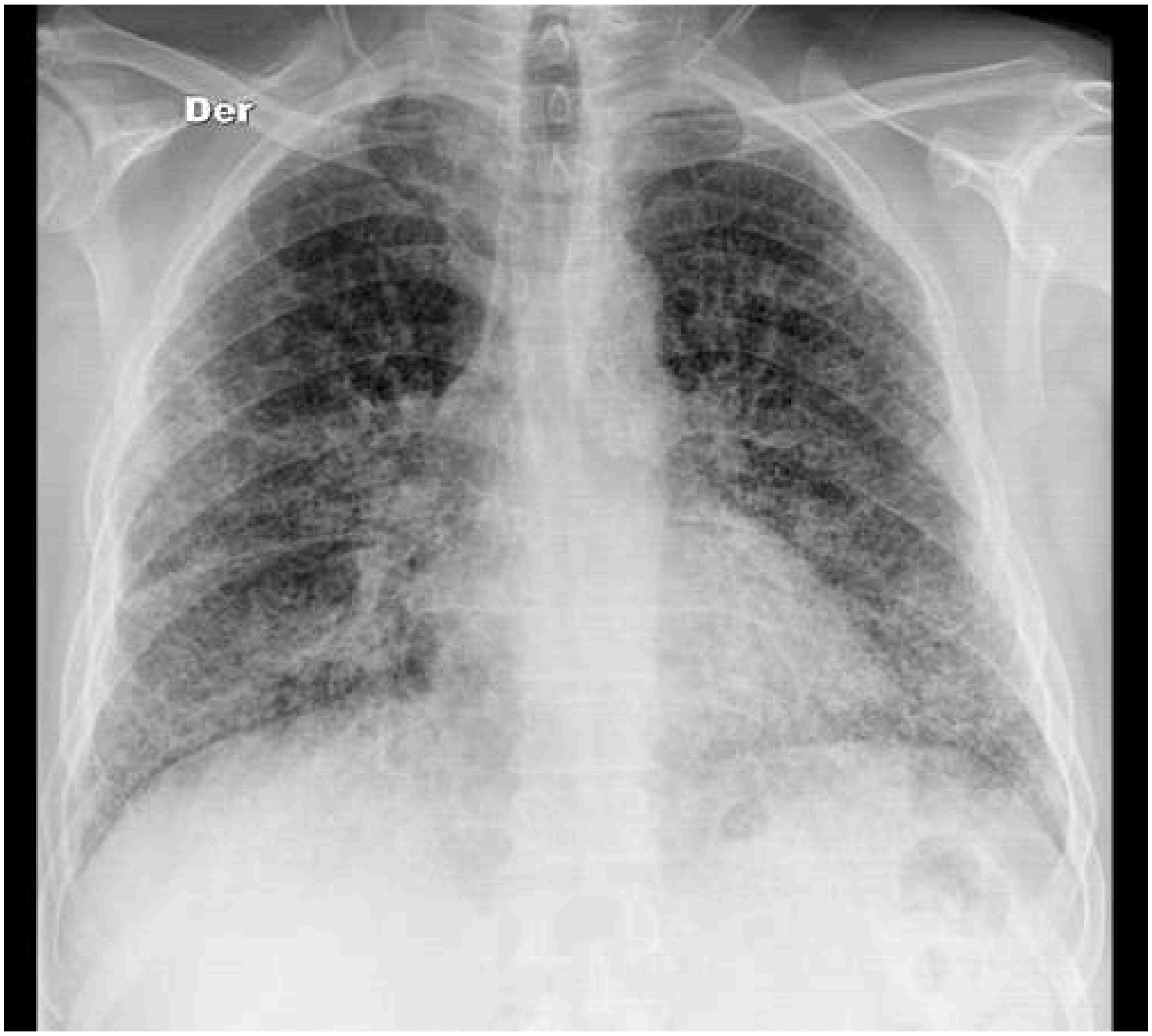

© Image used on license from Radiopaedia

What is the most likely diagnosis

- Sarcoidosis
- Extrinsic allergic alveolitis

- Silicosis
- Bronchiectasis
- Idiopathic pulmonary fibrosis

Submit answer

Reference ranges

Score: **0%**

1	-
2	-
3	-
4	-
5	-
6	-
7	-
8	-
9	-
10	-
11	-
12	-
13	-
14	-

All contents of this site are © 2024 Passmedicine Limited

A 63-year-old retired car mechanic is referred to the respiratory clinic by his GP due to progressive dyspnoea and low oxygen saturations. The GP had performed an ECG and BNP level, both of which were within normal limits.

The dyspnoea had been getting progressively worse for the past 2 years and is now limiting his daily activities. He also describes a dry cough which is worse after walking. There is no history of chest pain, On examination there is no clubbing, pulse is 84/min, respiratory rate 18/min and oxygen saturations are 91% on room air.

An x-ray is requested:

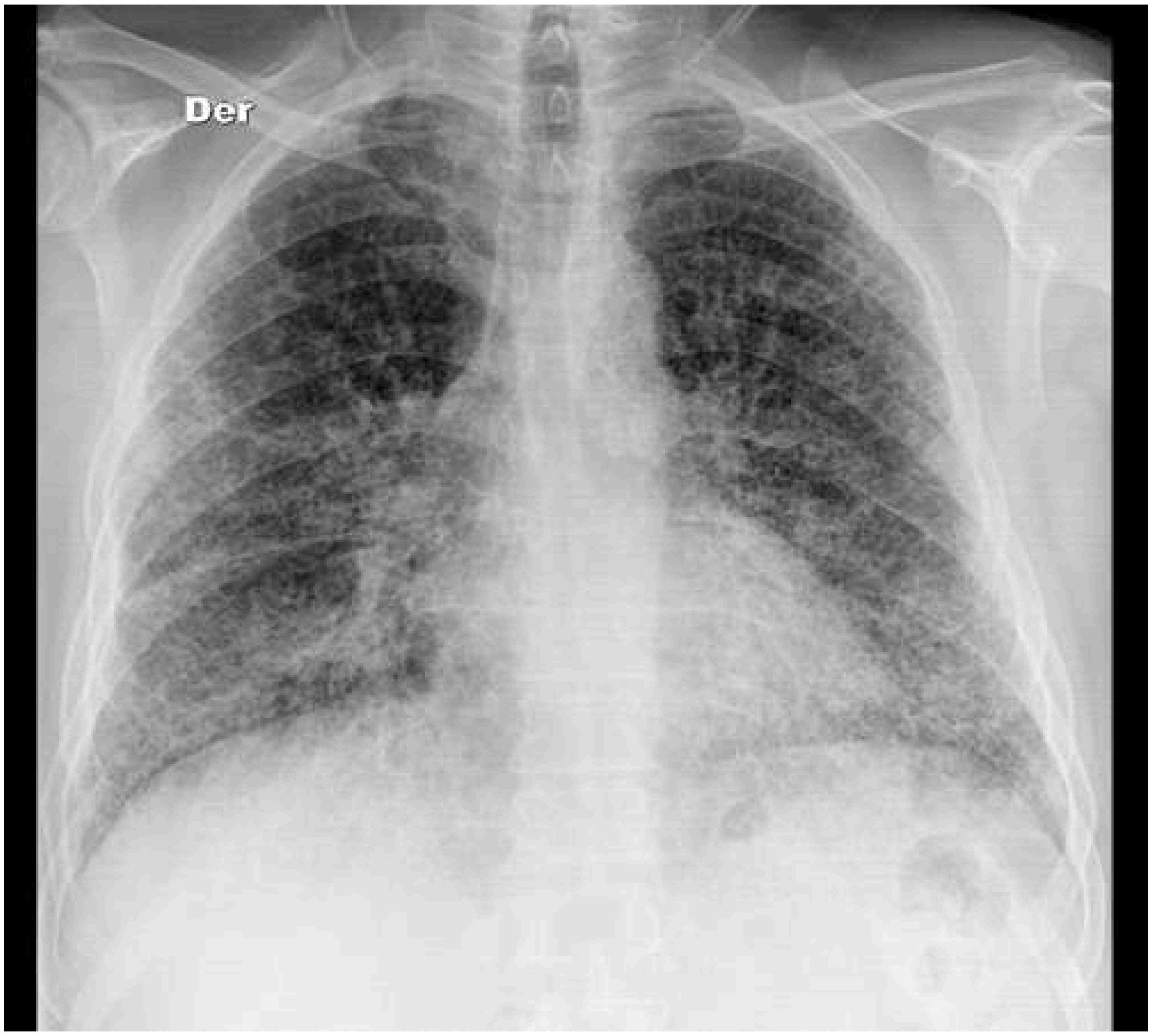

© Image used on license from Radiopaedia

What is the most likely diagnosis

- Sarcoidosis 3%
- Extrinsic allergic alveolitis 10%

Silicosis 16%

Bronchiectasis 1%

Idiopathic pulmonary fibrosis 71%

The chest x-ray shows reitcular opacities predominantly in the bases, a classic finding of idiopathic pulmonary fibrosis.

His occupation is not a risk factor for silicosis. This condition also most commonly affects the upper zones of the lungs.

There is no hilar lymphadenopathy to support a diagnosis of sarcoidosis.

Whilst there is some traction bronchiectasis of the lungs (seen most easily on the associated CT below) this is not the primary diagnosis and the history is not supportive.

With extrinsic allergic alveolitis there is often a relevant occupational history and the upper/mid zones are more commonly affected.

Discuss (5) | Improve

Next question >

Idiopathic pulmonary fibrosis

Idiopathic pulmonary fibrosis (IPF, previously termed cryptogenic fibrosing alveolitis) is a chronic lung condition characterised by progressive fibrosis of the interstitium of the lungs. Whilst there are many causes of lung fibrosis (e.g. medications, connective tissue disease, asbestos) the term IPF is reserved when no underlying cause exists.

IPF is typically seen in patients aged 50-70 years and is twice as common in men.

Features

- progressive exertional dyspnoea
- bibasal fine end-inspiratory crepitations on auscultation
- dry cough
- clubbing

Diagnosis

- spirometry: classically a restrictive picture (FEV1 normal/decreased, FVC decreased, FEV1/FVC increased)
- impaired gas exchange: reduced transfer factor (TLCO)
- imaging: bilateral interstitial shadowing (typically small, irregular, peripheral opacities - 'ground-glass' - later progressing to 'honeycombing') may be seen on a chest x-ray but high-resolution CT scanning is the investigation of choice and required to make a diagnosis of IPF
- ANA positive in 30%, rheumatoid factor positive in 10% but this does not necessarily mean that the fibrosis is secondary to a connective tissue disease. Titres are usually low

Management

- pulmonary rehabilitation
- very few medications have been shown to give any benefit in IPF. There is some evidence that pirfenidone (an antifibrotic agent) may be useful in selected patients (see NICE guidelines)
- many patients will require supplementary oxygen and eventually a lung transplant

Prognosis

- poor, average life expectancy is around 3-4 years

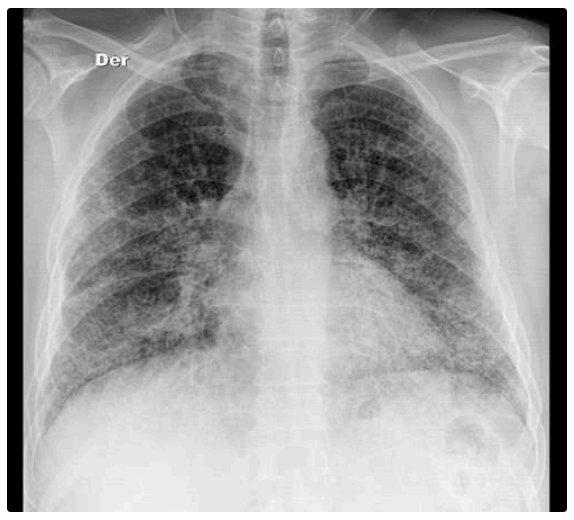

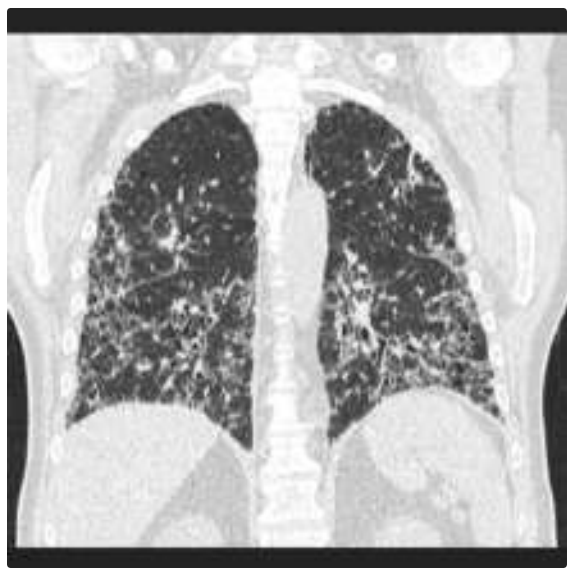

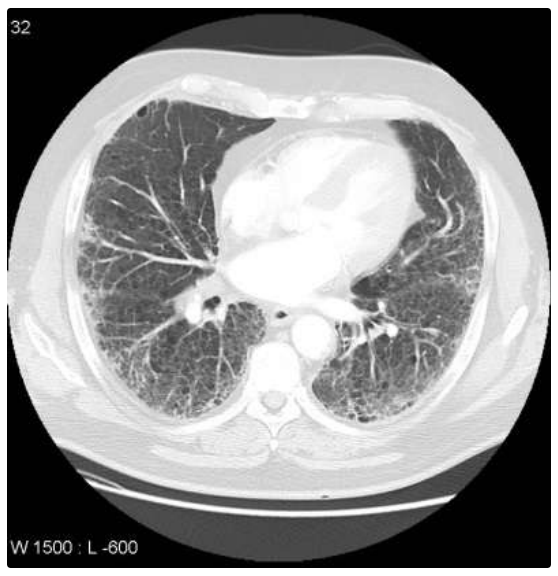

123

Next question

Textbooks

High-yield textbook

Extended textbook

Links

Royal College of Physicians 13 10

Update in diagnosis and management of interstitial lung disease

NICE 11 6

2013 Idiopathic pulmonary fibrosis guidelines

Suggest link Report broken link

Media

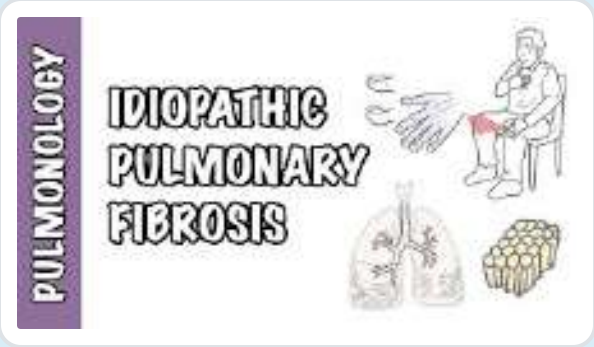

Idiopathic pulmonary fibrosis

Armando Hasudungan - YouTube 6 0

Interstitial Lung Disease (ILD) - Classification, pathophysiology, signs and symptoms

Armando Hasudungan - YouTube 5 0

Idiopathic pulmonary fibrosis

Osmosis - YouTube 4 0

Report broken media

Score: **24%**

1	✗
2	✗
3	✗
4	✗
5	✗
6	✗
7	✗
8	✗
9	✓
10	✓
11	✗
12	✗
13	✗
14	✓
15	✗
16	✓
17	✗
18	✗
19	✗
20	✗
21	✓
22	✓
23	✗
24	✗
25	✗

All contents of this site are © 2024 Passmedicine Limited

Back to top

An 81-year-old man is seen in the respiratory clinic due to poor control of his chronic obstructive pulmonary disease (COPD). Despite being prescribed inhaled salbutamol as required, he remains breathless on minimal exertion which is limiting his ability to carry out daily activities. He reports that these symptoms are consistently present with no diurnal variation.

He has a 50 pack year smoking history. His past medical history includes hypertension for which he takes ramipril and he has no allergies. Recent blood tests performed by the general practitioner show the following:

Hb	141 g/L	Male: (135-180) Female: (115 - 160)
Platelets	301 * 10^9/L	(150 - 400)
WBC	6.3 * 10^9/L	(4.0 - 11.0)
Neuts	4.1 * 10^9/L	(2.0 - 7.0)
Lymphs	1.7 * 10^9/L	(1.0 - 3.5)
Mono	0.4 * 10^9/L	(0.2 - 0.8)
Eosin	0.1 * 10^9/L	(0.0 - 0.4)

Which of the following would be most appropriate to initiate?

- Add a leukotriene receptor antagonist
- Add a long acting beta agonist + muscarinic antagonist (LABA + LAMA)
- Add an inhaled corticosteroid (ICS)
- Add prophylactic antibiotics
- Assessment for long term oxygen therapy

Submit answer

Reference ranges

Score: **0%**

1	-
2	-
3	-
4	-
5	-
6	-
7	-
8	-
9	-
10	-
11	-
12	-
13	-
14	-
15	-

All contents of this site are © 2024 Passmedicine Limited

Back to top

An 81-year-old man is seen in the respiratory clinic due to poor control of his chronic obstructive pulmonary disease (COPD). Despite being prescribed inhaled salbutamol as required, he remains breathless on minimal exertion which is limiting his ability to carry out daily activities. He reports that these symptoms are consistently present with no diurnal variation.

He has a 50 pack year smoking history. His past medical history includes hypertension for which he takes ramipril and he has no allergies. Recent blood tests performed by the general practitioner show the following:

Hb	141 g/L	Male: (135-180) Female: (115 - 160)
Platelets	$301 * 10^9/L$	(150 - 400)
WBC	$6.3 * 10^9/L$	(4.0 - 11.0)
Neuts	$4.1 * 10^9/L$	(2.0 - 7.0)
Lymphs	$1.7 * 10^9/L$	(1.0 - 3.5)
Mono	$0.4 * 10^9/L$	(0.2 - 0.8)
Eosin	$0.1 * 10^9/L$	(0.0 - 0.4)

Which of the following would be most appropriate to initiate?

- Add a leukotriene receptor antagonist 2%
- Add a long acting beta agonist + muscarinic antagonist (LABA + LAMA) 86%
- Add an inhaled corticosteroid (ICS) 11%
- Add prophylactic antibiotics 0%
- Assessment for long term oxygen therapy 1%

COPD - still breathless despite using SABA/SAMA and **no** asthma/steroid responsive features → add a LABA + LAMA

Important for me Less important

This man has presented with COPD that has not been adequately controlled by a SABA/SAMA. The next step in management depends on whether he shows asthma/steroid-responsive features. A lack of any history of asthma/atopy, variation in symptoms (including diurnal), and a normal eosinophil count indicates that this man is unlikely to be steroid responsive. Therefore the most appropriate second-line treatment is to add a LABA + LAMA.

Leukotriene receptor antagonists are not used second line in COPD.

ICS is indicated second line if there are any features suggestive of asthma/steroid responsiveness. As these are not present in the history or blood results, a LABA + LAMA is more appropriate.

Prophylactic antibiotics could be considered in cases of recurrent infective exacerbation however this is not the case here.

This man is not yet on optimal medical therapy so an assessment for long-term oxygen therapy would be premature at this stage.

Discuss (1) | Improve

Next question

COPD: stable management

NICE updated its guidelines on the management of chronic obstructive pulmonary disease (COPD) in 2018.

General management

- >smoking cessation advice: including offering nicotine replacement therapy, varenicline or bupropion
- annual influenza vaccination
- one-off pneumococcal vaccination
- pulmonary rehabilitation to all people who view themselves as functionally disabled by COPD (usually Medical Research Council [MRC] grade 3 and above)

Bronchodilator therapy

- a short-acting beta2-agonist (SABA) or short-acting muscarinic antagonist (SAMA) is first-line treatment
- for patients who remain breathless or have exacerbations despite using short-acting bronchodilators the next step is determined by whether the patient has '*asthmatic features/features suggesting steroid responsiveness*'

There are a number of criteria NICE suggest to determine whether a patient has asthmatic/steroid responsive features:

- any previous, secure diagnosis of asthma or of atopy
- a higher blood eosinophil count - note that NICE recommend a full blood count for all patients as part of the work-up
- substantial variation in FEV1 over time (at least 400 ml)
- substantial diurnal variation in peak expiratory flow (at least 20%)

Interestingly NICE do not recommend formal reversibility testing as one of the criteria. In the guidelines they state that *'routine spirometric reversibility testing is not necessary as part of the diagnostic process or to plan initial therapy with bronchodilators or corticosteroids. It may be unhelpful or misleading...'*. They then go on to discuss why they have reached this conclusion. Please see the guidelines for more details.

No asthmatic features/features suggesting steroid responsiveness

- add a long-acting beta2-agonist (LABA) + long-acting muscarinic antagonist (LAMA)
    - if already taking a SAMA, discontinue and switch to a SABA

Asthmatic features/features suggesting steroid responsiveness

- LABA + inhaled corticosteroid (ICS)
- if patients remain breathless or have exacerbations offer triple therapy i.e. LAMA + LABA + ICS
    - if already taking a SAMA, discontinue and switch to a SABA
- NICE recommend the use of combined inhalers where possible

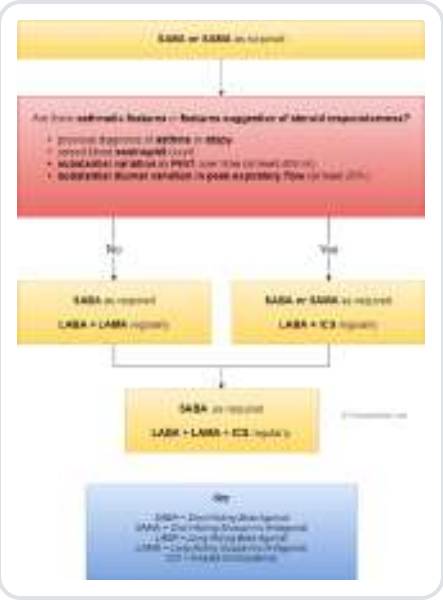

Oral theophylline

- NICE only recommends theophylline after trials of short and long-acting bronchodilators or to people who cannot used inhaled therapy
- the dose should be reduced if macrolide or fluoroquinolone antibiotics are co-prescribed

Oral prophylactic antibiotic therapy

- azithromycin prophylaxis is recommended in select patients

- patients should not smoke, have optimised standard treatments and continue to have exacerbations
- other prerequisites include a CT thorax (to exclude bronchiectasis) and sputum culture (to exclude atypical infections and tuberculosis)
- LFTs and an ECG to exclude QT prolongation should also be done as azithromycin can prolong the QT interval

Standby medication: NICE recommend offering a short course of oral corticosteroids and oral antibiotics to keep at home if: NICE

- have had an exacerbation within the last year
- understand how to take the medication, and are aware of associated risks and benefits
- know to when to seek help and when to ask for replacements once medication has been used

Mucolytics

- should be 'considered' in patients with a chronic productive cough and continued if symptoms improve

Phosphodiesterase-4 (PDE-4) inhibitors NICE

- oral PDE-4 inhibitors such as roflumilast reduce the risk of COPD exacerbations in patients with severe COPD and a history of frequent COPD exacerbations
- NICE recommend if:
    - the disease is severe, defined as a forced expiratory volume in 1 second (FEV1) after a bronchodilator of less than 50% of predicted normal, and
    - the person has had 2 or more exacerbations in the previous 12 months despite triple inhaled therapy with a long-acting muscarinic antagonist, a long-acting beta-2 agonist and an inhaled corticosteroid

Cor pulmonale

- features include peripheral oedema, raised jugular venous pressure, systolic parasternal heave, loud P2
- use a loop diuretic for oedema, consider long-term oxygen therapy
- ACE-inhibitors, calcium channel blockers and alpha blockers are not recommended by NICE

Factors which may improve survival in patients with stable COPD

- smoking cessation - the single most important intervention in patients who are still smoking
- long term oxygen therapy in patients who fit criteria
- lung volume reduction surgery in selected patients

AI + Q 123

Next question

Textbooks

High-yield textbook

Extended textbook

Links

Global Initiative for Chronic Obstructive Lung Disease 14 31

GOLD criteria 2017

NICE 33 29

2018 COPD guidelines

NICE 15 10

Roflumilast NICE recommendations

NICE 65 18

2018 COPD management diagram

Suggest link Report broken link

Media

[Cor pulmonale]

Zero To Finals - YouTube 5 0

[Chronic bronchitis]

Osmosis - YouTube 3 0

[Cor pulmonale]

Osmosis - YouTube 1 0

[Understanding COPD]

Armando Hasudungan - YouTube 0 0

[All about COPD (for Medical Students)]

MedFlix - YouTube 3 1

Report broken media

Score: **24%**

1 ✗

2	✗
3	✗
4	✗
5	✗
6	✗
7	✗
8	✗
9	✓
10	✓
11	✗
12	✗
13	✗
14	✓
15	✗
16	✓
17	✗
18	✗
19	✗
20	✗
21	✓
22	✓
23	✗
24	✗
25	✗

All contents of this site are © 2024 Passmedicine Limited

A 52-year-old woman presents with worsening exercise tolerance. Her GP has recently increased her asthma treatment but this has not helped, nor does she have any relief from her salbutamol inhaler. She has no other known medical history. On examination, her lung fields sound clear on auscultation but she has an early diastolic murmur. She has already had a chest X-ray demonstrating enlarged proximal pulmonary arteries. Which investigation is most likely to provide the correct diagnosis?

- ECG
- Renal function blood tests
- Echocardiogram
- High-resolution CT chest
- Right heart catheterisation

Submit answer

Reference ranges

Score: **0%**

1 -
2 -
3 -
4 -
5 -
6 -
7 -
8 -
9 -

10 -
11 -
12 -
13 -
14 -
15 -
16 -

All contents of this site are © 2024 Passmedicine Limited

A 52-year-old woman presents with worsening exercise tolerance. Her GP has recently increased her asthma treatment but this has not helped, nor does she have any relief from her salbutamol inhaler. She has no other known medical history. On examination, her lung fields sound clear on auscultation but she has an early diastolic murmur. She has already had a chest X-ray demonstrating enlarged proximal pulmonary arteries. Which investigation is most likely to provide the correct diagnosis?

ECG	0%
Renal function blood tests	1%
Echocardiogram	26%
High-resolution CT chest	6%
Right heart catheterisation	67%

The correct answer is right heart catheterisation to diagnose pulmonary arterial hypertension. The history is primarily of worsening shortness of breath in a middle-aged person with clear lung fields and a diastolic murmur. The chest X-ray with enlarged proximal pulmonary arteries is highly suggestive. Whilst an ECG or echocardiogram may show features of pulmonary arterial hypertension right heart catheterisation is the gold standard and would be most diagnostic.

Discuss (5) Improve

Next question >

Pulmonary hypertension: causes and classification

Pulmonary hypertension may be defined as a sustained elevation in mean pulmonary arterial pressure of greater than 20 mmHg at rest. It has recently been reclassified by the WHO:

Group 1: Pulmonary arterial hypertension (PAH)
- idiopathic*
- familial

- associated conditions: collagen vascular disease, congenital heart disease with systemic to pulmonary shunts, HIV**, drugs and toxins, sickle cell disease
- persistent pulmonary hypertension of the newborn

Group 2: Pulmonary hypertension with left heart disease
- left-sided atrial, ventricular or valvular disease such as left ventricular systolic and diastolic dysfunction, mitral stenosis and mitral regurgitation

Group 3: Pulmonary hypertension secondary to lung disease/hypoxia
- COPD
- interstitial lung disease
- sleep apnoea
- high altitude

Group 4: Pulmonary hypertension due to thromboembolic disease

Group 5: Miscellaneous conditions
- lymphangiomatosis e.g. secondary to carcinomatosis or sarcoidosis

*previously termed primary pulmonary hypertension
**the mechanism by which HIV infection produces pulmonary hypertension remains unknown

+ Q 123

Next question

Textbooks

High-yield textbook

Extended textbook

Links

Medcomic 8 3

Pulmonary hypertension

Suggest link Report broken link

Media

Pulmonary hypertension

Osmosis - YouTube 5 0

Report broken media

Score: **24%**

1	✗
2	✗
3	✗
4	✗
5	✗
6	✗
7	✗
8	✗
9	✓
10	✓
11	✗
12	✗
13	✗
14	✓
15	✗
16	✓
17	✗

18	✗
19	✗
20	✗
21	✓
22	✓
23	✗
24	✗
25	✗

All contents of this site are © 2024 Passmedicine Limited

Back to top

A 69-year-old man with a history of rheumatoid arthritis well controlled on methotrexate presents with gradual pain and swelling in his wrists and ankles.

The pain is described as a dull ache that is intermittent, often worse in the evenings. There is associated swelling which can sometimes feel warm. He has tried regular paracetamol but this has had limited effect.

He also describes a chronic cough and shortness of breath on exertion for the past 6 months that he has not mentioned to his GP. There has been no haemoptysis and he denies any fevers. His wife has noticed that he has been losing weight recently.

He has a past medical history of rheumatoid arthritis, hypertension, hypercholesterolaemia and type 2 diabetes mellitus. He currently takes methotrexate weekly, folic acid 5mg weekly, ramipril 5mg, simvastatin 20mg at night, metformin 500mg three times a day and paracetamol 1g four times daily.

He is a retired accountant and a current smoker with a 50 pack year smoking history. He drinks approximately 30 units of beer a week. He denies any recent foreign travel.

On examination, he is cachectic and short of breath on exertion. His pulse is 80/min and regular, blood pressure 140/93 mmHg, oxygen saturations of 93% on air. He has marked fingernail clubbing. Examination of his wrists reveals slightly swollen and tender joints. Swan neck and ulnar deviation deformities are noted in both hands. Other than his wrists, no other joint abnormalities are detected. Examination of the peripheral nervous system is normal.

Examination of his chest is normal with no focal consolidation.

Initial bloods are as follows:

Na+	134 mmol/L
K+	3.9 mmol/L
Urea	7.8 mmol/L
Creatinine	105 µmol/L
Hb	100 g/L
WBC	6.0x10^9/L
Platelets	200x10^9/L

LFTs	Normal
Serum uric acid	410 µmol/L
CRP	12 mg/L

Chest X-ray reveals a discrete opacification at the periphery of the right middle lobe.

What is the most likely cause of his joint pains?

- Rheumatoid arthritis flare
- Gout
- Hypertrophic pulmonary osteoarthropathy secondary to bronchogenic carcinoma
- Reiter's syndrome
- Osteoarthritis

Submit answer

Reference ranges

Score: **0%**

1 -
2 -
3 -
4 -
5 -
6 -
7 -
8 -
9 -
10 -
11 -
12 -

13	-
14	-
15	-
16	-
17	-

All contents of this site are © 2024 Passmedicine Limited

A 69-year-old man with a history of rheumatoid arthritis well controlled on methotrexate presents with gradual pain and swelling in his wrists and ankles.

The pain is described as a dull ache that is intermittent, often worse in the evenings. There is associated swelling which can sometimes feel warm. He has tried regular paracetamol but this has had limited effect.

He also describes a chronic cough and shortness of breath on exertion for the past 6 months that he has not mentioned to his GP. There has been no haemoptysis and he denies any fevers. His wife has noticed that he has been losing weight recently.

He has a past medical history of rheumatoid arthritis, hypertension, hypercholesterolaemia and type 2 diabetes mellitus. He currently takes methotrexate weekly, folic acid 5mg weekly, ramipril 5mg, simvastatin 20mg at night, metformin 500mg three times a day and paracetamol 1g four times daily.

He is a retired accountant and a current smoker with a 50 pack year smoking history. He drinks approximately 30 units of beer a week. He denies any recent foreign travel.

On examination, he is cachectic and short of breath on exertion. His pulse is 80/min and regular, blood pressure 140/93 mmHg, oxygen saturations of 93% on air. He has marked fingernail clubbing. Examination of his wrists reveals slightly swollen and tender joints. Swan neck and ulnar deviation deformities are noted in both hands. Other than his wrists, no other joint abnormalities are detected. Examination of the peripheral nervous system is normal.

Examination of his chest is normal with no focal consolidation.

Initial bloods are as follows:

Na+	134 mmol/L
K+	3.9 mmol/L
Urea	7.8 mmol/L
Creatinine	105 µmol/L
Hb	100 g/L
WBC	6.0x10^9/L
Platelets	200x10^9/L

LFTs	Normal
Serum uric acid	410 μmol/L
CRP	12 mg/L

Chest X-ray reveals a discrete opacification at the periphery of the right middle lobe.

What is the most likely cause of his joint pains?

Rheumatoid arthritis flare	5%
Gout	1%
Hypertrophic pulmonary osteoarthropathy secondary to bronchogenic carcinoma	90%
Reiter's syndrome	3%
Osteoarthritis	1%

This man has a history of intermittent swelling and pain in his wrists and to a lesser degree in his ankles. He has a past medical history of rheumatoid arthritis with some evidence of joint deformities but seems to be well controlled on methotrexate. There is no synovitis present in the typical pattern of rheumatoid arthritis.

He has a strong smoking history, a 6-month history of cough, weight loss, is clubbed and has an abnormal chest x-ray all highly suspicious of an underlying lung malignancy. Hypertrophic pulmonary osteoarthropathy occurs in about 5% of case of lung cancer and typically presents with intermittent aching and swelling in the wrists and ankles.

This man's serum uric acid is normal and gout typically presents in the first metatarsophalangeal joint. He has no previous history of gout but does have some risk factors for this.

Osteoarthritis is a possible diagnosis but does not typically present with signs of synovitis.

Reiter's syndrome is a seronegative arthritis characterised by the triad of urethritis, conjunctivitis and arthritis which doesn't fit with this patient's clinical picture.

Lung cancer: paraneoplastic features

Small cell

- ADH
- ACTH - not typical, hypertension, hyperglycaemia, hypokalaemia, alkalosis and muscle weakness are more common than buffalo hump etc
- Lambert-Eaton syndrome

Squamous cell

- parathyroid hormone-related protein (PTH-rp) secretion causing hypercalcaemia
- clubbing
- hypertrophic pulmonary osteoarthropathy (HPOA)
- hyperthyroidism due to ectopic TSH

Adenocarcinoma

- gynaecomastia
- hypertrophic pulmonary osteoarthropathy (HPOA)

© Image used on license from Radiopaedia

Hypertrophic pulmonary osteoarthropathy is a proliferative periostisis involving that typically involves the long bones. It is

often painful.

*whilst it is traditionally taught that HPOA is most common with squamous cell carcinoma some studies indicate that adenocarcinoma is the most common cause e.g. https://www.ncbi.nlm.nih.gov/pmc/articles/PMC4049689/

123

Next question >

Textbooks

High-yield textbook

Extended textbook

Links

Mayo Clinic 8 8

Paraneoplastic Syndromes: An Approach to Diagnosis and Treatment

Suggest link

Report broken link

Media

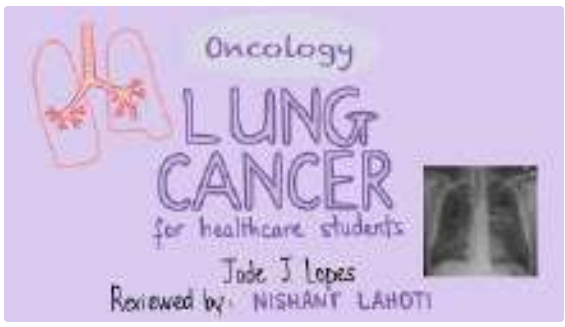

Lung cancer

MedFlix - YouTube 6 0

Lung Cancer: An Overview

Oncology for Medical Students - YouTube 3 0



Hypercalcemia in malignancy

Armando Hasudungan - YouTube 3 1

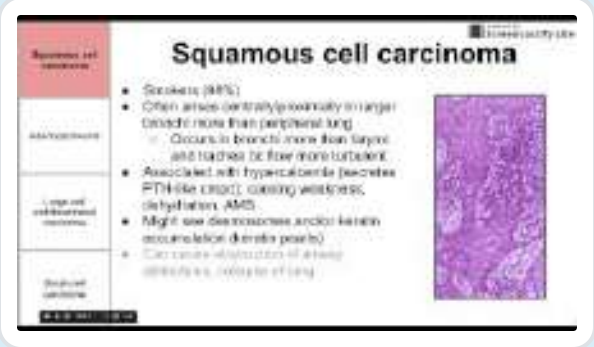

Cancers of the lung

MedLecturesMadeEasy - YouTube 2 2

Report broken media

Score: **24%**

1	✗
2	✗
3	✗
4	✗
5	✗
6	✗
7	✗
8	✗
9	✓
10	✓
11	✗

12	✗
13	✗
14	✓
15	✗
16	✓
17	✗
18	✗
19	✗
20	✗
21	✓
22	✓
23	✗
24	✗
25	✗

All contents of this site are © 2024 Passmedicine Limited

Back to top

A 57-year-old male is seen in the respiratory clinic with a three months history of a productive cough, weight loss and drenching night sweats. He reports that he is producing approximately 1 cup of green sputum each day and has lost 4 kgs during the same time period. He has smoked 20 cigarettes a day since he was 15 years old. He last traveled abroad 2 years ago, visiting family in North America.

The GP has performed routine blood tests which are unremarkable and a HIV test is negative. Several sputum samples have been sent for routine microscopy, culture & sensitivities (MC&S) growing only normal respiratory flora. Following a normal chest X-ray, you perform a high resolution CT (HRCT) scan. This demonstrates right middle lobe and left lower lobe bronchiectasis with multiple nodules in both lungs.

What other initial investigation would you perform to help reach a diagnosis?

- Sweat test
- PET-CT Scan
- Repeat HRCT scan in 3-6 months
- Sputum for acid fast bacilli (AFB)
- Bronchoscopy +/- biopsies

Submit answer

Reference ranges

Score: **0%**

1 -
2 -

3 -
4 -
5 -
6 -
7 -
8 -
9 -
10 -
11 -
12 -
13 -
14 -
15 -
16 -
17 -
18 -

All contents of this site are © 2024 Passmedicine Limited

Back to top

A 57-year-old male is seen in the respiratory clinic with a three months history of a productive cough, weight loss and drenching night sweats. He reports that he is producing approximately 1 cup of green sputum each day and has lost 4 kgs during the same time period. He has smoked 20 cigarettes a day since he was 15 years old. He last traveled abroad 2 years ago, visiting family in North America.

The GP has performed routine blood tests which are unremarkable and a HIV test is negative. Several sputum samples have been sent for routine microscopy, culture & sensitivities (MC&S) growing only normal respiratory flora. Following a normal chest X-ray, you perform a high resolution CT (HRCT) scan. This demonstrates right middle lobe and left lower lobe bronchiectasis with multiple nodules in both lungs.

What other initial investigation would you perform to help reach a diagnosis?

Sweat test	9%
PET-CT Scan	14%
Repeat HRCT scan in 3-6 months	3%
Sputum for acid fast bacilli (AFB)	35%
Bronchoscopy +/- biopsies	39%

The correct answer is to send sputum for acid fast bacilli (AFB).

Whilst the causative organism could potentially be either tuberculosis or non-tuberculosis mycobacterial (NTM) infection, the latter is the more appropriate here given the radiological findings on HRCT, which are classically seen in atypical mycobacterial infection. This question tests your understanding of the common presentations of pulmonary non-tuberculous mycobacterium (NTM) infection in immunocompetent individuals. NTM infection in the non-HIV population is becoming increasingly common and is often a challenging diagnosis to make due to the environmental nature of NTM.

Discuss (9) | Improve

Next question

Nontuberculous mycobacteria

Nontuberculous mycobacteria (NTM) are mycobacterial species other than those belonging to the *Mycobacterium tuberculosis* complex. NTM are typically free-living organisms that are common in the environment.

Most non-tuberculous mycobacteria are caused by *M. avium* complex (MAC) organisms.

Presentations include:

- pulmonary disease
  - cavitating lesions
  - nodular / bronchiectatic disease
- disseminated disease

123

Next question

Textbooks

High-yield textbook

Extended textbook

Links

British Thoracic Society 0 0

2017 Management of non-tuberculous mycobacterial pulmonary disease (NTM-PD)

Suggest link Report broken link

Score: **24%**

1	✗
2	✗
3	✗
4	✗
5	✗
6	✗
7	✗
8	✗
9	✓
10	✓
11	✗
12	✗
13	✗
14	✓
15	✗
16	✓
17	✗
18	✗
19	✗
20	✗
21	✓
22	✓
23	✗
24	✗
25	✗

All contents of this site are © 2024 Passmedicine Limited

A 24-year-old woman with a history of cystic fibrosis comes to the endocrinology clinic for review. She has been losing weight and a recent fasting plasma glucose has been measured at 8.1 mmol/l. Over the past year there has been three admissions to hospital with exacerbations of her CF. On examination her blood pressure is 122/81 mmHg, pulse is 71 beats per minute and regular. Auscultation of the chest reveals coarse crackles and scattered wheeze. Abdomen is soft and on tender, her body mass index is 19.5 kg/m^2. Which of the following is the best way to manage her diabetes?

- Low calorie diet
- Insulin and high calorie diet
- Metformin and low calorie diet
- Gliclazide and standard calorie diet
- Dapagliflozin and low calorie diet

Submit answer

Reference ranges

Score: **0%**

9	-
10	-
11	-
12	-
13	-
14	-
15	-
16	-
17	-
18	-
19	-

All contents of this site are © 2024 Passmedicine Limited

A 24-year-old woman with a history of cystic fibrosis comes to the endocrinology clinic for review. She has been losing weight and a recent fasting plasma glucose has been measured at 8.1 mmol/l. Over the past year there has been three admissions to hospital with exacerbations of her CF. On examination her blood pressure is 122/81 mmHg, pulse is 71 beats per minute and regular. Auscultation of the chest reveals coarse crackles and scattered wheeze. Abdomen is soft and on tender, her body mass index is 19.5 kg/m^2. Which of the following is the best way to manage her diabetes?

- Low calorie diet 2%
- Insulin and high calorie diet 89%
- Metformin and low calorie diet 4%
- Gliclazide and standard calorie diet 4%
- Dapagliflozin and low calorie diet 1%

Patients with cystic fibrosis suffer significant difficulties in maintaining their weight even before or if they never develop diabetes. Weight loss in cystic fibrosis is closely allied to both risk of exacerbations of the disease and an increase in overall mortality. For this reason it's important for patients to maintain a high calorie diet and take insulin to allow them to convert those calories into stored energy.

All of the other options which include either a standard or low calorie diet are incorrect because they won't allow the patient to maintain her body weight. Dapagliflozin promotes spilling of carbohydrate into the urine, and hence leads to a calorie deficit, this is therefore incorrect. Gliclazide can be used in the initial period of diabetes associated with cystic fibrosis, although it's important in this situation to also encourage patients to maintain a high calorie intake.

Link to Brompton guidelines:

http://www.rbht.nhs.uk/healthprofessionals/clinical-departments/paediatrics/childrencf/other/diabetes/

Discuss (1) Improve

Next question >

Cystic fibrosis: management

Management of cystic fibrosis (CF) involves a multidisciplinary approach

Key points

- regular (at least twice daily) chest physiotherapy and postural drainage. Parents are usually taught to do this. Deep breathing exercises are also useful
- high calorie diet, including high fat intake*
- patients with CF should try to minimise contact with each other to prevent cross infection with *Burkholderia cepacia* complex and *Pseudomonas aeruginosa*
- vitamin supplementation
- pancreatic enzyme supplements taken with meals
- lung transplantion
    - chronic infection with *Burkholderia cepacia* is an important CF-specific contraindication to lung transplantation

Lumacaftor/Ivacaftor (Orkambi)

- is used to treat cystic fibrosis patients who are homozygous for the delta F508 mutation
- lumacaftor increases the number of CFTR proteins that are transported to the cell surface
- ivacaftor is a potentiator of CFTR that is already at the cell surface, increasing the probability that the defective channel will be open and allow chloride ions to pass through the channel pore

*this is now the standard recommendation - previously high calorie, low-fat diets have been recommended to reduce the amount of steatorrhoea

AI + Q 123

Next question >

Textbooks

High-yield textbook

Extended textbook

Links

Cystic Fibrosis Trust 6 6

Nutrition for adults

NICE 9 4

2017 Cystic fibrosis: diagnosis and management

Suggest link

Report broken link

Media

Cystic fibrosis

Osmosis - YouTube 6 0

Cystic fibrosis: pathology review

Osmosis - YouTube 2 0

Report broken media

Score: **24%**

1	✗
2	✗
3	✗
4	✗
5	✗
6	✗
7	✗
8	✗
9	✓
10	✓
11	✗
12	✗
13	✗
14	✓
15	✗
16	✓
17	✗
18	✗
19	✗
20	✗
21	✓
22	✓
23	✗
24	✗
25	✗

All contents of this site are © 2024 Passmedicine Limited

A 73-year-old man is referred to the respiratory outpatient clinic with exertional shortness of breath. He has no past medical history and does not take any regular medications. He does not smoke or drink alcohol. He worked for 51 years at a paper mill.

On examination, he is mildly dyspnoeic at rest. There are bibasal inspiratory crackles heard on auscultation. The fingers are clubbed. Cardiovascular examination is unremarkable.

A high-resolution CT chest demonstrates parenchymal bands, traction bronchiectasis and honeycomb lung. There is no involvement of the pleura.

Given the likely diagnosis, what treatment is likely to be recommended?

- Chemotherapy
- Conservative management
- Prednisolone
- Radiotherapy
- Surgery

Submit answer

Reference ranges

5	-
6	-
7	-
8	-
9	-
10	-
11	-
12	-
13	-
14	-
15	-
16	-
17	-
18	-
19	-
20	-

All contents of this site are © 2024 Passmedicine Limited

Back to top

A 73-year-old man is referred to the respiratory outpatient clinic with exertional shortness of breath. He has no past medical history and does not take any regular medications. He does not smoke or drink alcohol. He worked for 51 years at a paper mill.

On examination, he is mildly dyspnoeic at rest. There are bibasal inspiratory crackles heard on auscultation. The fingers are clubbed. Cardiovascular examination is unremarkable.

A high-resolution CT chest demonstrates parenchymal bands, traction bronchiectasis and honeycomb lung. There is no involvement of the pleura.

Given the likely diagnosis, what treatment is likely to be recommended?

Chemotherapy	2%
Conservative management	55%
Prednisolone	40%
Radiotherapy	1%
Surgery	2%

Asbestosis is treated conservatively - no interventions offer a significant benefit

Important for me Less important

Conservative management is the correct answer. The patient presents with exertional shortness of breath and crackles and undergoes an HRCT chest, which demonstrates classic changes of fibrotic lung disease (parenchymal bands, honeycombing and traction bronchiectasis). The most likely cause of fibrosis is asbestos exposure. Historical work in a paper mill is a significant occupational risk for asbestos exposure.

Chemotherapy is incorrect. Asbestos exposure puts the patient at risk of developing mesothelioma, which is a malignant cancer of the pleura. Chemotherapy is an option in this condition. However, we are specifically told there is no pleural involvement and therefore this is unlikely.

Prednisolone is incorrect. This is often trialled in interstitial lung disease if the condition is felt to

be steroid-responsive. However, asbestosis is not felt to respond to medical treatment in this way. Additionally, HRCT appearances of ground glass (suggesting inflammation) rather than honeycombing (suggesting established fibrosis) tend to be more steroid responsive.

Radiotherapy is incorrect. This may be an option for treating lung cancer or mesothelioma. However, the HRCT chest does not describe pleural involvement or a primary lung malignancy and therefore this is not likely to be recommended.

Surgery is incorrect. Occupational exposure to asbestosis has been associated with lung cancer, which in some cases can be treated surgically. However, the description, in this case, is of pulmonary fibrosis, rather than a malignancy.

Discuss (1) Improve

Next question

Asbestos and the lung

Asbestos can cause a variety of lung diseases from benign pleural plaques to mesothelioma.

Pleural plaques

Pleural plaques are benign and do not undergo malignant change. They, therefore don't require any follow-up. They are the most common form of asbestos-related lung disease and generally occur after a latent period of 20-40 years.

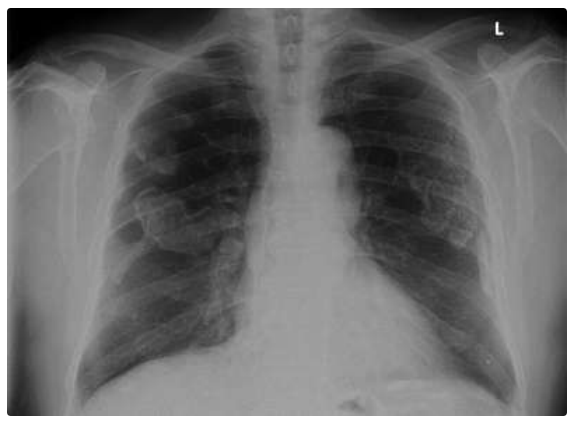

Pleural thickening

Asbestos exposure may cause diffuse pleural thickening in a similar pattern to that seen following an empyema or haemothorax. The underlying pathophysiology is not fully understood.

Asbestosis

The severity of asbestosis is related to the length of exposure. This is in contrast to mesothelioma

where even very limited exposure can cause disease. The latent period is typically 15-30 years. Asbestosis typically causes lower lobe fibrosis.

Features
- dyspnoea and reduced exercise tolerance
- clubbing
- bilateral end-inspiratory crackles
- lung function tests show a restrictive pattern with reduced gas transfer

It is treated conservatively - no interventions offer a significant benefit.

Mesothelioma

Mesothelioma is a malignant disease of the pleura. Crocidolite (blue) asbestos is the most dangerous form.

Possible features
- progressive shortness-of-breath
- chest pain
- pleural effusion

Patients are usually offered palliative chemotherapy and there is also a limited role for surgery and radiotherapy. Unfortunately, the prognosis is very poor, with a median survival from diagnosis of 8-14 months.

Lung cancer

Whilst mesothelioma is in some ways synonymous with asbestos, lung cancer is actually the most common form of cancer associated with asbestos exposure. It also has a synergistic effect with cigarette smoke in terms of the increased risk. Therefore, smoking cessation is very important as the risk of lung cancer in smokers who have a history of asbestos exposure is very high.

AI + Q 123

Next question

Textbooks

High-yield textbook

Extended textbook

Score: **24%**

1	✗
2	✗
3	✗
4	✗
5	✗
6	✗
7	✗
8	✗
9	✓
10	✓
11	✗
12	✗
13	✗
14	✓
15	✗
16	✓
17	✗

18	✗
19	✗
20	✗
21	✓
22	✓
23	✗
24	✗
25	✗

All contents of this site are © 2024 Passmedicine Limited

A 24-year-old woman with cystic fibrosis (CF) is reviewed in the endocrinology clinic. She has lost weight over the past few months despite maintaining a high-calorie diet and wakes three times per night to pass urine. Over the past year she has suffered two exacerbations of her CF and has seen a more rapid deterioration in her lung function. On examination her blood pressure is 122/82 mmHg, her pulse is 82 beats per minute and regular, and her body mass index is 19 kg/m^2. There are coarse crackles and wheeze on auscultation of the chest. A fasting blood glucose is 8.1 mmol/l, and her HbA1c is 60 mmol/mol.

Which of the following is the most appropriate way to manage her diabetes mellitus?

- Switch to a low calorie diet
- Start metformin monotherapy and continue high calorie diet
- Start gliclazide monotherapy
- Start sitagliptin monotherapy
- Start basal bolus insulin and continue high calorie diet

Submit answer

Reference ranges

Score: **0%**

1 -
2 -
3 -
4 -
5 -
6 -

7	-
8	-
9	-
10	-
11	-
12	-
13	-
14	-
15	-
16	-
17	-
18	-
19	-
20	-
21	-
22	-

All contents of this site are © 2024 Passmedicine Limited

A 24-year-old woman with cystic fibrosis (CF) is reviewed in the endocrinology clinic. She has lost weight over the past few months despite maintaining a high-calorie diet and wakes three times per night to pass urine. Over the past year she has suffered two exacerbations of her CF and has seen a more rapid deterioration in her lung function. On examination her blood pressure is 122/82 mmHg, her pulse is 82 beats per minute and regular, and her body mass index is 19 kg/m^2. There are coarse crackles and wheeze on auscultation of the chest. A fasting blood glucose is 8.1 mmol/l, and her HbA1c is 60 mmol/mol.

Which of the following is the most appropriate way to manage her diabetes mellitus?

- Switch to a low calorie diet — 2%
- Start metformin monotherapy and continue high calorie diet — 17%
- Start gliclazide monotherapy — 3%
- Start sitagliptin monotherapy — 1%
- Start basal bolus insulin and continue high calorie diet — 77%

Patients with cystic fibrosis and diabetes should follow a high calorie diet and use extra insulin to control their blood sugar

Important for me Less important

It's clear that the development of diabetes in patients with cystic fibrosis is associated with weight loss and the development of more frequent respiratory exacerbations. As such it's crucial to maintain adequate nutrition with a high calorie diet and adequate insulin to control blood glucose levels. This is at odds with management of diabetes in other conditions.

Gliclazide is of value in early diabetes associated with cystic fibrosis, although it rarely controls blood glucose levels adequately to allow patients to maintain a high calorie diet, hence insulin is preferred
. Insulin resistance isn't the primary problem in CF related diabetes, therefore metformin is of little value, and DPPIV inhibitors are less effective in lowering blood glucose versus sulphonylureas in this situation.

https://www.cysticfibrosis.org.uk/~/media/documents/life-with-cf/publications/factsheets/cfrd-factsheet-sep-2017.ashx?la=en

Discuss (1) Improve

Next question

Cystic fibrosis: management

Management of cystic fibrosis (CF) involves a multidisciplinary approach

Key points

- regular (at least twice daily) chest physiotherapy and postural drainage. Parents are usually taught to do this. Deep breathing exercises are also useful
- high calorie diet, including high fat intake*
- patients with CF should try to minimise contact with each other to prevent cross infection with *Burkholderia cepacia* complex and *Pseudomonas aeruginosa*
- vitamin supplementation
- pancreatic enzyme supplements taken with meals
- lung transplantion
  - chronic infection with *Burkholderia cepacia* is an important CF-specific contraindication to lung transplantation

Lumacaftor/Ivacaftor (Orkambi)

- is used to treat cystic fibrosis patients who are homozygous for the delta F508 mutation
- lumacaftor increases the number of CFTR proteins that are transported to the cell surface
- ivacaftor is a potentiator of CFTR that is already at the cell surface, increasing the probability that the defective channel will be open and allow chloride ions to pass through the channel pore

*this is now the standard recommendation - previously high calorie, low-fat diets have been recommended to reduce the amount of steatorrhoea

123

Next question

Textbooks

High-yield textbook

Extended textbook

Links

Cystic Fibrosis Trust 6 6

Nutrition for adults

NICE 9 4

2017 Cystic fibrosis: diagnosis and management

Suggest link Report broken link

Media

Cystic fibrosis

Osmosis - YouTube 6 0

Cystic fibrosis: pathology review

Osmosis - YouTube 2 0

Report broken media

Score: **24%**

1	✗
2	✗
3	✗
4	✗
5	✗
6	✗
7	✗
8	✗
9	✓
10	✓
11	✗
12	✗
13	✗
14	✓
15	✗
16	✓
17	✗
18	✗
19	✗
20	✗
21	✓
22	✓
23	✗
24	✗
25	✗

All contents of this site are © 2024 Passmedicine Limited

Back to top

A 54-year-old man presents to the respiratory clinic. He was found to have three pleural plaques on a chest X-ray when being screened for tuberculosis due to immigration purposes. He worked as a builder for four years 21 years ago. He has no shortness of breath or chest pain. A diagnosis of benign pleural disease is made. He is keen to seek compensation. What is the most appropriate advice?

- Seek compensation by criminal law suit
- Seek compensation by civil law suit
- Seek compensation via GP
- Seek compensation via department of social security
- Unlikely to receive compensation currently

Submit answer

Reference ranges

Score: **0%**

1 -
2 -
3 -
4 -
5 -
6 -
7 -
8 -
9 -
10 -

11 -
12 -
13 -
14 -
15 -
16 -
17 -
18 -
19 -
20 -
21 -
22 -

All contents of this site are © 2024 Passmedicine Limited

A 54-year-old man presents to the respiratory clinic. He was found to have three pleural plaques on a chest X-ray when being screened for tuberculosis due to immigration purposes. He worked as a builder for four years 21 years ago. He has no shortness of breath or chest pain. A diagnosis of benign pleural disease is made. He is keen to seek compensation. What is the most appropriate advice?

- Seek compensation by criminal law suit — 1%
- Seek compensation by civil law suit — 17%
- Seek compensation via GP — 5%
- Seek compensation via department of social security — 13%
- Unlikely to receive compensation currently — 65%

The correct answer is that he is unlikely to receive compensation currently. This is a gentleman who been identified to have pleural plaques, likely secondary to asbestos exposure but who is suffering no symptoms. These patients do not qualify for compensation. If a diagnosis of asbestosis or mesothelioma is made then the patient would qualify. Compensation can be obtained through Industrial Injuries Disablement Benefit from the Department of Social Security or a civil law claim for damages from the employer under which the exposure occurred. Patients should be advised to consult their local Department of Work and Pensions benefit agency for advice. Please see https://www.gov.uk/industrial-injuries-disablement-benefit/eligibility for further information.

Discuss (6) Improve

Next question

Asbestos and the lung

Asbestos can cause a variety of lung diseases from benign pleural plaques to mesothelioma.

Pleural plaques

Pleural plaques are benign and do not undergo malignant change. They, therefore don't require any follow-up. They are the most common form of asbestos-related lung disease and generally occur after a latent period of 20-40 years.

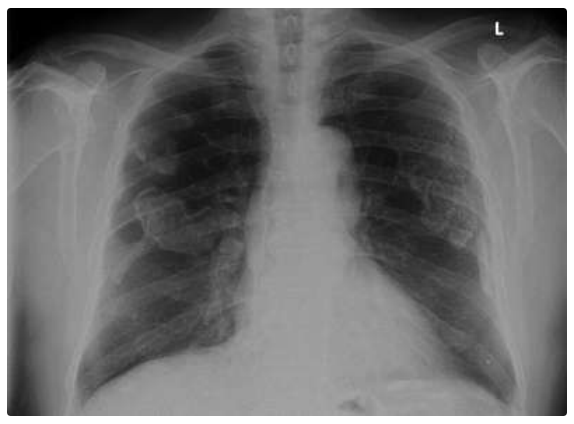

Pleural thickening

Asbestos exposure may cause diffuse pleural thickening in a similar pattern to that seen following an empyema or haemothorax. The underlying pathophysiology is not fully understood.

Asbestosis

The severity of asbestosis is related to the length of exposure. This is in contrast to mesothelioma where even very limited exposure can cause disease. The latent period is typically 15-30 years. Asbestosis typically causes lower lobe fibrosis.

Features
- dyspnoea and reduced exercise tolerance
- clubbing
- bilateral end-inspiratory crackles
- lung function tests show a restrictive pattern with reduced gas transfer

It is treated conservatively - no interventions offer a significant benefit.

Mesothelioma

Mesothelioma is a malignant disease of the pleura. Crocidolite (blue) asbestos is the most dangerous form.

Possible features
- progressive shortness-of-breath
- chest pain
- pleural effusion

Patients are usually offered palliative chemotherapy and there is also a limited role for surgery and radiotherapy. Unfortunately, the prognosis is very poor, with a median survival from diagnosis of 8-14 months.

Lung cancer

Whilst mesothelioma is in some ways synonymous with asbestos, lung cancer is actually the most common form of cancer associated with asbestos exposure. It also has a synergistic effect with cigarette smoke in terms of the increased risk. Therefore, smoking cessation is very important as the risk of lung cancer in smokers who have a history of asbestos exposure is very high.

AI + Q 123

Next question >

Textbooks

High-yield textbook

Extended textbook

Score: **24%**

1	✗
2	✗
3	✗
4	✗
5	✗
6	✗
7	✗
8	✗
9	✓
10	✓
11	✗
12	✗
13	✗
14	✓
15	✗
16	✓
17	✗
18	✗
19	✗
20	✗
21	✓
22	✓
23	✗
24	✗
25	✗

All contents of this site are © 2024 Passmedicine Limited

Back to top

A 61-year-old man with known lung cancer presents to the emergency department with shortness of breath. He was diagnosed with squamous cell lung cancer two years ago and has had several courses of radiotherapy but stopped as he was not tolerating the treatment. He has noticed worsening of his chronic shortness of breath and struggled to walk from his car to the hospital, a distance that he was managing well previously. On examination, he appears slightly pale, has dullness on right side of his chest with a few bronchial breaths. A chest X-ray demonstrates an effusion and an aspirate withdraws 40ml of blood. His observations show hypoxia with saturations at 91% but are otherwise normal, and blood tests, including a crossmatch, is requested. What is the most appropriate management?.

- Surgical chest drain
- Seldinger chest drain
- Repeat aspiration
- Conservative management only
- IV antibiotics

Submit answer

Reference ranges

Score: **0%**

1 -
2 -
3 -
4 -
5 -
6 -

7	-
8	-
9	-
10	-
11	-
12	-
13	-
14	-
15	-
16	-
17	-
18	-
19	-
20	-
21	-
22	-
23	-

All contents of this site are © 2024 Passmedicine Limited

Back to top

A 61-year-old man with known lung cancer presents to the emergency department with shortness of breath. He was diagnosed with squamous cell lung cancer two years ago and has had several courses of radiotherapy but stopped as he was not tolerating the treatment. He has noticed worsening of his chronic shortness of breath and struggled to walk from his car to the hospital, a distance that he was managing well previously. On examination, he appears slightly pale, has dullness on right side of his chest with a few bronchial breaths. A chest X-ray demonstrates an effusion and an aspirate withdraws 40ml of blood. His observations show hypoxia with saturations at 91% but are otherwise normal, and blood tests, including a crossmatch, is requested. What is the most appropriate management?.

Surgical chest drain	37%
Seldinger chest drain	39%
Repeat aspiration	4%
Conservative management only	19%
IV antibiotics	1%

The correct answer is a surgical chest drain. The key in this question is that blood, rather than blood-stained fluid, is aspirated. This means that a surgical chest drain rather than a narrow bore chest drain, a Seldinger chest drain, will be needed. Repeating the aspiration is unlikely to gain any further information, and would only be useful if it is suspected that the sample was due to aspiration of an artery. However, it is unlikely that 40ml could have been aspirated from an artery. There is no indication for antibiotics and treatment is clearly needed as the patient is hypoxic.

Discuss (8) | Improve

Next question

Pleural effusion: investigation and management

The British Thoracic Society (BTS) produced guidelines in 2010 covering the investigation of patients with a pleural effusion.

Imaging

- posterioranterior (PA) chest x-rays should be performed in all patients
- ultrasound is recommended: it increases the likelihood of successful pleural aspiration and is sensitive for detecting pleural fluid septations
- contrast CT is now increasingly performed to investigate the underlying cause, particularly for exudative effusions

Pleural aspiration

- as above, ultrasound is recommended to reduce the complication rate
- a 21G needle and 50ml syringe should be used
- fluid should be sent for pH, protein, lactate dehydrogenase (LDH), cytology and microbiology

Light's criteria was developed in 1972 to help distinguish between a transudate and an exudate. The BTS recommend using the criteria for borderline cases:

- exudates have a protein level of >30 g/L, transudates have a protein level of <30 g/L
- if the protein level is between 25-35 g/L, Light's criteria should be applied. An exudate is likely if at least one of the following criteria are met:
    - pleural fluid protein divided by serum protein >0.5
    - pleural fluid LDH divided by serum LDH >0.6
    - pleural fluid LDH more than two-thirds the upper limits of normal serum LDH

Other characteristic pleural fluid findings:

- low glucose: rheumatoid arthritis, tuberculosis
- raised amylase: pancreatitis, oesophageal perforation
- heavy blood staining: mesothelioma, pulmonary embolism, tuberculosis

Pleural infection

All patients with a pleural effusion in association with sepsis or a pneumonic illness require diagnostic pleural fluid sampling

- if the fluid is purulent or turbid/cloudy a chest tube should be placed to allow drainage

- if the fluid is clear but the **pH is less than 7.2 in patients with suspected pleural infection a chest tube should be placed**

Management of recurrent pleural effusion

Options for managing patients with recurrent pleural effusions include:
- recurrent aspiration
- pleurodesis
- indwelling pleural catheter
- drug management to alleviate symptoms e.g. opioids to relieve dyspnoea

123

Next question >

Textbooks

High-yield textbook

Extended textbook

Links

British Thoracic Society 17 14

2023 Pleural disease guidelines

Royal College of Physicians 13 7

2012 Pleural infection review

Suggest link Report broken link

Media

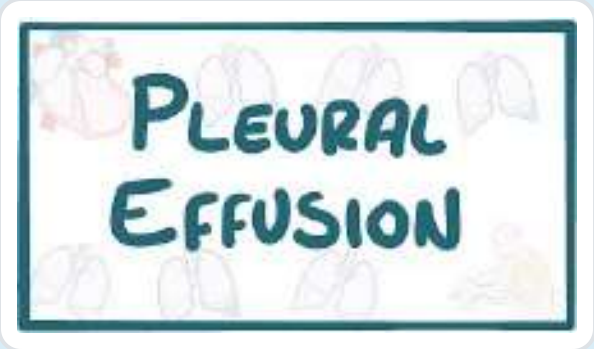

Pleural effusion

Osmosis - YouTube 8 1

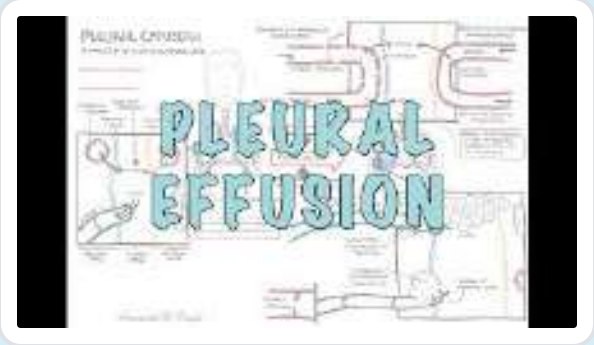

Pleural effusion

Armando Hasudungan - YouTube 6 1

Report broken media

Score: **24%**

1 ✗
2 ✗
3 ✗
4 ✗
5 ✗
6 ✗
7 ✗
8 ✗
9 ✓
10 ✓
11 ✗
12 ✗
13 ✗
14 ✓
15 ✗

16	✓
17	✗
18	✗
19	✗
20	✗
21	✓
22	✓
23	✗
24	✗
25	✗

All contents of this site are © 2024 Passmedicine Limited

A 45-year-old man presents to the emergency department with reports of 8 days of fever, headache, epistaxis, diarrhoea and cough. He has no past medical history. He drinks 32 units of alcohol a week. He keeps parrots and enjoys open water swimming in rivers.

Observations:

- Heart rate 88 beats per minute
- Blood pressure 115/74 mmHg
- Respiratory rate 21/minute
- Oxygen saturations 94% on room air

On examination, there is splenomegaly. Chest auscultation reveals crackles in both lungs.

Blood tests:

Hb	136 g/L	Male: (135-180) Female: (115 - 160)
Platelets	189 * 10^9/L	(150 - 400)
WBC	2.9 * 10^9/L	(4.0 - 11.0)
Na^+	136 mmol/L	(135 - 145)
K^+	4.2 mmol/L	(3.5 - 5.0)
Urea	4.2 mmol/L	(2.0 - 7.0)
Creatinine	88 µmol/L	(55 - 120)
CRP	52 mg/L	(< 5)
Bilirubin	12 µmol/L	(3 - 17)
ALP	88 u/L	(30 - 100)
ALT	32 u/L	(3 - 40)

Chest radiography reveals bilateral patchy airspace opacification.

Which organism is most likely responsible for his illness?

- *Chlamydia psittaci*

- *Klebsiella pneumoniae*
- *Legionella pneumophilia*
- *Leptospira alexanderi*
- *Staphylococcus aureus*

Submit answer

Reference ranges

Score: **0%**

1 -
2 -
3 -
4 -
5 -
6 -
7 -
8 -
9 -
10 -
11 -
12 -
13 -
14 -
15 -
16 -
17 -
18 -
19 -
20 -
21 -
22 -

23	-
24	-

All contents of this site are © 2024 Passmedicine Limited

A 45-year-old man presents to the emergency department with reports of 8 days of fever, headache, epistaxis, diarrhoea and cough. He has no past medical history. He drinks 32 units of alcohol a week. He keeps parrots and enjoys open water swimming in rivers.

Observations:

- Heart rate 88 beats per minute
- Blood pressure 115/74 mmHg
- Respiratory rate 21/minute
- Oxygen saturations 94% on room air

On examination, there is splenomegaly. Chest auscultation reveals crackles in both lungs.

Blood tests:

Hb	136 g/L	Male: (135-180) Female: (115 - 160)
Platelets	189 * 10^9/L	(150 - 400)
WBC	2.9 * 10^9/L	(4.0 - 11.0)
Na^+	136 mmol/L	(135 - 145)
K^+	4.2 mmol/L	(3.5 - 5.0)
Urea	4.2 mmol/L	(2.0 - 7.0)
Creatinine	88 µmol/L	(55 - 120)
CRP	52 mg/L	(< 5)
Bilirubin	12 µmol/L	(3 - 17)
ALP	88 u/L	(30 - 100)
ALT	32 u/L	(3 - 40)

Chest radiography reveals bilateral patchy airspace opacification.

Which organism is most likely responsible for his illness?

Chlamydia psittaci 64%

Klebsiella pneumoniae	10%
Legionella pneumophilia	11%
Leptospira alexanderi	14%
Staphylococcus aureus	1%

Chlamydia psittaci is a cause of atypical pneumonia. It is transmitted via aerosol inhalation of faecal and urinary products on bird feathers

Important for me   Less important

Chlamydia psittaci is the correct answer. This organism can cause Psittacosis, which is a cause of atypical pneumonia. The prodrome can involve diarrhoea, epistaxis and high fevers. Splenomegaly and a low white blood cell count are common. This organism should be suspected in cases of respiratory infection together with splenomegaly and epistaxis, which is rare as a constellation of symptoms. The classic zoonotic exposure for this condition is birds (including parrots).

Klebsiella pneumoniae is incorrect. This is common in those people who drink to excess, as this patient does. However, it tends to cause cavitating pneumonia and is not associated with epistaxis.

Legionella pneumophilia is incorrect. This can cause atypical pneumonia and diarrhoea. However, the white cell count will be elevated and it tends not to cause epistaxis and splenomegaly is less common. Sodium may be low and liver function may be deranged. Patients are typically exposed to poorly ventilated air conditioning systems.

Leptospira alexanderi is incorrect. This causes Leptospirosis. This is typically characterized by jaundice, subconjunctival haemorrhages and deranged liver function. While freshwater swimming may expose the patient to this organism, it does not cause atypical pneumonia.

Staphylococcus aureus is incorrect. This causes typical cavitating pneumonia. Often this occurs as a secondary bacterial infection after an episode of influenza.

Discuss (3)   Improve

Next question

Pneumonia: a very basic introduction

Pneumonia is one of the most common presentations encountered in clinical practice. Strictly speaking, it describes any inflammatory condition affecting the alveoli of the lungs, but in the vast majority of patients this is secondary to a bacterial infection.

Causes

As mentioned before, **bacterial pneumonia is by far the most common type of pneumonia** seen in clinical practice. Other infective causes include:

- viral
- fungal (e.g. *Pneumocystis jiroveci*)

The table below shows some of the organisms which can cause pneumonia

Organism	Notes
Streptococcus pneumoniae (pneumococcus)	Accounts for 80% of cases Particularly associated with high fever, rapid onset and herpes labialis A vaccine to pneumococcus is available
Haemophilus influenzae	Particularly common in patients with COPD
Staphylococcus aureus	Often occurs in patient following influenza infection
Mycoplasma pneumoniae	One of the atypical pneumonias, which often present a dry cough and atypical chest signs/x-ray findings Autoimmune haemolytic anaemia and erythema multiforme may be seen
Legionella pneumophilia	Another one of the atypical pneumonias Hyponatraemia and lymphopenia common Classically seen secondary to infected air conditioning units
Klebsiella pneumoniae	Classically seen in alcoholics
Pneumocystis jiroveci	Typically seen in patients with HIV Presents with a dry cough, exercise-induced desaturations and the absence of chest signs

Idiopathic interstitial pneumonia is a group of non-infective causes of pneumonia. Examples include cryptogenic organizing pneumonia which describes a form of bronchiolitis that may develop as a complication of rheumatoid arthritis or amiodarone therapy.

Community vs. hospital-acquired pneumonia

The majority of patients develop pneumonia within the community, i.e. outside of hospital and these patients are said to have community-acquired pneumonia (CAP). Patients who develop pneumonia within hospitals (occuring 48 hours or more after admission) are said to have hospital-acquired pneumonia. The distinction is important as the causative organisms vary and hence first-line antibiotic guidelines are also different.

Symptoms and signs

Symptoms

- cough
- sputum
- dyspnoea
- chest pain: may be pleuritic
- fever

Signs

- signs of systemic inflammatory response
  - fever
  - tachycardia
- reduced oxygen saturations
- auscultation:
  - reduced breath sounds
  - bronchial breathing

Investigations

Chest x-ray

- the classical x-ray finding in pneumonia is consolidation

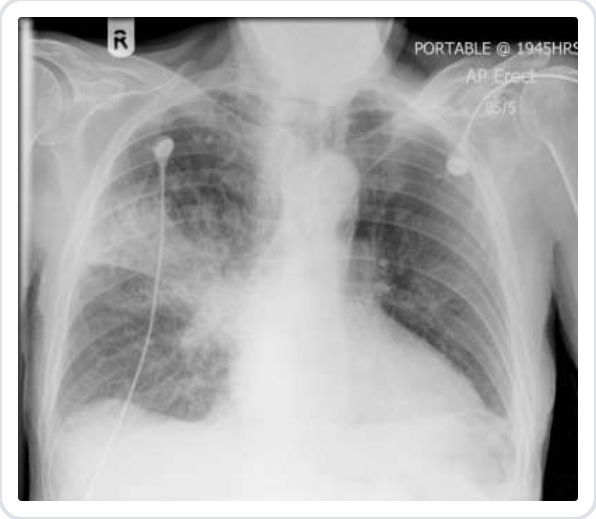

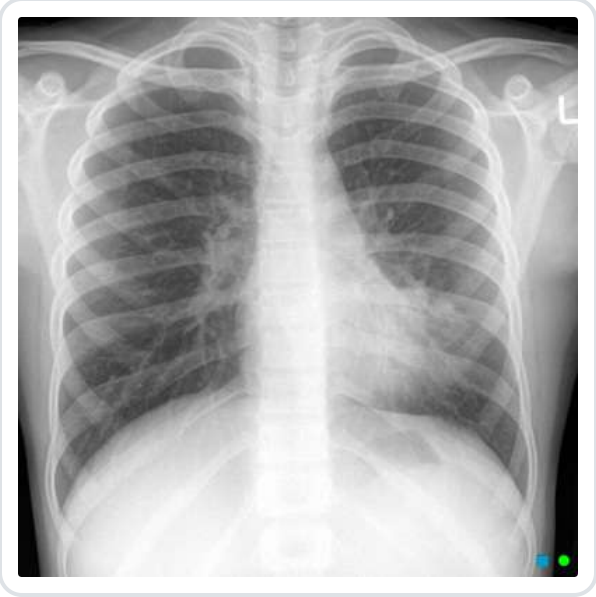

Bloods

- full blood count
  - would usually show a neutrophilia in bacterial infections
- urea and electrolytes
  - check for dehydration (remember the 'U' for urea in CURB-65, see below)
  - also other changes seen with some atypical pneumonias
- CRP
  - raised in response to infection

Arterial blood gases

- indicated if the oxygen saturations or low or the patient has pre-existing respiratory disease, for example, COPD

Management

Patients with pneumonia require the following:

- antibiotics: to treat the underlying infection
- supportive care, for example:
  - oxygen therapy if the patient is hypoxaemic
  - intravenous fluids if the patient is hypotensive or shows signs of dehydration

Risk stratification

The management of patients with community-acquired pneumonia is usually determined according to a risk stratification process using a scoring system called CURB-65. In a primary care setting this is CRB-65, due to the inability to get a serum urea result (urea is the 'U' in CURB-65).

The CRB-65 score is as follows:

Criterion	Marker
C	Confusion (abbreviated mental test score <= 8/10)
R	Respiration rate >= 30/min
B	Blood pressure: systolic <= 90 mmHg and/or diastolic <= 60 mmHg
65	Aged >= 65 years

NICE recommend, in conjunction with clinical judgement:

- home-based care for patients with a CRB65 score of 0
  - oral amoxicillin is generally used first-line
- hospital assessment for all other patients, particularly those with a CRB65 score of 2 or more.

The CURB-65 score also correlates with an increased risk of mortality at 30 days with patients with a CURB-65 score of 4 approaching a 30% mortality rate at 30 days.

+ Q 123

Next question >

Textbooks

High-yield textbook

Extended textbook

Links

Clinical Knowledge Summaries 3 7

Community-acquired pneumonia

NICE

9 3

2014 Pneumonia in adults: diagnosis and management

Suggest link

Report broken link

Media

Pneumonia

Osmosis - YouTube 1 0

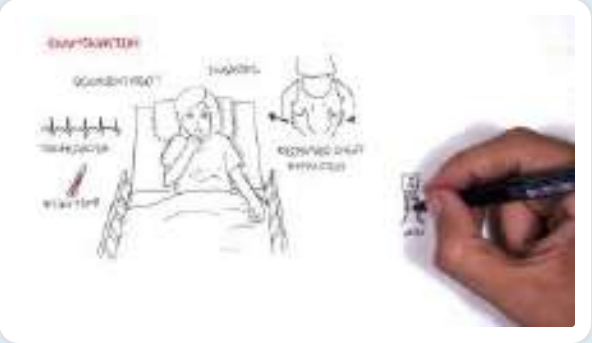

Community Acquired Pneumonia

Armando Hasudungan - YouTube 1 0

Report broken media

Score: **24%**

1 ✗
2 ✗
3 ✗
4 ✗
5 ✗
6 ✗
7 ✗
8 ✗
9 ✓

10	✓
11	✗
12	✗
13	✗
14	✓
15	✗
16	✓
17	✗
18	✗
19	✗
20	✗
21	✓
22	✓
23	✗
24	✗
25	✗

All contents of this site are © 2024 Passmedicine Limited

Back to top

A 26-year-old man is reviewed in the asthma clinic. Despite therapy with high dose fluticasone / salmeterol montelukast and oral theophylline, he has suffered a 4th exacerbation in the past year and is now unable to reduce his dose of oral prednisone below 10mg without a significant increase in shortness of breath and wheeze. On examination his blood pressure is 123/80 mmHg, his pulse is 80 beats per minute and regular. Auscultation of the chest reveals quiet wheeze. His peak flow is 429 ml/min, (550 predicted). Eosinophils are elevated at 3.9 x 10(9)/l. IgE is within the normal range.

Which of the following is the most appropriate next intervention?

- Mycophenolate
- Mepolizumab
- Infliximab
- Tiotropium
- Regular nebulisers

Submit answer

Reference ranges

Score: **0%**

1 -
2 -
3 -
4 -
5 -
6 -

7 -
8 -
9 -
10 -
11 -
12 -
13 -
14 -
15 -
16 -
17 -
18 -
19 -
20 -
21 -
22 -
23 -
24 -
25 -

All contents of this site are © 2024 Passmedicine Limited

A 26-year-old man is reviewed in the asthma clinic. Despite therapy with high dose fluticasone / salmeterol montelukast and oral theophylline, he has suffered a 4th exacerbation in the past year and is now unable to reduce his dose of oral prednisone below 10mg without a significant increase in shortness of breath and wheeze. On examination his blood pressure is 123/80 mmHg, his pulse is 80 beats per minute and regular. Auscultation of the chest reveals quiet wheeze. His peak flow is 429 ml/min, (550 predicted). Eosinophils are elevated at 3.9 x 10(9)/l. IgE is within the normal range.

Which of the following is the most appropriate next intervention?

Mycophenolate	4%
Mepolizumab	82%
Infliximab	4%
Tiotropium	8%
Regular nebulisers	2%

Mepolizumab may be used for asthma with high eosinophils

Important for me   Less important

Mepolizumab is an anti-IL5 monoclonal antibody and represents the optimal intervention here. It binds to IL5 and prevents it from binding to its receptor. IL5 is a cytokine which promotes growth in eosinophil numbers and activity. By blocking IL5 mepolizumab down-regulates eosinophil activity and has been shown to significantly improve symptoms in resistant asthma. Omalizumab is an anti-IgE monoclonal antibody, it is effective in treating resistant asthma with evidence of raised IgE and allergic symptoms and is often considered for similar patients to those treated with mepolizumab, although eosinophil count and IgE drive which of the two therapies are used.

Mycophenolate is not utilised as a disease modifying agent in resistant asthma, but is primarily used for the treatment of lupus nephritis and as an anti-rejection agent. Infliximab is an anti-TNF monoclonal antibody used in the treatment of inflammatory bowel disease and arthritides. Tiotropium is primarily used in the treatment of COPD, and is less effective than other options listed in the treatment of resistant asthma. Nebulisers only have a role in treating asthma where patients are unable to administer beta agonist therapy using a conventional inhaler and spacer

device.

https://www.nice.org.uk/guidance/ta431

Discuss (5) Improve

Next question

Drugs used in respiratory medicine

Drug	Mechanism of action	Notes
Salbutamol	Beta receptor agonist	• Short-acting inhaled bronchodilator. Relaxes bronchial smooth muscle through effects on beta 2 receptors • Used in asthma and chronic obstructive pulmonary disease (COPD). • Salmeterol has similar effects but is long-acting
Corticosteroids	Anti-inflammatory	• Inhaled corticosteroids are used as mainterance therapy • Oral or intravenous corticosteroids are used following an acute exacerbation of asthma or COPD
Ipratropium	Blocks the muscarinic acetylcholine receptors	• Short-acting inhaled bronchodilator. Relaxes bronchial smooth muscle • Used primarily in COPD • Tiotropium has similar effects but is long-acting
Methylxanthines (e.g. theophylline)	Non-specific inhibitor of phosphodiesterase resulting in an increase in cAMP	• Given orally or intravenously • Has a narrow therapeutic index
Monteleukast, zafirlukast	Blocks leukotriene receptors	• Usually taken orally • Useful in aspirin-induced asthma

123

Next question

Textbooks

High-yield textbook

Extended textbook

Score: **24%**

1	✗
2	✗
3	✗
4	✗
5	✗
6	✗
7	✗
8	✗
9	✓
10	✓
11	✗
12	✗
13	✗
14	✓
15	✗

16	✓
17	✗
18	✗
19	✗
20	✗
21	✓
22	✓
23	✗
24	✗
25	✗

All contents of this site are © 2024 Passmedicine Limited

Back to top

A 64-year-old is referred to the respiratory clinic by his general practitioner. He has had four exacerbations of chronic obstructive pulmonary disease in the last 12 months, having previously been well controlled. His forced expiratory volume in one second (FEV1) is 44% of the predicted normal. His inhaled medications include a long-acting muscarinic antagonist, a long-acting beta-2 agonist and an inhaled corticosteroid. He quit smoking five years previously. His six-minute walk distance is 100m.

On examination, he is barrel-chested and there is mild wheeze heard bilaterally. The jugular venous pulse is not raised and there is no peripheral oedema.

What is the most appropriate next step in management?

- Add furosemide
- Add oral prednisolone
- Add roflumilast
- Refer for lung volume reduction surgery
- Add zafirlukast

Submit answer

Reference ranges

Score: **24%**

1	×
2	×
3	×
4	×

5	✗
6	✗
7	✗
8	✗
9	✓
10	✓
11	✗
12	✗
13	✗
14	✓
15	✗
16	✓
17	✗
18	✗
19	✗
20	✗
21	✓
22	✓
23	✗
24	✗
25	✗
26	-

All contents of this site are © 2024 Passmedicine Limited

A 64-year-old is referred to the respiratory clinic by his general practitioner. He has had four exacerbations of chronic obstructive pulmonary disease in the last 12 months, having previously been well controlled. His forced expiratory volume in one second (FEV1) is 44% of the predicted normal. His inhaled medications include a long-acting muscarinic antagonist, a long-acting beta-2 agonist and an inhaled corticosteroid. He quit smoking five years previously. His six-minute walk distance is 100m.

On examination, he is barrel-chested and there is mild wheeze heard bilaterally. The jugular venous pulse is not raised and there is no peripheral oedema.

What is the most appropriate next step in management?

Add furosemide	0%
Add oral prednisolone	7%
Add roflumilast	73%
Refer for lung volume reduction surgery	13%
Add zafirlukast	6%

Roflumilast should be used in COPD for patients who are losing control on triple inhaled therapy

Important for me Less important

Add roflumilast is correct. This is a long-acting inhibitor of the enzyme phosphodiesterase-4. This is an option for treating severe COPD in cases where the FEV1 is < 50% and the person has had 2 or more exacerbations in the previous 12 months despite triple inhaled therapy with a long-acting muscarinic antagonist, a long-acting beta-2 agonist and an inhaled corticosteroid.

Add furosemide is incorrect. The patient presents with worsening symptoms of COPD rather than right heart failure. He is euvolemic and furosemide would not be of benefit in this case.

Refer for lung volume reduction surgery is incorrect. To be a candidate for lung volume reduction surgery, patients need to be able to complete a six-minute walk distance of at least 140m.

Add zafirlukast is incorrect. This is an orally administered leukotriene receptor antagonist used for the chronic treatment of asthma rather than COPD.

Add oral prednisolone is incorrect. This is typically used to treat acute exacerbations of COPD rather than prevent further exacerbations.

Discuss (3) Improve

Next question

Drugs used in respiratory medicine

Drug	Mechanism of action	Notes
Salbutamol	Beta receptor agonist	• Short-acting inhaled bronchodilator. Relaxes bronchial smooth muscle through effects on beta 2 receptors • Used in asthma and chronic obstructive pulmonary disease (COPD). • Salmeterol has similar effects but is long-acting
Corticosteroids	Anti-inflammatory	• Inhaled corticosteroids are used as maintenance therapy • Oral or intravenous corticosteroids are used following an acute exacerbation of asthma or COPD
Ipratropium	Blocks the muscarinic acetylcholine receptors	• Short-acting inhaled bronchodilator. Relaxes bronchial smooth muscle • Used primarily in COPD • Tiotropium has similar effects but is long-acting
Methylxanthines (e.g. theophylline)	Non-specific inhibitor of phosphodiesterase resulting in an increase in cAMP	• Given orally or intravenously • Has a narrow therapeutic index

Drug	Mechanism of action	Notes
Monteleukast, zafirlukast	Blocks leukotriene receptors	• Usually taken orally • Useful in aspirin-induced asthma

AI + Q 123

Next question >

Textbooks

High-yield textbook

Extended textbook

Score: **20.4%**

1	✗
2	✗
3	✗
4	✗
5	✗
6	✗
7	✗
8	✗
9	✓
10	✓

11	✗
12	✗
13	✗
14	✓
15	✗
16	✓
17	✗
18	✗
19	✗
20	✗
21	✓
22	✓
23	✗
24	✗
25	✗
26	✗
27	✓
28	✗
29	✗
30	✓
31	✓
32	✗
33	✗
34	✗
35	✗
36	✗
37	✗
38	✗
39	✗
40	-
41	✗
42	✗
43	✗
44	✗
45	✓
46	✗

47	✕
48	✕
49	✕
50	✕
51	-

All contents of this site are © 2024 Passmedicine Limited

A 25-year-old man attends the clinic. He is planning an expedition to the peak of Mount Everest. He is keen to take a medicine to prevent against acute mountain sickness. He has no past medical history and takes no regular medications.

What treatment will you prescribe?

- Dexamethasone
- Nifedipine
- Sildenafil
- Dorzolamide
- Acetazolamide

Submit answer

Reference ranges

Score: **24%**

1 ✗
2 ✗
3 ✗
4 ✗
5 ✗
6 ✗
7 ✗
8 ✗
9 ✓

10	✓
11	✗
12	✗
13	✗
14	✓
15	✗
16	✓
17	✗
18	✗
19	✗
20	✗
21	✓
22	✓
23	✗
24	✗
25	✗
26	-
27	-

All contents of this site are © 2024 Passmedicine Limited

A 25-year-old man attends the clinic. He is planning an expedition to the peak of Mount Everest. He is keen to take a medicine to prevent against acute mountain sickness. He has no past medical history and takes no regular medications.

What treatment will you prescribe?

Dexamethasone	6%
Nifedipine	6%
Sildenafil	2%
Dorzolamide	5%
Acetazolamide	82%

Acetazolamide (a carbonic anhydrase inhibitor) can be used to prevent acute mountain sickness

Important for me Less important

If pharmacological prophylaxis of acute mountain sickness is required, then acetazolamide is first line. This drug is a carbonic anhydrase inhibitor which acts on the kidneys to generate a primary a metabolic acidosis. A compensatory respiratory alkalosis occurs in response, resulting in hyperventilation and improved oxygenation.

Dexamethasone, nifedipine and phosphodiesterase type V inhibitors (e.g. sildenafil) can be used both in the treatment and prophylaxis of acute mountain sickness, however for prophylaxis they are second line agents.

Dorzolamide is a topical carbonic anhydrase inhibitor used in glaucoma.

Discuss (2) Improve

Next question

Altitude related disorders

There are three main types of altitude-related disorders: acute mountain sickness (AMS), which may progress to high altitude pulmonary oedema (HAPE) or high altitude cerebral oedema (HACE). All three conditions are due to the chronic hypobaric hypoxia which develops at high altitudes

Acute mountain sickness is generally a self-limiting condition. Features of AMS start to occur above 2,500 - 3,000m, developing gradually over 6-12 hours and potentially last a number of days:

- headache
- nausea
- fatigue

Prevention and treatment of AMS

- the risk of AMS may actually be positively correlated to physical fitness
- gain altitude at no more than 500 m per day
- acetazolamide (a carbonic anhydrase inhibitor) is widely used to prevent AMS and has a supporting evidence base
    - it causes a primary metabolic acidosis and compensatory respiratory alkalosis which increases respiratory rate and improves oxygenation
- treatment: descent

A minority of people above 4,000m go onto develop high altitude pulmonary oedema (HAPE) or high altitude cerebral oedema (HACE), potentially fatal conditions

- HAPE
    - mechanism: hypobaric hypoxia → uneven hypoxic pulmonary vasoconstriction → uneven blood flow in the lungs → areas of the lung receiving more blood experience an increase in capillary pressure → more fluid leakage. Hypoxia may also directly increase capillary permeability, exacerbating fluid leakage into the alveolar space.
    - presents with classical pulmonary oedema features
- HACE
    - in contrast to the above, cerebral *vasodilation* is the problem. Hypoxia → cerebral vasodilation → elevated cerebral blood volume
    - also, hypoxia → increase in the permeability of the blood-brain barrier → capillaries in the brain more leaky → leading to fluid accumulation in the extracellular spaces
    - both these factors → cerebral oedema
    - presents with headache, ataxia, papilloedema

Management of HACE

- descent

- dexamethasone

Management of HAPE

- descent
- nifedipine, dexamethasone, acetazolamide, phosphodiesterase type V inhibitors*
- oxygen if available

*the relative merits of these different treatments has only been studied in small trials. All seem to work by reducing systolic pulmonary artery pressure

123

Next question

Textbooks

High-yield textbook

Extended textbook

Media

High Altitude Illness

Individual - YouTube 6 0

Report broken media

Score: **20.4%**

1	✗
2	✗
3	✗
4	✗
5	✗
6	✗
7	✗
8	✗
9	✓
10	✓
11	✗
12	✗
13	✗
14	✓
15	✗
16	✓
17	✗
18	✗
19	✗
20	✗
21	✓
22	✓
23	✗
24	✗
25	✗
26	✗
27	✓
28	✗
29	✗
30	✓
31	✓
32	✗
33	✗

34	✗
35	✗
36	✗
37	✗
38	✗
39	✗
40	-
41	✗
42	✗
43	✗
44	✗
45	✓
46	✗
47	✗
48	✗
49	✗
50	✗
51	-

All contents of this site are © 2024 Passmedicine Limited

A 27-year-old woman with brittle asthma presents to the Emergency department. She is managed with high dose salmeterol/fluticasone and montelukast but reports steadily worsening symptoms since starting with a cold some 48hrs earlier. She has been admitted to the intensive care unit on 3 previous occasions. On examination her blood pressure is 122/82 mmHg pulse rate is 88 beats per minute. On auscultation of her chest you hear quiet breath sounds with polyphonic wheeze, her respiratory rate is 30/min. She is given back to back salbutamol nebulisers, ipratropium nebulisers, and IV hydrocortisone. These interventions only lead to minimal improvement in her PEFR from 110 to 140, (330 predicted). Oxygen saturation is 92% measured by pulse oximeter, on 60% oxygen delivered via mask. You call the anaesthetist for possible intubation.

Which of the following is the most appropriate next step?

- IV aminophylline
- IV chlorpheniramine
- IV magnesium
- IV salbutamol
- IV omalizumab

Submit answer

Reference ranges

Score: **24%**

1 ✗
2 ✗
3 ✗

4	✗
5	✗
6	✗
7	✗
8	✗
9	✓
10	✓
11	✗
12	✗
13	✗
14	✓
15	✗
16	✓
17	✗
18	✗
19	✗
20	✗
21	✓
22	✓
23	✗
24	✗
25	✗
26	-
27	-
28	-

All contents of this site are © 2024 Passmedicine Limited

Back to top

A 27-year-old woman with brittle asthma presents to the Emergency department. She is managed with high dose salmeterol/fluticasone and montelukast but reports steadily worsening symptoms since starting with a cold some 48hrs earlier. She has been admitted to the intensive care unit on 3 previous occasions. On examination her blood pressure is 122/82 mmHg pulse rate is 88 beats per minute. On auscultation of her chest you hear quiet breath sounds with polyphonic wheeze, her respiratory rate is 30/min. She is given back to back salbutamol nebulisers, ipratropium nebulisers, and IV hydrocortisone. These interventions only lead to minimal improvement in her PEFR from 110 to 140, (330 predicted). Oxygen saturation is 92% measured by pulse oximeter, on 60% oxygen delivered via mask. You call the anaesthetist for possible intubation.

Which of the following is the most appropriate next step?

- IV aminophylline 9%
- IV chlorpheniramine 0%
- IV magnesium 86%
- IV salbutamol 1%
- IV omalizumab 4%

This patient has acute severe asthma with little or no improvement from initial nebuliser therapy. As such she requires assessment for possible intubation. In the mean time however, guidelines support the use of IV magnesium. A dose of 2g is commonly given over a period of 20 mins, where it has been shown to improve pulmonary function when added to standard therapy.

Both IV aminophylline and salbutamol may be associated with significant tachyarrhythmias and hold limited benefit over and above inhaled beta agonists, they are therefore not recommended in this situation. Anti-histamines are of limited benefit, and IV omalizumab is used as a treatment for patients with allergic asthma which is resistant to other therapeutic options.

Discuss (2) Improve

Next question

Acute asthma: management

The British Thoracic Society (BTS) classify patients with acute asthma into moderate, severe or life-threatening categories.

Moderate	Severe	Life-threatening
PEFR 50-75% best or predicted Speech normal RR < 25 / min Pulse < 110 bpm	PEFR 33 - 50% best or predicted Can't complete sentences RR > 25/min Pulse > 110 bpm	PEFR < 33% best or predicted Oxygen sats < 92% 'Normal' $pC0_2$ (4.6-6.0 kPa) Silent chest, cyanosis or feeble respiratory effort Bradycardia, dysrhythmia or hypotension Exhaustion, confusion or coma

Note that a patient having any one of the life-threatening features should be treated as having a life-threatening attack.

A fourth category, '**Near-fatal asthma**', is also recognised characterised by a raised $pC0_2$ and/or requiring mechanical ventilation with raised inflation pressures.

Further assessment

- the BTS guidelines recommend arterial blood gases for patients with oxygen sats < 92%
- a chest x-ray is not routinely recommended, unless:
  - life-threatening asthma
  - suspected pneumothorax
  - failure to respond to treatment

Management

- admission
  - all patients with life-threatening should be admitted in hospital
  - patients with features of severe acute asthma should also be admitted if they fail to respond to initial treatment.
  - other admission criteria include a previous near-fatal asthma attack, pregnancy, an attack occurring despite already using oral corticosteroid and presentation at night
- oxygen
  - if patients are hypoxaemic, it is important to start them on supplemental oxygen therapy

    - if patients are acutely unwell they should be started on 15L of supplemental via a non-rebreathe mask, which can then be titrated down to a flow rate where they are able to maintain a SpO_2, 94-98%.
- bronchodilation with short-acting beta$_2$-agonists (SABA)
    - high-dose inhaled SABA e.g. salbutamol, terbutaline
    - in patients without features of life-threatening or near-fatal asthma, this can be given by a standard pressurised metered-dose inhaler (pMDI) or by an oxygen-driven nebulizer
    - in patients with features of a life-threatening exacerbation of asthma, nebulised SABA is recommended
- corticosteroid
    - all patients should be given 40-50mg of prednisolone orally (PO) daily, which should be continued for at least five days or until the patient recovers from the attack
    - during this time, patients should continue their normal medication routine including inhaled corticosteroids.
- ipratropium bromide: in patients with severe or life-threatening asthma, or in patients who have not responded to beta$_2$-agonist and corticosteroid treatment, nebulised ipratropium bromide, a short-acting muscarinic antagonist
- IV magnesium sulphate
    - the BTS notes that the evidence base is mixed for this treatment that is now commonly given for severe/life-threatening asthma
- IV aminophylline may be considered following consultation with senior medical staff
- patients who fail to respond require senior critical care support and should be treated in an appropriate ITU/HDU setting. Treatment options include:
    - intubation and ventilation
    - extracorporeal membrane oxygenation (ECMO)

Criteria for discharge

- been stable on their discharge medication (i.e. no nebulisers or oxygen) for 12-24 hours
- inhaler technique checked and recorded
- PEF >75% of best or predicted

123

Next question

Textbooks

High-yield textbook

Extended textbook

Links

British Thoracic Society 44 73

2019 Asthma guidelines

Suggest link Report broken link

Score: **20.4%**

1	✗
2	✗
3	✗
4	✗
5	✗
6	✗
7	✗
8	✗
9	✓
10	✓
11	✗
12	✗
13	✗
14	✓
15	✗
16	✓
17	✗
18	✗
19	✗

20	✗
21	✓
22	✓
23	✗
24	✗
25	✗
26	✗
27	✓
28	✗
29	✗
30	✓
31	✓
32	✗
33	✗
34	✗
35	✗
36	✗
37	✗
38	✗
39	✗
40	-
41	✗
42	✗
43	✗
44	✗
45	✓
46	✗
47	✗
48	✗
49	✗
50	✗
51	-

All contents of this site are © 2024 Passmedicine Limited

Back to top

A 49-year-old man attends the emergency department after becoming unwell with symptoms of progressive shortness of breath. The man is a Saudi Arabian national, who arrived in the UK 3 days previously on a business trip. The patient reported his shortness of breath had gradually worsened over the previous 2 days to the point whereby even minor physical activity had become challenging. In addition, the patient had noticed a dry cough, runny nose, myalgia and fever over a similar period. The patient denied any history of a productive cough, haemoptysis or gastrointestinal symptoms.

The patient reported being in generally good health aside from the type 2 diabetes mellitus and hypertension. To control these conditions, the patient took regular metformin and captopril. The patient had no known allergies to medications. The patient worked as an international businessman and normally resided in Riyadh with his family. He denied any contact with domestic animals in recent months and had not knowingly spent time with any unwell contacts.

General examination of the patient revealed a slightly overweight middle aged man who appeared unwell and diaphoretic. Basic physical observations are recorded in the below table. Examination of the respiratory system revealed mild tachypnoea at rest but with unremarkable percussion and auscultation of both lung fields. Examinations of the cardiovascular and abdominal systems were unremarkable. No clinical evidence of deep vein thrombosis was identified. Please see below for results of initial investigations requested following assessment by the respiratory medicine team.

Heart rate	95 beats / minute
Respiratory rate	23 respirations / minute
Blood pressure	128 / 85 mmHg
Oxygen saturations (room air)	89 %
Oxygen saturations (O2 3 L / minute via nasal cannulae)	95 %
Glasgow coma scale score	15

Haemoglobin	145 g / dL
Mean cell volume	80.2 fl
White cell count	3.1 x 10>3 / microlitre
Lymphocytes	1.0 x 10>3 / microlitre (reference 1.5-4.0)
Platelets	115 x 10>3 / microlitre
Urea	6.4 mmol / L

Creatinine	85 micromol / L
eGFR	85 ml / min / 1.73 m2
Sodium	139 mmol / L
Potassium	4.0 mmol / L
C-reactive protein	74 mg / L (reference < 7)
Urinalysis	no abnormality detected
Chest x-ray	no pneumothorax; lung fields generally clear with no focal consolidation; no mass lesions
Electrocardiogram	normal sinus rhythm
Nasopharyngeal swab RT-PCR	MERS-CoV RNA detected

What is appropriate medical management for the patient's condition?

- Treatment in the community with anti-pyretic
- Intravenous ganciclovir (5 mg / kg twice daily for 14 days)
- In-patient supportive treatment to relieve symptoms and prevent or treat complications
- Oral oseltamivir (75 mg twice daily for 5 days)
- Inhaled zanamivir (10 mg twice daily for 5 days)

Submit answer

Reference ranges

Score: **24%**

1 ✕
2 ✕
3 ✕

4	✗
5	✗
6	✗
7	✗
8	✗
9	✓
10	✓
11	✗
12	✗
13	✗
14	✓
15	✗
16	✓
17	✗
18	✗
19	✗
20	✗
21	✓
22	✓
23	✗
24	✗
25	✗
26	-
27	-
28	-
29	-

All contents of this site are © 2024 Passmedicine Limited

A 49-year-old man attends the emergency department after becoming unwell with symptoms of progressive shortness of breath. The man is a Saudi Arabian national, who arrived in the UK 3 days previously on a business trip. The patient reported his shortness of breath had gradually worsened over the previous 2 days to the point whereby even minor physical activity had become challenging. In addition, the patient had noticed a dry cough, runny nose, myalgia and fever over a similar period. The patient denied any history of a productive cough, haemoptysis or gastrointestinal symptoms.

The patient reported being in generally good health aside from the type 2 diabetes mellitus and hypertension. To control these conditions, the patient took regular metformin and captopril. The patient had no known allergies to medications. The patient worked as an international businessman and normally resided in Riyadh with his family. He denied any contact with domestic animals in recent months and had not knowingly spent time with any unwell contacts.

General examination of the patient revealed a slightly overweight middle aged man who appeared unwell and diaphoretic. Basic physical observations are recorded in the below table. Examination of the respiratory system revealed mild tachypnoea at rest but with unremarkable percussion and auscultation of both lung fields. Examinations of the cardiovascular and abdominal systems were unremarkable. No clinical evidence of deep vein thrombosis was identified. Please see below for results of initial investigations requested following assessment by the respiratory medicine team.

Heart rate	95 beats / minute
Respiratory rate	23 respirations / minute
Blood pressure	128 / 85 mmHg
Oxygen saturations (room air)	89 %
Oxygen saturations (O2 3 L / minute via nasal cannulae)	95 %
Glasgow coma scale score	15

Haemoglobin	145 g / dL
Mean cell volume	80.2 fl
White cell count	3.1 x 10>3 / microlitre
Lymphocytes	1.0 x 10>3 / microlitre (reference 1.5-4.0)
Platelets	115 x 10>3 / microlitre
Urea	6.4 mmol / L

Creatinine	85 micromol / L
eGFR	85 ml / min / 1.73 m2
Sodium	139 mmol / L
Potassium	4.0 mmol / L
C-reactive protein	74 mg / L (reference < 7)
Urinalysis	no abnormality detected
Chest x-ray	no pneumothorax; lung fields generally clear with no focal consolidation; no mass lesions
Electrocardiogram	normal sinus rhythm
Nasopharyngeal swab RT-PCR	MERS-CoV RNA detected

What is appropriate medical management for the patient's condition?

Treatment in the community with anti-pyretic	5%
Intravenous ganciclovir (5 mg / kg twice daily for 14 days)	3%
In-patient supportive treatment to relieve symptoms and prevent or treat complications	72%
Oral oseltamivir (75 mg twice daily for 5 days)	16%
Inhaled zanamivir (10 mg twice daily for 5 days)	4%

Middle East respiratory syndrome (MERS) is an acute viral respiratory tract infection caused by the betacoronavirus MERS-CoV. Infection with MERS-CoV is believed to originate from individuals coming in close contact with dromedary camels or consuming camel products (for example, unpasteurised camel milk). However, the majority of cases, are the result of human-to-human transmission via respiratory droplets, particularly secondary to outbreaks in the hospital setting. MERS is limited to the countries of the Arabian Peninsula, but individuals who have travelled from or through that region may present in other countries given the 2-14 day incubation period.

Most patients with MERS present with respiratory symptoms and fever. A cough secondary to MERS is typically dry, but may be productive in up to one-third of patients; haemoptysis is less common, occurring in around 10 % of patients. The clinical spectrum of MERS ranges from asymptomatic or minor respiratory symptoms through to severe pneumonia associated with multi-organ failure. Severe disease is more likely to occur in older individuals or in those with co-morbidities.

Routine blood tests in MERS can show lymphocytopenia, thrombocytopenia, acute kidney injury or

deranged liver function tests. MERS is confirmed via detection of viral RNA by reverse transcription polymerase chain reaction analysis of respiratory tract secretions.

Management of MERS requires intervention to minimise symptoms and prevent harm from complications such as respiratory failure or septic shock from superadded bacterial pneumonia. No specific drug treatment is available to treat MERS-CoV. The specific treatments given as possible answers are all anti-viral agents used in the treatment of other conditions: oseltamivir and zanamivir for influenza and ganciclovir for cytomegalovirus infections.

Given the patient's hypoxaemia, tachypnoea and comorbidities, it would not be appropriate to manage this patient in the community due to the high risk of clinical deterioration secondary to complications.

Shalhoub S, Omrani A. Middle East respiratory syndrome. BMJ 2016;355:i5281.

Discuss (8) Improve

Next question

Middle East respiratory syndrome

Middle East respiratory syndrome (MERS) is caused by the betacoronavirus MERS-CoV.

At the present time, MERS-CoV is limited to the Arabian Peninsula and its surrounding countries, although due to an incubation period of 2-14 days travellers returning from this region may present with MERS in other parts of the world.

Contact with camels (including camel products such as milk) is a significant risk factor for MERS-CoV.

The clinical syndrome of MERS is varied, ranging from very only mild symptoms through to life-threatening multi-organ failure.

123

Next question

Textbooks

High-yield textbook

Extended textbook

Media

MERS CoV - An overview

Let's Learn About Bugs - YouTube 3 1

Report broken media

Score: **20.4%**

1	✗
2	✗
3	✗
4	✗
5	✗
6	✗
7	✗
8	✗
9	✓
10	✓
11	✗
12	✗
13	✗

14	✓
15	✗
16	✓
17	✗
18	✗
19	✗
20	✗
21	✓
22	✓
23	✗
24	✗
25	✗
26	✗
27	✓
28	✗
29	✗
30	✓
31	✓
32	✗
33	✗
34	✗
35	✗
36	✗
37	✗
38	✗
39	✗
40	-
41	✗
42	✗
43	✗
44	✗
45	✓
46	✗
47	✗
48	✗
49	✗

50	✕
51	-

All contents of this site are © 2024 Passmedicine Limited

A 50-year-old man is admitted under the respiratory team with a left lower lobe pneumonia. He has a history of chronic obstructive pulmonary disease and continues to smoke. He also suffers with with hypertension and high cholesterol.

He is treated with steroids, nebulisers and antibiotics. After 5 days he continues to be hypoxic with saturations of 86% on air, ongoing left basal crepitations and wheeze.

A CT scan of the chest is performed which shows emphysematous changes and resolving left basal consolidation. There is also a 7mm lung nodule in the right upper lobe with surrounding ground glass change.

Over the next 3 days his saturations improve to 93% on air and his symptoms resolve. He is discharged home.

What imaging does he require to follow up his pulmonary nodule?

- PET CT 2 weeks
- PET CT 4 weeks
- Repeat chest x-ray 4 weeks
- Repeat CT chest 1 year
- Repeat CT chest 3 months

Submit answer

Reference ranges

Score: **24%**

1	✗
2	✗
3	✗
4	✗
5	✗
6	✗
7	✗
8	✗
9	✓
10	✓
11	✗
12	✗
13	✗
14	✓
15	✗
16	✓
17	✗
18	✗
19	✗
20	✗
21	✓
22	✓
23	✗
24	✗
25	✗
26	-
27	-
28	-
29	-
30	-

All contents of this site are © 2024 Passmedicine Limited

A 50-year-old man is admitted under the respiratory team with a left lower lobe pneumonia. He has a history of chronic obstructive pulmonary disease and continues to smoke. He also suffers with with hypertension and high cholesterol.

He is treated with steroids, nebulisers and antibiotics. After 5 days he continues to be hypoxic with saturations of 86% on air, ongoing left basal crepitations and wheeze.

A CT scan of the chest is performed which shows emphysematous changes and resolving left basal consolidation. There is also a 7mm lung nodule in the right upper lobe with surrounding ground glass change.

Over the next 3 days his saturations improve to 93% on air and his symptoms resolve. He is discharged home.

What imaging does he require to follow up his pulmonary nodule?

PET CT 2 weeks	7%
PET CT 4 weeks	6%
Repeat chest x-ray 4 weeks	7%
Repeat CT chest 1 year	12%
Repeat CT chest 3 months	68%

Risk stratification of incidental pulmonary nodules is complex and needs to take into account the risk factors for lung cancer or metastases, as well as size and character of the nodule. Algorithms for surveillance are well defined in the British Thoracic Society Guidelines published in 2005.

Broadly:

- Nodules < 5 mm require no further surveillance.
- Nodules 5-6mm require CT at 1 year
- Nodules 6-8 mm require CT at 3 months
- Nodules > 8 mm require malignancy risk calculation using the Brock model and should then have CT or PET according to whether this risk is > 10%.

The Brock model (see McWilliams et al) takes into account age, gender, family history and features of the nodule

References:

British Thoracic Society. BTS guidelines for pulmonary nodules. 2015.
McWilliams A, Tammemagi MC, Mayo JR, et al: Probability of cancer in pulmonary nodules detected on first screening CT. N Engl J Med 2013: 369; 910-9.

Discuss (5) Improve

Next question

Chest x-ray: coin lesions

Coin lesions

- malignant tumour: lung cancer or metastases
- benign tumour: hamartoma
- infection: pneumonia, abscess, TB, hydatid cyst
- AV malformation

AI + Q 123

Next question

Textbooks

High-yield textbook

Extended textbook

Links

British Institute of Radiology 1 0

Unofficial guide to radiology

British Thoracic Society 0 0

Guidelines for the Investigation and Management of Pulmonary Nodules

Suggest link Report broken link

Score: **20.4%**

1	✗
2	✗
3	✗
4	✗
5	✗
6	✗
7	✗
8	✗
9	✓
10	✓
11	✗
12	✗
13	✗
14	✓
15	✗
16	✓
17	✗
18	✗
19	✗
20	✗
21	✓

22	✓
23	✗
24	✗
25	✗
26	✗
27	✓
28	✗
29	✗
30	✓
31	✓
32	✗
33	✗
34	✗
35	✗
36	✗
37	✗
38	✗
39	✗
40	-
41	✗
42	✗
43	✗
44	✗
45	✓
46	✗
47	✗
48	✗
49	✗
50	✗
51	-

All contents of this site are © 2024 Passmedicine Limited

Back to top

A 51 year-old man is referred by her GP to the respiratory outpatient clinic. He has had several episodes of sinusitis over the past three years and is currently being referred to plastic surgery as the bridge of his nose has partially collapsed. A chest X-ray that was performed three weeks ago show five nodules and blood tests reveal a urea of 11.6 mmol/l and a creatinine of 198 µmol/l.

Which of the following is the most appropriate initial treatment for this condition?

- Methotrexate
- Cyclophosphamide
- Azathioprine
- Corticosteroids
- Cyclophosphamide and corticosteroids

Submit answer

Reference ranges

Score: **24%**

1	✕
2	✕
3	✕
4	✕
5	✕
6	✕
7	✕
8	✕

9	✓
10	✓
11	✗
12	✗
13	✗
14	✓
15	✗
16	✓
17	✗
18	✗
19	✗
20	✗
21	✓
22	✓
23	✗
24	✗
25	✗
26	-
27	-
28	-
29	-
30	-
31	-

All contents of this site are © 2024 Passmedicine Limited

Back to top

A 51 year-old man is referred by her GP to the respiratory outpatient clinic. He has had several episodes of sinusitis over the past three years and is currently being referred to plastic surgery as the bridge of his nose has partially collapsed. A chest X-ray that was performed three weeks ago show five nodules and blood tests reveal a urea of 11.6 mmol/l and a creatinine of 198 µmol/l.

Which of the following is the most appropriate initial treatment for this condition?

Methotrexate	1%
Cyclophosphamide	7%
Azathioprine	1%
Corticosteroids	25%
Cyclophosphamide and corticosteroids	67%

This man has a likely diagnosis of granulomatosis with polyangiitis, as suggested by the recurrent sinusitis, collapsed nasal bridge and x-ray nodules. First-line treatment is with cyclophosphamide and corticosteroids in patients with moderate to severe disease.

Discuss (5) | Improve

Next question >

Granulomatosis with polyangiitis

Granulomatosis with polyangiitis is now the preferred term for Wegener's granulomatosis. It is an autoimmune condition associated with a necrotizing granulomatous vasculitis, affecting both the upper and lower respiratory tract as well as the kidneys.

Features
- upper respiratory tract: epistaxis, sinusitis, nasal crusting
- lower respiratory tract: dyspnoea, haemoptysis
- rapidly progressive glomerulonephritis ('pauci-immune', 80% of patients)

- saddle-shape nose deformity
- also: vasculitic rash, eye involvement (e.g. proptosis), cranial nerve lesions

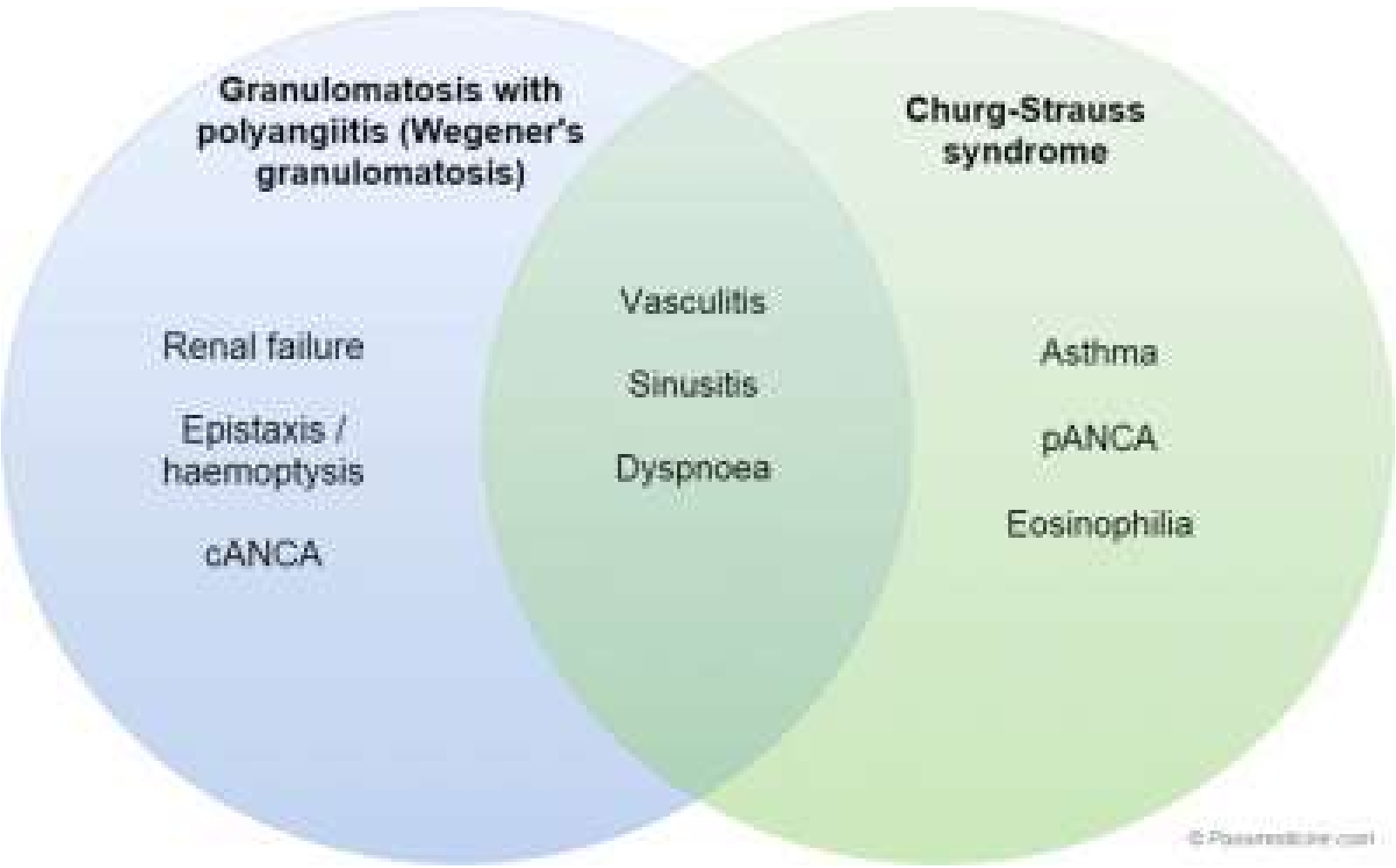

Comparison of granulomatosis with polyangiitis and Churg-Strauss syndrome

Investigations

- cANCA positive in > 90%, pANCA positive in 25%
- chest x-ray: wide variety of presentations, including cavitating lesions
- renal biopsy: epithelial crescents in Bowman's capsule

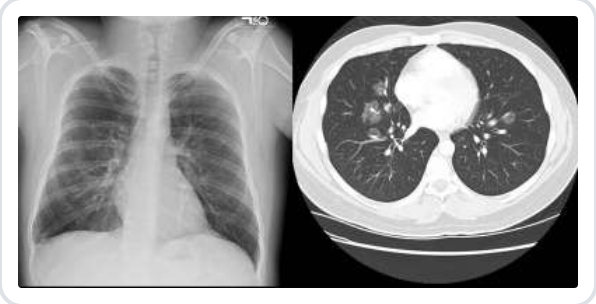
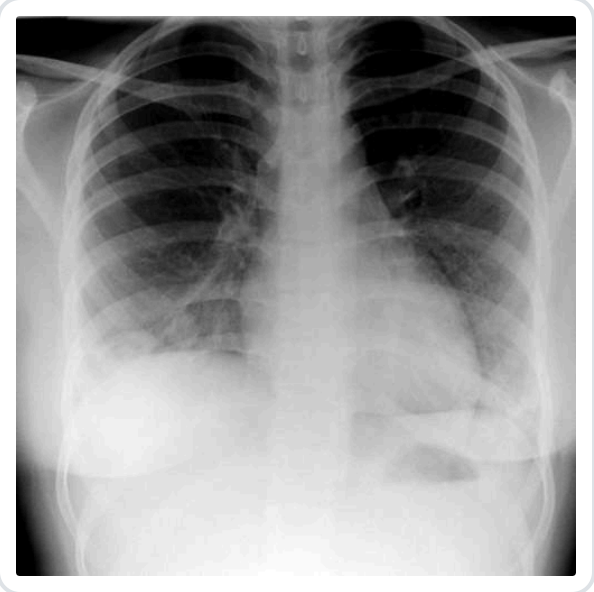
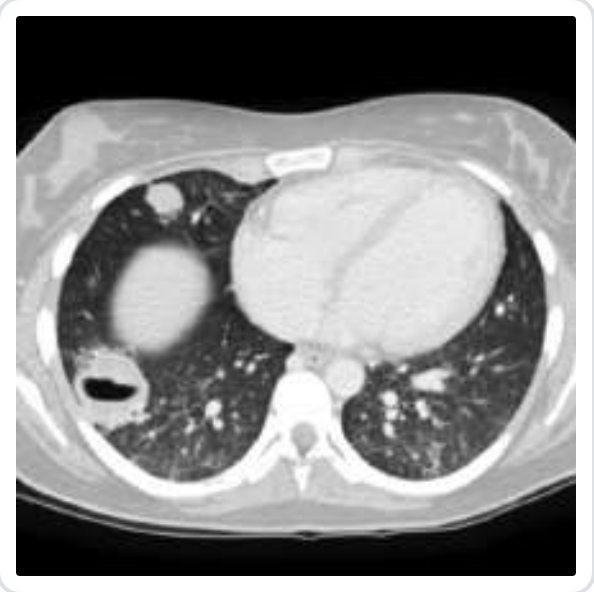

Management

- steroids
- cyclophosphamide (90% response)
- plasma exchange
- median survival = 8-9 years

AI + Q 123

Next question

Textbooks

High-yield textbook

Extended textbook

Media

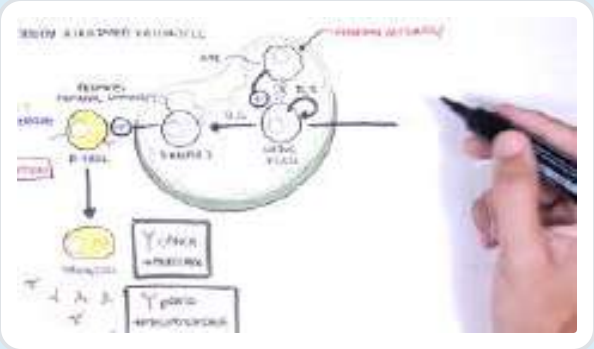

ANCA (Anti-Neutrophil Cytoplasmic Antibody) Associated Vasculitis - Causes, Pathophysiology, Types

Armando Hasudungan - YouTube 5 1

Granulomatosis with polyangiitis

Armando Hasudungan - YouTube 5 2

Report broken media

Score: **20.4%**

1 ✗
2 ✗
3 ✗

4	✗
5	✗
6	✗
7	✗
8	✗
9	✓
10	✓
11	✗
12	✗
13	✗
14	✓
15	✗
16	✓
17	✗
18	✗
19	✗
20	✗
21	✓
22	✓
23	✗
24	✗
25	✗
26	✗
27	✓
28	✗
29	✗
30	✓
31	✓
32	✗
33	✗
34	✗
35	✗
36	✗
37	✗
38	✗
39	✗

40	-
41	✗
42	✗
43	✗
44	✗
45	✓
46	✗
47	✗
48	✗
49	✗
50	✗
51	-

All contents of this site are © 2024 Passmedicine Limited

Back to top

An 88-year-old man presents with increasing shortness of breath over the past three months. He lives with his wife and is usually independent, but is recovering after an admission 6 months ago for pneumonia.

He has lost 10kg in weight compared to before the admission. He has not had any fevers or night sweats. His chest feels tight at times.

He feels short of breath with minimal exertion and this is not worse at any time of day. He has a constant dry cough. He takes ramipril for hypertension and has never smoked. He had tuberculosis as a child.

On examination, he is frail and has bilateral crepitations in the left mid and upper zones and right middle and lower zones. The chest is resonant to percussion and his respiratory rate is 24 breaths/min. His saturation are 92% at rest but on standing drop to 86% and his lips turn purple. He has a palpable heave and his ankles are both swollen.

B-natriuretic peptide	upper limit of normal
CRP	13
FEV1 (% predicted)	87%
FVC (% predicted)	75%
ECG	right bundle branch block, sinus, rate 70/min
Chest X-Ray	reticular shadows bilaterally with reduced chest expansion

ABG in air	
pH	7.35
PaO2	7.9 kPa
PaCO2	6.8 kPa
HCO3	28 mmol/l

What is the most likely diagnosis?

- Tuberculosis reactivation
- Asthma

- Pulmonary fibrosis
- Congestive cardiac failure
- Physiological ageing

Submit answer

Reference ranges

Score: **24%**

1	✗
2	✗
3	✗
4	✗
5	✗
6	✗
7	✗
8	✗
9	✓
10	✓
11	✗
12	✗
13	✗
14	✓
15	✗
16	✓
17	✗
18	✗
19	✗
20	✗
21	✓

22 ✓
23 ✗
24 ✗
25 ✗
26 -
27 -
28 -
29 -
30 -
31 -
32 -

All contents of this site are © 2024 Passmedicine Limited

Back to top

An 88-year-old man presents with increasing shortness of breath over the past three months. He lives with his wife and is usually independent, but is recovering after an admission 6 months ago for pneumonia.

He has lost 10kg in weight compared to before the admission. He has not had any fevers or night sweats. His chest feels tight at times.

He feels short of breath with minimal exertion and this is not worse at any time of day. He has a constant dry cough. He takes ramipril for hypertension and has never smoked. He had tuberculosis as a child.

On examination, he is frail and has bilateral crepitations in the left mid and upper zones and right middle and lower zones. The chest is resonant to percussion and his respiratory rate is 24 breaths/min. His saturation are 92% at rest but on standing drop to 86% and his lips turn purple. He has a palpable heave and his ankles are both swollen.

B-natriuretic peptide	upper limit of normal
CRP	13
FEV1 (% predicted)	87%
FVC (% predicted)	75%
ECG	right bundle branch block, sinus, rate 70/min
Chest X-Ray	reticular shadows bilaterally with reduced chest expansion

ABG in air	
pH	7.35
PaO2	7.9 kPa
PaCO2	6.8 kPa
HCO3	28 mmol/l

What is the most likely diagnosis?

- Tuberculosis reactivation 7%
- Asthma 1%

Pulmonary fibrosis 75%

Congestive cardiac failure 15%

Physiological ageing 3%

Pulmonary fibrosis can occur following pneumonia

Important for me Less important

This gentleman has a compensated respiratory acidosis with hypoxia which suggests that he has been ill for at least a few weeks. He also has a restrictive picture on his lung function tests with a relatively preserved FEV1. These changes are abnormal and do not reflect ageing.

He has no sputum and no systemic features making TB unlikely.

He has no wheeze. Asthma would also have obstructive lung function tests.

His BNP is not supportive of cardiac failure.

Discuss (10) Improve

Next question

Lung fibrosis

It is important in the exam to be able to differentiate between conditions causing predominately upper or lower zone fibrosis. It should be noted that the more common causes (idiopathic pulmonary fibrosis, drugs) tend to affect the lower zones

Fibrosis predominately affecting the upper zones

- hypersensitivity pneumonitis (also known as extrinsic allergic alveolitis)
- coal worker's pneumoconiosis/progressive massive fibrosis
- silicosis
- sarcoidosis
- ankylosing spondylitis (rare)
- histiocytosis
- tuberculosis
- radiation-induced pulmonary fibrosis
    - may develop following radiotherapy for breast or lung cancer

- typically seen between 6 and 12 months following completion of radiotherapy course

Fibrosis predominately affecting the lower zones

- idiopathic pulmonary fibrosis
- most connective tissue disorders (except ankylosing spondylitis) e.g. SLE
- drug-induced: amiodarone, bleomycin, methotrexate
- asbestosis

Acronym for causes of upper zone fibrosis:

CHARTS

- C - Coal worker's pneumoconiosis
- H - Histiocytosis/ hypersensitivity pneumonitis
- A - Ankylosing spondylitis
- R - Radiation
- T - Tuberculosis
- S - Silicosis/sarcoidosis

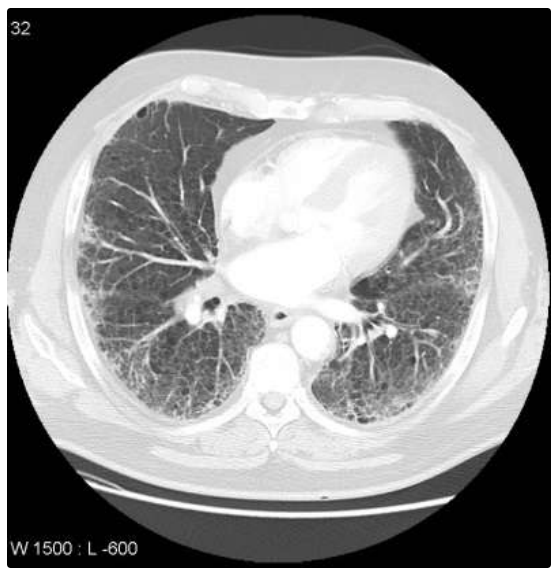

AI + Q 123

Next question >

Textbooks

High-yield textbook

Extended textbook

Media

[Interstitial Lung Disease (ILD) - Classification, pathophysiology, signs and symptoms]

Armando Hasudungan - YouTube 👍 1 👎 0

Report broken media

Score: **20.4%**

1 ✗
2 ✗
3 ✗
4 ✗
5 ✗
6 ✗
7 ✗
8 ✗
9 ✓
10 ✓
11 ✗
12 ✗
13 ✗
14 ✓
15 ✗

16	✓
17	✗
18	✗
19	✗
20	✗
21	✓
22	✓
23	✗
24	✗
25	✗
26	✗
27	✓
28	✗
29	✗
30	✓
31	✓
32	✗
33	✗
34	✗
35	✗
36	✗
37	✗
38	✗
39	✗
40	-
41	✗
42	✗
43	✗
44	✗
45	✓
46	✗
47	✗
48	✗
49	✗
50	✗
51	-

All contents of this site are © 2024 Passmedicine Limited

A 70-year-old woman presents to her GP with increasing shortness of breath over the last 4 months. She also reports an occasional productive cough. Her past medical history includes two previous heart attacks, both treated with percutaneous coronary intervention and hypercholesterolaemia that is treated with simvastatin. She has a 35 pack-year history and does not drink alcohol.

The GP refers her for lung function tests which reveal:

Forced expiratory volume in 1 second (FEV1)	0.78L
Forced vital capacity (FVC)	1.68L
Total lung capacity	5.08L

What is the most likely diagnosis?

- Chronic obstructive pulmonary disease (COPD)
- Congestive cardiac failure
- Pulmonary embolism
- Bronchiectasis
- Asthma

Submit answer

Reference ranges

2	✗
3	✗
4	✗
5	✗
6	✗
7	✗
8	✗
9	✓
10	✓
11	✗
12	✗
13	✗
14	✓
15	✗
16	✓
17	✗
18	✗
19	✗
20	✗
21	✓
22	✓
23	✗
24	✗
25	✗
26	-
27	-
28	-
29	-
30	-
31	-
32	-
33	-

All contents of this site are © 2024 Passmedicine Limited

Back to top

A 70-year-old woman presents to her GP with increasing shortness of breath over the last 4 months. She also reports an occasional productive cough. Her past medical history includes two previous heart attacks, both treated with percutaneous coronary intervention and hypercholesterolaemia that is treated with simvastatin. She has a 35 pack-year history and does not drink alcohol.

The GP refers her for lung function tests which reveal:

Forced expiratory volume in 1 second (FEV1)	0.78L
Forced vital capacity (FVC)	1.68L
Total lung capacity	5.08L

What is the most likely diagnosis?

- Chronic obstructive pulmonary disease (COPD) 78%
- Congestive cardiac failure 8%
- Pulmonary embolism 2%
- Bronchiectasis 10%
- Asthma 1%

The most likely diagnosis in this case is COPD, based on the reduced FEV1 and and FEV1/FVC. The high pack-year history and the patient's age also points towards a diagnosis of COPD, as opposed to asthma.

Discuss (9) Improve

Next question

Pulmonary function tests

Pulmonary function tests can be used to determine whether a respiratory disease is obstructive or restrictive. The table below summarises the main findings and gives some example conditions:

Obstructive lung disease	Restrictive lung disease
FEV1 - significantly reduced FVC - reduced or normal FEV1% (FEV1/FVC) - reduced	FEV1 - reduced FVC - significantly reduced FEV1% (FEV1/FVC) - normal or increased
Asthma COPD Bronchiectasis Bronchiolitis obliterans	Pulmonary fibrosis Asbestosis Sarcoidosis Acute respiratory distress syndrome Infant respiratory distress syndrome Kyphoscoliosis e.g. ankylosing spondylitis Neuromuscular disorders Severe obesity

AI + Q 123

Next question >

Textbooks

High-yield textbook

Extended textbook

Media

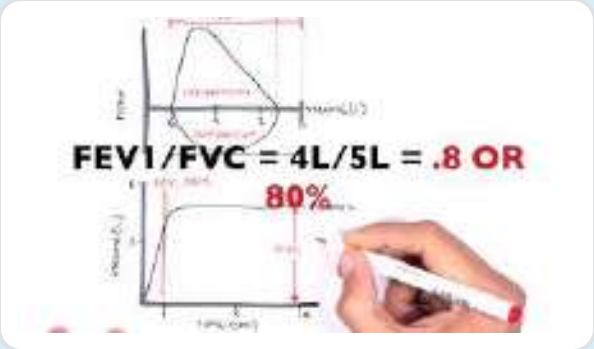

[Understanding Spirometry - Normal, Obstructive vs Restrictive]

Armando Hasudungan - YouTube 17 0

Restrictive lung disease

Osmosis - YouTube 4 0

Peak Flow and Spirometry - Lung Function Tests

Oxford Medical Education - YouTube 4 0

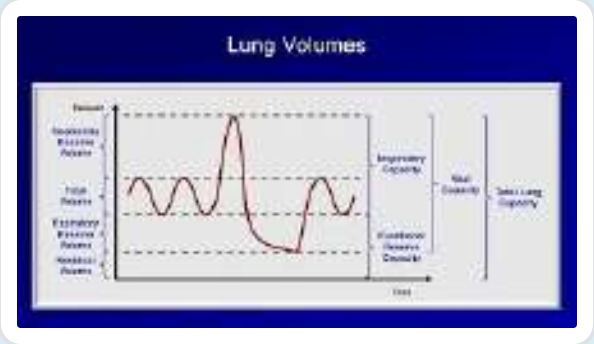

Pulmonary Function Tests

Strong Medicine - YouTube 4 0

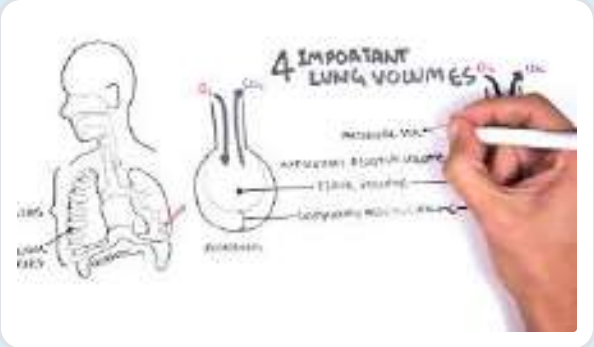

Lung Function - Lung Volumes and Capacities

Armando Hasudungan - YouTube 3 0

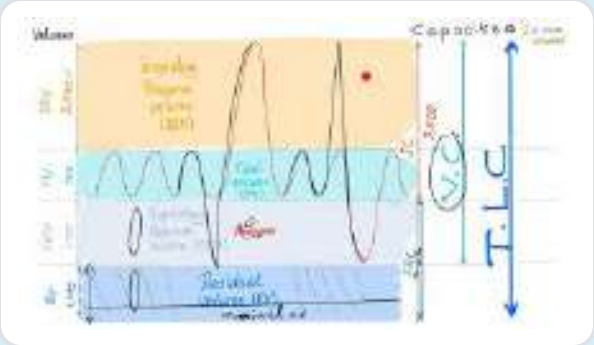

Pulmonary Function Tests (PFTs) Made Simple

Medicosis Perfectionalis - YouTube 4 1

Report broken media

Score: **20.4%**

1	✗
2	✗
3	✗
4	✗
5	✗
6	✗
7	✗
8	✗
9	✓
10	✓
11	✗
12	✗
13	✗
14	✓
15	✗
16	✓
17	✗
18	✗
19	✗
20	✗
21	✓
22	✓
23	✗
24	✗
25	✗
26	✗
27	✓

28	✗
29	✗
30	✓
31	✓
32	✗
33	✗
34	✗
35	✗
36	✗
37	✗
38	✗
39	✗
40	-
41	✗
42	✗
43	✗
44	✗
45	✓
46	✗
47	✗
48	✗
49	✗
50	✗
51	-

All contents of this site are © 2024 Passmedicine Limited

A 24-year-old woman is admitted to Accident and Emergency with acute shortness of breath. She is unable to detail a clinical history due to shortness of breath. Her medication includes;

Cetirizine 10mg Orally Once Daily
Clobetasone butyrate (Eumovate) Topical

Her initial examination revealed bilateral widespread polyphonic wheezes. Her pulse rate was 102 beats per minute and blood pressure 128/75 mmHg. Her respiration rate was 33. Her oxygen saturations were 96% on 4L/min via face mask. She had a dry flaking rash in her elbow flexures with signs of excoriation.

The following blood tests were obtained;

Hb	11.2 g/dl
Platelets	204*10^9/l
WBC	10.3 *10^9/l
Eosinophil	0.56 *10^9/l
CRP	65
Na+	135 mmol/l
K+	4.4 mmol/l
Urea	7.6 mmol/l
Creatinine	101 µmol/l

Chest x-ray was clear. A peak expiratory flow was 200 L/min(expected 402).

Initial arterial blood gas on 4L/min oxygen via face mask;

pH	7.46
pCO2	3.5 kPa
pO2	14 kPa
HCO3	19 mmol/l
Lactate	1.8 mmol/l

She is treated with nebulised salbutamol and ipratropium bromide and oral prednisolone 40mg

and oxygen 4L/min.

You re-review the patient 30 minutes later on the Admissions Unit. Her examination reveals symmetrical quiet breath sounds and quiet bilateral wheezes. She has symmetrical chest wall movement. Her pulse rate is 80 beats per minute. Blood pressure 103/68 mmHg. Her respiratory was 18 with oxygen saturations 94% on 6L/min via face mask. Peak expiratory flow was 120 L/min.

Repeat arterial blood gas on 6L/min oxygen via face mask;

pH	7.33
pCO2	6.2kPa
pO2	13kPa
HCO3	20 mmol/l
Lactate	2.2 mmol/l

What is the most appropriate next step in management?

- Intravenous Magnesium
- Reduce oxygen levels
- Intravenous Salbutamol
- Referral to intensive care
- Biphasic positive airway pressure

Submit answer

Reference ranges

Score: **24%**

1 ✕
2 ✕

3	✗
4	✗
5	✗
6	✗
7	✗
8	✗
9	✓
10	✓
11	✗
12	✗
13	✗
14	✓
15	✗
16	✓
17	✗
18	✗
19	✗
20	✗
21	✓
22	✓
23	✗
24	✗
25	✗
26	-
27	-
28	-
29	-
30	-
31	-
32	-
33	-
34	-

All contents of this site are © 2024 Passmedicine Limited

Back to top

A 24-year-old woman is admitted to Accident and Emergency with acute shortness of breath. She is unable to detail a clinical history due to shortness of breath. Her medication includes;

Cetirizine 10mg Orally Once Daily
Clobetasone butyrate (Eumovate) Topical

Her initial examination revealed bilateral widespread polyphonic wheezes. Her pulse rate was 102 beats per minute and blood pressure 128/75 mmHg. Her respiration rate was 33. Her oxygen saturations were 96% on 4L/min via face mask. She had a dry flaking rash in her elbow flexures with signs of excoriation.

The following blood tests were obtained;

Hb	11.2 g/dl
Platelets	204*10^9/l
WBC	10.3 *10^9/l
Eosinophil	0.56 *10^9/l
CRP	65
Na+	135 mmol/l
K+	4.4 mmol/l
Urea	7.6 mmol/l
Creatinine	101 µmol/l

Chest x-ray was clear. A peak expiratory flow was 200 L/min(expected 402).

Initial arterial blood gas on 4L/min oxygen via face mask;

pH	7.46
pCO2	3.5 kPa
pO2	14 kPa
HCO3	19 mmol/l
Lactate	1.8 mmol/l

She is treated with nebulised salbutamol and ipratropium bromide and oral prednisolone 40mg

and oxygen 4L/min.

You re-review the patient 30 minutes later on the Admissions Unit. Her examination reveals symmetrical quiet breath sounds and quiet bilateral wheezes. She has symmetrical chest wall movement. Her pulse rate is 80 beats per minute. Blood pressure 103/68 mmHg. Her respiratory was 18 with oxygen saturations 94% on 6L/min via face mask. Peak expiratory flow was 120 L/min.

Repeat arterial blood gas on 6L/min oxygen via face mask;

pH	7.33
pCO2	6.2kPa
pO2	13kPa
HCO3	20 mmol/l
Lactate	2.2 mmol/l

What is the most appropriate next step in management?

- Intravenous Magnesium 12%
- Reduce oxygen levels 3%
- Intravenous Salbutamol 1%
- Referral to intensive care 77%
- Biphasic positive airway pressure 7%

According to British Guideline on Management of Asthma BTS/SIGN 2011.

This patient had acute severe asthma as highlighted by her first set of results and examination.

Acute Severe

- PEF 33-50% best or predicted
- RR >25, HR >110
- Inability to complete sentences

Her ABG was consistent with type one respiratory failure with hypocapnia due to hyperventilation.

Her condition deteriorated to life threatening with raised PaCO2 suggesting of near fatal asthma

Life Threatening

- PEF <33%
- SpO2 <92% or PaO2 <8kPa
- Normal PaCO2
- Silent chest, cyanosis, poor respiratory effort, arrhythmia, exhaustion

Near Fatal

- Raised PaCO2
- Requiring mechanical ventilaion with raised inflation pressures

The patient had a deteriorating picture. Her respiratory rate was decreasing suggesting exhaustion, worsening hypoxia, hypercapnic acidotic ABG, deteriorating PEF indicating deterioration.

Intravenous Magnesium - This patient would certainly require consideration of IV Magnesium however as the picture is deteriorating they would require ITU referral immediately.

Reduce oxygen levels - Incorrect. Retention of CO2 is not secondary to her oxygen therapy, it is more likely due to exhaustion.

Intravenous Salbutamol - Not utilised in current guidance.

Referral to intensive care - Correct answer. The patient has near fatal asthma with deterioration despite nebulisers and steroids.

Biphasic positive airway pressure - No evidence to support NIV use in acute asthma.

Discuss (10) Improve

Next question

Acute asthma: management

The British Thoracic Society (BTS) classify patients with acute asthma into moderate, severe or life-threatening categories.

Moderate	Severe	Life-threatening
PEFR 50-75% best or predicted Speech normal RR < 25 / min Pulse < 110 bpm	PEFR 33 - 50% best or predicted Can't complete sentences RR > 25/min Pulse > 110 bpm	PEFR < 33% best or predicted Oxygen sats < 92% 'Normal' $pC0_2$ (4.6-6.0 kPa) Silent chest, cyanosis or feeble respiratory effort Bradycardia, dysrhythmia or hypotension Exhaustion, confusion or coma

Note that a patient having any one of the life-threatening features should be treated as having a life-threatening attack.

A fourth category, '**Near-fatal asthma**', is also recognised characterised by a raised $pC0_2$ and/or requiring mechanical ventilation with raised inflation pressures.

Further assessment

- the BTS guidelines recommend arterial blood gases for patients with oxygen sats < 92%
- a chest x-ray is not routinely recommended, unless:
  - life-threatening asthma
  - suspected pneumothorax
  - failure to respond to treatment

Management

- admission
  - all patients with life-threatening should be admitted in hospital
  - patients with features of severe acute asthma should also be admitted if they fail to respond to initial treatment.
  - other admission criteria include a previous near-fatal asthma attack, pregnancy, an attack occurring despite already using oral corticosteroid and presentation at night
- oxygen
  - if patients are hypoxaemic, it is important to start them on supplemental oxygen therapy
  - if patients are acutely unwell they should be started on 15L of supplemental via a non-rebreathe mask, which can then be titrated down to a flow rate where they are able to maintain a SpO,, 94-98%.
- bronchodilation with short-acting beta,,-agonists (SABA)
  - high-dose inhaled SABA e.g. salbutamol, terbutaline
  - in patients without features of life-threatening or near-fatal asthma, this can be given by a standard pressurised metered-dose inhaler (pMDI) or by an oxygen-driven nebulizer
  - in patients with features of a life-threatening exacerbation of asthma, nebulised SABA is recommended

- corticosteroid
  - all patients should be given 40-50mg of prednisolone orally (PO) daily, which should be continued for at least five days or until the patient recovers from the attack
  - during this time, patients should continue their normal medication routine including inhaled corticosteroids.
- ipratropium bromide: in patients with severe or life-threatening asthma, or in patients who have not responded to beta,,-agonist and corticosteroid treatment, nebulised ipratropium bromide, a short-acting muscarinic antagonist
- IV magnesium sulphate
  - the BTS notes that the evidence base is mixed for this treatment that is now commonly given for severe/life-threatening asthma
- IV aminophylline may be considered following consultation with senior medical staff
- patients who fail to respond require senior critical care support and should be treated in an appropriate ITU/HDU setting. Treatment options include:
  - intubation and ventilation
  - extracorporeal membrane oxygenation (ECMO)

Criteria for discharge

- been stable on their discharge medication (i.e. no nebulisers or oxygen) for 12-24 hours
- inhaler technique checked and recorded
- PEF >75% of best or predicted

+ Q 123

Next question >

Textbooks

High-yield textbook

Extended textbook

Links

British Thoracic Society

2019 Asthma guidelines

44 73

Suggest link

Report broken link

Score: **20.4%**

1	✗
2	✗
3	✗
4	✗
5	✗
6	✗
7	✗
8	✗
9	✓
10	✓
11	✗
12	✗
13	✗
14	✓
15	✗
16	✓
17	✗
18	✗
19	✗
20	✗
21	✓
22	✓
23	✗
24	✗
25	✗
26	✗

27	✓
28	✗
29	✗
30	✓
31	✓
32	✗
33	✗
34	✗
35	✗
36	✗
37	✗
38	✗
39	✗
40	-
41	✗
42	✗
43	✗
44	✗
45	✓
46	✗
47	✗
48	✗
49	✗
50	✗
51	-

All contents of this site are © 2024 Passmedicine Limited

A 27-year-old woman presents for review to the respiratory clinic. She has a past medical history of cystic fibrosis and has been struggling at home. Her GP sent a sputum sample prior to her clinic appointment as he was concerned with the worsening nature of her cough and shortness of breath. Which microorganism is associated with the worst prognosis?

- Burkholderia
- Klebsiella pneumoniae
- Pseudomonas aeruginosa
- Staphylococcus aureus
- Haemophilus influenzae

Submit answer

Reference ranges

Score: **24%**

1 ✕
2 ✕
3 ✕
4 ✕
5 ✕
6 ✕
7 ✕
8 ✕

9	✓
10	✓
11	✗
12	✗
13	✗
14	✓
15	✗
16	✓
17	✗
18	✗
19	✗
20	✗
21	✓
22	✓
23	✗
24	✗
25	✗
26	-
27	-
28	-
29	-
30	-
31	-
32	-
33	-
34	-
35	-

All contents of this site are © 2024 Passmedicine Limited

A 27-year-old woman presents for review to the respiratory clinic. She has a past medical history of cystic fibrosis and has been struggling at home. Her GP sent a sputum sample prior to her clinic appointment as he was concerned with the worsening nature of her cough and shortness of breath. Which microorganism is associated with the worst prognosis?

Burkholderia	70%
Klebsiella pneumoniae	2%
Pseudomonas aeruginosa	24%
Staphylococcus aureus	2%
Haemophilus influenzae	2%

The correct answer is Burkholderia. All of the pathogens listed are potential pathogens which commonly cause exacerbation of cystic fibrosis, but Burkholderia and Pseudomonas are two pathogens which are very difficult to eradicate. Of those, Burkholderia has the worst prognosis.

Discuss (2) Improve

Next question

Cystic fibrosis: management

Management of cystic fibrosis (CF) involves a multidisciplinary approach

Key points

- regular (at least twice daily) chest physiotherapy and postural drainage. Parents are usually taught to do this. Deep breathing exercises are also useful
- high calorie diet, including high fat intake*

- patients with CF should try to minimise contact with each other to prevent cross infection with *Burkholderia cepacia* complex and *Pseudomonas aeruginosa*
- vitamin supplementation
- pancreatic enzyme supplements taken with meals
- lung transplantation
  - chronic infection with *Burkholderia cepacia* is an important CF-specific contraindication to lung transplantation

Lumacaftor/Ivacaftor (Orkambi)

- is used to treat cystic fibrosis patients who are homozygous for the delta F508 mutation
- lumacaftor increases the number of CFTR proteins that are transported to the cell surface
- ivacaftor is a potentiator of CFTR that is already at the cell surface, increasing the probability that the defective channel will be open and allow chloride ions to pass through the channel pore

*this is now the standard recommendation - previously high calorie, low-fat diets have been recommended to reduce the amount of steatorrhoea

AI + Q 123

Next question >

Textbooks

High-yield textbook

Extended textbook

Links

Cystic Fibrosis Trust 6 6

Nutrition for adults

NICE

2017 Cystic fibrosis: diagnosis and management

9 4

Suggest link

Report broken link

Media

Cystic fibrosis

Osmosis - YouTube 6 0

Cystic fibrosis: pathology review

Osmosis - YouTube 2 0

Report broken media

Score: **20.4%**

1 ✗
2 ✗
3 ✗
4 ✗
5 ✗
6 ✗
7 ✗
8 ✗
9 ✓

10	✓
11	✗
12	✗
13	✗
14	✓
15	✗
16	✓
17	✗
18	✗
19	✗
20	✗
21	✓
22	✓
23	✗
24	✗
25	✗
26	✗
27	✓
28	✗
29	✗
30	✓
31	✓
32	✗
33	✗
34	✗
35	✗
36	✗
37	✗
38	✗
39	✗
40	-
41	✗
42	✗
43	✗
44	✗
45	✓

46	✕
47	✕
48	✕
49	✕
50	✕
51	-

All contents of this site are © 2024 Passmedicine Limited

An 80-year-old woman presents with dyspnoea to the Emergency Department. According to her daughter she has been getting progressively worse over the past 4 weeks. Her past medical history includes a myocardial infarction 20 years ago following which she had a 'pacemaker' inserted. She still smokes 20 cigarettes/day.

On examination her pulse is 120/min irregularly irregular. Blood pressure is 102/72 mmHg, oxygen saturations are 94% on 40% oxygen via a Venturi mask.

Her chest x-ray is shown below:

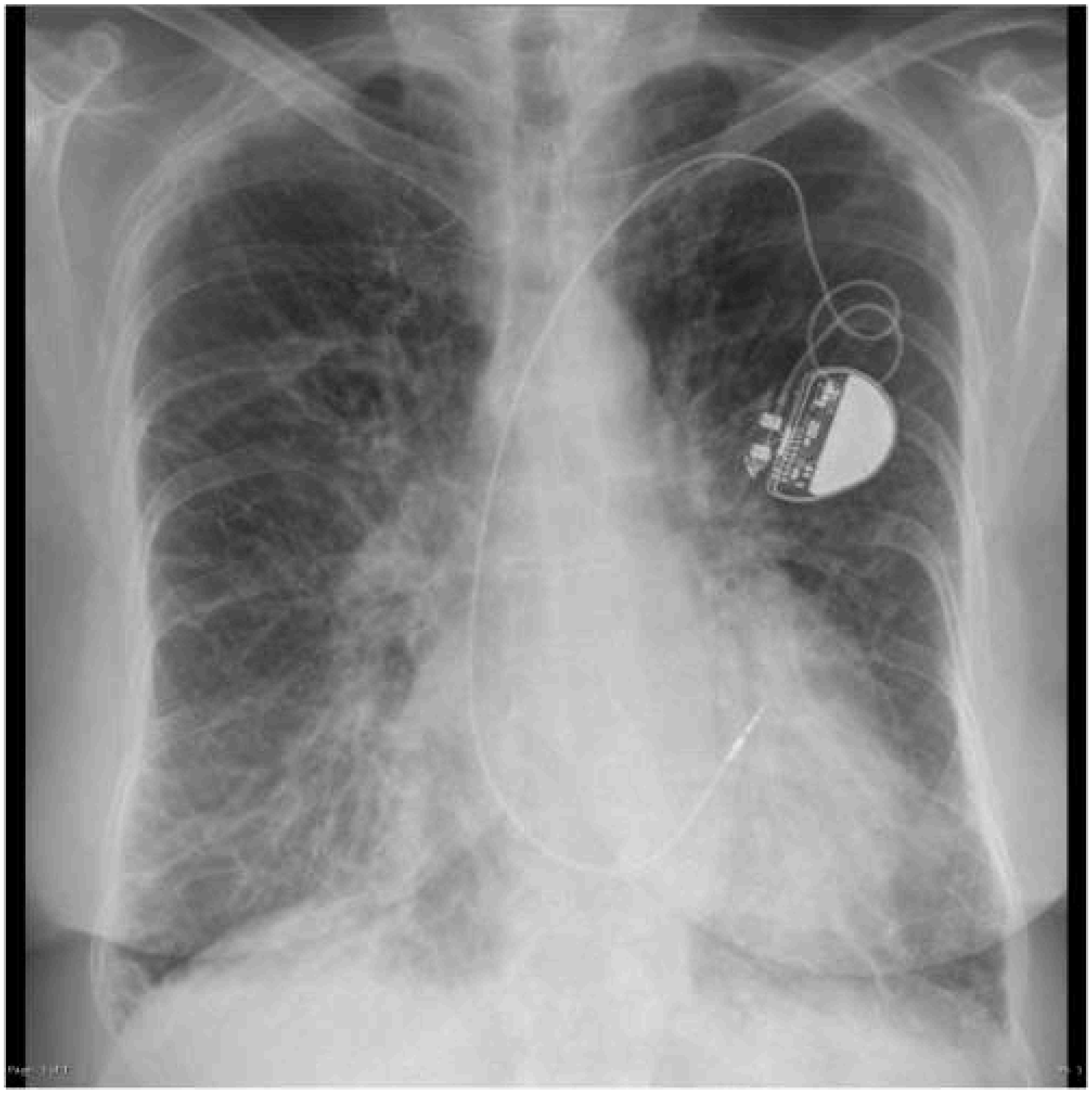

© Image used on license from Radiopaedia

What is the most appropriate initial treatment?

- Oral beta-blocker

- ◯ Low-molecular weight heparin ×
- ◯ Intravenous loop diuretic ×
- ◯ Reduce oxygen to 24% and nebulised bronchodilator ×
- ◯ Intravenous broad-spectrum antibiotic ×

Submit answer

Reference ranges ﹀

Score: **24%**

1	✗
2	✗
3	✗
4	✗
5	✗
6	✗
7	✗
8	✗
9	✓
10	✓
11	✗
12	✗
13	✗
14	✓
15	✗
16	✓
17	✗
18	✗
19	✗

20	✗
21	✓
22	✓
23	✗
24	✗
25	✗
26	-
27	-
28	-
29	-
30	-
31	-
32	-
33	-
34	-
35	-
36	-

All contents of this site are © 2024 Passmedicine Limited

Back to top

An 80-year-old woman presents with dyspnoea to the Emergency Department. According to her daughter she has been getting progressively worse over the past 4 weeks. Her past medical history includes a myocardial infarction 20 years ago following which she had a 'pacemaker' inserted. She still smokes 20 cigarettes/day.

On examination her pulse is 120/min irregularly irregular. Blood pressure is 102/72 mmHg, oxygen saturations are 94% on 40% oxygen via a Venturi mask.

Her chest x-ray is shown below:

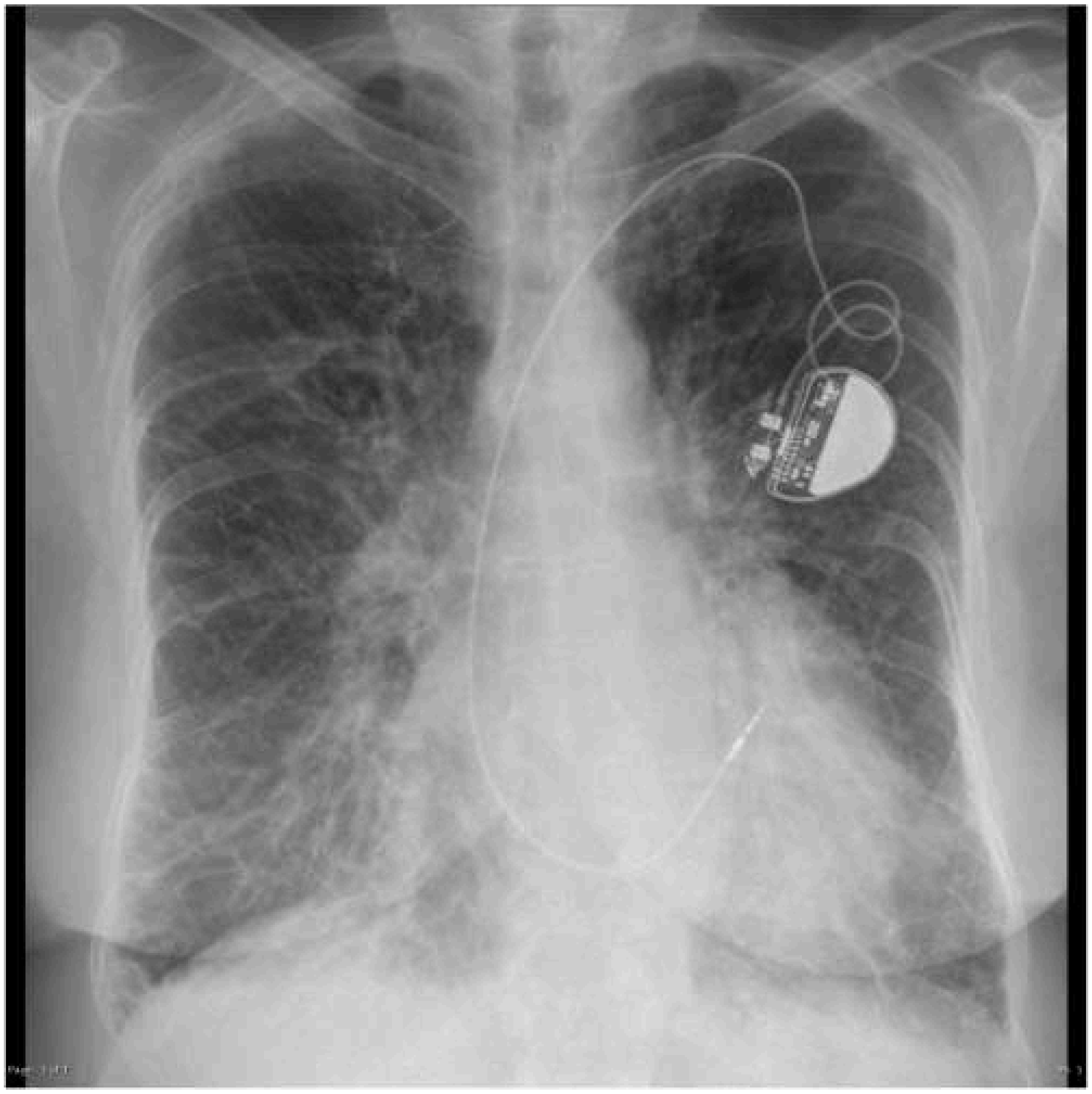

© Image used on license from Radiopaedia

What is the most appropriate initial treatment?

- Oral beta-blocker 6%

Low-molecular weight heparin 4%

Intravenous loop diuretic 60%

Reduce oxygen to 24% and nebulised bronchodilator 19%

Intravenous broad-spectrum antibiotic 11%

The chest x-ray is consistent with acute pulmonary oedema. Single lead PPM in situ. The heart is enlarged and there is marked prominence of the interstitial lines. Minimal blunting of the left costophrenic angle.

Discuss (13) Improve

Next question

Chest x-ray: pulmonary oedema

Features of pulmonary oedema on a chest x-ray may include:

- interstitial oedema
- bat's wing appearance
- upper lobe diversion (increased blood flow to the superior parts of the lung)
- Kerley B lines
- pleural effusion
- cardiomegaly may be seen if there is cardiogenic cause

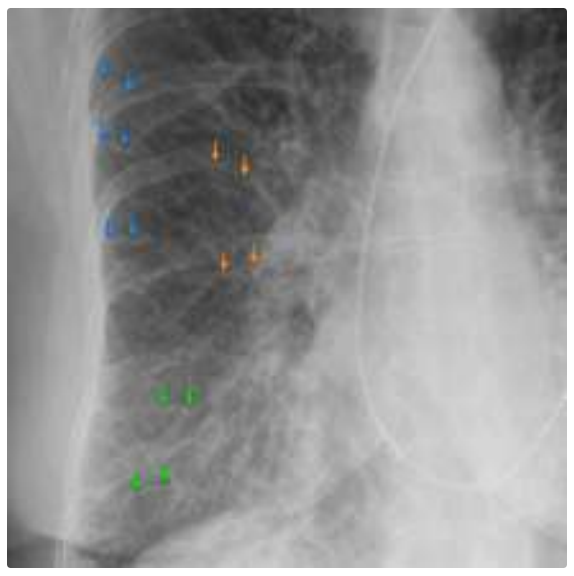

123

Next question

Textbooks

High-yield textbook

Extended textbook

Links

Radiology Masterclass 3 2

Cardiomegaly and heart failure

British Institute of Radiology 1 1

Unofficial guide to radiology

Suggest link Report broken link

Media

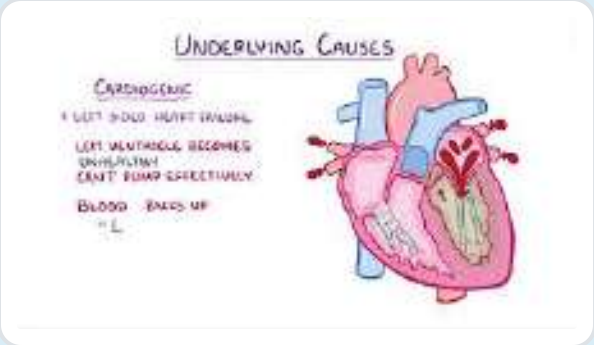

Pulmonary oedema

Osmosis - YouTube 2 0

Report broken media

Score: **20.4%**

1	✗
2	✗
3	✗
4	✗
5	✗
6	✗
7	✗
8	✗
9	✓
10	✓
11	✗
12	✗
13	✗
14	✓
15	✗
16	✓
17	✗
18	✗
19	✗
20	✗
21	✓
22	✓
23	✗
24	✗
25	✗
26	✗
27	✓
28	✗
29	✗
30	✓
31	✓
32	✗
33	✗
34	✗
35	✗

36	✗
37	✗
38	✗
39	✗
40	-
41	✗
42	✗
43	✗
44	✗
45	✓
46	✗
47	✗
48	✗
49	✗
50	✗
51	-

All contents of this site are © 2024 Passmedicine Limited
Back to top

You are caring for 54 year-old lady on the respiratory ward. She has community acquired pneumonia and large left sided pleural effusion. She is dyspnoeic at rest and hypoxic - oxygen saturations are 96% on 60% high flow oxygen.

A bedside ultrasound scan shows an anechoic effusion with no apparent loculations. You proceed to perform a diagnostic aspirate and the results are as follows:

pH	6.9
Glucose	2.9mmol/L
Protein	32g/dL
Gram stain	No organisms seen

What is the correct course of action?

- 18Fr chest drain and intravenous antibiotics
- Therapeutic aspiration and intravenous antibiotics
- Referral to thoracic surgeons
- Broad spectrum intravenous antibiotics
- 18Fr chest drain, intravenous antibiotics and intrapleural fibrinolysis

Submit answer

Reference ranges

Score: **24%**

1 ×

2	✗
3	✗
4	✗
5	✗
6	✗
7	✗
8	✗
9	✓
10	✓
11	✗
12	✗
13	✗
14	✓
15	✗
16	✓
17	✗
18	✗
19	✗
20	✗
21	✓
22	✓
23	✗
24	✗
25	✗
26	-
27	-
28	-
29	-
30	-
31	-
32	-
33	-
34	-
35	-
36	-
37	-

All contents of this site are © 2024 Passmedicine Limited

You are caring for 54 year-old lady on the respiratory ward. She has community acquired pneumonia and large left sided pleural effusion. She is dyspnoeic at rest and hypoxic - oxygen saturations are 96% on 60% high flow oxygen.

A bedside ultrasound scan shows an anechoic effusion with no apparent loculations. You proceed to perform a diagnostic aspirate and the results are as follows:

pH	6.9
Glucose	2.9mmol/L
Protein	32g/dL
Gram stain	No organisms seen

What is the correct course of action?

- 18Fr chest drain and intravenous antibiotics 75%
- Therapeutic aspiration and intravenous antibiotics 10%
- Referral to thoracic surgeons 4%
- Broad spectrum intravenous antibiotics 3%
- 18Fr chest drain, intravenous antibiotics and intrapleural fibrinolysis 8%

Although the ultrasound appearances in this case are suggestive of a simple parapneumonic effusion the aspirate results suggest an empyema. Empyema must be treated promptly and aggressively with broad spectrum antibiotics and drainage*. Intra-pleural fibrinolysis is useful in loculated effusions and thoracic surgery should be considered if initial management fails.

*BTS pleural diseases guidelines 2010: Management of pleural infection in adults

Discuss (13) Improve

Next question

Pleural effusion: investigation and management

The British Thoracic Society (BTS) produced guidelines in 2010 covering the investigation of patients with a pleural effusion.

Imaging

- posterioranterior (PA) chest x-rays should be performed in all patients
- ultrasound is recommended: it increases the likelihood of successful pleural aspiration and is sensitive for detecting pleural fluid septations
- contrast CT is now increasingly performed to investigate the underlying cause, particularly for exudative effusions

Pleural aspiration

- as above, ultrasound is recommended to reduce the complication rate
- a 21G needle and 50ml syringe should be used
- fluid should be sent for pH, protein, lactate dehydrogenase (LDH), cytology and microbiology

Light's criteria was developed in 1972 to help distinguish between a transudate and an exudate. The BTS recommend using the criteria for borderline cases:

- exudates have a protein level of >30 g/L, transudates have a protein level of <30 g/L
- if the protein level is between 25-35 g/L, Light's criteria should be applied. An exudate is likely if at least one of the following criteria are met:
  - pleural fluid protein divided by serum protein >0.5
  - pleural fluid LDH divided by serum LDH >0.6
  - pleural fluid LDH more than two-thirds the upper limits of normal serum LDH

Other characteristic pleural fluid findings:

- low glucose: rheumatoid arthritis, tuberculosis
- raised amylase: pancreatitis, oesophageal perforation
- heavy blood staining: mesothelioma, pulmonary embolism, tuberculosis

Pleural infection

All patients with a pleural effusion in association with sepsis or a pneumonic illness require diagnostic pleural fluid sampling

- if the fluid is purulent or turbid/cloudy a chest tube should be placed to allow drainage
- if the fluid is clear but the **pH is less than 7.2 in patients with suspected pleural infection a chest tube should be placed**

Management of recurrent pleural effusion

Options for managing patients with recurrent pleural effusions include:

- recurrent aspiration
- pleurodesis
- indwelling pleural catheter
- drug management to alleviate symptoms e.g. opioids to relieve dyspnoea

AI + Q 123

Next question >

Textbooks

High-yield textbook

Extended textbook

Links

British Thoracic Society 17 14

2023 Pleural disease guidelines

Royal College of Physicians 13 7

2012 Pleural infection review

Suggest link Report broken link

Media

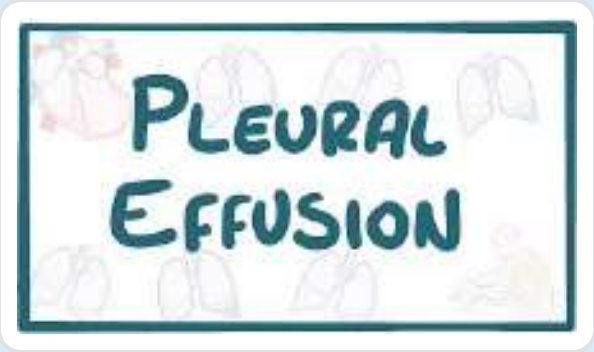

Pleural effusion

Osmosis - YouTube 8 1

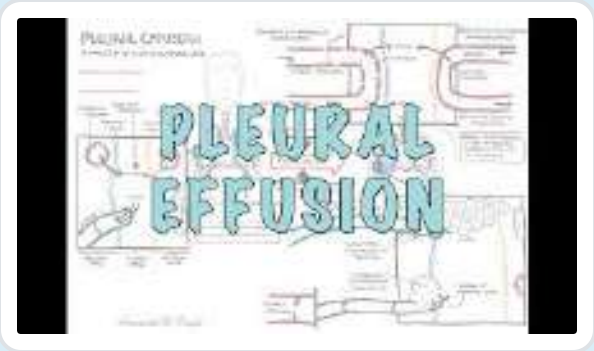

Pleural effusion

Armando Hasudungan - YouTube 6 1

Report broken media

Score: **20.4%**

1 ✗
2 ✗
3 ✗
4 ✗
5 ✗
6 ✗
7 ✗
8 ✗
9 ✓
10 ✓
11 ✗

12	✗
13	✗
14	✓
15	✗
16	✓
17	✗
18	✗
19	✗
20	✗
21	✓
22	✓
23	✗
24	✗
25	✗
26	✗
27	✓
28	✗
29	✗
30	✓
31	✓
32	✗
33	✗
34	✗
35	✗
36	✗
37	✗
38	✗
39	✗
40	-
41	✗
42	✗
43	✗
44	✗
45	✓
46	✗
47	✗

48	✕
49	✕
50	✕
51	-

All contents of this site are © 2024 Passmedicine Limited

A 56-year-old gentleman was admitted to the Emergency Department with a two-week history of progressively increasing shortness of breath, with frank haemoptysis for the last couple of days. He had recently returned from a holiday in Turkey a few weeks ago. By the point of admission, he was short of breath on minimal exertion and at rest and was unable to complete full sentences. He also complained of increasing orthopnoea for the last few weeks. He had a long history of recurrent epistaxis, rhinitis and sinusitis, as a well as a past medical history of diabetes, hypertension, hypercholesterolaemia and gout. His medication regimen comprised of mometasone nasal spray, allopurinol 100mg OD, ramipril 2.5 mg OD, amlodipine 5mg OD, simvastatin 40mg OD, metformin 500mg TDS and gliclazide 80mg OD. He smoked 20 cigarettes per day and did not consume alcohol.

On examination, he appeared very unwell with obvious respiratory distress. His respiratory rate was 28/min, his oxygen saturations were 90% on air, his blood pressure was 108/72 mmHg, his heart rate was 129 and his temperature was 37.9 degrees celsius. Examination of his cardiovascular system revealed normal heart sounds with a JVP of 3cm. Examination of the respiratory system revealed the use of accessory muscles with bibasal fine crackles. Examination of the gastrointestinal and neurological systems was unremarkable.

Initial investigations revealed the following:

Hb	82 g/l
Platelets	342 * 10^9/l
WBC	14.2 * 10^9/l
ESR	88 mm/hr

Na^+	128 mmol/l
K^+	6.1 mmol/l
Urea	28 mmol/l
Creatinine	762 µmol/l
CRP	42 mg/l
Glucose	5.6 mmol/l

Chest x-ray: bilateral patchy infiltration
ECG: heart rate 132 bpm normal sinus rhythm, no other changes
Urinalysis blood ++++ protein +++ leuc/nit negative glucose negative

ABG on 15 l/min oxygen:

PaO2	16.9 kPa
PaCO2	2.8 kPa
HCO3	18.2 mmol/l
pH	7.49

He was catheterized, commenced on an intravenous infusion of normal saline, as well as co-amoxiclav 625mg TDS and quickly transferred to the Intensive Care Unit. A decision was made to institute immediate haemodialysis, for which preparations were being made.

Further investigations revealed the following:

Urine MCS: nil grown
Blood culture - interim results: nil grown

Transoesophageal echocardiogram: normal systolic function, valvular appearances and no vegetations seen

C3	1.22 (NR 0.65 1.65g/L)
C4	0.32 (NR 0.16 0.60 g/L)
ANA	negative
ENA	negative
dsDNA	negative
cANCA	positive
pANCA	negative
Rheumatoid factor	negative

Given the likely underlying diagnosis, which of the following interventions is the next best step whilst awaiting haemodialysis?

- Stop IV augmentin, commence IV meropenem
- Commence IV immunoglobulins
- Commence high dose IV methylprednisolone and cyclophosphamide

- ○ Institute immediate plasma exchange
- ○ Commence intravenous activated protein C

Submit answer

Reference ranges

Score: **24%**

1	✗
2	✗
3	✗
4	✗
5	✗
6	✗
7	✗
8	✗
9	✓
10	✓
11	✗
12	✗
13	✗
14	✓
15	✗
16	✓
17	✗
18	✗
19	✗
20	✗
21	✓
22	✓
23	✗

24	✕
25	✕
26	-
27	-
28	-
29	-
30	-
31	-
32	-
33	-
34	-
35	-
36	-
37	-
38	-

All contents of this site are © 2024 Passmedicine Limited

A 56-year-old gentleman was admitted to the Emergency Department with a two-week history of progressively increasing shortness of breath, with frank haemoptysis for the last couple of days. He had recently returned from a holiday in Turkey a few weeks ago. By the point of admission, he was short of breath on minimal exertion and at rest and was unable to complete full sentences. He also complained of increasing orthopnoea for the last few weeks. He had a long history of recurrent epistaxis, rhinitis and sinusitis, as a well as a past medical history of diabetes, hypertension, hypercholesterolaemia and gout. His medication regimen comprised of mometasone nasal spray, allopurinol 100mg OD, ramipril 2.5 mg OD, amlodipine 5mg OD, simvastatin 40mg OD, metformin 500mg TDS and gliclazide 80mg OD. He smoked 20 cigarettes per day and did not consume alcohol.

On examination, he appeared very unwell with obvious respiratory distress. His respiratory rate was 28/min, his oxygen saturations were 90% on air, his blood pressure was 108/72 mmHg, his heart rate was 129 and his temperature was 37.9 degrees celsius. Examination of his cardiovascular system revealed normal heart sounds with a JVP of 3cm. Examination of the respiratory system revealed the use of accessory muscles with bibasal fine crackles. Examination of the gastrointestinal and neurological systems was unremarkable.

Initial investigations revealed the following:

Hb	82 g/l
Platelets	342 * 10^9/l
WBC	14.2 * 10^9/l
ESR	88 mm/hr

Na^+	128 mmol/l
K^+	6.1 mmol/l
Urea	28 mmol/l
Creatinine	762 µmol/l
CRP	42 mg/l
Glucose	5.6 mmol/l

Chest x-ray: bilateral patchy infiltration
ECG: heart rate 132 bpm normal sinus rhythm, no other changes
Urinalysis blood ++++ protein +++ leuc/nit negative glucose negative

ABG on 15 l/min oxygen:

PaO2	16.9 kPa
PaCO2	2.8 kPa
HCO3	18.2 mmol/l
pH	7.49

He was catheterized, commenced on an intravenous infusion of normal saline, as well as co-amoxiclav 625mg TDS and quickly transferred to the Intensive Care Unit. A decision was made to institute immediate haemodialysis, for which preparations were being made.

Further investigations revealed the following:

Urine MCS: nil grown
Blood culture - interim results: nil grown

Transoesophageal echocardiogram: normal systolic function, valvular appearances and no vegetations seen

C3	1.22 (NR 0.65 1.65g/L)
C4	0.32 (NR 0.16 0.60 g/L)
ANA	negative
ENA	negative
dsDNA	negative
cANCA	positive
pANCA	negative
Rheumatoid factor	negative

Given the likely underlying diagnosis, which of the following interventions is the next best step whilst awaiting haemodialysis?

- Stop IV augmentin, commence IV meropenem 1%
- Commence IV immunoglobulins 4%
- Commence high dose IV methylprednisolone and cyclophosphamide 78%

Institute immediate plasma exchange 17%

Commence intravenous activated protein C 0%

This patient has granulomatosis with polyangiitis, with severe pulmonary and renal involvement. He requires urgent immunosuppression. Of the available options, the next best step is therefore to institute cyclophosphamide and methylprednisolone. The options may serve a role, but this question is asking what the most appropriate next best step is. Therefore the best option is option 3.

Discuss (11) Improve

Next question

Granulomatosis with polyangiitis

Granulomatosis with polyangiitis is now the preferred term for Wegener's granulomatosis. It is an autoimmune condition associated with a necrotizing granulomatous vasculitis, affecting both the upper and lower respiratory tract as well as the kidneys.

Features

- upper respiratory tract: epistaxis, sinusitis, nasal crusting
- lower respiratory tract: dyspnoea, haemoptysis
- rapidly progressive glomerulonephritis ('pauci-immune', 80% of patients)
- saddle-shape nose deformity
- also: vasculitic rash, eye involvement (e.g. proptosis), cranial nerve lesions

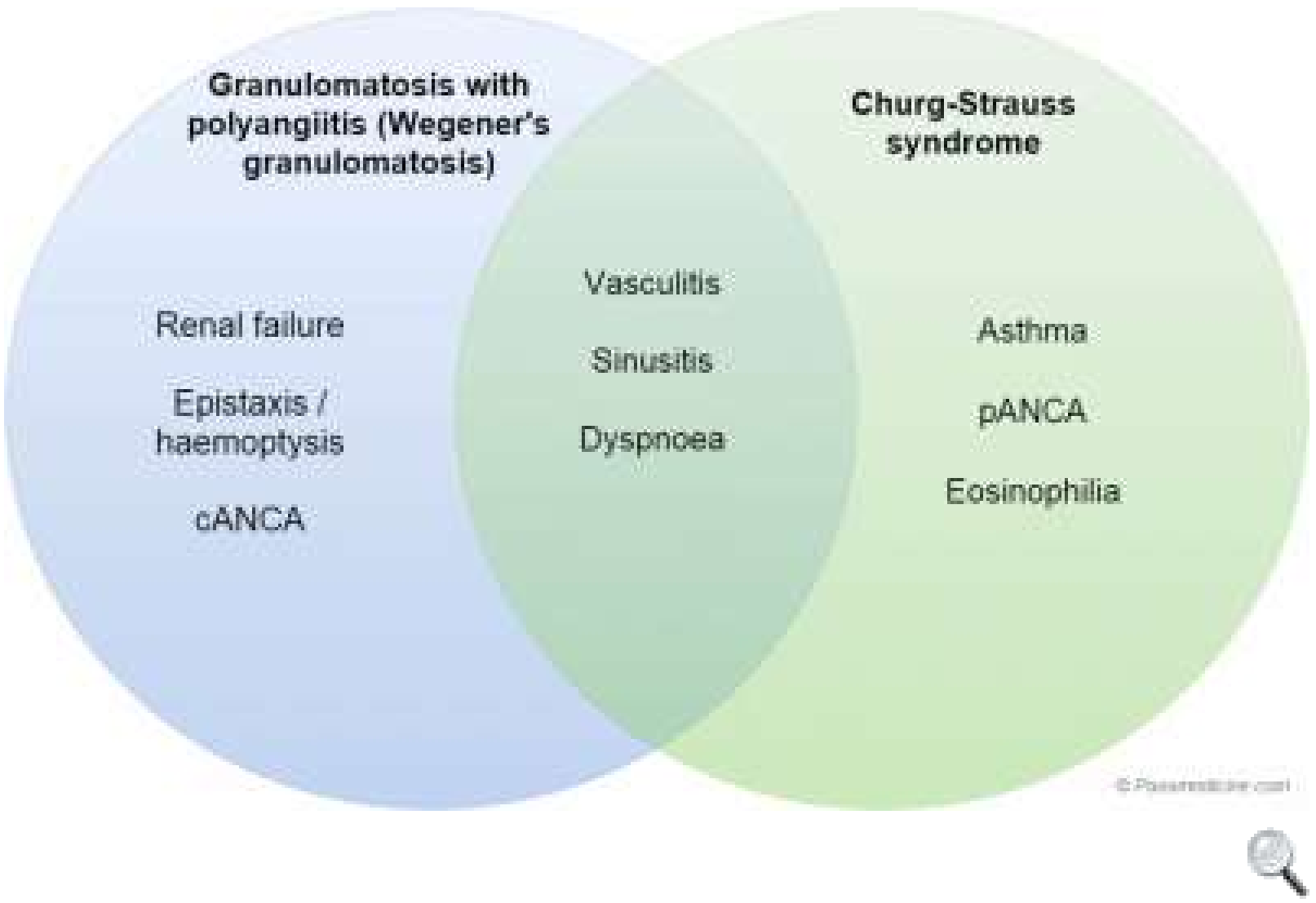

Comparison of granulomatosis with polyangiitis and Churg-Strauss syndrome

Investigations

- cANCA positive in > 90%, pANCA positive in 25%
- chest x-ray: wide variety of presentations, including cavitating lesions
- renal biopsy: epithelial crescents in Bowman's capsule

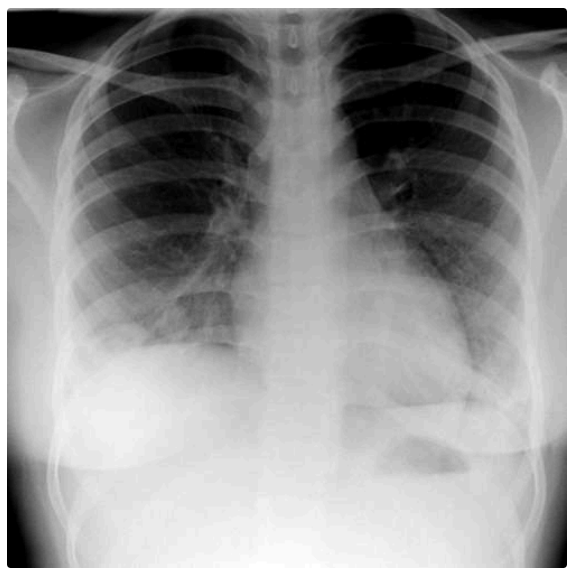
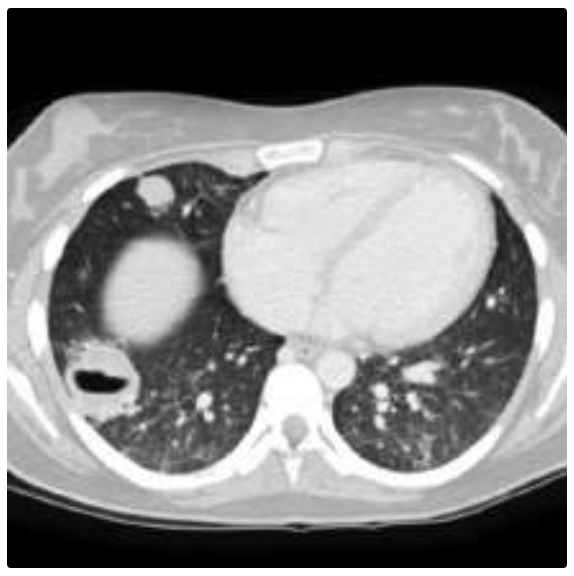

Management

- steroids
- cyclophosphamide (90% response)
- plasma exchange
- median survival = 8-9 years

123

Next question

Textbooks

High-yield textbook

Extended textbook

Media

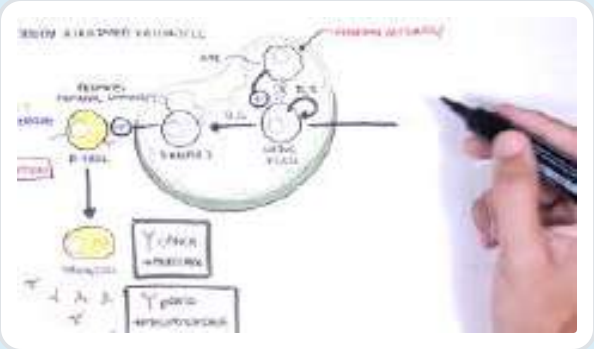

ANCA (Anti-Neutrophil Cytoplasmic Antibody) Associated Vasculitis - Causes, Pathophysiology, Types

Armando Hasudungan - YouTube

5 1

Granulomatosis with polyangiitis

Armando Hasudungan - YouTube

5 2

Report broken media

Score: **20.4%**

1	✗
2	✗
3	✗
4	✗
5	✗
6	✗
7	✗
8	✗
9	✓
10	✓
11	✗
12	✗
13	✗
14	✓
15	✗

16	✓
17	✗
18	✗
19	✗
20	✗
21	✓
22	✓
23	✗
24	✗
25	✗
26	✗
27	✓
28	✗
29	✗
30	✓
31	✓
32	✗
33	✗
34	✗
35	✗
36	✗
37	✗
38	✗
39	✗
40	-
41	✗
42	✗
43	✗
44	✗
45	✓
46	✗
47	✗
48	✗
49	✗
50	✗
51	-

All contents of this site are © 2024 Passmedicine Limited

An 83-year-old female presents to A&E with a four day history of increasing shortness of breath and worsening of a chronic productive cough. She speaks no English but you know from her medical records that she recently emigrated from rural India to live with her family two years ago. She has no diagnosed underlying lung condition. On examination, she has bilateral expiratory wheeze and hyperexpanded lungs with no clear inspiratory crackles. Heart sounds appear normal and mild bilateral pitting oedema. Her saturation measures 88% on air via pulse oxymeter, respiratory rate is 24 to 28 per minute. Her chest radiograph is hyperexpanded with mild bibasal fibrotic changes but demonstrates no focal signs of consolidation. She has no smoking or alcohol history. Her blood tests are as follows:

Hb	15.0 g/dl
Platelets	211 * 10^9/l
WBC	11.4 * 10^9/l
Neutrophils	9.5 * 10^9/l

Urea	8.4 mmol/l
Creatinine	112 μmol/l
CRP	37 mg/l

What is the most likely diagnosis?

- Exacerbation of congestive cardiac failure
- Infective exacerbation COPD
- Community acquired pneumonia
- Tuberculosis
- Progression of pulmonary fibrosis

Submit answer

Reference ranges

Score: **24%**

1	✗
2	✗
3	✗
4	✗
5	✗
6	✗
7	✗
8	✗
9	✓
10	✓
11	✗
12	✗
13	✗
14	✓
15	✗
16	✓
17	✗
18	✗
19	✗
20	✗
21	✓
22	✓
23	✗
24	✗
25	✗
26	-
27	-
28	-
29	-
30	-
31	-
32	-
33	-

34	-
35	-
36	-
37	-
38	-
39	-

All contents of this site are © 2024 Passmedicine Limited

Back to top

An 83-year-old female presents to A&E with a four day history of increasing shortness of breath and worsening of a chronic productive cough. She speaks no English but you know from her medical records that she recently emigrated from rural India to live with her family two years ago. She has no diagnosed underlying lung condition. On examination, she has bilateral expiratory wheeze and hyperexpanded lungs with no clear inspiratory crackles. Heart sounds appear normal and mild bilateral pitting oedema. Her saturation measures 88% on air via pulse oxymeter, respiratory rate is 24 to 28 per minute. Her chest radiograph is hyperexpanded with mild bibasal fibrotic changes but demonstrates no focal signs of consolidation. She has no smoking or alcohol history. Her blood tests are as follows:

Hb	15.0 g/dl
Platelets	211 * 10^9/l
WBC	11.4 * 10^9/l
Neutrophils	9.5 * 10^9/l

Urea	8.4 mmol/l
Creatinine	112 µmol/l
CRP	37 mg/l

What is the most likely diagnosis?

- Exacerbation of congestive cardiac failure 4%
- Infective exacerbation COPD 57%
- Community acquired pneumonia 3%
- Tuberculosis 7%
- Progression of pulmonary fibrosis 29%

Although COPD is often associated as a disease of smokers, it is prudent to remember other causes of chronic emphysematous changes. In patients from the developing world, non-smokers from the Indian subcontinent and African countries often present with a COPD-like history from

using open fires in their homes, particularly if burnt indoors for cooking or heating. The World Health Organisation (WHO) estimate that up to 3 billion people cook in this manner, accounting for up to 1 million deaths worldwide as a result of COPD without smoking history[1]. The clinical findings are consistent with an obstructive picture and hyperexpansion of the lungs suggest a chronic element to an underlying lung condition, despite no formal previous diagnosis. Mild oedema may simply represent a degree of right heart failure from the underlying lung pathology. Bibasal fibrotic changes may be consistent with lung fibrosis but you would expect a restrictive picture instead. Community acquired pneumonia would be the main differential diagnosis but again, does not account for the chronic cough or hyperexpanded lungs.

1. WHO fact sheet on indoor air pollution and health
http://www.who.int/mediacentre/factsheets/fs292/en/

Discuss (9) Improve

Next question

Acute exacerbation of COPD

Acute exacerbations of COPD are one of the most common reasons why people present to hospital in developed countries.

The most common infective causes of COPD exacerbations are:

- bacteria
  - *Haemophilus influenzae* (most common cause)
  - *Streptococcus pneumoniae*
  - *Moraxella catarrhalis*
- respiratory viruses
  - account for around 30% of exacerbations
  - human rhinovirus is the most important pathogen

Features

- increase in dyspnoea, cough, wheeze
- there may be an increase in sputum suggestive of an infective cause
- patients may be hypoxic and in some cases have acute confusion

NICE guidelines from 2010 recommend the following:

- increase the frequency of bronchodilator use and consider giving via a nebuliser
- give prednisolone 30 mg daily for 5 days

- it is common practice for all patients with an exacerbation of COPD to receive antibiotics. NICE do not support this approach. They recommend giving oral antibiotics 'if sputum is purulent or there are clinical signs of pneumonia'
- the BNF recommends one of the following oral antibiotics first-line: amoxicillin or clarithromycin or doxycycline.

Admission is recommended if any of the following criteria are met

- severe breathlessness
- acute confusion or impaired consciousness
- cyanosis
- oxygen saturation less than 90% on pulse oximetry.
- social reasons e.g. inability to cope at home (or living alone)
- significant comorbidity (such as cardiac disease or insulin-dependent diabetes)

Severe exacerbations requiring secondary care

Oxygen therapy

- COPD patients are at risk of hypercapnia - therefore an initial oxygen saturation target of 88-92% should be used
- prior to the availability of blood gases, use a 28% Venturi mask at 4 l/min and aim for an oxygen saturation of 88-92% for patients with risk factors for hypercapnia but no prior history of respiratory acidosis
- adjust target range to 94-98% if the pCO2 is normal

Nebulised bronchodilator

- beta adrenergic agonist: e.g. salbutamol
- muscarinic antagonists: e.g. ipratropium

Steroid therapy as above

- IV hydrocortisone may sometimes be considered instead of oral prednisolone

IV theophylline

- may be considered for patients not responding to nebulised bronchodilators

Patients with COPD are prone to develop type 2 respiratory failure. If this develops then non-invasive ventilation may be used

- typically used for COPD with respiratory acidosis pH 7.25-7.35

- the BTS guidelines state that NIV can be used in patients who are more acidotic (i.e. pH < 7.25) but that a greater degree of monitoring is required (e.g. HDU) and a lower threshold for intubation and ventilation should be used
- bilevel positive airway pressure (BiPaP) is typically used with initial settings:
  - Expiratory Positive Airway Pressure (EPAP): 4-5 cm H_2O
  - Inspiratory Positive Airway Pressure (IPAP): RCP advocate 10 cm H20 whilst BTS suggest 12-15 cm H_2O

123

Next question

Textbooks

High-yield textbook

Extended textbook

Links

Clinical Knowledge Summaries 28 25

Acute exacerbation of COPD guidelines

NICE 22 10

2018 COPD guidelines

Suggest link Report broken link

Media

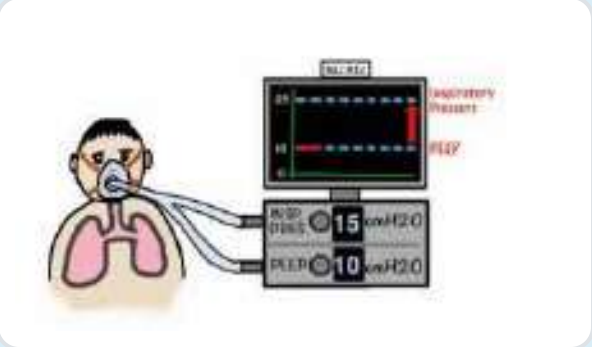

[CPAP and Non-Invasive Ventilation in 5 minutes](#)

Nick Smith - YouTube 6 2

Report broken media

Score: **20.4%**

1	✗
2	✗
3	✗
4	✗
5	✗
6	✗
7	✗
8	✗
9	✓
10	✓
11	✗
12	✗
13	✗
14	✓
15	✗
16	✓
17	✗
18	✗
19	✗
20	✗
21	✓
22	✓
23	✗

24	✗
25	✗
26	✗
27	✓
28	✗
29	✗
30	✓
31	✓
32	✗
33	✗
34	✗
35	✗
36	✗
37	✗
38	✗
39	✗
40	-
41	✗
42	✗
43	✗
44	✗
45	✓
46	✗
47	✗
48	✗
49	✗
50	✗
51	-

All contents of this site are © 2024 Passmedicine Limited

Back to top

A 52-year-old man presents to the emergency department with shortness of breath. This started recently following a flight from Australia. He is morbidly obese and has a past medical history of type two diabetes mellitus, high cholesterol, hypertension and a previous cholecystectomy. He denies any leg pain or swelling and denies any chest pain. Observations are stable, and an ECG demonstrates sinus rhythm. A chest X-ray is clear. He undergoes a CT pulmonary angiogram (CTPA) to exclude a pulmonary embolus (PE). The CTPA is reported as finding no evidence of PE but notes a 7mm pulmonary nodule in the left lower lobe.

How should the pulmonary nodule be investigated or monitored?

- Urgent CT-PET
- Urgent image-guided biopsy
- CT chest in three months
- CT chest in one year
- No further investigations needed

Submit answer

Reference ranges

Score: **24%**

1 ✗
2 ✗
3 ✗
4 ✗
5 ✗

6	✗
7	✗
8	✗
9	✓
10	✓
11	✗
12	✗
13	✗
14	✓
15	✗
16	✓
17	✗
18	✗
19	✗
20	✗
21	✓
22	✓
23	✗
24	✗
25	✗
26	-
27	-
28	-
29	-
30	-
31	-
32	-
33	-
34	-
35	-
36	-
37	-
38	-
39	-
40	-

All contents of this site are © 2024 Passmedicine Limited

A 52-year-old man presents to the emergency department with shortness of breath. This started recently following a flight from Australia. He is morbidly obese and has a past medical history of type two diabetes mellitus, high cholesterol, hypertension and a previous cholecystectomy. He denies any leg pain or swelling and denies any chest pain. Observations are stable, and an ECG demonstrates sinus rhythm. A chest X-ray is clear. He undergoes a CT pulmonary angiogram (CTPA) to exclude a pulmonary embolus (PE). The CTPA is reported as finding no evidence of PE but notes a 7mm pulmonary nodule in the left lower lobe.

How should the pulmonary nodule be investigated or monitored?

- Urgent CT-PET
- Urgent image-guided biopsy
- CT chest in three months
- CT chest in one year
- No further investigations needed

Submit answer

Reference ranges

Score: **20.4%**

1 ✗
2 ✗
3 ✗
4 ✗
5 ✗

6	✗
7	✗
8	✗
9	✓
10	✓
11	✗
12	✗
13	✗
14	✓
15	✗
16	✓
17	✗
18	✗
19	✗
20	✗
21	✓
22	✓
23	✗
24	✗
25	✗
26	✗
27	✓
28	✗
29	✗
30	✓
31	✓
32	✗
33	✗
34	✗
35	✗
36	✗
37	✗
38	✗
39	✗
40	-
41	✗

42	✗
43	✗
44	✗
45	✓
46	✗
47	✗
48	✗
49	✗
50	✗
51	-

All contents of this site are © 2024 Passmedicine Limited

A 40-year-old lady presents with dyspnoea. She describes a gradual onset of shortness of breath on exercise over several months. She has a past medical history of wheeze as an infant. She has recently commenced a intranasal steroid spray for rhinitis. She is a non-smoker.

On examination she has oxygen saturations of 91% on air. She has blood stained crusting around her anterior nares. On auscultation her chest has bilateral reduced air entry and coarse crepitations on both lung bases. Her temperature is 37.8 degrees centrigrade.

Hb	13.2 g/dL
WCC	10.3 *10^9/l
Neutrophil	7.8 *10^9/l
Eosinophil	0.07 *10^9/l

Sodium	135 mmol/l
Potassium	4.5 mmol/l
Creatinine	113 µmol/l
Urea	5.4 mmol/l

CRP	230 mg/L
Chest X - ray	Bilateral basal consolidation
Urine microscopy	Culture negative RBC +++ WCC +
c-ANCA	Positive
p-ANCA	Positive
Anti-GBM	Negative

What is the most likely diagnosis?

- Pneumonia
- Churg-Strauss Syndrome
- Microscopic polyangiitis

- ○ Granulomatosis with polyangiitis ×
- ○ Goodpastures disease ×

Submit answer

Reference ranges

Score: **24%**

1	✗
2	✗
3	✗
4	✗
5	✗
6	✗
7	✗
8	✗
9	✓
10	✓
11	✗
12	✗
13	✗
14	✓
15	✗
16	✓
17	✗
18	✗
19	✗
20	✗
21	✓
22	✓
23	✗

24	✕
25	✕
26	-
27	-
28	-
29	-
30	-
31	-
32	-
33	-
34	-
35	-
36	-
37	-
38	-
39	-
40	-
41	-

All contents of this site are © 2024 Passmedicine Limited

Back to top

A 40-year-old lady presents with dyspnoea. She describes a gradual onset of shortness of breath on exercise over several months. She has a past medical history of wheeze as an infant. She has recently commenced a intranasal steroid spray for rhinitis. She is a non-smoker.

On examination she has oxygen saturations of 91% on air. She has blood stained crusting around her anterior nares. On auscultation her chest has bilateral reduced air entry and coarse crepitations on both lung bases. Her temperature is 37.8 degrees centrigrade.

Hb	13.2 g/dL
WCC	10.3 *10^9/l
Neutrophil	7.8 *10^9/l
Eosinophil	0.07 *10^9/l

Sodium	135 mmol/l
Potassium	4.5 mmol/l
Creatinine	113 µmol/l
Urea	5.4 mmol/l

CRP	230 mg/L
Chest X - ray	Bilateral basal consolidation
Urine microscopy	Culture negative RBC +++ WCC +
c-ANCA	Positive
p-ANCA	Positive
Anti-GBM	Negative

What is the most likely diagnosis?

- Pneumonia 1%
- Churg-Strauss Syndrome 21%
- Microscopic polyangiitis 14%

Granulomatosis with polyangiitis 62%

Goodpastures disease 2%

Consider granulomatosis with polyangiitis when a patient presents with ENT, respiratory and kidney involvement

Important for me Less important

Definitive diagnosis of vasculitis will require biopsy. However, granulomatosis with polyangiitisis the most likely as the presentation includes sinus disease, lung disease with likely renal involvement. Both ANCA tests can be positive but it is most associated with c-ANCA.

This patient had wheeze as a child, which is very common. Churg-Strauss is more associated with a progressive presentation of asthma, which may present later in life. The patient also does not have eosinophilia which is associated with this diagnosis.

Goodpasture's is a possibility but less likely with a negative anti-GBM. Pnemonia is less likely with such a prolonged presentation.

Microscopic polyangiitis can present very similar to granulomatosis with polyangiitis but is more associated with renal involvement, which is mild in this case. It is less associated with ENT disease.

Discuss (3) Improve

Next question

Granulomatosis with polyangiitis

Granulomatosis with polyangiitis is now the preferred term for Wegener's granulomatosis. It is an autoimmune condition associated with a necrotizing granulomatous vasculitis, affecting both the upper and lower respiratory tract as well as the kidneys.

Features

- upper respiratory tract: epistaxis, sinusitis, nasal crusting
- lower respiratory tract: dyspnoea, haemoptysis
- rapidly progressive glomerulonephritis ('pauci-immune', 80% of patients)
- saddle-shape nose deformity
- also: vasculitic rash, eye involvement (e.g. proptosis), cranial nerve lesions

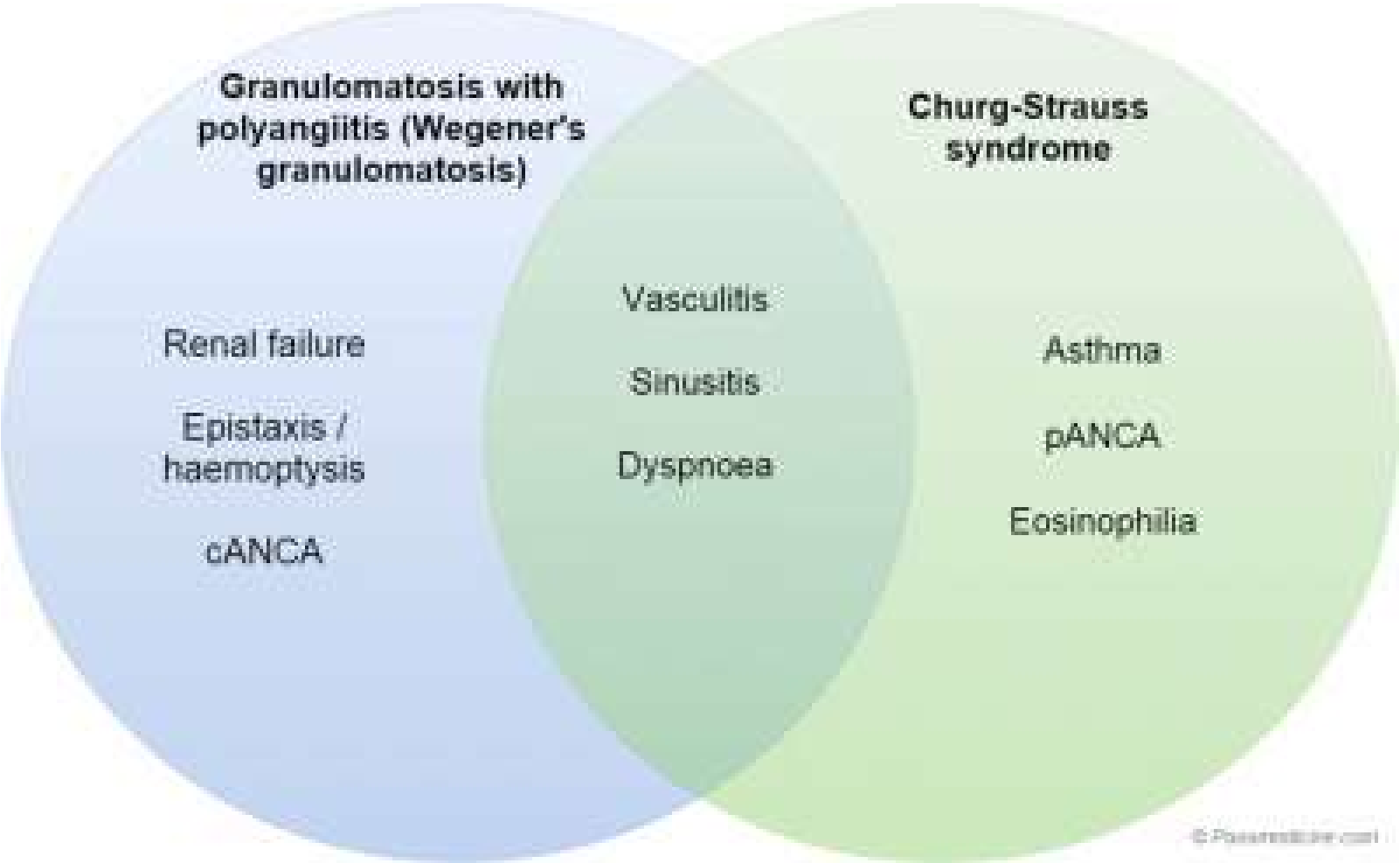

Comparison of granulomatosis with polyangiitis and Churg-Strauss syndrome

Investigations

- cANCA positive in > 90%, pANCA positive in 25%
- chest x-ray: wide variety of presentations, including cavitating lesions
- renal biopsy: epithelial crescents in Bowman's capsule

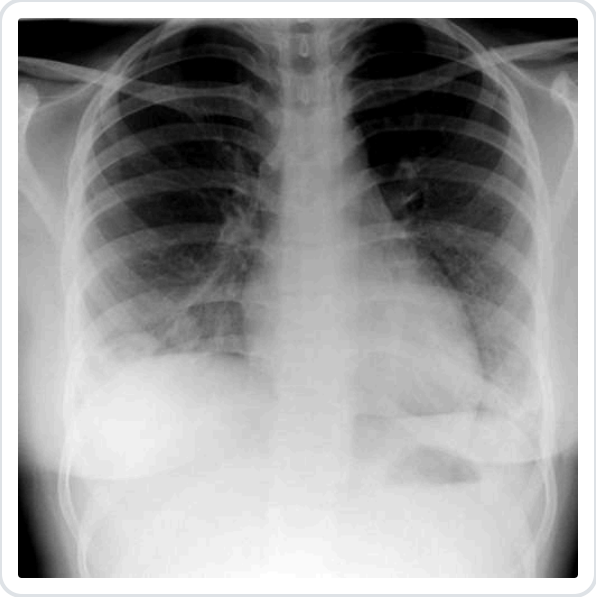
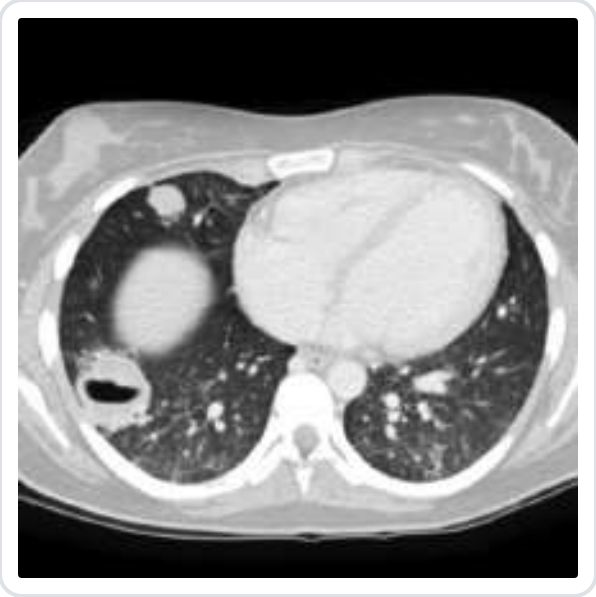

Management

- steroids
- cyclophosphamide (90% response)
- plasma exchange
- median survival = 8-9 years

123

Next question

Textbooks

High-yield textbook

Extended textbook

Media

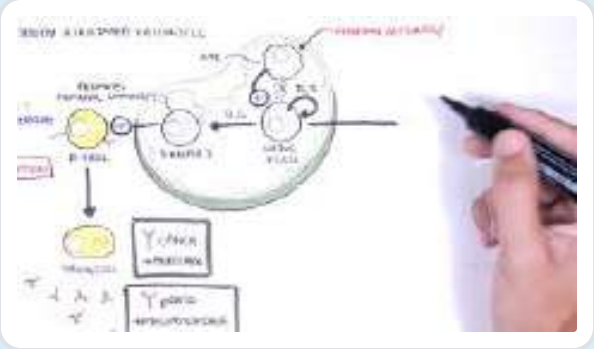

ANCA (Anti-Neutrophil Cytoplasmic Antibody) Associated Vasculitis - Causes, Pathophysiology, Types

Armando Hasudungan - YouTube 5 1

Granulomatosis with polyangiitis

Armando Hasudungan - YouTube 5 2

Report broken media

Score: **20.4%**

1 ✗
2 ✗
3 ✗
4 ✗
5 ✗
6 ✗

7	✗
8	✗
9	✓
10	✓
11	✗
12	✗
13	✗
14	✓
15	✗
16	✓
17	✗
18	✗
19	✗
20	✗
21	✓
22	✓
23	✗
24	✗
25	✗
26	✗
27	✓
28	✗
29	✗
30	✓
31	✓
32	✗
33	✗
34	✗
35	✗
36	✗
37	✗
38	✗
39	✗
40	-
41	✗
42	✗

43	✗
44	✗
45	✓
46	✗
47	✗
48	✗
49	✗
50	✗
51	-

All contents of this site are © 2024 Passmedicine Limited

A 67-year-old man attends with reduced consciousness and shortness of breath. His wife accompanying him reports some diarrhoea over the past few days and he has taken himself to bed but was weak and unable to get up today. He is usually well but has been reporting morning headaches and is being referred to the sleep clinic. He takes no regular medications.

On examination, he has a respiratory rate of 11 breaths/minute and is saturating at 94% on 4 litres through a face mask. His chest clear is clear and his abdomen is soft and non tender. He is generally weak but is able to follow commands. It is difficult to understand him and you can only hear whispers when he speaks to you. His calves are soft with mild oedema in the ankles and he is overweight.

Na^+	139mmol/l
K^+	4.2 mmol/l
Urea	6.5 mmol/l
Creatinine	98 µmol/l
CRP	34
Hb	119 g/l
Platelets	$298 * 10^9/l$
WBC	$5.6 * 10^9/l$

ABG (in air)	
pH	7.30
pO2	7.9 kPa
pCO2	6.5 kPa
HCO3	24mmol/l
Lactate	2.4 mmol/l

Chest x-ray	poor inspiratory effort, clear lung fields, heart size within normal parameters
ECG	sinus tachycardia

What is the likely diagnosis?

- Obstructive sleep apnoea
- Myasthenia gravis
- COPD exacerbation
- Pneumonia
- Pulmonary embolism

Submit answer

Reference ranges

Score: **24%**

1	✗
2	✗
3	✗
4	✗
5	✗
6	✗
7	✗
8	✗
9	✓
10	✓
11	✗
12	✗
13	✗
14	✓
15	✗
16	✓
17	✗
18	✗

19	✗
20	✗
21	✓
22	✓
23	✗
24	✗
25	✗
26	-
27	-
28	-
29	-
30	-
31	-
32	-
33	-
34	-
35	-
36	-
37	-
38	-
39	-
40	-
41	-
42	-

All contents of this site are © 2024 Passmedicine Limited

A 67-year-old man attends with reduced consciousness and shortness of breath. His wife accompanying him reports some diarrhoea over the past few days and he has taken himself to bed but was weak and unable to get up today. He is usually well but has been reporting morning headaches and is being referred to the sleep clinic. He takes no regular medications.

On examination, he has a respiratory rate of 11 breaths/minute and is saturating at 94% on 4 litres through a face mask. His chest clear is clear and his abdomen is soft and non tender. He is generally weak but is able to follow commands. It is difficult to understand him and you can only hear whispers when he speaks to you. His calves are soft with mild oedema in the ankles and he is overweight.

Na^+	139mmol/l
K^+	4.2 mmol/l
Urea	6.5 mmol/l
Creatinine	98 µmol/l
CRP	34
Hb	119 g/l
Platelets	298 * 10^9/l
WBC	5.6 * 10^9/l

ABG (in air)	
pH	7.30
pO2	7.9 kPa
pCO2	6.5 kPa
HCO3	24mmol/l
Lactate	2.4 mmol/l

Chest x-ray	poor inspiratory effort, clear lung fields, heart size within normal parameters
ECG	sinus tachycardia

What is the likely diagnosis?

Obstructive sleep apnoea	43%
Myasthenia gravis	41%
COPD exacerbation	5%
Pneumonia	1%
Pulmonary embolism	9%

Type 2 respiratory failure with normal CXR -> neuromuscular weakness

Important for me Less important

This gentleman has presented with a type 2 respiratory failure. His bicarbonate is normal suggesting this is an acute deterioration and is less likely to be a COPD exacerbation or obstructive sleep apnoea where there is CO2 retainers and a raised bicarbonate. His chest x-ray shows no evidence of pneumonia. A pulmonary embolism is possible but usually presents with type 1 respiratory failure. Given that he has a poor respiratory effort and is not tachypnoeic, this should prompt thoughts of whether the ventilation is inadequate and this may reflect neuromuscular failure. These patients have shallow ventilation and spirometry shows a hugely reduced functional vital capacity.

Discuss (11) Improve

Next question

Respiratory acidosis

Respiratory acidosis may be caused by a number of conditions:

- COPD
- decompensation in other respiratory conditions e.g. life-threatening asthma / pulmonary oedema
- neuromuscular disease
- obesity hypoventilation syndrome
- sedative drugs: benzodiazepines, opiate overdose

123

Next question >

Textbooks

High-yield textbook

Extended textbook

Media

ABG Interpretation Made Easy

Respiratory Therapy Zone - YouTube 5 0

Acid-base disturbances

Osmosis - YouTube 3 0

Report broken media

Score: **20.4%**

1 ✕

2	✗
3	✗
4	✗
5	✗
6	✗
7	✗
8	✗
9	✓
10	✓
11	✗
12	✗
13	✗
14	✓
15	✗
16	✓
17	✗
18	✗
19	✗
20	✗
21	✓
22	✓
23	✗
24	✗
25	✗
26	✗
27	✓
28	✗
29	✗
30	✓
31	✓
32	✗
33	✗
34	✗
35	✗
36	✗
37	✗

38	✗
39	✗
40	-
41	✗
42	✗
43	✗
44	✗
45	✓
46	✗
47	✗
48	✗
49	✗
50	✗
51	-

All contents of this site are © 2024 Passmedicine Limited

Back to top

A 35-year-old woman is investigated for lethargy, fever, cough and weight loss. She has been treated by her GP with five courses of antibiotics over the past six months for a combination of chest and sinus infections. Her symptoms, however, have continued unabated.

Clinical examination is unremarkable other than some scattered crackles in the right base. She is apyrexial. Urine dipstick: blood ++, protein +

Lung function tests and blood tests show the following

FEV1	4.3 L (99% of predicted)
FVC	5.1 L (101% of predicted)
FEV1/FVC	84%

Hb	13.1 g/dl	Na^+	141 mmol/l
Platelets	459 * 10^9/l	K^+	3.6 mmol/l
WBC	6.9 * 10^9/l	Urea	10.9 mmol/l
		Creatinine	131 µmol/l
		CRP	78 mg/l

A chest x-ray is requested:

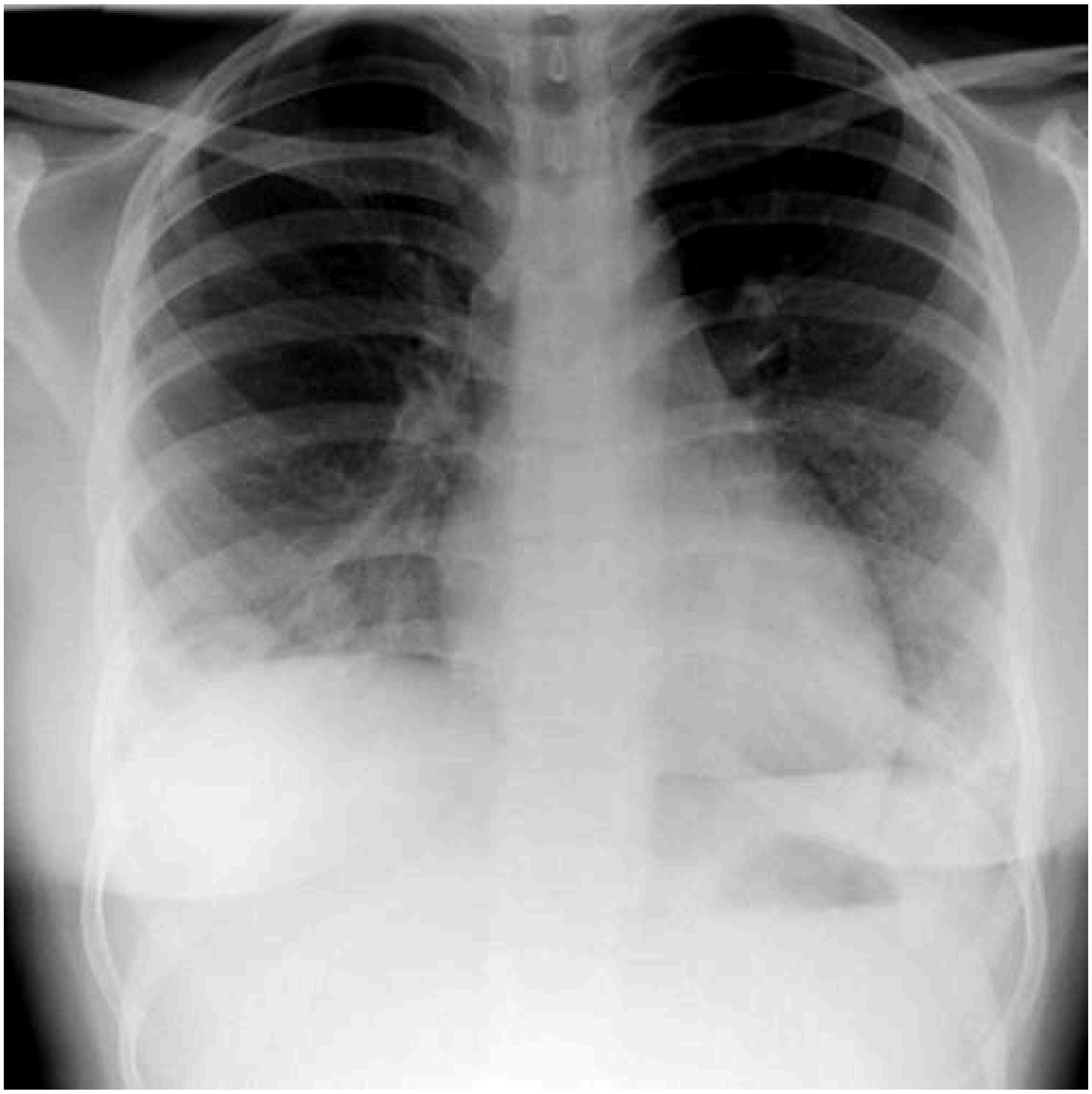

© Image used on license from Radiopaedia

What is the most likely diagnosis?

- Lung cancer
- Tuberculosis
- Granulomatosis with polyangiitis
- Cryptogenic organizing pneumonia
- Churg-Strauss syndrome

Submit answer

Reference ranges

Score: **24%**

1	✗
2	✗
3	✗
4	✗
5	✗
6	✗
7	✗
8	✗
9	✓
10	✓
11	✗
12	✗
13	✗
14	✓
15	✗
16	✓
17	✗
18	✗
19	✗
20	✗
21	✓
22	✓
23	✗
24	✗
25	✗
26	-
27	-
28	-
29	-
30	-
31	-
32	-
33	-
34	-

35 -
36 -
37 -
38 -
39 -
40 -
41 -
42 -
43 -

All contents of this site are © 2024 Passmedicine Limited
Back to top

A 35-year-old woman is investigated for lethargy, fever, cough and weight loss. She has been treated by her GP with five courses of antibiotics over the past six months for a combination of chest and sinus infections. Her symptoms, however, have continued unabated.

Clinical examination is unremarkable other than some scattered crackles in the right base. She is apyrexial. Urine dipstick: blood ++, protein +

Lung function tests and blood tests show the following

FEV1	4.3 L (99% of predicted)
FVC	5.1 L (101% of predicted)
FEV1/FVC	84%

Hb	13.1 g/dl	Na^+	141 mmol/l
Platelets	459 * 10^9/l	K^+	3.6 mmol/l
WBC	6.9 * 10^9/l	Urea	10.9 mmol/l
		Creatinine	131 µmol/l
		CRP	78 mg/l

A chest x-ray is requested:

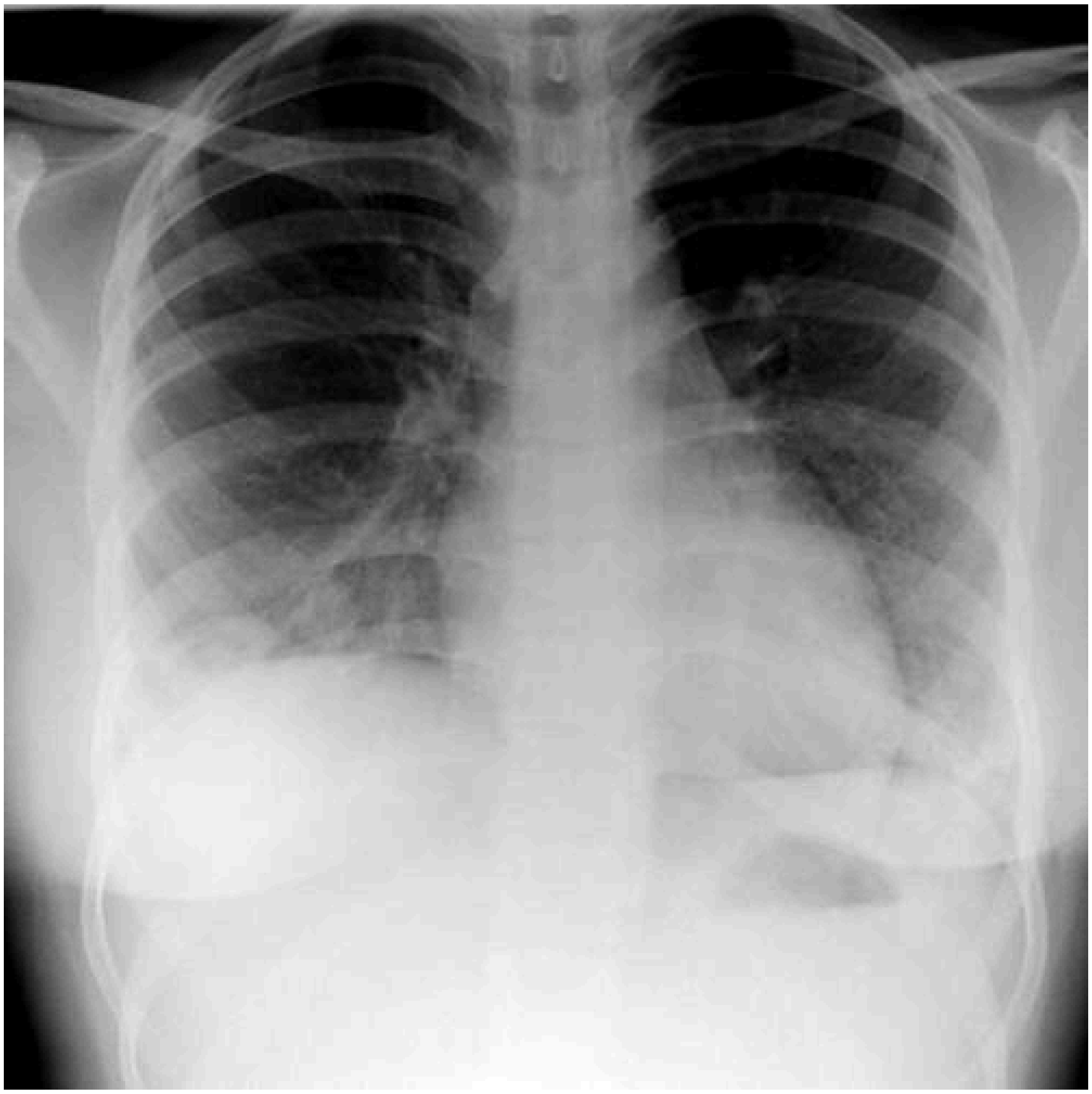

© Image used on license from Radiopaedia

What is the most likely diagnosis?

Lung cancer	2%
Tuberculosis	1%
Granulomatosis with polyangiitis	76%
Cryptogenic organizing pneumonia	9%
Churg-Strauss syndrome	13%

Whilst the changes are subtle the chest x-ray demonstrates a number of ill-defined nodules the largest of which projects over the dome of the right hemidiaphragm. This nodule appears to have a central lucency suggesting cavitation. Please see the accompanying CT scan from the same patient below.

Discuss (3) Improve

Next question

Granulomatosis with polyangiitis

Granulomatosis with polyangiitis is now the preferred term for Wegener's granulomatosis. It is an autoimmune condition associated with a necrotizing granulomatous vasculitis, affecting both the upper and lower respiratory tract as well as the kidneys.

Features

- upper respiratory tract: epistaxis, sinusitis, nasal crusting
- lower respiratory tract: dyspnoea, haemoptysis
- rapidly progressive glomerulonephritis ('pauci-immune', 80% of patients)
- saddle-shape nose deformity
- also: vasculitic rash, eye involvement (e.g. proptosis), cranial nerve lesions

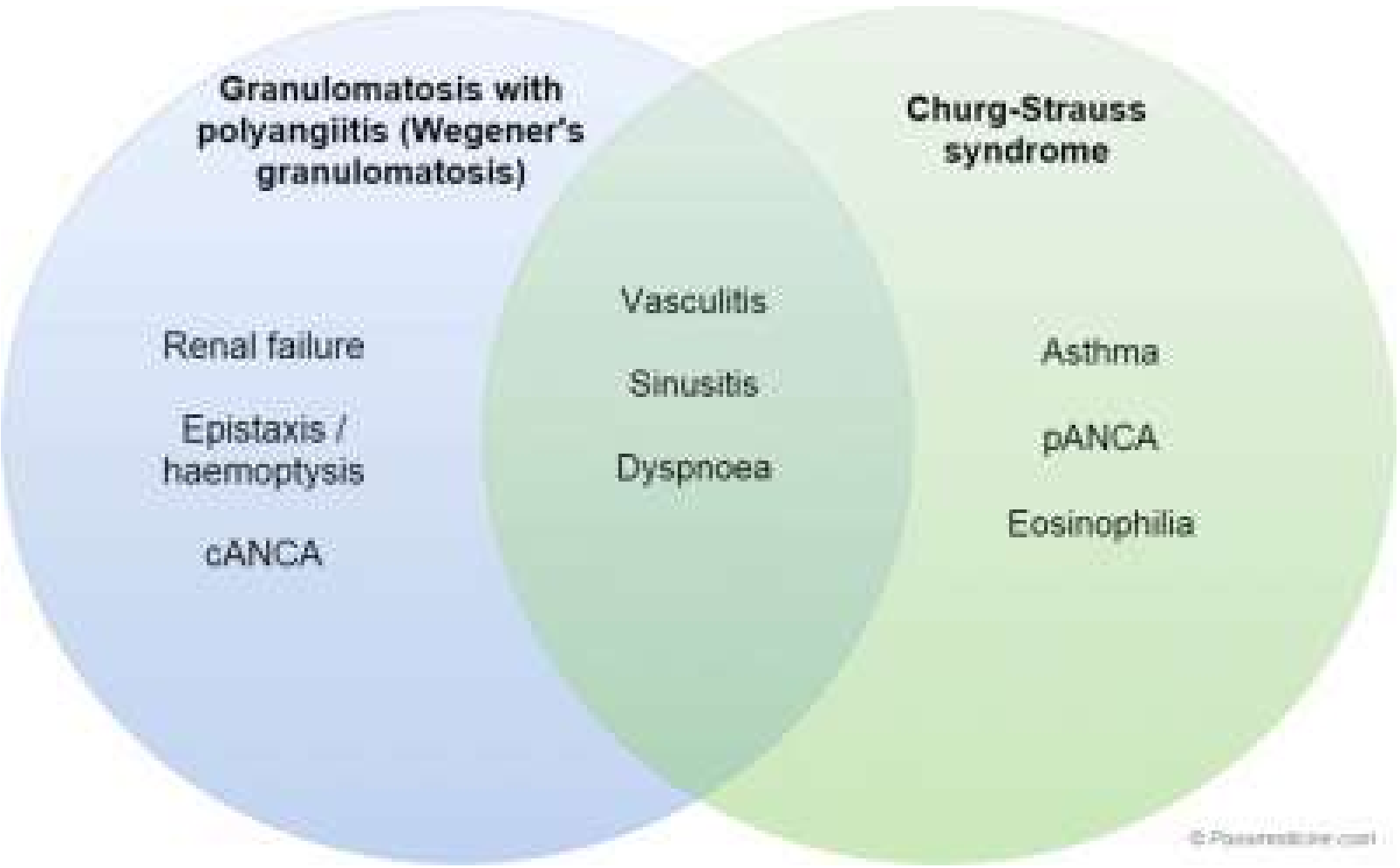

Comparison of granulomatosis with polyangiitis and Churg-Strauss syndrome

Investigations

- cANCA positive in > 90%, pANCA positive in 25%
- chest x-ray: wide variety of presentations, including cavitating lesions
- renal biopsy: epithelial crescents in Bowman's capsule

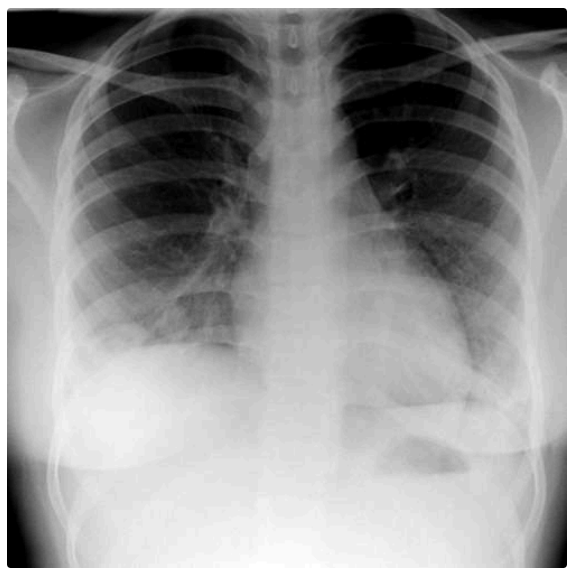 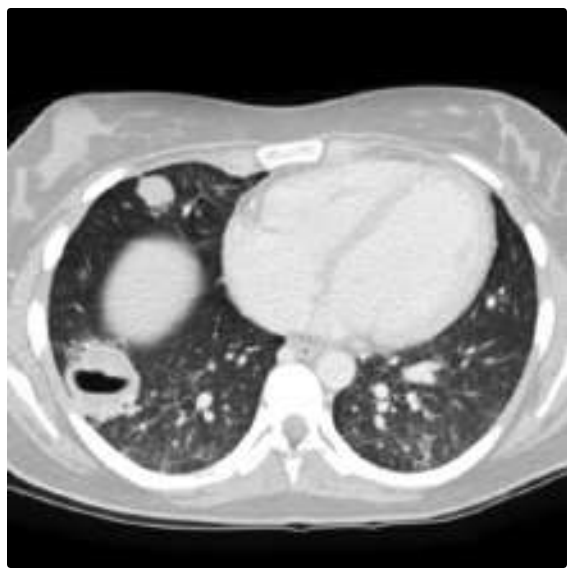

Management

- steroids
- cyclophosphamide (90% response)
- plasma exchange
- median survival = 8-9 years

123

Next question

Textbooks

High-yield textbook

Extended textbook

Media

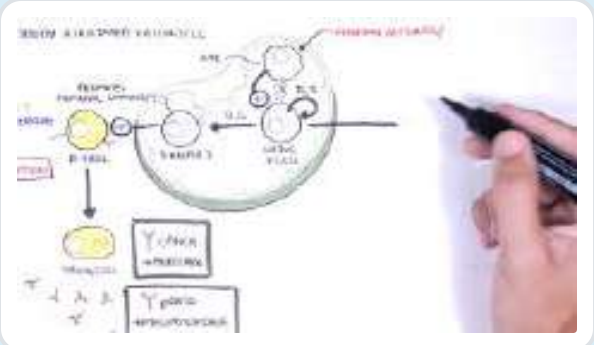

ANCA (Anti-Neutrophil Cytoplasmic Antibody) Associated Vasculitis - Causes, Pathophysiology, Types

Armando Hasudungan - YouTube 5 1

Granulomatosis with polyangiitis

Armando Hasudungan - YouTube

👍 5 👎 2

Report broken media

Score: **20.4%**

1	✗
2	✗
3	✗
4	✗
5	✗
6	✗
7	✗
8	✗
9	✓
10	✓
11	✗
12	✗
13	✗
14	✓
15	✗
16	✓
17	✗
18	✗
19	✗
20	✗
21	✓
22	✓
23	✗
24	✗

25	✗
26	✗
27	✓
28	✗
29	✗
30	✓
31	✓
32	✗
33	✗
34	✗
35	✗
36	✗
37	✗
38	✗
39	✗
40	-
41	✗
42	✗
43	✗
44	✗
45	✓
46	✗
47	✗
48	✗
49	✗
50	✗
51	-

All contents of this site are © 2024 Passmedicine Limited

A 42-year-old lady presents to the Emergency Department with a 3-week history of a dry cough, fever and lethargy. She has no past medical history and takes no regular medications. There is no history of recent foreign travel. Clinical examination reveals inspiratory crepitations affecting the left upper zone and R lower zone. Saturations are 91% on room air. Chest x-ray shows bilateral peripheral pulmonary infiltrates.

Bloods show:

Hb	110 g/L
MCV	78 fL
WCC	13 x 10^9/L
Neutrophils	8 x 10^9/L
Lymphocytes	1 x 10^9/L
Eosinophils	3.1 x 10^9/L
Platelets	560 x 10^9/L
CRP	115mg/l

What is the most appropriate treatment given the likely diagnosis?

- Oral prednisolone
- High dose co-trimoxazole
- Plasma exchange
- Rifampicin, isoniazid, ethambutol and pyrazinamide
- Amoxicillin and clarithromycin

Submit answer

Reference ranges

Score: **24%**

1	✗
2	✗
3	✗
4	✗
5	✗
6	✗
7	✗
8	✗
9	✓
10	✓
11	✗
12	✗
13	✗
14	✓
15	✗
16	✓
17	✗
18	✗
19	✗
20	✗
21	✓
22	✓
23	✗
24	✗
25	✗
26	-
27	-
28	-
29	-
30	-
31	-
32	-
33	-
34	-
35	-

36	-
37	-
38	-
39	-
40	-
41	-
42	-
43	-
44	-

All contents of this site are © 2024 Passmedicine Limited

A 42-year-old lady presents to the Emergency Department with a 3-week history of a dry cough, fever and lethargy. She has no past medical history and takes no regular medications. There is no history of recent foreign travel. Clinical examination reveals inspiratory crepitations affecting the left upper zone and R lower zone. Saturations are 91% on room air. Chest x-ray shows bilateral peripheral pulmonary infiltrates.

Bloods show:

Hb	110 g/L
MCV	78 fL
WCC	13 x 10^9/L
Neutrophils	8 x 10^9/L
Lymphocytes	1 x 10^9/L
Eosinophils	3.1 x 10^9/L
Platelets	560 x 10^9/L
CRP	115mg/l

What is the most appropriate treatment given the likely diagnosis?

- Oral prednisolone — 78%
- High dose co-trimoxazole — 9%
- Plasma exchange — 2%
- Rifampicin, isoniazid, ethambutol and pyrazinamide — 2%
- Amoxicillin and clarithromycin — 9%

Eosinophilic pneumonia is the most likely diagnosis. It is characterised by sub acute respiratory symptoms, alveolar and/ or blood eosinophilia, and peripheral pulmonary infiltrates on imaging. Treatment with oral corticosteroids leads to a rapid improvement of symptoms and the prognosis is good. Tuberculosis is usually associated with upper lobe consolidation and eosinophilia is not typical. Pneumocystis jirovecii pneumonia and community-acquired pneumonia are not usually associated with eosinophilia and are less likely.

Discuss (2) Improve

Next question

Pulmonary eosinophilia

Pulmonary eosinophilia describes a situation where there are increased numbers of eosinophils in the lung airways and parenchyma. This is generally associated with a blood eosinophilia.

Causes of pulmonary eosinophilia
- Churg-Strauss syndrome
- allergic bronchopulmonary aspergillosis (ABPA)
- Loffler's syndrome
- eosinophilic pneumonia
- hypereosinophilic syndrome
- tropical pulmonary eosinophilia
- drugs: nitrofurantoin, sulphonamides
- less common: Wegener's granulomatosis

Loffler's syndrome
- transient CXR shadowing and blood eosinophilia
- thought to be due to parasites such as *Ascaris lumbricoides* causing an alveolar reaction
- presents with a fever, cough and night sweats which often last for less than 2 weeks.
- generally a self-limiting disease

Acute eosinophilic pneumonia
- highly responsive to steroids

Tropical pulmonary eosinophilia
- associated with *Wuchereria bancrofti* infection

AI + Q 123

Next question

Textbooks

High-yield textbook

Extended textbook

Score: **20.4%**

1	✗
2	✗
3	✗
4	✗
5	✗
6	✗
7	✗
8	✗
9	✓
10	✓
11	✗
12	✗
13	✗
14	✓
15	✗
16	✓
17	✗
18	✗
19	✗
20	✗
21	✓

22	✓
23	✗
24	✗
25	✗
26	✗
27	✓
28	✗
29	✗
30	✓
31	✓
32	✗
33	✗
34	✗
35	✗
36	✗
37	✗
38	✗
39	✗
40	-
41	✗
42	✗
43	✗
44	✗
45	✓
46	✗
47	✗
48	✗
49	✗
50	✗
51	-

All contents of this site are © 2024 Passmedicine Limited

An 18-year-old-female is brought into the emergency room after having a tonic-clonic seizure. On examination she has a Glasgow coma scale of 11 (M4, E3, V4). Her blood pressure is 85/65 mmHg. Her heart rate is 135bpm and an ECG demonstrates atrial fibrillation. She has a past medical history of asthma which she takes betamethasone, salbutamol, salmeterol, montelukast and theophylline. She has recently started erythromycin for a chest infection. She has been taking 6g of paracetamol per day for the last 3 days for fever and chest discomfort.

You commence fluid resuscitation with 0.9% saline and treat the supraventricular tachycardia with a beta blocker.

You suspect theophylline toxicity and administer repeated doses of activated charcoal. However the patient continues to deteriorate.

What treatment is indicated?

- N-acetylcysteine (NAC)
- Sodium bicarbonate
- Flumazenil
- Hydroxocobalamin
- Intermittent haemodialysis or charcoal haemoperfusion

Submit answer

Reference ranges

Score: **24%**

1 ×

2	✗
3	✗
4	✗
5	✗
6	✗
7	✗
8	✗
9	✓
10	✓
11	✗
12	✗
13	✗
14	✓
15	✗
16	✓
17	✗
18	✗
19	✗
20	✗
21	✓
22	✓
23	✗
24	✗
25	✗
26	-
27	-
28	-
29	-
30	-
31	-
32	-
33	-
34	-
35	-
36	-
37	-
38	-

39	-
40	-
41	-
42	-
43	-
44	-
45	-

All contents of this site are © 2024 Passmedicine Limited

An 18-year-old-female is brought into the emergency room after having a tonic-clonic seizure. On examination she has a Glasgow coma scale of 11 (M4, E3, V4). Her blood pressure is 85/65 mmHg. Her heart rate is 135bpm and an ECG demonstrates atrial fibrillation. She has a past medical history of asthma which she takes betamethasone, salbutamol, salmeterol, montelukast and theophylline. She has recently started erythromycin for a chest infection. She has been taking 6g of paracetamol per day for the last 3 days for fever and chest discomfort.

You commence fluid resuscitation with 0.9% saline and treat the supraventricular tachycardia with a beta blocker.

You suspect theophylline toxicity and administer repeated doses of activated charcoal. However the patient continues to deteriorate.

What treatment is indicated?

N-acetylcysteine (NAC)	11%
Sodium bicarbonate	21%
Flumazenil	3%
Hydroxocobalamin	5%
Intermittent haemodialysis or charcoal haemoperfusion	61%

In cases of severe theophylline toxicity, charcoal haemoperfusion can be used

Important for me Less important

The patient has presented with several features of theophylline toxicity - seizures, reduced Glasgow coma score, and a tachyarrhythmia. The drug erythromycin which has recently been started, is an enzyme inhibitor which can precipitate theophylline toxicity.

The severity of symptoms warrants use of haemodialysis orcharcoal haemoperfusion.

Activated charcoal should also be considered. Since many products are slow release formulations, charcoal given more than 1 hour after ingestion may be of benefit. Repeated doses should also be administered.

Although the patient has been exceeding the maximum dose of paracetamol (4g / 24 hours), the clinical features are not in keeping with paracetamol toxicity.

Hydroxocobalamin is the antidote for cyanide poisoning.

Flumazenil is the antidote for benzodiazepine overdose.

Discuss (8) | Improve

Next question

Theophylline

Theophylline, like caffeine, is one of the naturally occurring methylxanthines. The main use of theophyllines in clinical medicine is as a bronchodilator in the management of asthma and COPD

The exact mechanism of action has yet to be discovered. One theory suggests theophyllines may be a non-specific inhibitor of phosphodiesterase resulting in an increase in cAMP. Other proposed mechanisms include antagonism of adenosine and prostaglandin inhibition

Theophylline poisoning

Features
- acidosis, hypokalaemia
- vomiting
- tachycardia, arrhythmias
- seizures

Management
- consider gastric lavage if <1 hour prior to ingestion
- activated charcoal
- whole-bowel irrigation can be performed if theophylline is sustained release form
- charcoal haemoperfusion is preferable to haemodialysis

AI + Q 123

Next question

Textbooks

High-yield textbook

Extended textbook

Score: **20.4%**

1	✗
2	✗
3	✗
4	✗
5	✗
6	✗
7	✗
8	✗
9	✓
10	✓
11	✗
12	✗
13	✗
14	✓
15	✗
16	✓
17	✗

18	✗
19	✗
20	✗
21	✓
22	✓
23	✗
24	✗
25	✗
26	✗
27	✓
28	✗
29	✗
30	✓
31	✓
32	✗
33	✗
34	✗
35	✗
36	✗
37	✗
38	✗
39	✗
40	-
41	✗
42	✗
43	✗
44	✗
45	✓
46	✗
47	✗
48	✗
49	✗
50	✗
51	-

All contents of this site are © 2024 Passmedicine Limited

A 35 year old chronic alcoholic male is admitted with severe epigastric pain. Laboratory investigations confirmed a significantly raised amylase. He is started on treatment for severe pancreatitis but his condition deteriorated over the next 2 days and he developed acute kidney injury with severe respiratory distress to an extent needing mechanical ventilation. Initial chest radiographs revealed widespread bilateral infiltrates. Which of the following therapies has been shown to most likely decrease overall mortality of ARDS?

- Immediate initiation of glucocorticoid therapy to limit inflammatory progression
- Placing patient in the prone position, allowing for greater recruitment of unaffected alveoli and improving PaO2/FiO2 ratio
- Implementing a low tidal volume ventilation protocol
- Changing from O2 to Nitric oxide at 5 ppm and titrating up until pt has an acceptable PaO2/FiO2 ratio
- Aggressive diuresis to reduce pulmonary edema and vascular congestion

Submit answer

Reference ranges

Score: **24%**

1 ✗
2 ✗
3 ✗
4 ✗
5 ✗
6 ✗

7	✗
8	✗
9	✓
10	✓
11	✗
12	✗
13	✗
14	✓
15	✗
16	✓
17	✗
18	✗
19	✗
20	✗
21	✓
22	✓
23	✗
24	✗
25	✗
26	-
27	-
28	-
29	-
30	-
31	-
32	-
33	-
34	-
35	-
36	-
37	-
38	-
39	-
40	-
41	-
42	-
43	-
44	-

45 -

46 -

All contents of this site are © 2024 Passmedicine Limited

A 35 year old chronic alcoholic male is admitted with severe epigastric pain. Laboratory investigations confirmed a significantly raised amylase. He is started on treatment for severe pancreatitis but his condition deteriorated over the next 2 days and he developed acute kidney injury with severe respiratory distress to an extent needing mechanical ventilation. Initial chest radiographs revealed widespread bilateral infiltrates. Which of the following therapies has been shown to most likely decrease overall mortality of ARDS?

Immediate initiation of glucocorticoid therapy to limit inflammatory progression	13%
Placing patient in the prone position, allowing for greater recruitment of unaffected alveoli and improving PaO2/FiO2 ratio	60%
Implementing a low tidal volume ventilation protocol	20%
Changing from O2 to Nitric oxide at 5 ppm and titrating up until pt has an acceptable PaO2/FiO2 ratio	4%
Aggressive diuresis to reduce pulmonary edema and vascular congestion	3%

Choice A - glucocorticoids to this point have not been shown to help patients in the acute phase of ARDS. There is some evidence that they may help in the fibroproliferative stage but not acutely

Choice B - While this is true, there is as of yet no good evidence showing improved overall mortality.

Choice C - ARDS causes severe hypoxaemia, almost always requiring invasive artificial ventilation. However, mechanical ventilation itself can injure the damaged lungs causing ventilation-induced lung injury. The main goal of treatment is to minimise any additional damage while maintaining adequate gas exchange. This has been effectively done by maintaining low tidal volume ventilation. A Cochrane Database review (1) and meta-analysis (2) suggest that a strategy of low tidal volume ventilation reduces the absolute mortality by about 7-9% as compared to using higher tidal volumes. This converts to a Number needed to treat (NNT) of between 11-15 people with ARDS to prevent one death by using low tidal volume ventilation.

Choice D - Nitric oxide does improve PaO2/FiO2 ratio but has not shown improved survival

Choice E - Since the infiltrate of ARDS is primarily inflammatory, diuretics are not particularly

effective. Overdiuresis also runs the risk of hemodynamic compromise, further decreasing the patient's already insufficient oxygen delivery to tissues.

References:

- 1 - Ventilation with lower tidal volumes versus traditional tidal volumes in adults for acute lung injury and acute respiratory distress syndrome. Cochrane Database Syst Rev. 2004;(2):CD003844. Petrucci N, Iacovelli W.
- 2 - Meta-analysis: ventilation strategies and outcomes of the acute respiratory distress syndrome and acute lung injury. Ann Intern Med. 2009 Oct 20;151(8):566-76. Putensen C, Theuerkauf N, Zinserling J, Wrigge H, Pelosi P.

Discuss (5) | Improve

Next question

Acute respiratory distress syndrome

Acute respiratory distress syndrome (ARDS) is caused by the increased permeability of alveolar capillaries leading to fluid accumulation in the alveoli, i.e. non-cardiogenic pulmonary oedema. It is a serious condition that has a mortality of around 40% and is associated with significant morbidity in those who survive.

Causes

- infection: sepsis, pneumonia
- massive blood transfusion
- trauma
- smoke inhalation
- acute pancreatitis
- Covid-19
- cardio-pulmonary bypass

Clinical features are typically of an acute onset and severe:

- dyspnoea
- elevated respiratory rate
- bilateral lung crackles
- low oxygen saturations

A chest x-ray and arterial blood gases are the key investigations.

Criteria (American-European Consensus Conference)

- acute onset (within 1 week of a known risk factor)
- pulmonary oedema: bilateral infiltrates on chest x-ray ('not fully explained by effusions, lobar/lung collapse or nodules)
- non-cardiogenic (pulmonary artery wedge pressure needed if doubt)
- $pO_2/FiO_2 < 40kPa$ (300 mmHg)

Management

- due to the severity of the condition patients are generally managed in ITU
- oxygenation/ventilation to treat the hypoxaemia
- general organ support e.g. vasopressors as needed
- treatment of the underlying cause e.g. antibiotics for sepsis
- certain strategies such as prone positioning and muscle relaxation have been shown to improve outcome in ARDS

+ Q 123

Next question >

Textbooks

High-yield textbook

Extended textbook

Links

Royal College of Physicians 6 6

2011 Acute lung injury review

Radiopaedia 13 4

Acute respiratory distress syndrome

Suggest link Report broken link

Media



Respiratory distress syndrome

Osmosis - YouTube 8 1

Report broken media

Score: **20.4%**

1	✗
2	✗
3	✗
4	✗
5	✗
6	✗
7	✗
8	✗
9	✓
10	✓
11	✗
12	✗
13	✗
14	✓
15	✗
16	✓
17	✗
18	✗
19	✗

20	✗
21	✓
22	✓
23	✗
24	✗
25	✗
26	✗
27	✓
28	✗
29	✗
30	✓
31	✓
32	✗
33	✗
34	✗
35	✗
36	✗
37	✗
38	✗
39	✗
40	-
41	✗
42	✗
43	✗
44	✗
45	✓
46	✗
47	✗
48	✗
49	✗
50	✗
51	-

All contents of this site are © 2024 Passmedicine Limited

Back to top

The x-ray below was taken from a 7-year-old child who presented to the Emergency Department with respiratory symptoms:

© Image used on license from Radiopaedia

What does the x-ray show?

- Cystic fibrosis
- Right upper lobe collapse
- Lung cancer
- Right-sided pneumothorax
- Normal

Submit answer

Reference ranges

Score: **24%**

1	✗
2	✗
3	✗
4	✗
5	✗
6	✗
7	✗
8	✗
9	✓
10	✓
11	✗
12	✗
13	✗
14	✓
15	✗
16	✓
17	✗
18	✗
19	✗
20	✗
21	✓
22	✓
23	✗
24	✗
25	✗
26	-
27	-
28	-
29	-
30	-
31	-

32	-
33	-
34	-
35	-
36	-
37	-
38	-
39	-
40	-
41	-
42	-
43	-
44	-
45	-
46	-
47	-

All contents of this site are © 2024 Passmedicine Limited
Back to top

The x-ray below was taken from a 7-year-old child who presented to the Emergency Department with respiratory symptoms:

© Image used on license from Radiopaedia

What does the x-ray show?

Cystic fibrosis	5%
Right upper lobe collapse	87%
Lung cancer	1%
Right-sided pneumothorax	2%
Normal	6%

There is increased opacity in the right upper zone, The lateral / inferior border of the shadowing actually represents the horizontal fissure which has been 'dragged' upwards.

Discuss (7) Improve

Next question

Chest x-ray: lobar collapse

Common causes of lobar collapse include:

- lung cancer (the most common cause in older adults)
- asthma (due to mucous plugging)
- foreign body

The general signs of lobar collapse on a chest x-ray are as follows:

- tracheal deviation towards the side of the collapse
- mediastinal shift towards the side of the collapse
- elevation of the hemidiaphragm

123

Next question

Textbooks

High-yield textbook

Extended textbook

Links

British Institute of Radiology 4 3

Unofficial guide to radiology

Suggest link

Report broken link

Media

Golden S sign - radiology video tutorial (x-ray)

Radiology Channel - YouTube 11 1

Report broken media

Score: **20.4%**

1	✗
2	✗
3	✗
4	✗
5	✗
6	✗
7	✗
8	✗
9	✓
10	✓
11	✗
12	✗
13	✗
14	✓
15	✗
16	✓
17	✗
18	✗
19	✗

20	✗
21	✓
22	✓
23	✗
24	✗
25	✗
26	✗
27	✓
28	✗
29	✗
30	✓
31	✓
32	✗
33	✗
34	✗
35	✗
36	✗
37	✗
38	✗
39	✗
40	-
41	✗
42	✗
43	✗
44	✗
45	✓
46	✗
47	✗
48	✗
49	✗
50	✗
51	-

All contents of this site are © 2024 Passmedicine Limited

A 56-year-old male presents with symptoms and signs consistent with exacerbation of chronic obstructive pulmonary disease (COPD). This is his fourth exacerbation in the last two months. His most recent FEV 1 is 40%. He is currently taking salbutamol as required once daily regimen.

On reviewing his peak flow diary you note a significant (> 20%) diurnal variation in his peak flow.

Which of the following drugs should be added next to his regular control of COPD?

- Combined salmeterol and fluticasone inhaler
- Salmeterol
- Theophylline
- Ipratropium bromide
- Long term oxygen therapy

Submit answer

Reference ranges

Score: **24%**

1	✕
2	✕
3	✕
4	✕
5	✕
6	✕
7	✕

8	✗
9	✓
10	✓
11	✗
12	✗
13	✗
14	✓
15	✗
16	✓
17	✗
18	✗
19	✗
20	✗
21	✓
22	✓
23	✗
24	✗
25	✗
26	-
27	-
28	-
29	-
30	-
31	-
32	-
33	-
34	-
35	-
36	-
37	-
38	-
39	-
40	-
41	-
42	-
43	-
44	-
45	-

46 -
47 -
48 -

All contents of this site are © 2024 Passmedicine Limited

Back to top

A 56-year-old male presents with symptoms and signs consistent with exacerbation of chronic obstructive pulmonary disease (COPD). This is his fourth exacerbation in the last two months. His most recent FEV 1 is 40%. He is currently taking salbutamol as required once daily regimen.

On reviewing his peak flow diary you note a significant (> 20%) diurnal variation in his peak flow.

Which of the following drugs should be added next to his regular control of COPD?

Combined salmeterol and fluticasone inhaler	89%
Salmeterol	4%
Theophylline	1%
Ipratropium bromide	5%
Long term oxygen therapy	1%

COPD - still breathless despite using SABA/SAMA and **asthma/steroid responsive features** → add a LABA + ICS

Important for me Less important

As this patient has a feature suggestive of asthma/steroid responsiveness (significant diurnal variation) the next step in management is a long-acting beta agonist (e.g. salmeterol) + an inhaled corticosteroid. NICE now recommend the use of combined inhalers where possible.

Discuss (5) Improve

Next question

COPD: stable management

NICE updated its guidelines on the management of chronic obstructive pulmonary disease (COPD) in 2018.

General management

- >smoking cessation advice: including offering nicotine replacement therapy, varenicline or bupropion
- annual influenza vaccination
- one-off pneumococcal vaccination
- pulmonary rehabilitation to all people who view themselves as functionally disabled by COPD (usually Medical Research Council [MRC] grade 3 and above)

Bronchodilator therapy

- a short-acting beta2-agonist (SABA) or short-acting muscarinic antagonist (SAMA) is first-line treatment
- for patients who remain breathless or have exacerbations despite using short-acting bronchodilators the next step is determined by whether the patient has '*asthmatic features/features suggesting steroid responsiveness*'

There are a number of criteria NICE suggest to determine whether a patient has asthmatic/steroid responsive features:

- any previous, secure diagnosis of asthma or of atopy
- a higher blood eosinophil count - note that NICE recommend a full blood count for all patients as part of the work-up
- substantial variation in FEV1 over time (at least 400 ml)
- substantial diurnal variation in peak expiratory flow (at least 20%)

Interestingly NICE do not recommend formal reversibility testing as one of the criteria. In the guidelines they state that '*routine spirometric reversibility testing is not necessary as part of the diagnostic process or to plan initial therapy with bronchodilators or corticosteroids. It may be unhelpful or misleading...*'. They then go on to discuss why they have reached this conclusion. Please see the guidelines for more details.

No asthmatic features/features suggesting steroid responsiveness

- add a long-acting beta2-agonist (LABA) + long-acting muscarinic antagonist (LAMA)
    - if already taking a SAMA, discontinue and switch to a SABA

Asthmatic features/features suggesting steroid responsiveness

- LABA + inhaled corticosteroid (ICS)
- if patients remain breathless or have exacerbations offer triple therapy i.e. LAMA + LABA + ICS
    - if already taking a SAMA, discontinue and switch to a SABA
- NICE recommend the use of combined inhalers where possible

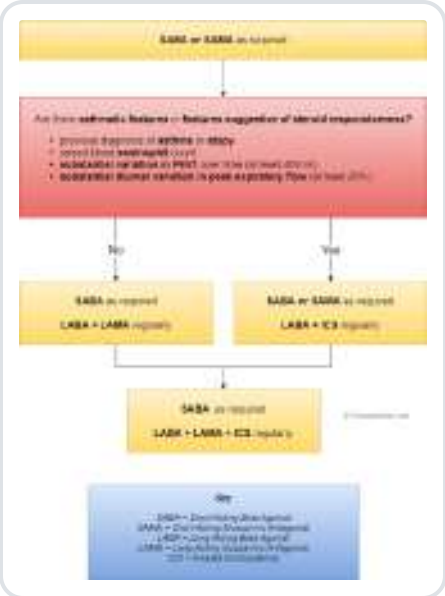

Oral theophylline

- NICE only recommends theophylline after trials of short and long-acting bronchodilators or to people who cannot used inhaled therapy
- the dose should be reduced if macrolide or fluoroquinolone antibiotics are co-prescribed

Oral prophylactic antibiotic therapy

- azithromycin prophylaxis is recommended in select patients
- patients should not smoke, have optimised standard treatments and continue to have exacerbations
- other prerequisites include a CT thorax (to exclude bronchiectasis) and sputum culture (to exclude atypical infections and tuberculosis)
- LFTs and an ECG to exclude QT prolongation should also be done as azithromycin can prolong the QT interval

Standby medication: NICE recommend offering a short course of oral corticosteroids and oral antibiotics to keep at home if: NICE

- have had an exacerbation within the last year
- understand how to take the medication, and are aware of associated risks and benefits
- know to when to seek help and when to ask for replacements once medication has been used

Mucolytics

- should be 'considered' in patients with a chronic productive cough and continued if symptoms improve

Phosphodiesterase-4 (PDE-4) inhibitors NICE

- oral PDE-4 inhibitors such as roflumilast reduce the risk of COPD exacerbations in patients with severe COPD and a history of frequent COPD exacerbations
- NICE recommend if:
  - the disease is severe, defined as a forced expiratory volume in 1 second (FEV1) after a bronchodilator of less than 50% of predicted normal, and
  - the person has had 2 or more exacerbations in the previous 12 months despite triple inhaled therapy with a long-acting muscarinic antagonist, a long-acting beta-2 agonist

and an inhaled corticosteroid

Cor pulmonale

- features include peripheral oedema, raised jugular venous pressure, systolic parasternal heave, loud P2
- use a loop diuretic for oedema, consider long-term oxygen therapy
- ACE-inhibitors, calcium channel blockers and alpha blockers are not recommended by NICE

Factors which may improve survival in patients with stable COPD

- smoking cessation - the single most important intervention in patients who are still smoking
- long term oxygen therapy in patients who fit criteria
- lung volume reduction surgery in selected patients

+ Q 123

Next question

Textbooks

High-yield textbook

Extended textbook

Links

Global Initiative for Chronic Obstructive Lung Disease 14 31

GOLD criteria 2017

NICE 33 29

2018 COPD guidelines

NICE 15 10

Roflumilast NICE recommendations

NICE 65 18

2018 COPD management diagram

Suggest link Report broken link

Media

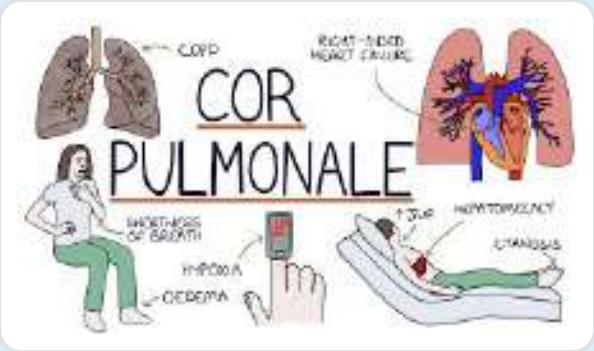

Cor pulmonale

Zero To Finals - YouTube 5 0

Chronic bronchitis

Osmosis - YouTube 3 0

Cor pulmonale

Osmosis - YouTube 1 0

Understanding COPD

Armando Hasudungan - YouTube 0 0

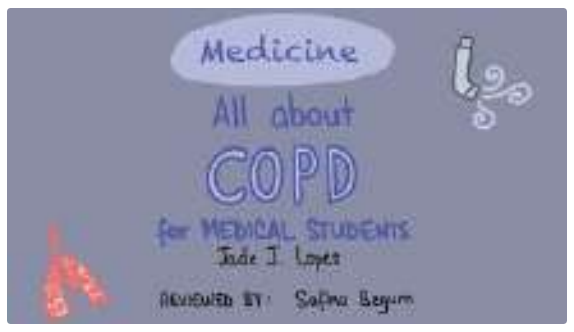

All about COPD (for Medical Students)

MedFlix - YouTube 3 1

Report broken media

Score: **20.4%**

1	✗
2	✗
3	✗
4	✗
5	✗
6	✗
7	✗
8	✗
9	✓
10	✓
11	✗
12	✗
13	✗
14	✓
15	✗
16	✓
17	✗
18	✗
19	✗
20	✗
21	✓
22	✓
23	✗

24	✗
25	✗
26	✗
27	✓
28	✗
29	✗
30	✓
31	✓
32	✗
33	✗
34	✗
35	✗
36	✗
37	✗
38	✗
39	✗
40	-
41	✗
42	✗
43	✗
44	✗
45	✓
46	✗
47	✗
48	✗
49	✗
50	✗
51	-

All contents of this site are © 2024 Passmedicine Limited

Back to top

A 22-year-old agricultural student presents to the respiratory clinic with cough, breathlessness, fatigue and weight loss of 2 kg in 6 weeks. Examination reveals bilateral wheeze and crackles. His GP has tried 2 courses of antibiotics and a salbutamol inhaler with no real benefit; he had some relief from a short course of oral prednisolone. He denies any fever, haemoptysis, foreign travel or exposure to TB. He has never smoked.

His chest radiograph shows mid to upper zone alveolar fine nodular shadowing bilaterally. His lung function shows a FVC (forced vital capacity) of 70% and FEV1/FVC of 85% predicted. Bloods show:

CRP	3 mg/l
ESR	45mm/hr

What is the most likely diagnosis?

- Pulmonary embolus (PE)
- Community acquired pneumonia
- Asthma
- Extrinsic allergic alveolitis
- Silicosis

Submit answer

Reference ranges

Score: **24%**

1 ×

2	✗
3	✗
4	✗
5	✗
6	✗
7	✗
8	✗
9	✓
10	✓
11	✗
12	✗
13	✗
14	✓
15	✗
16	✓
17	✗
18	✗
19	✗
20	✗
21	✓
22	✓
23	✗
24	✗
25	✗
26	-
27	-
28	-
29	-
30	-
31	-
32	-
33	-
34	-
35	-
36	-
37	-
38	-

39 -
40 -
41 -
42 -
43 -
44 -
45 -
46 -
47 -
48 -
49 -

All contents of this site are © 2024 Passmedicine Limited

A 22-year-old agricultural student presents to the respiratory clinic with cough, breathlessness, fatigue and weight loss of 2 kg in 6 weeks. Examination reveals bilateral wheeze and crackles. His GP has tried 2 courses of antibiotics and a salbutamol inhaler with no real benefit; he had some relief from a short course of oral prednisolone. He denies any fever, haemoptysis, foreign travel or exposure to TB. He has never smoked.

His chest radiograph shows mid to upper zone alveolar fine nodular shadowing bilaterally. His lung function shows a FVC (forced vital capacity) of 70% and FEV1/FVC of 85% predicted. Bloods show:

CRP	3 mg/l
ESR	45mm/hr

What is the most likely diagnosis?

- Pulmonary embolus (PE) 1%
- Community acquired pneumonia 0%
- Asthma 1%
- Extrinsic allergic alveolitis 88%
- Silicosis 9%

Extrinsic allergic alveolitis is associated with upper/mid zone lung fibrosis

Important for me Less important

Extrinsic allergic alveolitis is the most likely diagnosis in this agricultural student with a restrictive picture on spirometry. Extrinsic allergic alveolitis is caused by acute neutrophilic inflammation followed by lymphocytic infiltration & collagen deposition. Broncho alveolar lavage would show an excess of eosinophils. The presence of crepitations and wheeze make the diagnosis of PE less likely. Community acquired pneumonia would be associated with a higher CRP. Asthma would not cause a restrictive picture on spirometry. Silicosis is unlikely as there is no occupational exposure to silicon dioxide.

Discuss (5) Improve

Next question

Extrinsic allergic alveolitis

Extrinsic allergic alveolitis (EAA, also known as hypersensitivity pneumonitis) is a condition caused by hypersensitivity induced lung damage due to a variety of inhaled organic particles. It is thought to be largely caused by immune-complex mediated tissue damage (type III hypersensitivity) although delayed hypersensitivity (type IV) is also thought to play a role in EAA, especially in the chronic phase.

Examples
- bird fanciers' lung: avian proteins from bird droppings
- farmers lung: spores of *Saccharopolyspora rectivirgula* from wet hay (formerly *Micropolyspora faeni*)
- malt workers' lung: *Aspergillus clavatus*
- mushroom workers' lung: thermophilic actinomycetes*

Presentation
- acute (occurs 4-8 hrs after exposure)
  - dyspnoea
  - dry cough
  - fever
- chronic (occurs weeks-months after exposure)
  - lethargy
  - dyspnoea
  - productive cough
  - anorexia and weight loss

Investigation
- imaging: upper/mid-zone fibrosis
- bronchoalveolar lavage: lymphocytosis
- serologic assays for specific IgG antibodies
- blood: NO eosinophilia

Management
- avoid precipitating factors
- oral glucocorticoids

*here the terminology is slightly confusing as thermophilic actinomycetes is an umbrella term covering strains such as *Micropolyspora faeni*

© Image used on license from Radiopaedia

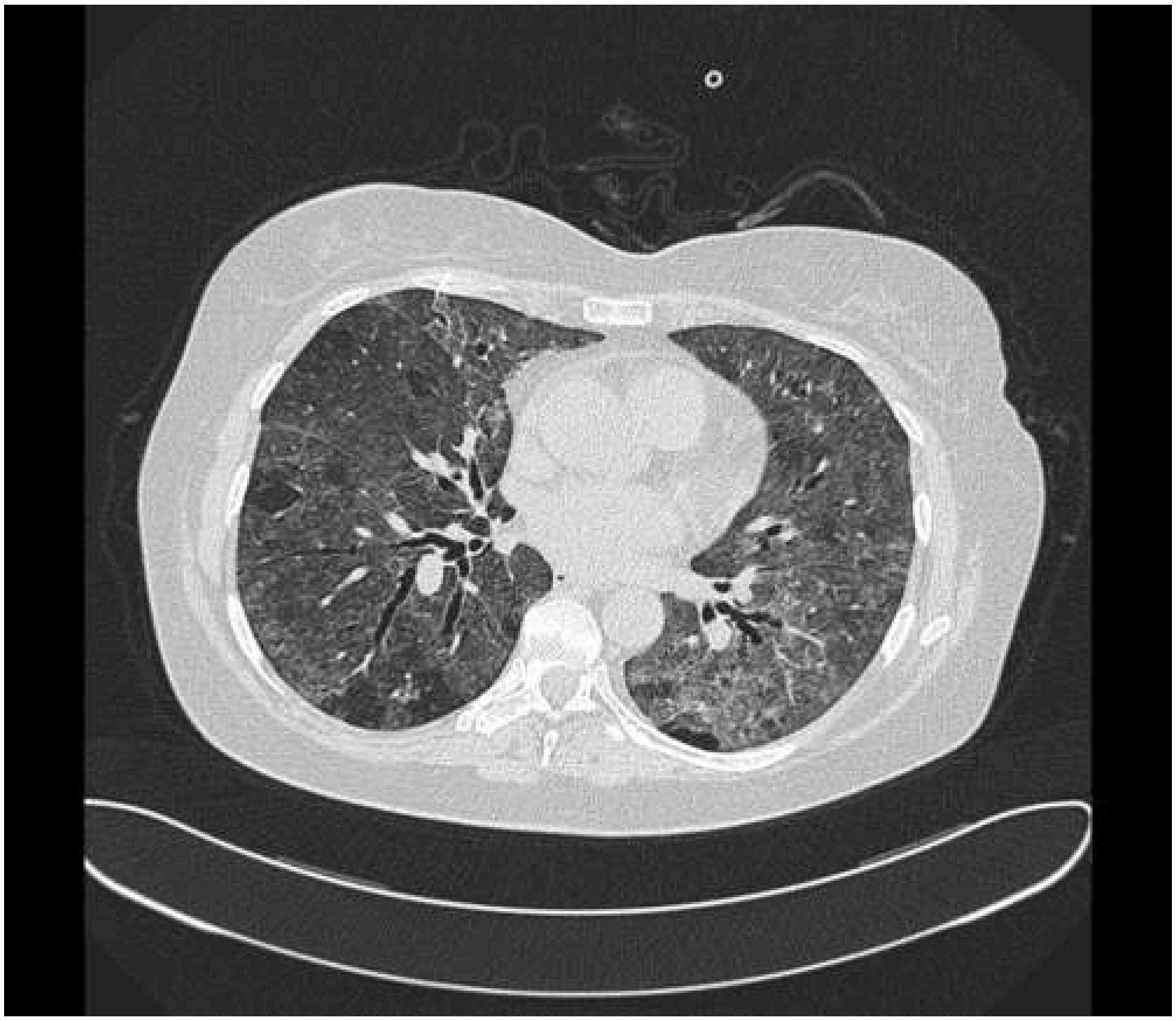

© Image used on license from Radiopaedia

Chest x-ray and CT scan from a middle-aged woman who presented with dyspnoea. The CT demonstrates multuple centrilobular ground glass nodules consistent with hypersensitivity pneumonitis

AI + Q 123

Next question >

Textbooks

High-yield textbook

Extended textbook

Media

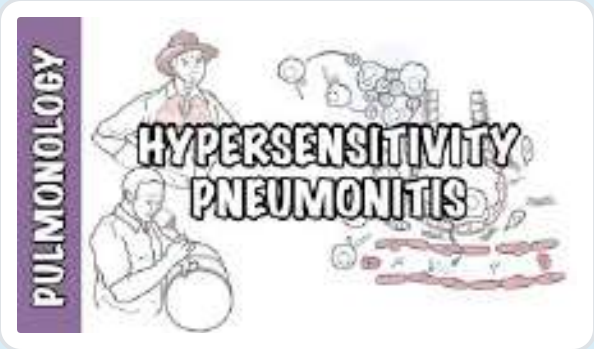

Hypersensitivity pneumonitis

Armando Hasudungan - YouTube 3 1

Report broken media

Score: **20.4%**

1 ✗

2	✗
3	✗
4	✗
5	✗
6	✗
7	✗
8	✗
9	✓
10	✓
11	✗
12	✗
13	✗
14	✓
15	✗
16	✓
17	✗
18	✗
19	✗
20	✗
21	✓
22	✓
23	✗
24	✗
25	✗
26	✗
27	✓
28	✗
29	✗
30	✓
31	✓
32	✗
33	✗
34	✗
35	✗
36	✗
37	✗

38	✗
39	✗
40	-
41	✗
42	✗
43	✗
44	✗
45	✓
46	✗
47	✗
48	✗
49	✗
50	✗
51	-

All contents of this site are © 2024 Passmedicine Limited

Back to top

A 53-year-old gentleman presents to the respiratory clinic for review. He has a history of chronic recurrent coughing episodes lasting for months. This has been worse over winters. He also has found that over the last two years his exercise tolerance has reduced and that he is more easily short of breath. He has no past medical history and takes no regular medications. He has a 20 pack-year history. He has undergone spirometry with shows an FEV1/FVC ratio of 63%, whilst FEV1 is 74% of predicted. His chest X-ray is unremarkable. Blood tests are normal as well. Previous sputum sample from during an exacerbation shows growth with pseudomonas. What factor is not in keeping with a diagnosis of COPD?

- FEV1/FVC ratio
- Pseudomonas
- FEV1
- Smoking history
- Clinical history

Submit answer

Reference ranges

Score: **24%**

1 ×
2 ×
3 ×
4 ×
5 ×
6 ×

7	✗
8	✗
9	✓
10	✓
11	✗
12	✗
13	✗
14	✓
15	✗
16	✓
17	✗
18	✗
19	✗
20	✗
21	✓
22	✓
23	✗
24	✗
25	✗
26	-
27	-
28	-
29	-
30	-
31	-
32	-
33	-
34	-
35	-
36	-
37	-
38	-
39	-
40	-
41	-
42	-
43	-
44	-

45	-
46	-
47	-
48	-
49	-
50	-

All contents of this site are © 2024 Passmedicine Limited

Back to top

A 53-year-old gentleman presents to the respiratory clinic for review. He has a history of chronic recurrent coughing episodes lasting for months. This has been worse over winters. He also has found that over the last two years his exercise tolerance has reduced and that he is more easily short of breath. He has no past medical history and takes no regular medications. He has a 20 pack-year history. He has undergone spirometry with shows an FEV1/FVC ratio of 63%, whilst FEV1 is 74% of predicted. His chest X-ray is unremarkable. Blood tests are normal as well. Previous sputum sample from during an exacerbation shows growth with pseudomonas. What factor is not in keeping with a diagnosis of COPD?

FEV1/FVC ratio	8%
Pseudomonas	44%
FEV1	29%
Smoking history	3%
Clinical history	16%

The correct answer is Pseudomonas. This is a patient with an otherwise straightforward diagnosis of COPD. COPD is an obstructive disease and therefore an FEV1/FVC ratio of 63% is matching, as does a low FEV1. Smoking is the main cause of COPD as well, and the history, describing winter bronchitis with a general decline in exercise tolerance fits COPD too. Pseudomonas is more common in bronchiectasis but may be a contaminant rather than a pathogen.

Discuss (4) Improve

Next question

COPD: investigation and diagnosis

NICE recommend considering a diagnosis of COPD in patients over 35 years of age who are smokers or ex-smokers and have symptoms such as exertional breathlessness, chronic cough or regular sputum production.

The following investigations are recommended in patients with suspected COPD:

- post-bronchodilator spirometry to demonstrate airflow obstruction: FEV1/FVC ratio less than 70%
- chest x-ray: hyperinflation, bullae, flat hemidiaphragm. Also important to exclude lung cancer
- full blood count: exclude secondary polycythaemia
- body mass index (BMI) calculation

The severity of COPD is categorised using the FEV1*:

Post-bronchodilator FEV1/FVC	**FEV1 (of predicted)**	**Severity**
< 0.7	> 80%	Stage 1 - Mild - symptoms should be present to diagnose COPD in these patients
< 0.7	50-79%	Stage 2 - Moderate
< 0.7	30-49%	Stage 3 - Severe
< 0.7	< 30%	Stage 4 - Very severe

Measuring peak expiratory flow is of limited value in COPD, as it may underestimate the degree of airflow obstruction.

*note that the grading system has changed following the 2010 NICE guidelines. If the FEV1 is greater than 80% predicted but the post-bronchodilator FEV1/FVC is < 0.7 then this is classified as Stage 1 - mild

123

Next question

Textbooks

High-yield textbook

Extended textbook

Links

NICE 9 8

2018 COPD guidelines

Suggest link Report broken link

Media

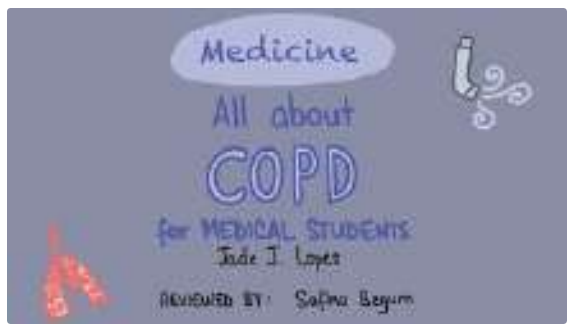

All about COPD (for Medical Students)

MedFlix - YouTube 1 0

Peak Flow and Spirometry - Lung Function Tests

Oxford Medical Education - YouTube 1 2

Report broken media

Score: **20.4%**

1 ✗
2 ✗
3 ✗
4 ✗

5	✗
6	✗
7	✗
8	✗
9	✓
10	✓
11	✗
12	✗
13	✗
14	✓
15	✗
16	✓
17	✗
18	✗
19	✗
20	✗
21	✓
22	✓
23	✗
24	✗
25	✗
26	✗
27	✓
28	✗
29	✗
30	✓
31	✓
32	✗
33	✗
34	✗
35	✗
36	✗
37	✗
38	✗
39	✗
40	-

41	✗
42	✗
43	✗
44	✗
45	✓
46	✗
47	✗
48	✗
49	✗
50	✗
51	-

All contents of this site are © 2024 Passmedicine Limited

A 66-year-old retired farmer presents with a 4-week history of increasing shortness of breath, non-specific non-pleuritic chest pain and weight loss. His past medical history includes previous angina, for which he was previously prescribed a GTN spray that he has not required for 3 years and hypertension. He is known to keep racing pigeons in a barn on his property. He keeps active and lives with his wife, drinks moderate amount of alcohol and is an active smoker with a 40 pack year history. He has no known allergies. On examination, you note bilateral clubbing and tar staining. Respiratory examination revealed a respiratory rate of 19 breaths per minute, sats 94% on air, reduced bilateral chest expansion and reduced air entry in both bases associated with dullness to percussion.

A chest radiograph demonstrates moderate right >left bilateral pleural effusions and patchy opacities across both lung fields in a non-lobar distribution. CT thorax with high-resolution slices demonstrates bilateral pleural effusion, thickened pleura with no lung parenchyma abnormalities.

Lung function testing demonstrates FEV1 1.7ls, FVC 55% of predicted.

What is the most appropriate next investigation?

- CT chest/abdomen/pelvis with contrast
- High resolution CT chest (HRCT)
- Video assisted thoracoscopic biopsy (VATS)
- Chest drain
- Bronchoscopy with bronchoalveolar lavage (BAL)

Submit answer

Reference ranges

Score: **20.4%**

1	✗
2	✗
3	✗
4	✗
5	✗
6	✗
7	✗
8	✗
9	✓
10	✓
11	✗
12	✗
13	✗
14	✓
15	✗
16	✓
17	✗
18	✗
19	✗
20	✗
21	✓
22	✓
23	✗
24	✗
25	✗
26	✗
27	✓
28	✗
29	✗
30	✓
31	✓
32	✗
33	✗
34	✗

35	✗
36	✗
37	✗
38	✗
39	✗
40	-
41	✗
42	✗
43	✗
44	✗
45	✓
46	✗
47	✗
48	✗
49	✗
50	✗
51	-

All contents of this site are © 2024 Passmedicine Limited

A 66-year-old retired farmer presents with a 4-week history of increasing shortness of breath, non-specific non-pleuritic chest pain and weight loss. His past medical history includes previous angina, for which he was previously prescribed a GTN spray that he has not required for 3 years and hypertension. He is known to keep racing pigeons in a barn on his property. He keeps active and lives with his wife, drinks moderate amount of alcohol and is an active smoker with a 40 pack year history. He has no known allergies. On examination, you note bilateral clubbing and tar staining. Respiratory examination revealed a respiratory rate of 19 breaths per minute, sats 94% on air, reduced bilateral chest expansion and reduced air entry in both bases associated with dullness to percussion.

A chest radiograph demonstrates moderate right >left bilateral pleural effusions and patchy opacities across both lung fields in a non-lobar distribution. CT thorax with high-resolution slices demonstrates bilateral pleural effusion, thickened pleura with no lung parenchyma abnormalities.

Lung function testing demonstrates FEV1 1.7ls, FVC 55% of predicted.

What is the most appropriate next investigation?

CT chest/abdomen/pelvis with contrast	11%
High resolution CT chest (HRCT)	23%
Video assisted thoracoscopic biopsy (VATS)	32%
Chest drain	11%
Bronchoscopy with bronchoalveolar lavage (BAL)	23%

An underlying pleural pathology should be strongly suspected in the case of thickened pleura, restrictive lung function and non-specific constitutional symptoms. The bilateral pleural effusions do not appear to be causing respiratory compromise and hence a chest drain is not indicated. In the absence of parenchymal lesions to target for tissue diagnosis, VATS is appropriate to differentiate pleural thickening described between organised empyema or mesothelioma, and also to obtain tissue to differentiate mesothelioma from other primary or metastatic cancers. VATS is optimally performed with a small amount of pleural fluid in situ.

A diagnosis of extrinsic allergic alveolitis (EAA) should also be considered as presentations with

weight loss, dyspnoea and chest tightness can be similar to pleural pathology. BAL would be indicated if EAA is a significant differential. However, the lack of reticulonodular changes on chest radiograph and fibrotic changes on CT make hypersensitivity pneumonitis less likely. Be aware that only 20% of mesothelioma patients present with radiographic changes consistent with asbestosis, although the majority present with pleural abnormalities.

Discuss (16) | Improve

Next question

Pleural effusion: investigation and management

The British Thoracic Society (BTS) produced guidelines in 2010 covering the investigation of patients with a pleural effusion.

Imaging

- posterioranterior (PA) chest x-rays should be performed in all patients
- ultrasound is recommended: it increases the likelihood of successful pleural aspiration and is sensitive for detecting pleural fluid septations
- contrast CT is now increasingly performed to investigate the underlying cause, particularly for exudative effusions

Pleural aspiration

- as above, ultrasound is recommended to reduce the complication rate
- a 21G needle and 50ml syringe should be used
- fluid should be sent for pH, protein, lactate dehydrogenase (LDH), cytology and microbiology

Light's criteria was developed in 1972 to help distinguish between a transudate and an exudate. The BTS recommend using the criteria for borderline cases:

- exudates have a protein level of >30 g/L, transudates have a protein level of <30 g/L
- if the protein level is between 25-35 g/L, Light's criteria should be applied. An exudate is likely if at least one of the following criteria are met:
  - pleural fluid protein divided by serum protein >0.5

    - pleural fluid LDH divided by serum LDH >0.6
    - pleural fluid LDH more than two-thirds the upper limits of normal serum LDH

Other characteristic pleural fluid findings:

- low glucose: rheumatoid arthritis, tuberculosis
- raised amylase: pancreatitis, oesophageal perforation
- heavy blood staining: mesothelioma, pulmonary embolism, tuberculosis

Pleural infection

All patients with a pleural effusion in association with sepsis or a pneumonic illness require diagnostic pleural fluid sampling

- if the fluid is purulent or turbid/cloudy a chest tube should be placed to allow drainage
- if the fluid is clear but the **pH is less than 7.2 in patients with suspected pleural infection a chest tube should be placed**

Management of recurrent pleural effusion

Options for managing patients with recurrent pleural effusions include:

- recurrent aspiration
- pleurodesis
- indwelling pleural catheter
- drug management to alleviate symptoms e.g. opioids to relieve dyspnoea

AI + Q 123

Next question >

Textbooks

High-yield textbook

Extended textbook

Links

British Thoracic Society 17 14

2023 Pleural disease guidelines

Royal College of Physicians 13 7

2012 Pleural infection review

Suggest link Report broken link

Media

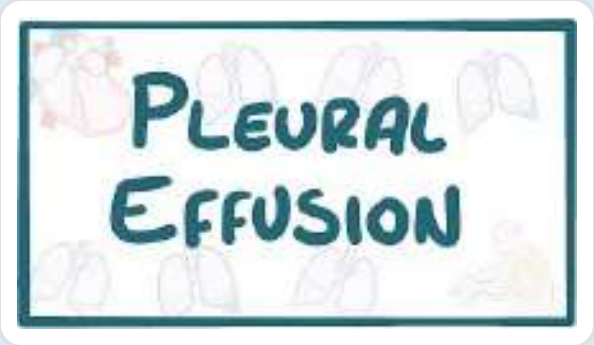

Pleural effusion

Osmosis - YouTube 8 1

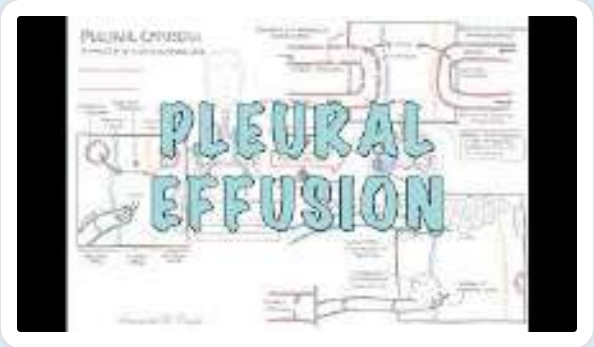

Pleural effusion

Armando Hasudungan - YouTube 6 1

Report broken media

Score: **17.8%**

1 ×

2	✗
3	✗
4	✗
5	✗
6	✗
7	✗
8	✗
9	✓
10	✓
11	✗
12	✗
13	✗
14	✓
15	✗
16	✓
17	✗
18	✗
19	✗
20	✗
21	✓
22	✓
23	✗
24	✗
25	✗
26	✗
27	✓
28	✗
29	✗
30	✓
31	✓
32	✗
33	✗
34	✗
35	✗
36	✗
37	✗

38	✗
39	✗
40	-
41	✗
42	✗
43	✗
44	✗
45	✓
46	✗
47	✗
48	✗
49	✗
50	✗
51	✗
52	✗
53	✗
54	✗
55	✗
56	✗
57	✗
58	✗
59	✗
60	✗
61	✗
62	✗
63	✗
64	✗
65	✗
66	✗
67	✓
68	✗
69	✓
70	✗
71	✗
72	✓
73	✗

74	✕
75	-

All contents of this site are © 2024 Passmedicine Limited

A 72 year-old woman has been referred to the chest clinic by her General Practitioner (GP). The patient describes a 3-year history of cough and progressive shortness of breath. Over the past 3 years the GP had prescribed numerous courses of antibiotics and steroids but these had had little benefit. She was a non-smoker, did not drink alcohol and was on no regular medications. The cough was productive of purulent sputum with occasional streaks of blood. There was no history of weight loss or fever, but the patient did note lethargy. The rest of her family were well and the only medical history of note was an episode of pneumonia as a child.

Respiratory examination revealed bilateral crackles but no other added sounds. You note that the patient was not clubbed.

A chest x-ray, organised by the GP, shows minor bilateral atelectasis and opacities.

What is the most appropriate diagnostic test?

- Bronchoscopy
- Genetic testing for Primary Ciliary Dyskinesia
- High resolution CT scan of chest
- Serum α1-antitrypsin level
- Tuberculin skin test

Submit answer

Reference ranges

Score: **20.4%**

1 ✕

2	✗
3	✗
4	✗
5	✗
6	✗
7	✗
8	✗
9	✓
10	✓
11	✗
12	✗
13	✗
14	✓
15	✗
16	✓
17	✗
18	✗
19	✗
20	✗
21	✓
22	✓
23	✗
24	✗
25	✗
26	✗
27	✓
28	✗
29	✗
30	✓
31	✓
32	✗
33	✗
34	✗
35	✗
36	✗
37	✗

38	✗
39	✗
40	-
41	✗
42	✗
43	✗
44	✗
45	✓
46	✗
47	✗
48	✗
49	✗
50	✗
51	-
52	-

All contents of this site are © 2024 Passmedicine Limited

Back to top

A 72 year-old woman has been referred to the chest clinic by her General Practitioner (GP). The patient describes a 3-year history of cough and progressive shortness of breath. Over the past 3 years the GP had prescribed numerous courses of antibiotics and steroids but these had had little benefit. She was a non-smoker, did not drink alcohol and was on no regular medications. The cough was productive of purulent sputum with occasional streaks of blood. There was no history of weight loss or fever, but the patient did note lethargy. The rest of her family were well and the only medical history of note was an episode of pneumonia as a child.

Respiratory examination revealed bilateral crackles but no other added sounds. You note that the patient was not clubbed.

A chest x-ray, organised by the GP, shows minor bilateral atelectasis and opacities.

What is the most appropriate diagnostic test?

Bronchoscopy	5%
Genetic testing for Primary Ciliary Dyskinesia	6%
High resolution CT scan of chest	77%
Serum α1-antitrypsin level	10%
Tuberculin skin test	3%

The history is highly suggestive of bronchiectasis, which often presents as a lower respiratory tract infection with a productive cough. Patents may also present with haemoptysis, chest pain and shortness of breath. Over time the condition can progress to respiratory failure.

The most common findings on examination are crackles (75%) and wheeze (22%). Clubbing is only found in 2%.

A chest x-ray should be performed in all suspected cases and, indeed, anyone presenting with a chronic cough. In some cases a suggestive history and chest x-ray will be enough to diagnose bronchiectasis. However, the best diagnostic test for bronchiectasis is high-resolution CT scan (HRCT). A HRCT will show the classic features of bronchial wall thickening and dilatation, it may also demonstrate features that suggest a cause for the underlying cause, e.g. allergic

bronchopulmonary aspergillosis (ABPA) of cystic fibrosis (CF).

The routine work up for patients with suspected bronchiectasis should include bloods for serum immunoglobulins and protein electrophoresis, total IgE and skin prick testing or serum IgE testing to Aspergillus species. Bronchoscopy is not performed routinely unless there is a suspicion of a lesion or foreign body. α1-Antitrypsin levels are not routinely requested but may be of help if the HRCT shows evidence of emphysema. A tuberculin skin test is very unlikely to be helpful in a patient of this age and is not the test of choice. Tuberculin skin tests can identify cases of latent tuberculosis but must be interpreted with the patients immunisation history.

Genetic testing, although potentially diagnostic, would not be appropriate in this case. Primary Ciliary Dyskinesia is an autosomal recessive disorder that can cause bronchiesctasis but patients usually present as newborns or in childhood and not in the elderly.

Discuss (2) Improve

Next question

Bronchiectasis: causes

Bronchiectasis describes a permanent dilatation of the airways secondary to chronic infection or inflammation. There are a wide variety of causes are listed below:

Causes
- post-infective: tuberculosis, measles, pertussis, pneumonia
- cystic fibrosis
- bronchial obstruction e.g. lung cancer/foreign body
- immune deficiency: selective IgA, hypogammaglobulinaemia
- allergic bronchopulmonary aspergillosis (ABPA)
- ciliary dyskinetic syndromes: Kartagener's syndrome, Young's syndrome
- yellow nail syndrome

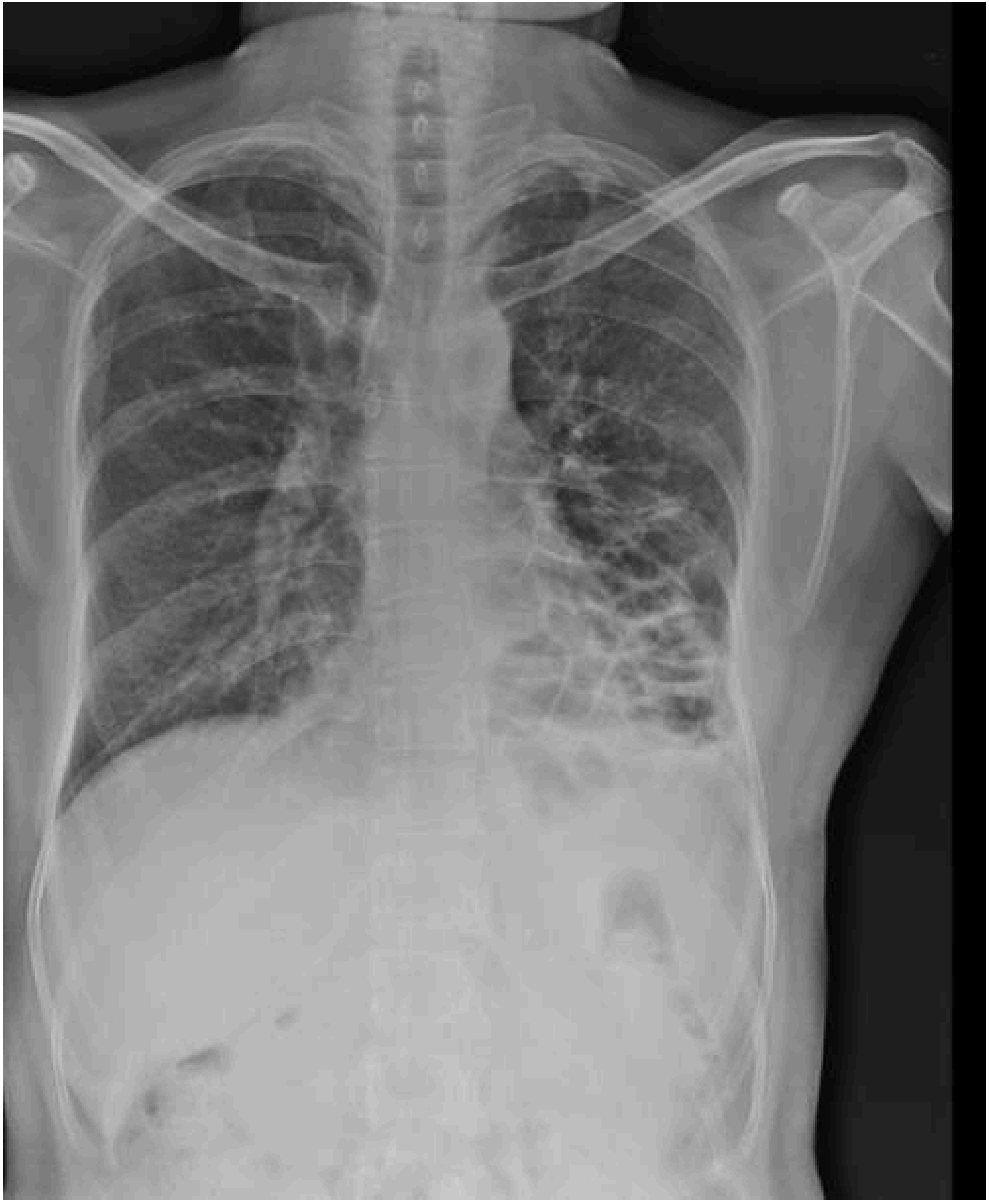

© Image used on license from Radiopaedia

Chest x-ray showing tramlines, most prominent in the left lower zone

© Image used on license from Radiopaedia

CT chest showing widespread tram-track and signet ring signs

123

Next question

Textbooks

High-yield textbook

Extended textbook

Links

British Thoracic Society 2 1

2018 Bronchiectasis guidelines

Suggest link

Report broken link

Media

Bronchiectasis - causes, pathophysiology, signs and symptoms, investigations and treatment

Armando Hasudungan - YouTube 3 0

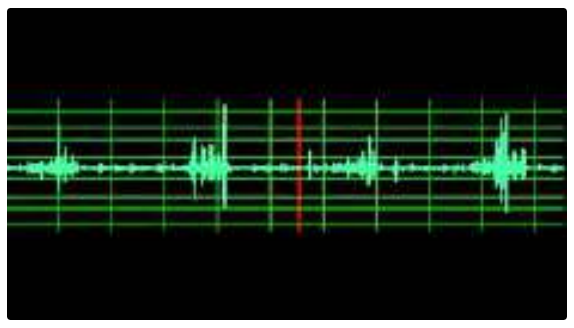

Bronchiectasis crackles - REQUIRES HEADPHONES

Thinklabs - YouTube 3 1

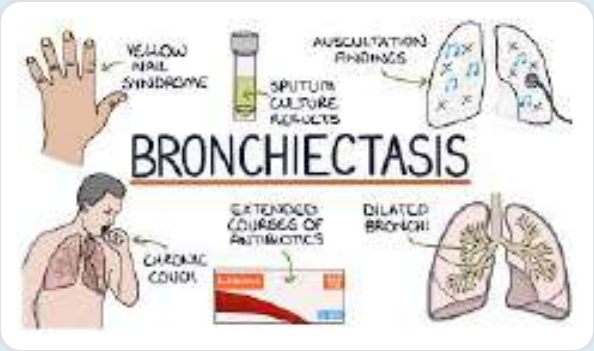

Bronchiectasis

Zero To Finals - YouTube 0 2

Report broken media

Score: **17.8%**

1 ✗
2 ✗
3 ✗
4 ✗
5 ✗
6 ✗
7 ✗
8 ✗
9 ✓
10 ✓
11 ✗
12 ✗
13 ✗
14 ✓
15 ✗
16 ✓
17 ✗
18 ✗
19 ✗
20 ✗
21 ✓

22	✓
23	✗
24	✗
25	✗
26	✗
27	✓
28	✗
29	✗
30	✓
31	✓
32	✗
33	✗
34	✗
35	✗
36	✗
37	✗
38	✗
39	✗
40	-
41	✗
42	✗
43	✗
44	✗
45	✓
46	✗
47	✗
48	✗
49	✗
50	✗
51	✗
52	✗
53	✗
54	✗
55	✗
56	✗
57	✗

58	✗
59	✗
60	✗
61	✗
62	✗
63	✗
64	✗
65	✗
66	✗
67	✓
68	✗
69	✓
70	✗
71	✗
72	✓
73	✗
74	✗
75	-

All contents of this site are © 2024 Passmedicine Limited

A 30 year old gentleman returns from a camping holiday in the Nile Delta with nocturnal wheeziness and dry cough, weight loss, and fever. He recalls multiple mosquito bites. Chest X-ray demonstrates pulmonary infiltrates. His blood results are shown below.

Hb	14 g/dl
Platelets	385 * 10^9/l
WBC	14 * 10^9/l
Neutrophils	7.5 * 10^9/l (reference range 2.0-7.5 * 10^9/l)
Eosinophils	1.2 * 10^9/l (reference range 0.04-0.44 * 10^9/l)

Serum IgG	90 mg/dl (reference range 80 - 350 mg/dl)
Serum IgM	200 mg/dl (reference range 45 - 250 mg/dl)
Serum IgE	6.0 mg/dl (reference range 0.002 - 0.2 mg/dl)

Given the likely diagnosis which of the following treatments will be most effective?

- Antiretrovirals
- Tazocin
- Steroids
- Diethylcarbamazine
- Quinine

Submit answer

Reference ranges

Score: **20.4%**

1	✗
2	✗
3	✗
4	✗
5	✗
6	✗
7	✗
8	✗
9	✓
10	✓
11	✗
12	✗
13	✗
14	✓
15	✗
16	✓
17	✗
18	✗
19	✗
20	✗
21	✓
22	✓
23	✗
24	✗
25	✗
26	✗
27	✓
28	✗
29	✗
30	✓
31	✓
32	✗
33	✗
34	✗

35	✗
36	✗
37	✗
38	✗
39	✗
40	-
41	✗
42	✗
43	✗
44	✗
45	✓
46	✗
47	✗
48	✗
49	✗
50	✗
51	-
52	-
53	-

All contents of this site are © 2024 Passmedicine Limited

Back to top

A 30 year old gentleman returns from a camping holiday in the Nile Delta with nocturnal wheeziness and dry cough, weight loss, and fever. He recalls multiple mosquito bites. Chest X-ray demonstrates pulmonary infiltrates. His blood results are shown below.

Hb	14 g/dl
Platelets	385 * 10^9/l
WBC	14 * 10^9/l
Neutrophils	7.5 * 10^9/l (reference range 2.0-7.5 * 10^9/l)
Eosinophils	1.2 * 10^9/l (reference range 0.04-0.44 * 10^9/l)

Serum IgG	90 mg/dl (reference range 80 - 350 mg/dl)
Serum IgM	200 mg/dl (reference range 45 - 250 mg/dl)
Serum IgE	6.0 mg/dl (reference range 0.002 - 0.2 mg/dl)

Given the likely diagnosis which of the following treatments will be most effective?

Antiretrovirals	2%
Tazocin	1%
Steroids	44%
Diethylcarbamazine	45%
Quinine	8%

The diagnosis here is tropical pulmonary eosinophilia. HIV and indeed plasmodium falcipirum malaria could present with fever and weight loss however the blood picture along with wheeze is suggestive of an eosinophilic lung disease. The eosinophilic lung diseases are allergic reactions to some environmental toxin and all present with cough, wheeze, pulmonary infiltrates on chest X-ray, raised serum IgE, and a raised eosinophil count. They are a differential for asthma, which can present in a similar fashion clinically and on bloods, and therefore a careful history (particularly travel and medications) is important. It is important to recognise them as the management is different to asthma. Here are some examples worth knowing for the exam:

Allergic bronchopulmonary aspergillosis: an allergic reaction to the fungus aspergillus fumigates. The course is characterised by recurrent episodes of eosinophilic pneumonia, especially in the autumn and winter. Test for precipitating antibodies to Aspergillus species, which will be present in 90% of cases. Also order sputum microscopy and culture, which can show fungal spores or hyphae. A skin-prick test can be ordered and almost always positive to Aspergillus fumigates. Management is with steroids.

Simple pulmonary eosinophilia, aka Loeffler's syndrome. This is caused by Ascaris lumbricoides, Strongyloides, or Ancylostoma. Infection with these worms is prevalent worldwide, especially in tropical and subtropical countries. Their eggs are passed in the stool of an infected person and then ingestion in food that has had contact with human sewage (they are surprising resilient eggs). The ingested eggs mature into larval worms in the gut and seed into the blood stream via the duodenal walls, from where they circulate around in the blood to eventually enter the lungs were they are coughed up (the pulmonary eosinophilia phase with wheeze and cough for around 2 weeks) and then swallowed back down and settle into mature worms in the small intestine, resulting in a chronic malabsorption condition. The pulmonary condition is self-limmiting although mebendazole given for 3 days can help.

Tropical pulmonary eosinophilia: caused by the roundworms Wuchereria bancrofti or Brugia malayi, common in the Asian Subcontinent and Africa. The worms are spread via a mosquito vector. It takes a human blood meal and thereby ingests microfilariae (worm-like sheathed eggs) from an infected patient and deposits them into a new host. They spread through the blood to settle in the lymphatics where they mature into adults and reside there for 15 or more years, reproducing sexually, and causing elephantiasis. The pulmonary involvement happens as there is intense inflammation of lung parenchyma to microfilariae which are periodically released into the circulation by those adult worms. There is therefore a history of paroxysmal nocturnal cough, wheeze, and breathlessness. Diagnosis is aided by a clinical response to diethylcarbamazine, which is also the main treatment.

Churg-Strauss syndrome: a pANCA positive small to medium vessel vasculitis that presents with a refractory asthma type of picture, mononeurtitis multiplex (look out for e.g foot drop in a stem that sounds like asthma), and sinusitis. Biopsy of affected tissue is helpful diagnostically. Management is largely with steroids but can progress to the need for steroid-sparing agents such as cyclophosphamide/azathioprine.

Drugs-induced pulmonary eosinophilia: sulphonamides (e.g. sulfasalazine), nitrofurantoin, penicillin, tetracycline. Stop the offending drug.

Discuss (8) | Improve

Next question >

Pulmonary eosinophilia

Pulmonary eosinophilia describes a situation where there are increased numbers of eosinophils in the lung airways and parenchyma. This is generally associated with a blood eosinophilia.

Causes of pulmonary eosinophilia

- Churg-Strauss syndrome
- allergic bronchopulmonary aspergillosis (ABPA)
- Loffler's syndrome
- eosinophilic pneumonia
- hypereosinophilic syndrome
- tropical pulmonary eosinophilia
- drugs: nitrofurantoin, sulphonamides
- less common: Wegener's granulomatosis

Loffler's syndrome

- transient CXR shadowing and blood eosinophilia
- thought to be due to parasites such as *Ascaris lumbricoides* causing an alveolar reaction
- presents with a fever, cough and night sweats which often last for less than 2 weeks.
- generally a self-limiting disease

Acute eosinophilic pneumonia

- highly responsive to steroids

Tropical pulmonary eosinophilia

- associated with *Wuchereria bancrofti* infection

AI + Q 123

Next question >

Textbooks

High-yield textbook

Extended textbook

Score: **17.8%**

1	✗
2	✗
3	✗
4	✗
5	✗
6	✗
7	✗
8	✗
9	✓
10	✓
11	✗
12	✗
13	✗
14	✓
15	✗
16	✓
17	✗
18	✗
19	✗
20	✗
21	✓
22	✓
23	✗
24	✗

25	✗
26	✗
27	✓
28	✗
29	✗
30	✓
31	✓
32	✗
33	✗
34	✗
35	✗
36	✗
37	✗
38	✗
39	✗
40	-
41	✗
42	✗
43	✗
44	✗
45	✓
46	✗
47	✗
48	✗
49	✗
50	✗
51	✗
52	✗
53	✗
54	✗
55	✗
56	✗
57	✗
58	✗
59	✗
60	✗

61	✗
62	✗
63	✗
64	✗
65	✗
66	✗
67	✓
68	✗
69	✓
70	✗
71	✗
72	✓
73	✗
74	✗
75	-

All contents of this site are © 2024 Passmedicine Limited

Back to top

A 46-year-old man presents with a persistent cough. This has been present for around 2 months and is productive of yellow-green sputum. He feels more short-of-breath on exertion but is experiencing chest pain. He has not lost any weight and has not coughed up blood.

He has a 25-pack-year history of smoking although is trying to give up. He does not drink alcohol.

On examination his respiratory rate is 18/min, heart rate 84/min, blood pressure 114/72 mmHg and temperature 37.3ºC. His oxygen saturations on room air are 96%. Scattered crackles are heard in both bases.

A chest x-ray is requested:

© Image used on license from Radiopaedia

What is the most likely diagnosis?

- Pneumonia
- Sarcoidosis
- Chronic obstructive pulmonary disease
- Bronchiectasis
- Pulmonary fibrosis

Submit answer

Reference ranges

Score: **20.4%**

1	✗
2	✗
3	✗
4	✗
5	✗
6	✗
7	✗
8	✗
9	✓
10	✓
11	✗
12	✗
13	✗
14	✓
15	✗

16	✓
17	✗
18	✗
19	✗
20	✗
21	✓
22	✓
23	✗
24	✗
25	✗
26	✗
27	✓
28	✗
29	✗
30	✓
31	✓
32	✗
33	✗
34	✗
35	✗
36	✗
37	✗
38	✗
39	✗
40	-
41	✗
42	✗
43	✗
44	✗
45	✓
46	✗
47	✗
48	✗
49	✗
50	✗
51	-

52 -
53 -
54 -

All contents of this site are © 2024 Passmedicine Limited

A 46-year-old man presents with a persistent cough. This has been present for around 2 months and is productive of yellow-green sputum. He feels more short-of-breath on exertion but is experiencing chest pain. He has not lost any weight and has not coughed up blood.

He has a 25-pack-year history of smoking although is trying to give up. He does not drink alcohol.

On examination his respiratory rate is 18/min, heart rate 84/min, blood pressure 114/72 mmHg and temperature 37.3ºC. His oxygen saturations on room air are 96%. Scattered crackles are heard in both bases.

A chest x-ray is requested:

© Image used on license from Radiopaedia

What is the most likely diagnosis?

Pneumonia	3%
Sarcoidosis	3%
Chronic obstructive pulmonary disease	5%
Bronchiectasis	76%
Pulmonary fibrosis	13%

The chest x-ray has classical changes of bronchiectasis - tramlines are seen, most prominently in the left lower zone.

Discuss (6) Improve

Next question

Bronchiectasis: causes

Bronchiectasis describes a permanent dilatation of the airways secondary to chronic infection or inflammation. There are a wide variety of causes are listed below:

Causes

- post-infective: tuberculosis, measles, pertussis, pneumonia
- cystic fibrosis
- bronchial obstruction e.g. lung cancer/foreign body
- immune deficiency: selective IgA, hypogammaglobulinaemia
- allergic bronchopulmonary aspergillosis (ABPA)
- ciliary dyskinetic syndromes: Kartagener's syndrome, Young's syndrome
- yellow nail syndrome

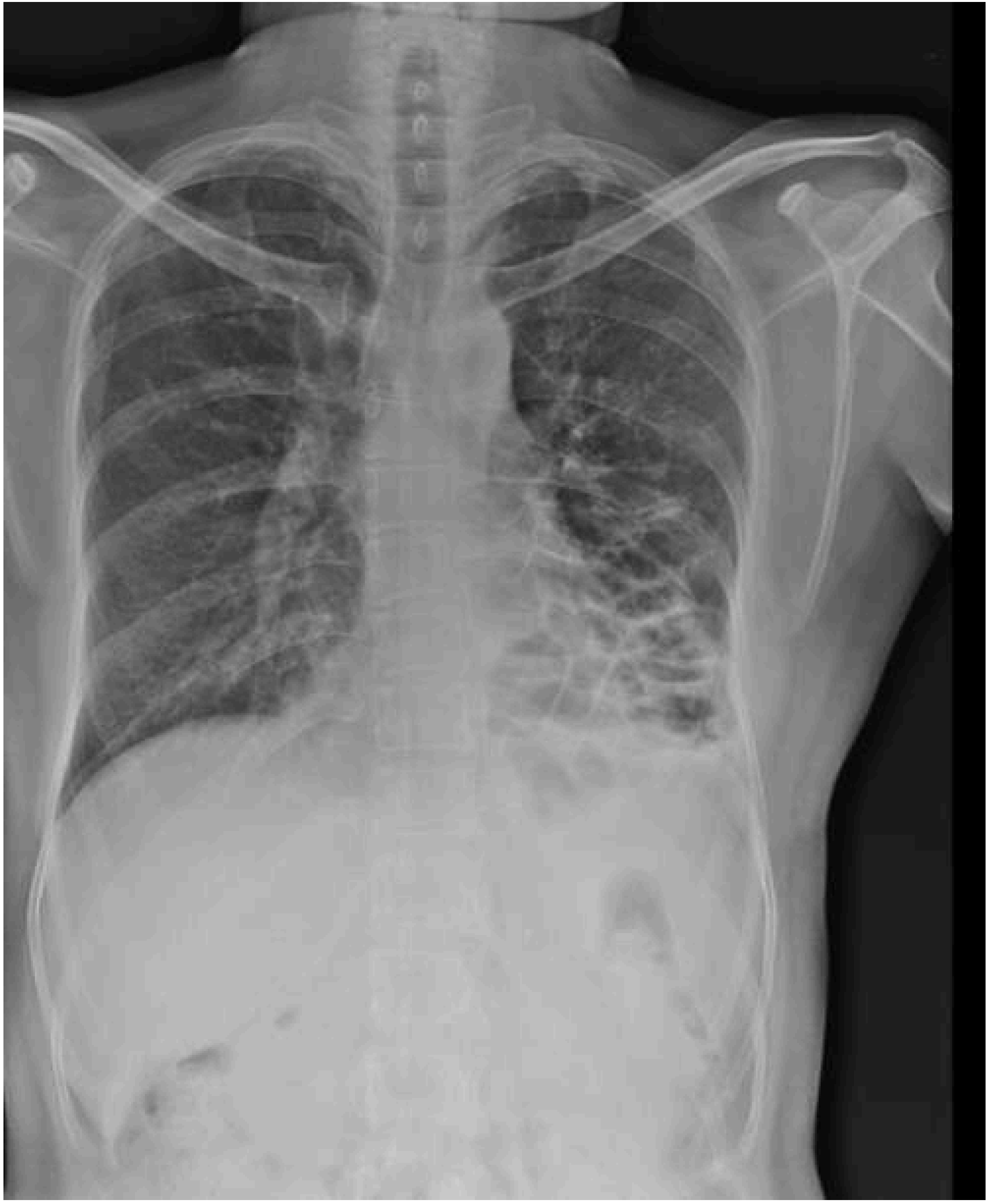

© Image used on license from Radiopaedia

Chest x-ray showing tramlines, most prominent in the left lower zone

© Image used on license from Radiopaedia

CT chest showing widespread tram-track and signet ring signs

123

Next question

Textbooks

High-yield textbook

Extended textbook

Links

British Thoracic Society 2 1

2018 Bronchiectasis guidelines

Suggest link Report broken link

Media

Bronchiectasis - causes, pathophysiology, signs and symptoms, investigations and treatment

Armando Hasudungan - YouTube 3 0

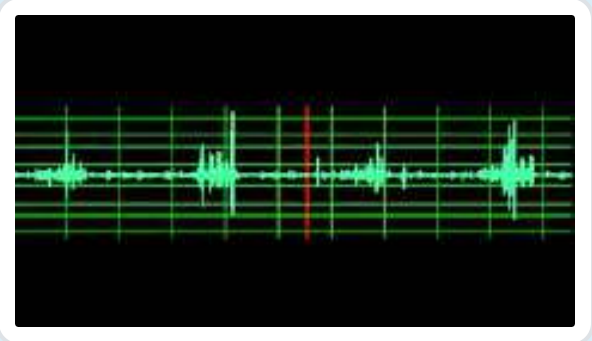

[Bronchiectasis crackles - REQUIRES HEADPHONES]

Thinklabs - YouTube 👍 3 👎 1

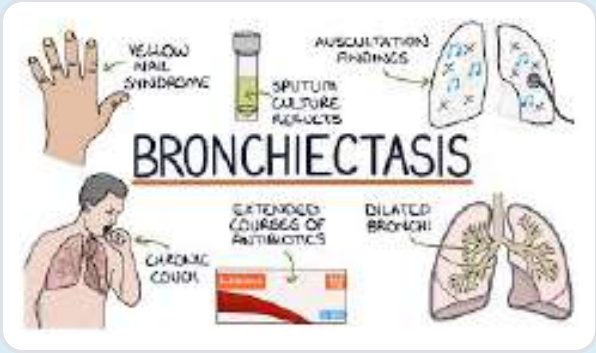

[Bronchiectasis]

Zero To Finals - YouTube 👍 0 👎 2

Report broken media

Score: **17.8%**

1	✗
2	✗
3	✗
4	✗
5	✗
6	✗
7	✗
8	✗
9	✓
10	✓
11	✗
12	✗
13	✗
14	✓
15	✗
16	✓
17	✗
18	✗
19	✗
20	✗
21	✓

22	✓
23	✗
24	✗
25	✗
26	✗
27	✓
28	✗
29	✗
30	✓
31	✓
32	✗
33	✗
34	✗
35	✗
36	✗
37	✗
38	✗
39	✗
40	-
41	✗
42	✗
43	✗
44	✗
45	✓
46	✗
47	✗
48	✗
49	✗
50	✗
51	✗
52	✗
53	✗
54	✗
55	✗
56	✗
57	✗

58	✗
59	✗
60	✗
61	✗
62	✗
63	✗
64	✗
65	✗
66	✗
67	✓
68	✗
69	✓
70	✗
71	✗
72	✓
73	✗
74	✗
75	-

All contents of this site are © 2024 Passmedicine Limited

Back to top

A 66 year old gentleman, who is a known heavy smoker, presents with a non infective exacerbation of chronic obstructive pulmonary disease (COPD). Upon admission despite maximal medical therapy his blood gasses worsen and he is commenced on non invasive ventilation and transferred to the high dependency unit. The nurses call you in the middle of the night to come and urgently review the patient. They have been titrating up the patient's non invasive ventilation (NIV) as they felt his blood gasses were not improving on standard settings. On arrival the patient is diaphoretic and complaining of chest pain. He is unable to tolerate his face mask. Observations are recorded as a pulse of 110/min regular, respiratory rate 32/min, Sats 75% on air, Blood pressure 100/82 mmHg. What is the most likely cause for this patient's acute deterioration?

- Ventilator associated pneumonia
- Acute myocardial infarction
- Ventilator associated pneumothorax
- Worsening of his COPD
- Panic attack

Submit answer

Reference ranges

Score: **20.4%**

1 ✗
2 ✗
3 ✗
4 ✗
5 ✗

6	✗
7	✗
8	✗
9	✓
10	✓
11	✗
12	✗
13	✗
14	✓
15	✗
16	✓
17	✗
18	✗
19	✗
20	✗
21	✓
22	✓
23	✗
24	✗
25	✗
26	✗
27	✓
28	✗
29	✗
30	✓
31	✓
32	✗
33	✗
34	✗
35	✗
36	✗
37	✗
38	✗
39	✗
40	-
41	✗

42	✗
43	✗
44	✗
45	✓
46	✗
47	✗
48	✗
49	✗
50	✗
51	-
52	-
53	-
54	-
55	-

All contents of this site are © 2024 Passmedicine Limited

Back to top

A 66 year old gentleman, who is a known heavy smoker, presents with a non infective exacerbation of chronic obstructive pulmonary disease (COPD). Upon admission despite maximal medical therapy his blood gasses worsen and he is commenced on non invasive ventilation and transferred to the high dependency unit. The nurses call you in the middle of the night to come and urgently review the patient. They have been titrating up the patient's non invasive ventilation (NIV) as they felt his blood gasses were not improving on standard settings. On arrival the patient is diaphoretic and complaining of chest pain. He is unable to tolerate his face mask. Observations are recorded as a pulse of 110/min regular, respiratory rate 32/min, Sats 75% on air, Blood pressure 100/82 mmHg. What is the most likely cause for this patient's acute deterioration?

Ventilator associated pneumonia	2%
Acute myocardial infarction	4%
Ventilator associated pneumothorax	85%
Worsening of his COPD	3%
Panic attack	6%

This question assesses candidates ability to recognise some of the complications of NIV. This patient has developed a pneumothorax secondary to the increasing pressures used as part of his NIV. Although less common these days due to nurse training, ventilation associated pneumothorax is an important complication of NIV to be aware of and therefore, prompt assessment and treatment will be essential in the management of this patient.
Ventilator associated pneumonia tends to present in patients who have been ventilated for long a long period of time and would not present so acutely.
Acute myocardial infarction would be unlikely as the question makes a point of mentioning the increasing pressures that are needed.

Candidates should also familiarise themselves with some of the contraindications to NIV:

- Recent facial or upper airway surgery or facial injuries.
- Recent upper gastrointestinal surgery.
- Confusion/agitation.
- Bowel obstruction.
- Upper airway obstruction.

- Excessive upper airway secretions.
- Patient actively vomiting.

May of these are self explanatory, for a more comprehensive list, including the indications for use of NIV please visit: https://www.brit-thoracic.org.uk/document-library/clinical-information/niv/niv-guidelines/nippv-non-invasive-ventilation-in-acute-respiratory-failure/

Discuss (7) Improve

Next question

Non-invasive ventilation

The British Thoracic Society (BTS) published guidelines in 2002 on the use of non-invasive ventilation in acute respiratory failure. Following these the Royal College of Physicians published guidelines in 2008.

Non-invasive ventilation - key indications

- COPD with respiratory acidosis pH 7.25-7.35
    - the BTS guidelines state that NIV can be used in patients who are more acidotic (i.e. pH < 7.25) but that a greater degree of monitoring is required (e.g. HDU) and a lower threshold for intubation and ventilation should be used
- type II respiratory failure secondary to chest wall deformity, neuromuscular disease or obstructive sleep apnoea
- cardiogenic pulmonary oedema unresponsive to CPAP
- weaning from tracheal intubation

Recommended initial settings for bi-level pressure support in COPD

- Expiratory Positive Airway Pressure (EPAP): 4-5 cm H2O
- Inspiratory Positive Airway Pressure (IPAP): RCP advocate 10 cm H20 whilst BTS suggest 12-15 cm H2O
- back up rate: 15 breaths/min
- back up inspiration:expiration ratio: 1:3

AI + Q 123

Next question

Textbooks

High-yield textbook

Extended textbook

Links

British Thoracic Society 12 4

2016 BTS/ICS Guidelines for the Ventilatory Management of Acute Hypercapnic Respiratory Failure in Adults

Suggest link

Report broken link

Media

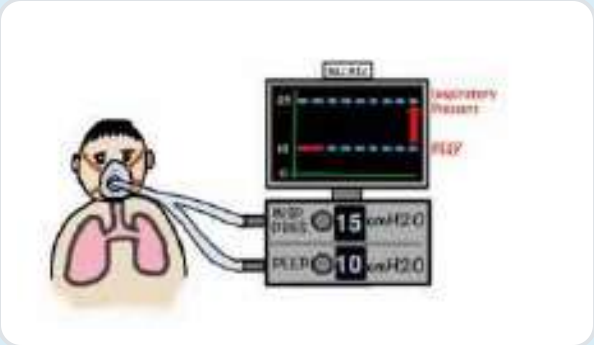

CPAP and Non-Invasive Ventilation in 5 minutes

Nick Smith - YouTube 31 2

Clinical Skills: BiPAP and CPAP

Osmosis - YouTube 3 7

Report broken media

Score: **17.8%**

1	✗
2	✗
3	✗
4	✗
5	✗
6	✗
7	✗
8	✗
9	✓
10	✓
11	✗
12	✗
13	✗
14	✓
15	✗
16	✓
17	✗
18	✗
19	✗
20	✗
21	✓
22	✓
23	✗
24	✗
25	✗
26	✗
27	✓
28	✗
29	✗
30	✓
31	✓
32	✗

33	✗
34	✗
35	✗
36	✗
37	✗
38	✗
39	✗
40	-
41	✗
42	✗
43	✗
44	✗
45	✓
46	✗
47	✗
48	✗
49	✗
50	✗
51	✗
52	✗
53	✗
54	✗
55	✗
56	✗
57	✗
58	✗
59	✗
60	✗
61	✗
62	✗
63	✗
64	✗
65	✗
66	✗
67	✓
68	✗

69	✓
70	✗
71	✗
72	✓
73	✗
74	✗
75	-

All contents of this site are © 2024 Passmedicine Limited

A 66-year-old man, presented with two episodes of mild haemoptysis in the past 3 months. He also had lost 5 kilograms of weight in the past 3 months. He was a smoker with 50 pack years history and a social drinker. He was actively mobile and had no significant past medical history.

Clinical examination revealed no abnormality except clubbing.

A contrast enhanced CT chest showed a 4 cm mass in the right upper lobe periphery close to the chest wall and enlarged right hilar (2 cm) and subcarinal (2 cm) lymph nodes. A positron emission tomography (PET) scan was done which showed a standard uptake value (SUV) max of 20 for the lung mass. The ipsilateral hilar and subcarinal lymph nodes were also found to be FDG (fluorodeoxyglucose) avid. There was no evidence of distant metastasis.

What is the next appropriate step in the management?

- CT guided biopsy of the lung mass
- Ultrasound guided biopsy of the lung mass
- Flexible bronchoscopic biopsy of the lung mass
- Endobronchial ultrasound (EBUS) guided mediastinal lymph node sampling
- Video-Assisted Thoracoscopic Surgery (VATS) biopsy of the mediastinal lymph nodes

Submit answer

Reference ranges

Score: **20.4%**

1 ✗
2 ✗

3	✗
4	✗
5	✗
6	✗
7	✗
8	✗
9	✓
10	✓
11	✗
12	✗
13	✗
14	✓
15	✗
16	✓
17	✗
18	✗
19	✗
20	✗
21	✓
22	✓
23	✗
24	✗
25	✗
26	✗
27	✓
28	✗
29	✗
30	✓
31	✓
32	✗
33	✗
34	✗
35	✗
36	✗
37	✗
38	✗

39	✗
40	-
41	✗
42	✗
43	✗
44	✗
45	✓
46	✗
47	✗
48	✗
49	✗
50	✗
51	-
52	-
53	-
54	-
55	-
56	-

All contents of this site are © 2024 Passmedicine Limited

A 66-year-old man, presented with two episodes of mild haemoptysis in the past 3 months. He also had lost 5 kilograms of weight in the past 3 months. He was a smoker with 50 pack years history and a social drinker. He was actively mobile and had no significant past medical history.

Clinical examination revealed no abnormality except clubbing.

A contrast enhanced CT chest showed a 4 cm mass in the right upper lobe periphery close to the chest wall and enlarged right hilar (2 cm) and subcarinal (2 cm) lymph nodes. A positron emission tomography (PET) scan was done which showed a standard uptake value (SUV) max of 20 for the lung mass. The ipsilateral hilar and subcarinal lymph nodes were also found to be FDG (fluorodeoxyglucose) avid. There was no evidence of distant metastasis.

What is the next appropriate step in the management?

- CT guided biopsy of the lung mass 32%
- Ultrasound guided biopsy of the lung mass 12%
- Flexible bronchoscopic biopsy of the lung mass 10%
- Endobronchial ultrasound (EBUS) guided mediastinal lymph node sampling 33%
- Video-Assisted Thoracoscopic Surgery (VATS) biopsy of the mediastinal lymph nodes 13%

This is probably a stage IIIA (T2aN2M0) lung cancer. Diagnosis and staging has to be confirmed by tissue sampling. EBUS guided mediastinal lymph node sampling provides diagnosis and staging in a single step whereas CT guided or ultrasound guided or bronchoscopic biopsy of the lung mass yields only tissue diagnosis (not staging). Wherever possible minimally invasive procedures should be undertaken first for mediastinal node sampling (e.g., EBUS) before embarking into more invasive procedures like VATS.

Reference: ESMO Consensus Guidelines: Locally-advanced stage III non-small-cell lung cancer (NSCLC)
http://annonc.oxfordjournals.org/content/26/8/1573.full

Next question >

Lung cancer: investigation

Chest x-ray
- this is often the first investigation done in patients with suspected lung cancer
- in around 10% of patients subsequently diagnosed with lung cancer the chest x-ray was reported as normal

CT
- is the investigation of choice to investigate suspected lung cancer

Bronchoscopy
- this allows a biopsy to be taken to obtain a histological diagnosis sometimes aided by endobronchial ultrasound

PET scanning
- is typically done in non-small cell lung cancer to establish eligibility for curative treatment
- uses 18-fluorodeoxygenase which is preferentially taken up by neoplastic tissue
- has been shown to improve diagnostic sensitivity of both local and distant metastasis spread in non-small cell lung cancer

Bloods
- raised platelets may be seen

AI + Q 123

Next question >

Textbooks

High-yield textbook

Extended textbook

Links

Royal College of Physicians 2 3

2012 PET/CT in oncology review

Radiopaedia 3 1

Lung cancer review

Suggest link

Report broken link

Media

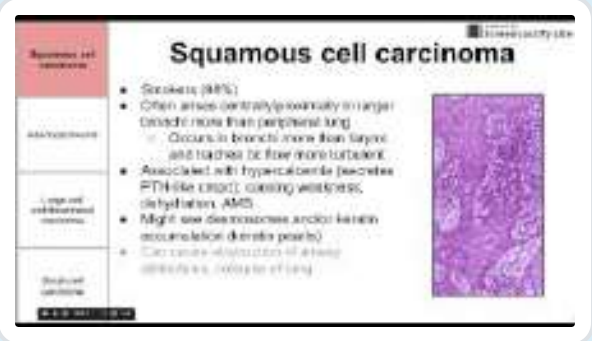

Cancers of the lung

MedLecturesMadeEasy - YouTube 5 0

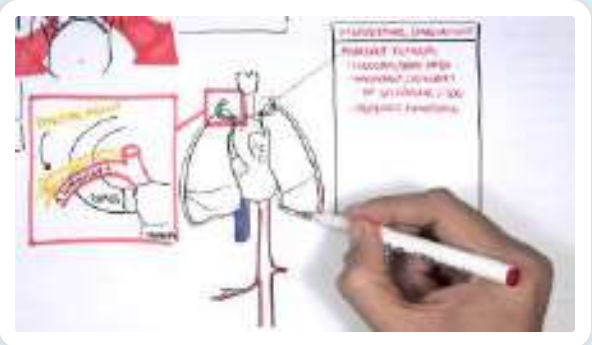

Lung cancer

Armando Hasudungan - YouTube 1 0

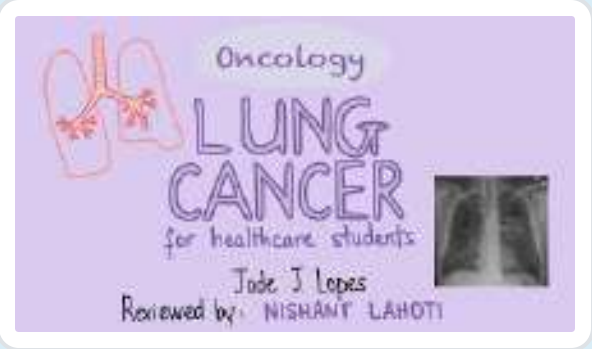

[Lung cancer]

MedFlix - YouTube 2 1

[Lung Cancer: An Overview]

Oncology for Medical Students - YouTube 1 1

Report broken media

Score: **17.8%**

1	✗
2	✗
3	✗
4	✗
5	✗
6	✗
7	✗
8	✗
9	✓
10	✓
11	✗
12	✗
13	✗
14	✓
15	✗
16	✓
17	✗

18	✗
19	✗
20	✗
21	✓
22	✓
23	✗
24	✗
25	✗
26	✗
27	✓
28	✗
29	✗
30	✓
31	✓
32	✗
33	✗
34	✗
35	✗
36	✗
37	✗
38	✗
39	✗
40	-
41	✗
42	✗
43	✗
44	✗
45	✓
46	✗
47	✗
48	✗
49	✗
50	✗
51	✗
52	✗
53	✗

54	✗
55	✗
56	✗
57	✗
58	✗
59	✗
60	✗
61	✗
62	✗
63	✗
64	✗
65	✗
66	✗
67	✓
68	✗
69	✓
70	✗
71	✗
72	✓
73	✗
74	✗
75	-

All contents of this site are © 2024 Passmedicine Limited

Back to top

A 17-year-old male is admitted to the resuscitation area of the emergency department with an acute exacerbation of asthma. It is his 3rd hospital attendance this winter. He has widespread wheeze, globally poor air entry and looks tired. He cannot complete full sentences. His arterial blood gases reveal:

pH	7.4
PaO2	9.3 kPa
PaCO2	3.3 kPa
HCO3-	26 mmol/L

You treat him with 100% oxygen, high dose steroids, back to back salbutamol nebulisers and commence intravenous magnesium sulphate infusion. 1 hour later his arterial blood gases reveal:

pH	7.35
PaO2	15.4 kPa
PaCO2	4.7 kPa
HC03-	22 mmol/L

What is the next management step?

- Start BIPAP
- Intensive care review
- Move to medical ward with close monitoring
- Intravenous adrenaline
- Start CPAP

Submit answer

Reference ranges

Score: **20.4%**

1	✗
2	✗
3	✗
4	✗
5	✗
6	✗
7	✗
8	✗
9	✓
10	✓
11	✗
12	✗
13	✗
14	✓
15	✗
16	✓
17	✗
18	✗
19	✗
20	✗
21	✓
22	✓
23	✗
24	✗
25	✗
26	✗
27	✓
28	✗
29	✗
30	✓

31	✓
32	✗
33	✗
34	✗
35	✗
36	✗
37	✗
38	✗
39	✗
40	-
41	✗
42	✗
43	✗
44	✗
45	✓
46	✗
47	✗
48	✗
49	✗
50	✗
51	-
52	-
53	-
54	-
55	-
56	-
57	-

All contents of this site are © 2024 Passmedicine Limited

A 17-year-old male is admitted to the resuscitation area of the emergency department with an acute exacerbation of asthma. It is his 3rd hospital attendance this winter. He has widespread wheeze, globally poor air entry and looks tired. He cannot complete full sentences. His arterial blood gases reveal:

pH	7.4
PaO2	9.3 kPa
PaCO2	3.3 kPa
HCO3-	26 mmol/L

You treat him with 100% oxygen, high dose steroids, back to back salbutamol nebulisers and commence intravenous magnesium sulphate infusion. 1 hour later his arterial blood gases reveal:

pH	7.35
PaO2	15.4 kPa
PaCO2	4.7 kPa
HC03-	22 mmol/L

What is the next management step?

Start BIPAP	8%
Intensive care review	76%
Move to medical ward with close monitoring	13%
Intravenous adrenaline	0%
Start CPAP	3%

Rising CO2 is an indication that the patient is becoming tired. Oxygenation has only mildly improved despite 100% oxygen. Patients with life-threatening features of asthma do not always appear distressed. The patient will likely require mechanical ventilation.

Discuss (6) | Improve

Next question

Acute asthma: management

The British Thoracic Society (BTS) classify patients with acute asthma into moderate, severe or life-threatening categories.

Moderate	Severe	Life-threatening
PEFR 50-75% best or predicted Speech normal RR < 25 / min Pulse < 110 bpm	PEFR 33 - 50% best or predicted Can't complete sentences RR > 25/min Pulse > 110 bpm	PEFR < 33% best or predicted Oxygen sats < 92% 'Normal' $pC0_2$ (4.6-6.0 kPa) Silent chest, cyanosis or feeble respiratory effort Bradycardia, dysrhythmia or hypotension Exhaustion, confusion or coma

Note that a patient having any one of the life-threatening features should be treated as having a life-threatening attack.

A fourth category, '**Near-fatal asthma**', is also recognised characterised by a raised $pC0_2$ and/or requiring mechanical ventilation with raised inflation pressures.

Further assessment
- the BTS guidelines recommend arterial blood gases for patients with oxygen sats < 92%
- a chest x-ray is not routinely recommended, unless:
  - life-threatening asthma
  - suspected pneumothorax
  - failure to respond to treatment

Management
- admission
  - all patients with life-threatening should be admitted in hospital
  - patients with features of severe acute asthma should also be admitted if they fail to respond to initial treatment.

    - other admission criteria include a previous near-fatal asthma attack, pregnancy, an attack occurring despite already using oral corticosteroid and presentation at night
- oxygen
    - if patients are hypoxaemic, it is important to start them on supplemental oxygen therapy
    - if patients are acutely unwell they should be started on 15L of supplemental via a non-rebreathe mask, which can then be titrated down to a flow rate where they are able to maintain a SpO_2 94-98%.
- bronchodilation with short-acting beta$_2$-agonists (SABA)
    - high-dose inhaled SABA e.g. salbutamol, terbutaline
    - in patients without features of life-threatening or near-fatal asthma, this can be given by a standard pressurised metered-dose inhaler (pMDI) or by an oxygen-driven nebulizer
    - in patients with features of a life-threatening exacerbation of asthma, nebulised SABA is recommended
- corticosteroid
    - all patients should be given 40-50mg of prednisolone orally (PO) daily, which should be continued for at least five days or until the patient recovers from the attack
    - during this time, patients should continue their normal medication routine including inhaled corticosteroids.
- ipratropium bromide: in patients with severe or life-threatening asthma, or in patients who have not responded to beta$_2$-agonist and corticosteroid treatment, nebulised ipratropium bromide, a short-acting muscarinic antagonist
- IV magnesium sulphate
    - the BTS notes that the evidence base is mixed for this treatment that is now commonly given for severe/life-threatening asthma
- IV aminophylline may be considered following consultation with senior medical staff
- patients who fail to respond require senior critical care support and should be treated in an appropriate ITU/HDU setting. Treatment options include:
    - intubation and ventilation
    - extracorporeal membrane oxygenation (ECMO)

Criteria for discharge

- been stable on their discharge medication (i.e. no nebulisers or oxygen) for 12-24 hours
- inhaler technique checked and recorded
- PEF >75% of best or predicted

123

Next question

Textbooks

High-yield textbook

Extended textbook

Links

British Thoracic Society

2019 Asthma guidelines

44 73

Suggest link

Report broken link

Score: **17.8%**

1	✗
2	✗
3	✗
4	✗
5	✗
6	✗
7	✗
8	✗
9	✓
10	✓
11	✗
12	✗
13	✗
14	✓

15	✗
16	✓
17	✗
18	✗
19	✗
20	✗
21	✓
22	✓
23	✗
24	✗
25	✗
26	✗
27	✓
28	✗
29	✗
30	✓
31	✓
32	✗
33	✗
34	✗
35	✗
36	✗
37	✗
38	✗
39	✗
40	-
41	✗
42	✗
43	✗
44	✗
45	✓
46	✗
47	✗
48	✗
49	✗
50	✗

51 ✗
52 ✗
53 ✗
54 ✗
55 ✗
56 ✗
57 ✗
58 ✗
59 ✗
60 ✗
61 ✗
62 ✗
63 ✗
64 ✗
65 ✗
66 ✗
67 ✓
68 ✗
69 ✓
70 ✗
71 ✗
72 ✓
73 ✗
74 ✗
75 -

All contents of this site are © 2024 Passmedicine Limited

Back to top

An 83-year-old male presents with his third admission of right lower zone community-acquired pneumonia in 5 months. A CT thorax demonstrates a 2.2cm mass in right lower lobar bronchus with no regional lymph nodes. Bronchoscopy reveals non-small cell lung Ca 4cm from the carina, CT staging reveals no other metastases. A final staging diagnosis of T1b N0 M0 is made, at stage 1A. The patient undergoes lung function testing as follows:

FVC	2.2l
FEV1	1.7l/s
TLCO	42% of predicted

What is the most appropriate treatment?

- Right pneumonectomy
- Right lower lobectomy
- Chemotherapy
- Radiotherapy
- Palliative care

Submit answer

Reference ranges

Score: **20.4%**

1 ✗
2 ✗
3 ✗

4	✗
5	✗
6	✗
7	✗
8	✗
9	✓
10	✓
11	✗
12	✗
13	✗
14	✓
15	✗
16	✓
17	✗
18	✗
19	✗
20	✗
21	✓
22	✓
23	✗
24	✗
25	✗
26	✗
27	✓
28	✗
29	✗
30	✓
31	✓
32	✗
33	✗
34	✗
35	✗
36	✗
37	✗
38	✗
39	✗

40	-
41	✗
42	✗
43	✗
44	✗
45	✓
46	✗
47	✗
48	✗
49	✗
50	✗
51	-
52	-
53	-
54	-
55	-
56	-
57	-
58	-

All contents of this site are © 2024 Passmedicine Limited

An 83-year-old male presents with his third admission of right lower zone community-acquired pneumonia in 5 months. A CT thorax demonstrates a 2.2cm mass in right lower lobar bronchus with no regional lymph nodes. Bronchoscopy reveals non-small cell lung Ca 4cm from the carina, CT staging reveals no other metastases. A final staging diagnosis of T1b N0 M0 is made, at stage 1A. The patient undergoes lung function testing as follows:

FVC	2.2l
FEV1	1.7l/s
TLCO	42% of predicted

What is the most appropriate treatment?

- Right pneumonectomy 10%
- Right lower lobectomy 64%
- Chemotherapy 9%
- Radiotherapy 13%
- Palliative care 3%

The patient has been diagnosed with surgically resectable non-small cell lung carcinoma (NSCLC). All NSCLC with stage I or II disease should undergo resection surgery where possible, stage III disease generally is focused on chemotherapy while stage IV disease is managed with symptomatic palliative treatments. However, while the disease burden may be amenable to surgery, the patient's lung function testing may restrict management options. Multiple studies have demonstrated FEV1 and transfer coefficients to be the most accurate predictors of post-operative dyspnoea, with the British Thoracic Society recommending the patient to demonstrate FEV1 >2l/s for pneumonectomy and 1.5l/s for lobectomy. TLCO is similarly recommended to be greater than 40% of predicted for resective surgery1. Forced vital capacity is not demonstrated to be a significant predictor of post-operative outcomes.

1. BTS guidelines: guidelines on the selection of patients with lung cancer for surgery. Thorax. 2001;56(2):89.

Discuss (8) Improve

Next question

Lung cancer: non-small cell management

Management

- only 20% suitable for surgery
  - mediastinoscopy performed prior to surgery as CT does not always show mediastinal lymph node involvement
- curative or palliative radiotherapy
- poor response to chemotherapy

Surgery contraindications

- assess general health
- stage IIIb or IV (i.e. metastases present)
- FEV1 < 1.5 litres is considered a general cut-off point*
- malignant pleural effusion
- tumour near hilum
- vocal cord paralysis
- SVC obstruction

* However if FEV1 < 1.5 for lobectomy or < 2.0 for pneumonectomy then some authorities advocate further lung function tests as operations may still go ahead based on the results

Next question

Textbooks

High-yield textbook

Extended textbook

Links

SIGN

2014 Lung cancer management guidelines

2 3

Radiopaedia

Lung cancer review

8 2

Suggest link

Report broken link

Media

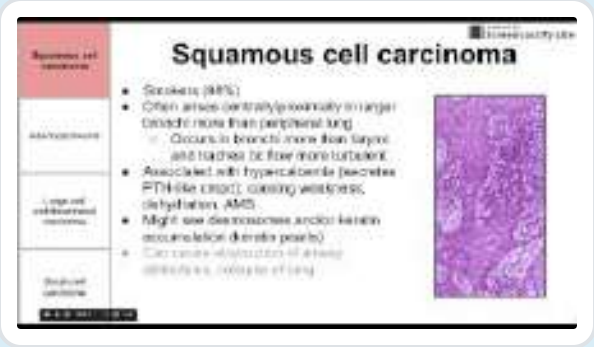

Cancers of the lung

MedLecturesMadeEasy - YouTube 2 0

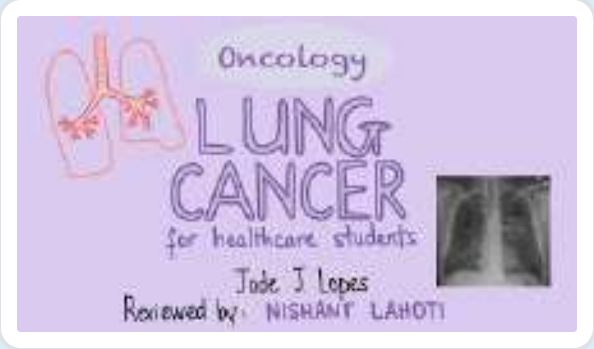

Lung cancer

MedFlix - YouTube 2 1

Report broken media

Score: **17.8%**

1 ✕

2	✗
3	✗
4	✗
5	✗
6	✗
7	✗
8	✗
9	✓
10	✓
11	✗
12	✗
13	✗
14	✓
15	✗
16	✓
17	✗
18	✗
19	✗
20	✗
21	✓
22	✓
23	✗
24	✗
25	✗
26	✗
27	✓
28	✗
29	✗
30	✓
31	✓
32	✗
33	✗
34	✗
35	✗
36	✗
37	✗

38	✗
39	✗
40	-
41	✗
42	✗
43	✗
44	✗
45	✓
46	✗
47	✗
48	✗
49	✗
50	✗
51	✗
52	✗
53	✗
54	✗
55	✗
56	✗
57	✗
58	✗
59	✗
60	✗
61	✗
62	✗
63	✗
64	✗
65	✗
66	✗
67	✓
68	✗
69	✓
70	✗
71	✗
72	✓
73	✗

74	✕
75	-

All contents of this site are © 2024 Passmedicine Limited

A 39-year-old lady presented to the emergency department acutely unwell with fever, weight loss and malaise. She had been finding it increasingly difficult to mobilise in recent weeks due to weakness in her right ankle. She had diarrhoea and was passing loose brown stool up to five times a day. She had a previous medical history of asthma and sinusitis. Her medications included a salbutamol inhaler, salmeterol inhaler, montelukast and intermittent courses of prednisolone and antibiotics as required.

On examination, she appeared unwell, had petechial purpura in the nail beds of her fingers and on her feet, expiratory wheeze on auscultation of her chest, a soft abdomen with no palpable masses and weakness of dorsiflexion of her right ankle. Her temperature was 37.4 degrees Celsius, her pulse was 115 beats per minute and regular, her blood pressure was 140/95 mmHg, her respiratory rate was 24 breaths per minute and her oxygen saturations were 94% on room air.

Investigations:

Urine dip: blood++, protein+

Haemoglobin	95 g/L
White cell count	23.6 x10^9 /L
Platelet Count	181x10^9/L
Neutrophils	12.3 x10^9/L
Eosinophils	9.6 x10^9/L
Basophils	0.2 x10^9/L
Lymphocytes	1 x10^9/L
Monocytes	0.5 x10^9/L
Erythrocyte sedimentation rate	65mm/hr
INR	0.9

Serum sodium	138mmol/L
Serum potassium	4.6mmol/L
Serum urea	15.4mmol/L
Serum creatinine	220micromol/L

Antinuclear antibody	negative

C-terminus antineutrophil cytoplasmic antibodies	negative
Myeloperoxidase anti-neutrophil cytoplasmic antibodies	positive

What is the most likely diagnosis?

- Infective endocarditis
- Wegener's granulomatosis
- E.Coli gastroenteritis
- Churg-Strauss syndrome
- Crohn's disease

Submit answer

Reference ranges

Score: **20.4%**

1 ✗
2 ✗
3 ✗
4 ✗
5 ✗
6 ✗
7 ✗
8 ✗
9 ✓
10 ✓
11 ✗
12 ✗
13 ✗

14	✓
15	✗
16	✓
17	✗
18	✗
19	✗
20	✗
21	✓
22	✓
23	✗
24	✗
25	✗
26	✗
27	✓
28	✗
29	✗
30	✓
31	✓
32	✗
33	✗
34	✗
35	✗
36	✗
37	✗
38	✗
39	✗
40	-
41	✗
42	✗
43	✗
44	✗
45	✓
46	✗
47	✗
48	✗
49	✗

50	✕
51	-
52	-
53	-
54	-
55	-
56	-
57	-
58	-
59	-

All contents of this site are © 2024 Passmedicine Limited

A 39-year-old lady presented to the emergency department acutely unwell with fever, weight loss and malaise. She had been finding it increasingly difficult to mobilise in recent weeks due to weakness in her right ankle. She had diarrhoea and was passing loose brown stool up to five times a day. She had a previous medical history of asthma and sinusitis. Her medications included a salbutamol inhaler, salmeterol inhaler, montelukast and intermittent courses of prednisolone and antibiotics as required.

On examination, she appeared unwell, had petechial purpura in the nail beds of her fingers and on her feet, expiratory wheeze on auscultation of her chest, a soft abdomen with no palpable masses and weakness of dorsiflexion of her right ankle. Her temperature was 37.4 degrees Celsius, her pulse was 115 beats per minute and regular, her blood pressure was 140/95 mmHg, her respiratory rate was 24 breaths per minute and her oxygen saturations were 94% on room air.

Investigations:

Urine dip: blood++, protein+

Haemoglobin	95 g/L
White cell count	23.6 x10^9 /L
Platelet Count	181x10^9/L
Neutrophils	12.3 x10^9/L
Eosinophils	9.6 x10^9/L
Basophils	0.2 x10^9/L
Lymphocytes	1 x10^9/L
Monocytes	0.5 x10^9/L
Erythrocyte sedimentation rate	65mm/hr
INR	0.9

Serum sodium	138mmol/L
Serum potassium	4.6mmol/L
Serum urea	15.4mmol/L
Serum creatinine	220micromol/L

Antinuclear antibody	negative

C-terminus antineutrophil cytoplasmic antibodies	negative
Myeloperoxidase anti-neutrophil cytoplasmic antibodies	positive

What is the most likely diagnosis?

Infective endocarditis	1%
Wegener's granulomatosis	14%
E.Coli gastroenteritis	1%
Churg-Strauss syndrome	83%
Crohn's disease	1%

This lady with a history of asthma and sinusitis has presented systemically unwell with diarrhoea, a right common peroneal nerve palsy, vasculitic rash and has evidence of a nephritis. Investigations show a significant eosinophilia and immunological screen has shown she is P-ANCA positive. The most likely diagnosis is, therefore, Churg-Strauss syndrome. This is a small vessel vasculitis with eosinophilic infiltration and granulomatous formation that is characterised by chronic sinusitis, asthma and eosinophilia. Systemic features of malaise, myalgia, fever and weight loss are common. Other symptoms and signs depend on other organ systems involved which most commonly are the lung (asthma, pneumonitis) and skin (purpura, subcutaneous nodules); however, any organ system can be affected including the cardiovascular (heart failure, myocarditis), gastrointestinal (gastroenteritis, ischaemia, bleeding), renal (glomerulonephritis, hypertension), and central nervous systems (mononeuritis multiplex). ANCA is positive in approximately 60% of cases and is predominantly P-ANCA.

Infective endocarditis could account for some of her symptoms however the absence of a heart murmur and the multisystem involvement, in this case, makes it less likely. Wegener's granulomatosis is another granulomatous small vessel vasculitis which most commonly presents with lesions in the upper respiratory tract (rhinorrhoea, sinusitis, saddle nose deformity), lungs (infiltrates and pulmonary haemorrhage) and kidneys (rapidly progressive glomerulonephritis). It is classically C-ANCA positive. The history of immunological screen of this case is, therefore, more typical of Churg-Strauss syndrome. E.coli gastroenteritis would be unlikely to present in this fashion.

Crohn's disease is a chronic inflammatory bowel disease that classically presents with abdominal pain, weight loss and change in bowel habit. There are often extra-intestinal manifestations involving the mouth, skin, eyes, joints and episodes of perianal abscess or anal fissure. Crohn's disease could account for some of this lady's symptoms but again is less likely than Churg-Strauss syndrome.

Discuss (3) Improve

Next question

Eosinophilic granulomatosis with polyangiitis (Churg-Strauss syndrome)

Eosinophilic granulomatosis with polyangiitis (EGPA) is now the preferred term for **Churg-Strauss syndrome**. It is an ANCA associated small-medium vessel vasculitis.

Features
- asthma
- blood eosinophilia (e.g. > 10%)
- paranasal sinusitis
- mononeuritis multiplex
- pANCA positive in 60%

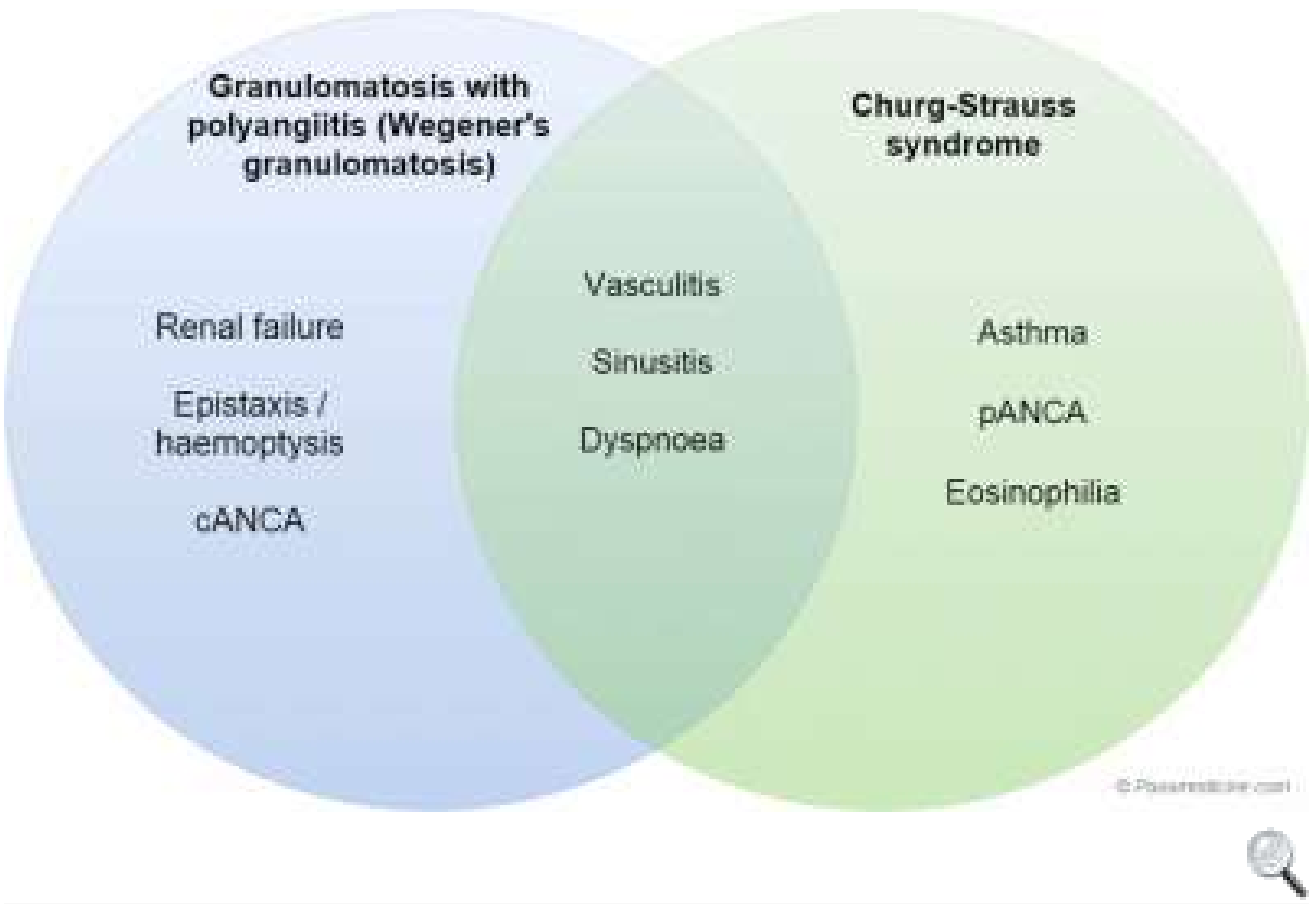

Comparison of granulomatosis with polyangiitis and Churg-Strauss syndrome

Leukotriene receptor antagonists may precipitate the disease.

123

Next question

Textbooks

High-yield textbook

Extended textbook

Media

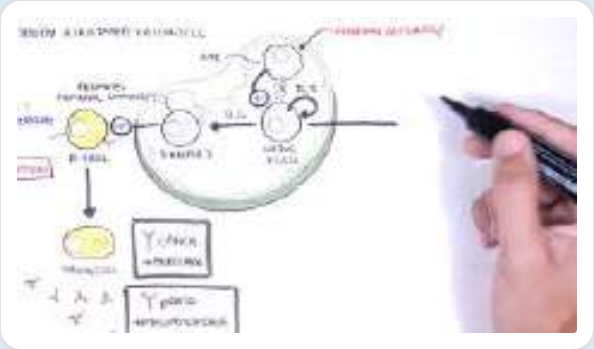

ANCA (Anti-Neutrophil Cytoplasmic Antibody) Associated Vasculitis - Causes, Pathophysiology, Types

Armando Hasudungan - YouTube 3 3

Report broken media

Score: **17.8%**

1	✗
2	✗
3	✗
4	✗
5	✗
6	✗
7	✗
8	✗
9	✓
10	✓

11	✗
12	✗
13	✗
14	✓
15	✗
16	✓
17	✗
18	✗
19	✗
20	✗
21	✓
22	✓
23	✗
24	✗
25	✗
26	✗
27	✓
28	✗
29	✗
30	✓
31	✓
32	✗
33	✗
34	✗
35	✗
36	✗
37	✗
38	✗
39	✗
40	-
41	✗
42	✗
43	✗
44	✗
45	✓
46	✗

47	✗
48	✗
49	✗
50	✗
51	✗
52	✗
53	✗
54	✗
55	✗
56	✗
57	✗
58	✗
59	✗
60	✗
61	✗
62	✗
63	✗
64	✗
65	✗
66	✗
67	✓
68	✗
69	✓
70	✗
71	✗
72	✓
73	✗
74	✗
75	-

All contents of this site are © 2024 Passmedicine Limited

Back to top

A 70-year-old gentleman is admitted with three days of shortness of breath and arrives to the emergency department where he is started on non invasive ventilation for a suspected infective exacerbation of COPD.

On examination, he is in respiratory distress with cyanosis and a retention flap. He has widespread wheeze throughout and crepitation at the right base. There is no oedema and he has a capillary refill time of 3 seconds. Blood pressure 90/65mmHg, respiratory rate 24 breaths per minute, oxygen saturations are 84% on arrival and rise to 92% with 28% oxygen.

He is treated with full maximal therapy but fails to improve. He appears comfortable with the mask on and there is hissing heard with each inflation breath. The machine is set to 12cmH2O IPAP and 4cmH2O EPAP but the pressures recorded are 8cmH2O IPAP and 3cm H2O EPAP.

ABG	on arrival
pH	7.32
pCO2	8.2kPa
pO2	7.1 kPa
HCO3	26mmol/l
Lactate	3.02 mmol/l
ABG	current
pH	7.31
pCO2	8.3kPa
pO2	8kPa (on FiO2 0.28)
HCO3	26mmol/l
Lactate	2.78 mmol/l
Chest x-ray	hyperexpanded lung fields, consolidation on right middle zone

What is the most likely explanation of the failure to improve?

- Carbon dioxide narcosis
- Dyssynchrony

- ○ Mucus plugging ×
- ○ Mask leak ×
- ○ Pneumothorax ×

Submit answer

Reference ranges

Score: **20.4%**

1	✗
2	✗
3	✗
4	✗
5	✗
6	✗
7	✗
8	✗
9	✓
10	✓
11	✗
12	✗
13	✗
14	✓
15	✗
16	✓
17	✗
18	✗
19	✗
20	✗
21	✓

22	✓
23	✗
24	✗
25	✗
26	✗
27	✓
28	✗
29	✗
30	✓
31	✓
32	✗
33	✗
34	✗
35	✗
36	✗
37	✗
38	✗
39	✗
40	-
41	✗
42	✗
43	✗
44	✗
45	✓
46	✗
47	✗
48	✗
49	✗
50	✗
51	-
52	-
53	-
54	-
55	-
56	-
57	-
58	-

59	-
60	-

All contents of this site are © 2024 Passmedicine Limited

A 70-year-old gentleman is admitted with three days of shortness of breath and arrives to the emergency department where he is started on non invasive ventilation for a suspected infective exacerbation of COPD.

On examination, he is in respiratory distress with cyanosis and a retention flap. He has widespread wheeze throughout and crepitation at the right base. There is no oedema and he has a capillary refill time of 3 seconds. Blood pressure 90/65mmHg, respiratory rate 24 breaths per minute, oxygen saturations are 84% on arrival and rise to 92% with 28% oxygen.

He is treated with full maximal therapy but fails to improve. He appears comfortable with the mask on and there is hissing heard with each inflation breath. The machine is set to 12cmH2O IPAP and 4cmH2O EPAP but the pressures recorded are 8cmH2O IPAP and 3cm H2O EPAP.

ABG	on arrival
pH	7.32
pCO2	8.2kPa
pO2	7.1 kPa
HCO3	26mmol/l
Lactate	3.02 mmol/l
ABG	current
pH	7.31
pCO2	8.3kPa
pO2	8kPa (on FiO2 0.28)
HCO3	26mmol/l
Lactate	2.78 mmol/l
Chest x-ray	hyperexpanded lung fields, consolidation on right middle zone

What is the most likely explanation of the failure to improve?

- Carbon dioxide narcosis 4%
- Dyssynchrony 11%

Mucus plugging 13%

Mask leak 67%

Pneumothorax 6%

Significant air leak from the mask will prevent adequate pressures being achieved with non-invasive ventilation

Important for me   Less important

The patient has a clear COPD exacerbation and starts non invasive ventilation but fails to improve. The clues are the audible hiss of air that can be heard from the mask and the failure of the machine to achieve the pressures set. Poor mask application or facial dysmorphia can lead to a poor seal to the face. Air will leak and the pressure will fall with this. The patient is unlikely to have deteriorated due to reducing consciousness secondary to CO2 narcosis as he continues to breathe at an elevated respiratory rate. There is no suggestion of a pneumothorax and this usually presents as a deterioration rather than a failure to improve. The patient is comfortable and does not appear to be fighting the machine as in dyssynchrony. A large mucus plug usually presents with sudden desaturation which is not seen here.

Discuss (1)   Improve

Next question

Non-invasive ventilation

The British Thoracic Society (BTS) published guidelines in 2002 on the use of non-invasive ventilation in acute respiratory failure. Following these the Royal College of Physicians published guidelines in 2008.

Non-invasive ventilation - key indications

- COPD with respiratory acidosis pH 7.25-7.35
    - the BTS guidelines state that NIV can be used in patients who are more acidotic (i.e. pH < 7.25) but that a greater degree of monitoring is required (e.g. HDU) and a lower threshold for intubation and ventilation should be used
- type II respiratory failure secondary to chest wall deformity, neuromuscular disease or obstructive sleep apnoea
- cardiogenic pulmonary oedema unresponsive to CPAP
- weaning from tracheal intubation

Recommended initial settings for bi-level pressure support in COPD

- Expiratory Positive Airway Pressure (EPAP): 4-5 cm H2O
- Inspiratory Positive Airway Pressure (IPAP): RCP advocate 10 cm H20 whilst BTS suggest 12-15 cm H2O
- back up rate: 15 breaths/min
- back up inspiration:expiration ratio: 1:3

123

Next question

Textbooks

High-yield textbook

Extended textbook

Links

British Thoracic Society 12 4

2016 BTS/ICS Guidelines for the Ventilatory Management of Acute Hypercapnic Respiratory Failure in Adults

Suggest link Report broken link

Media

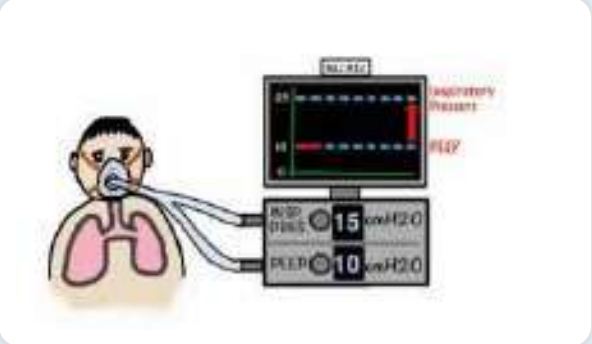

CPAP and Non-Invasive Ventilation in 5 minutes

Nick Smith - YouTube 31 2

Clinical Skills: BiPAP and CPAP

Osmosis - YouTube 👍 3 👎 7

Report broken media

Score: **17.8%**

1	✗
2	✗
3	✗
4	✗
5	✗
6	✗
7	✗
8	✗
9	✓
10	✓
11	✗
12	✗
13	✗
14	✓
15	✗
16	✓
17	✗
18	✗
19	✗
20	✗
21	✓
22	✓
23	✗

24	✗
25	✗
26	✗
27	✓
28	✗
29	✗
30	✓
31	✓
32	✗
33	✗
34	✗
35	✗
36	✗
37	✗
38	✗
39	✗
40	-
41	✗
42	✗
43	✗
44	✗
45	✓
46	✗
47	✗
48	✗
49	✗
50	✗
51	✗
52	✗
53	✗
54	✗
55	✗
56	✗
57	✗
58	✗
59	✗

60	✗
61	✗
62	✗
63	✗
64	✗
65	✗
66	✗
67	✓
68	✗
69	✓
70	✗
71	✗
72	✓
73	✗
74	✗
75	-

All contents of this site are © 2024 Passmedicine Limited

Back to top

A 59-year-old man is investigated for dyspnoea. Over the past 12 months he has become more breathless on exertion and has been troubled by a cough. He stopped smoking 10 years ago but prior to this had a 30-pack-year history. There is no history of chest pain, fever, night sweats or asbestos exposure. A CT chest is requested and shown below:

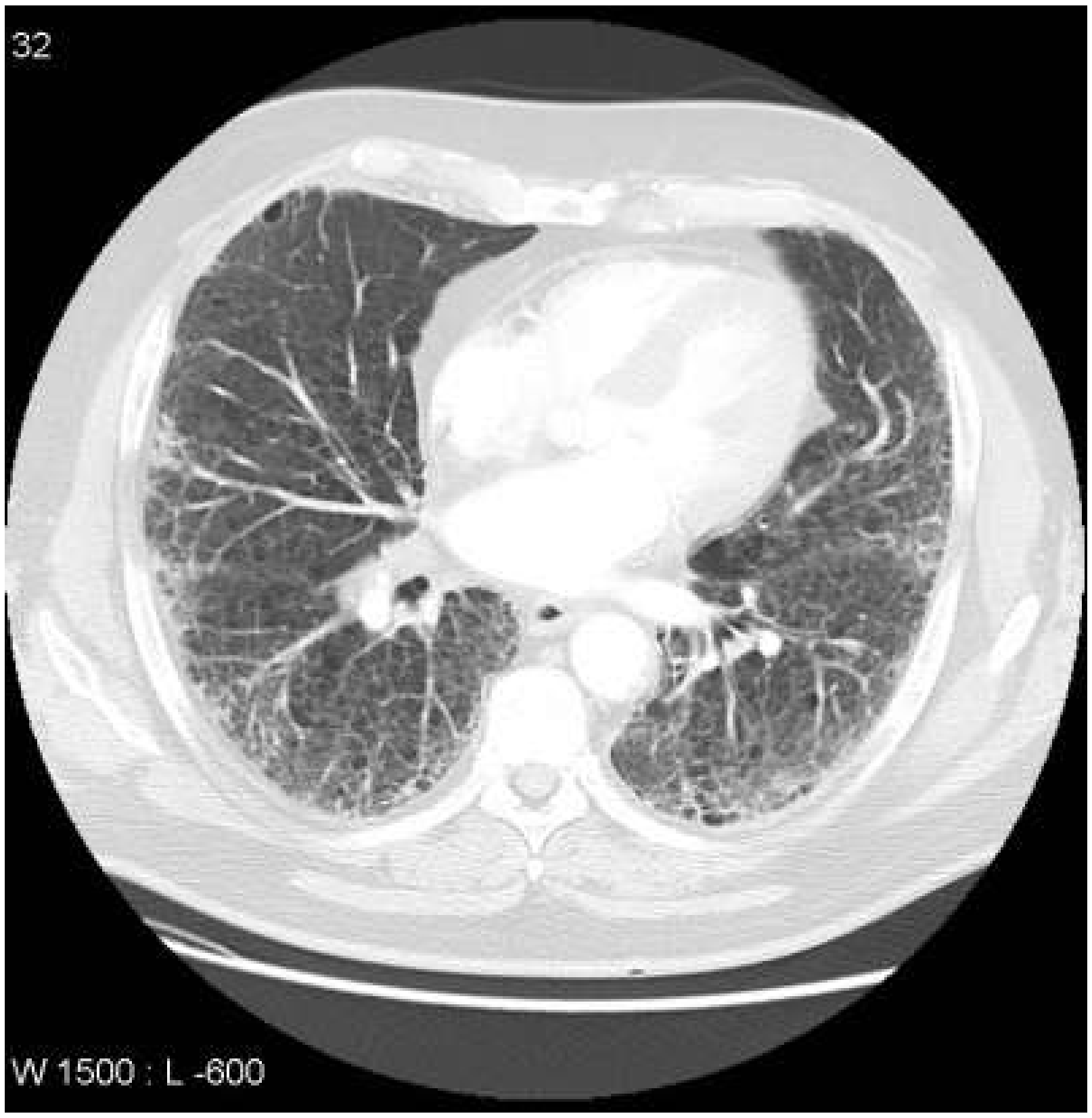

© Image used on license from Radiopaedia

What does the CT scan show?

- Lung cancer
- Idiopathic pulmonary fibrosis
- Multiple pulmonary embolisms
- Bronchiectasis
- Emphysema

Submit answer

Reference ranges

Score: **20.4%**

1	✗
2	✗
3	✗
4	✗
5	✗
6	✗
7	✗
8	✗
9	✓
10	✓
11	✗
12	✗
13	✗
14	✓
15	✗
16	✓
17	✗
18	✗
19	✗
20	✗
21	✓
22	✓
23	✗
24	✗
25	✗
26	✗
27	✓
28	✗
29	✗
30	✓

31	✓
32	✗
33	✗
34	✗
35	✗
36	✗
37	✗
38	✗
39	✗
40	-
41	✗
42	✗
43	✗
44	✗
45	✓
46	✗
47	✗
48	✗
49	✗
50	✗
51	-
52	-
53	-
54	-
55	-
56	-
57	-
58	-
59	-
60	-
61	-

All contents of this site are © 2024 Passmedicine Limited

Back to top

A 59-year-old man is investigated for dyspnoea. Over the past 12 months he has become more breathless on exertion and has been troubled by a cough. He stopped smoking 10 years ago but prior to this had a 30-pack-year history. There is no history of chest pain, fever, night sweats or asbestos exposure. A CT chest is requested and shown below:

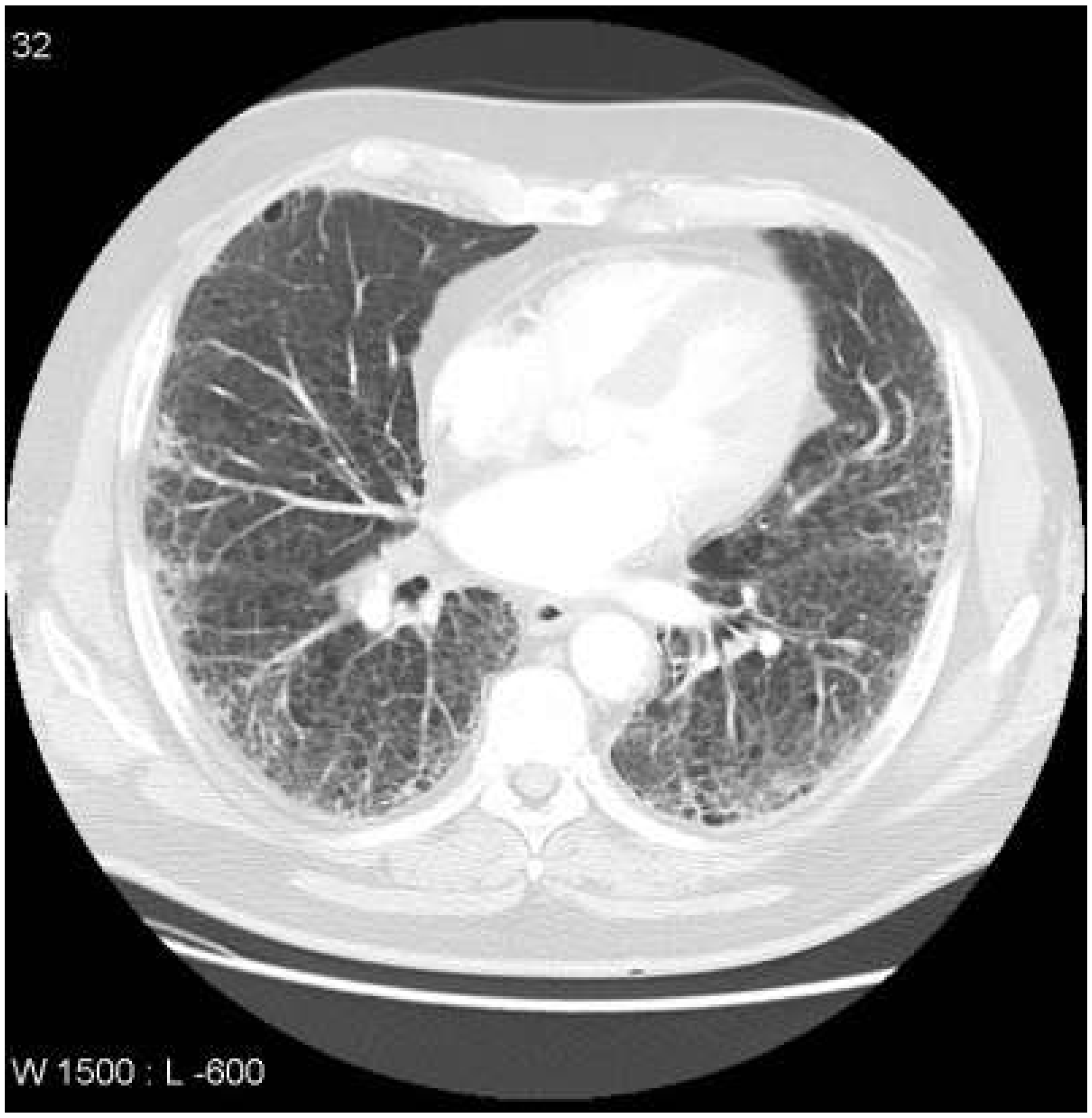

© Image used on license from Radiopaedia

What does the CT scan show?

Lung cancer	2%
Idiopathic pulmonary fibrosis	74%
Multiple pulmonary embolisms	1%
Bronchiectasis	15%
Emphysema	9%

The CT scan shows advanced pulmonary fibrosis including 'honeycombing'.

Next question

Idiopathic pulmonary fibrosis

Idiopathic pulmonary fibrosis (IPF, previously termed cryptogenic fibrosing alveolitis) is a chronic lung condition characterised by progressive fibrosis of the interstitium of the lungs. Whilst there are many causes of lung fibrosis (e.g. medications, connective tissue disease, asbestos) the term IPF is reserved when no underlying cause exists.

IPF is typically seen in patients aged 50-70 years and is twice as common in men.

Features

- progressive exertional dyspnoea
- bibasal fine end-inspiratory crepitations on auscultation
- dry cough
- clubbing

Diagnosis

- spirometry: classically a restrictive picture (FEV1 normal/decreased, FVC decreased, FEV1/FVC increased)
- impaired gas exchange: reduced transfer factor (TLCO)
- imaging: bilateral interstitial shadowing (typically small, irregular, peripheral opacities - 'ground-glass' - later progressing to 'honeycombing') may be seen on a chest x-ray but high-resolution CT scanning is the investigation of choice and required to make a diagnosis of IPF
- ANA positive in 30%, rheumatoid factor positive in 10% but this does not necessarily mean that the fibrosis is secondary to a connective tissue disease. Titres are usually low

Management

- pulmonary rehabilitation
- very few medications have been shown to give any benefit in IPF. There is some evidence that pirfenidone (an antifibrotic agent) may be useful in selected patients (see NICE guidelines)
- many patients will require supplementary oxygen and eventually a lung transplant

Prognosis

- poor, average life expectancy is around 3-4 years

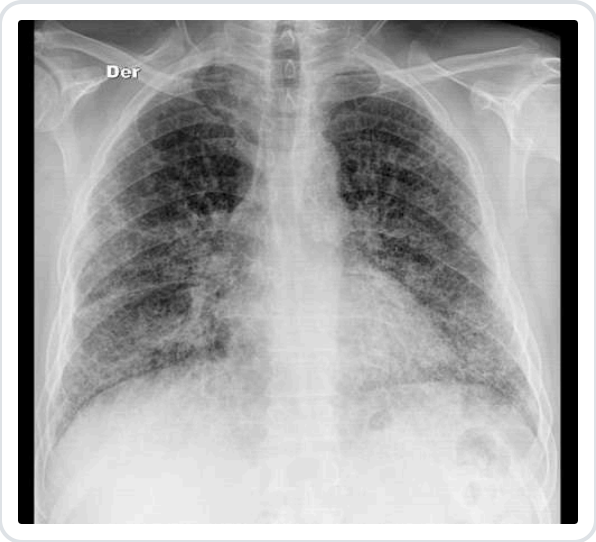

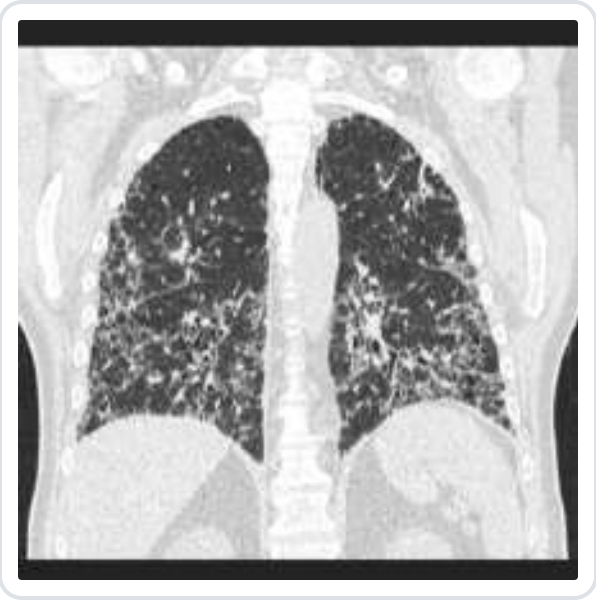

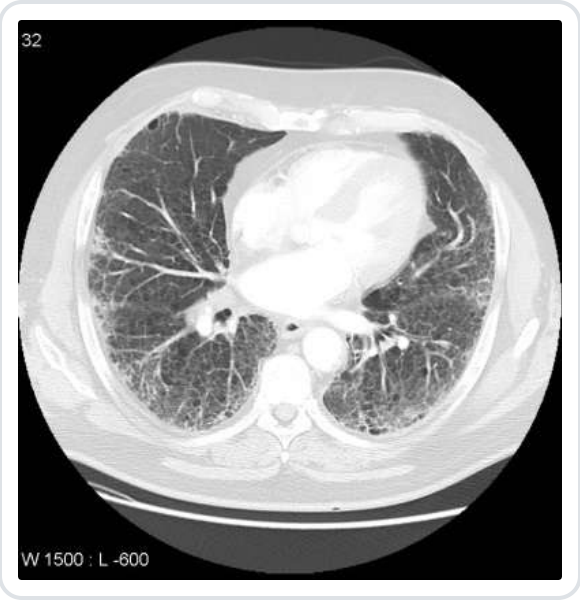

123

Next question

Textbooks

High-yield textbook

Extended textbook

Links

Royal College of Physicians 13 10

Update in diagnosis and management of interstitial lung disease

NICE 11 6

2013 Idiopathic pulmonary fibrosis guidelines

Suggest link

Report broken link

Media

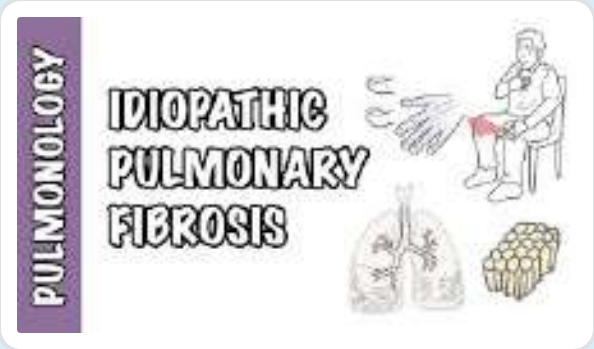

Idiopathic pulmonary fibrosis

Armando Hasudungan - YouTube 6 0

Interstitial Lung Disease (ILD) - Classification, pathophysiology, signs and symptoms

Armando Hasudungan - YouTube 5 0

Idiopathic pulmonary fibrosis

Osmosis - YouTube 4 0

Report broken media

Score: **17.8%**

1 ✗
2 ✗
3 ✗
4 ✗
5 ✗
6 ✗
7 ✗
8 ✗
9 ✓
10 ✓

11	✗
12	✗
13	✗
14	✓
15	✗
16	✓
17	✗
18	✗
19	✗
20	✗
21	✓
22	✓
23	✗
24	✗
25	✗
26	✗
27	✓
28	✗
29	✗
30	✓
31	✓
32	✗
33	✗
34	✗
35	✗
36	✗
37	✗
38	✗
39	✗
40	-
41	✗
42	✗
43	✗
44	✗
45	✓
46	✗

47	✗
48	✗
49	✗
50	✗
51	✗
52	✗
53	✗
54	✗
55	✗
56	✗
57	✗
58	✗
59	✗
60	✗
61	✗
62	✗
63	✗
64	✗
65	✗
66	✗
67	✓
68	✗
69	✓
70	✗
71	✗
72	✓
73	✗
74	✗
75	-

All contents of this site are © 2024 Passmedicine Limited

Back to top

A 75-year-old man with a background of chronic kidney disease, hypertension and type 2 diabetes presents to the Emergency Department with cough and breathlessness on minimal exertion. On examination, he has bilateral inspiratory crepitations and bilateral pitting oedema up to his sacrum. His chest radiograph shows a moderate right-sided effusion and smaller left-sided effusion.

What single management would be most appropriate?

- Fluid restriction to 1L daily
- IV furosemide
- Oral spironolactone
- Referral for dialysis
- Therapeutic aspiration of right-sided effusion

Submit answer

Reference ranges

Score: **20.4%**

1	✗
2	✗
3	✗
4	✗
5	✗
6	✗
7	✗

8	✗
9	✓
10	✓
11	✗
12	✗
13	✗
14	✓
15	✗
16	✓
17	✗
18	✗
19	✗
20	✗
21	✓
22	✓
23	✗
24	✗
25	✗
26	✗
27	✓
28	✗
29	✗
30	✓
31	✓
32	✗
33	✗
34	✗
35	✗
36	✗
37	✗
38	✗
39	✗
40	-
41	✗
42	✗
43	✗

44	✗
45	✓
46	✗
47	✗
48	✗
49	✗
50	✗
51	-
52	-
53	-
54	-
55	-
56	-
57	-
58	-
59	-
60	-
61	-
62	-

All contents of this site are © 2024 Passmedicine Limited

A 75-year-old man with a background of chronic kidney disease, hypertension and type 2 diabetes presents to the Emergency Department with cough and breathlessness on minimal exertion. On examination, he has bilateral inspiratory crepitations and bilateral pitting oedema up to his sacrum. His chest radiograph shows a moderate right-sided effusion and smaller left-sided effusion.

What single management would be most appropriate?

Fluid restriction to 1L daily	4%
IV furosemide	68%
Oral spironolactone	2%
Referral for dialysis	11%
Therapeutic aspiration of right-sided effusion	14%

In the assessment of a pleural effusions, if the clinical picture suggests a transudate, then you should treat the cause initially. If this does not resolve the effusion then perform a diagnostic aspiration

Important for me Less important

This patient presents with signs and symptoms of fluid overload, possibly due to worsening chronic kidney disease. While he has bilateral pleural effusions, they are most likely transudative and initial management should be to offload with **IV diuretics such as furosemide**. This may lead to the resolution of his fluid overload and pleural effusions.

Fluid restriction to 1-1.5L daily would be appropriate as part of medical management. It should be recommended alongside diuresis with medication as on its own it would not lead to significant offloading in a patient who is significantly fluid overloaded.

Oral spironolactone is a diuretic that would help to offload the patient. However, it is not commonly used as a first-line diuretic in a patient who is significantly fluid overloaded. It also cannot be given intravenously. Intravenous diuresis may be clinically more effective as patients who are significantly fluid overloaded may also have gut oedema and thus have poor absorption of oral diuretics.

The patient may need to eventually be **referred for dialysis** if they have end-stage renal disease. However, many patients with chronic kidney disease may be safely treated with diuretics without their renal function significantly worsening. IV diuresis should thus be attempted first. Should this fail, a renal physician could be consulted for advice, including regarding dialysis.

Therapeutic aspiration of the larger right-sided effusion involves aspirating up to 1.5L of fluid or inserting a chest drain to reduce the size of the effusion. This may relieve symptoms but would be unlikely to lead to the resolution of the contralateral effusion or improvement of this patient's peripheral oedema. If there are atypical features, or the patient has failed to respond to treatment such as with IV diuretics, he can be referred for therapeutic aspiration.

Discuss (4) Improve

Next question

Pleural effusion: investigation and management

The British Thoracic Society (BTS) produced guidelines in 2010 covering the investigation of patients with a pleural effusion.

Imaging

- posterioranterior (PA) chest x-rays should be performed in all patients
- ultrasound is recommended: it increases the likelihood of successful pleural aspiration and is sensitive for detecting pleural fluid septations
- contrast CT is now increasingly performed to investigate the underlying cause, particularly for exudative effusions

Pleural aspiration

- as above, ultrasound is recommended to reduce the complication rate
- a 21G needle and 50ml syringe should be used
- fluid should be sent for pH, protein, lactate dehydrogenase (LDH), cytology and microbiology

Light's criteria was developed in 1972 to help distinguish between a transudate and an exudate. The BTS recommend using the criteria for borderline cases:

- exudates have a protein level of >30 g/L, transudates have a protein level of <30 g/L
- if the protein level is between 25-35 g/L, Light's criteria should be applied. An exudate is likely if at least one of the following criteria are met:
    - pleural fluid protein divided by serum protein >0.5
    - pleural fluid LDH divided by serum LDH >0.6
    - pleural fluid LDH more than two-thirds the upper limits of normal serum LDH

Other characteristic pleural fluid findings:

- low glucose: rheumatoid arthritis, tuberculosis
- raised amylase: pancreatitis, oesophageal perforation
- heavy blood staining: mesothelioma, pulmonary embolism, tuberculosis

Pleural infection

All patients with a pleural effusion in association with sepsis or a pneumonic illness require diagnostic pleural fluid sampling

- if the fluid is purulent or turbid/cloudy a chest tube should be placed to allow drainage
- if the fluid is clear but the **pH is less than 7.2 in patients with suspected pleural infection a chest tube should be placed**

Management of recurrent pleural effusion

Options for managing patients with recurrent pleural effusions include:

- recurrent aspiration
- pleurodesis
- indwelling pleural catheter
- drug management to alleviate symptoms e.g. opioids to relieve dyspnoea

AI + Q 123

Next question >

Textbooks

High-yield textbook

Extended textbook

Links

British Thoracic Society 17 14

2023 Pleural disease guidelines

Royal College of Physicians 13 7

2012 Pleural infection review

Suggest link Report broken link

Media

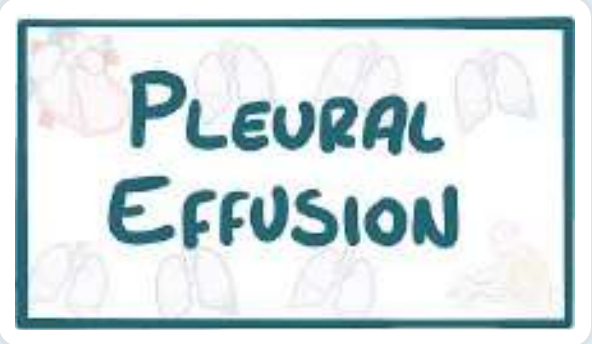

Pleural effusion

Osmosis - YouTube 8 1

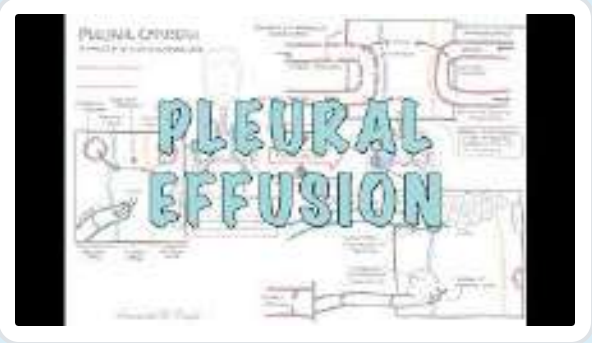

Pleural effusion

Armando Hasudungan - YouTube 6 1

Report broken media

Score: **17.8%**

1	✗
2	✗
3	✗
4	✗
5	✗
6	✗
7	✗
8	✗
9	✓
10	✓
11	✗
12	✗
13	✗
14	✓
15	✗
16	✓
17	✗
18	✗
19	✗
20	✗
21	✓
22	✓
23	✗
24	✗
25	✗
26	✗
27	✓
28	✗
29	✗
30	✓
31	✓
32	✗
33	✗

34	✗
35	✗
36	✗
37	✗
38	✗
39	✗
40	-
41	✗
42	✗
43	✗
44	✗
45	✓
46	✗
47	✗
48	✗
49	✗
50	✗
51	✗
52	✗
53	✗
54	✗
55	✗
56	✗
57	✗
58	✗
59	✗
60	✗
61	✗
62	✗
63	✗
64	✗
65	✗
66	✗
67	✓
68	✗
69	✓

70	✗
71	✗
72	✓
73	✗
74	✗
75	-

All contents of this site are © 2024 Passmedicine Limited

Back to top

A 66-year-old gentleman presented with a 4 day history of cough associated with green sputum. He has also been feeling more breathless, wheezy, feverish at times and having some right sided pleuritic chest pains. His past medical history includes chronic obstructive pulmonary disease, hypertension and diabetes. He has a 40 pack year history of smoking but he stopped 3 years ago.

On examination, he looks unwell, flushed and breathless at rest. His heart sounds are normal and he has right basal crackles with bronchial breathing and wheeze. There is no leg oedema or tenderness. His vital signs show pulse of 120 beats per minute, blood pressure of 120/70 mmHg, SaO2 = 89% on 24% oxygen, respiratory rate of 32 breaths per minute and T=38.5oC.

His Electrocardiogram reveals sinus tachycardia and the chest X-ray confirms right basal consolidation.

The following bloods tests have been obtained:

Hb	13.1 g/dl
Platelets	180 * 10^9/l
WBC	15.4 * 10^9/l

Na^+	135 mmol/l
K^+	4.9 mmol/l
Urea	10 mmol/l
Creatinine	120 µmol/l
CRP	180 mg/l

pH	7.28
pCO2	5.0 kPa
pO2	8.5 kPa
HCO3-	15 mEq/l

What is the best management?

- Intravenous fluids, intravenous antibiotics, steroids, nebulisers and non-invasive ventilation
- Intravenous fluids, intravenous antibiotics, nebulisers and steroids
- Intravenous fluids, oral antibiotics, nebulisers and steroids
- Oral fluids, intravenous antibiotics, nebulisers and non-invasive ventilation
- Oral fluids, oral antibiotics, nebulisers and steroids

Submit answer

Reference ranges

Score: **20.4%**

1	✗
2	✗
3	✗
4	✗
5	✗
6	✗
7	✗
8	✗
9	✓
10	✓
11	✗
12	✗
13	✗
14	✓
15	✗
16	✓
17	✗

18	✗
19	✗
20	✗
21	✓
22	✓
23	✗
24	✗
25	✗
26	✗
27	✓
28	✗
29	✗
30	✓
31	✓
32	✗
33	✗
34	✗
35	✗
36	✗
37	✗
38	✗
39	✗
40	-
41	✗
42	✗
43	✗
44	✗
45	✓
46	✗
47	✗
48	✗
49	✗
50	✗
51	-
52	-
53	-

54	-
55	-
56	-
57	-
58	-
59	-
60	-
61	-
62	-
63	-

All contents of this site are © 2024 Passmedicine Limited

A 66-year-old gentleman presented with a 4 day history of cough associated with green sputum. He has also been feeling more breathless, wheezy, feverish at times and having some right sided pleuritic chest pains. His past medical history includes chronic obstructive pulmonary disease, hypertension and diabetes. He has a 40 pack year history of smoking but he stopped 3 years ago.

On examination, he looks unwell, flushed and breathless at rest. His heart sounds are normal and he has right basal crackles with bronchial breathing and wheeze. There is no leg oedema or tenderness. His vital signs show pulse of 120 beats per minute, blood pressure of 120/70 mmHg, SaO2 = 89% on 24% oxygen, respiratory rate of 32 breaths per minute and T=38.5oC.

His Electrocardiogram reveals sinus tachycardia and the chest X-ray confirms right basal consolidation.

The following bloods tests have been obtained:

Hb	13.1 g/dl
Platelets	180 * 10^9/l
WBC	15.4 * 10^9/l

Na^+	135 mmol/l
K^+	4.9 mmol/l
Urea	10 mmol/l
Creatinine	120 µmol/l
CRP	180 mg/l

pH	7.28
pCO2	5.0 kPa
pO2	8.5 kPa
HCO3-	15 mEq/l

What is the best management?

- Intravenous fluids, intravenous antibiotics, steroids, nebulisers and non-invasive ventilation 43%
- Intravenous fluids, intravenous antibiotics, nebulisers and steroids 47%
- Intravenous fluids, oral antibiotics, nebulisers and steroids 2%
- Oral fluids, intravenous antibiotics, nebulisers and non-invasive ventilation 5%
- Oral fluids, oral antibiotics, nebulisers and steroids 2%

The aim of this question aims to increase awareness about the use of non-invasive ventilation (NIV) in patients with chronic obstructive pulmonary disease (COPD).

The guidelines mention that NIV should be considered in patients with COPD exacerbation in whom a respiratory acidosis persists despite immediate maximum standard medical treatment on controlled oxygen for no more than one hour. Patients with COPD can develop community acquired pneumonia (CAP) with metabolic acidosis due to the sepsis, but in these cases NIV is not indicated.

This patient presented with CAP and he had metabolic acidosis. His CURB65 score is 3 and he also has acute kidney injury. He should be treated with intravenous fluids, intravenous antibiotics, nebulisers and steroids but not NIV.

Discuss (11) | Improve

Next question

Non-invasive ventilation

The British Thoracic Society (BTS) published guidelines in 2002 on the use of non-invasive ventilation in acute respiratory failure. Following these the Royal College of Physicians published guidelines in 2008.

Non-invasive ventilation - key indications

- COPD with respiratory acidosis pH 7.25-7.35
  - the BTS guidelines state that NIV can be used in patients who are more acidotic (i.e. pH < 7.25) but that a greater degree of monitoring is required (e.g. HDU) and a lower threshold for intubation and ventilation should be used

- type II respiratory failure secondary to chest wall deformity, neuromuscular disease or obstructive sleep apnoea
- cardiogenic pulmonary oedema unresponsive to CPAP
- weaning from tracheal intubation

Recommended initial settings for bi-level pressure support in COPD

- Expiratory Positive Airway Pressure (EPAP): 4-5 cm H2O
- Inspiratory Positive Airway Pressure (IPAP): RCP advocate 10 cm H20 whilst BTS suggest 12-15 cm H2O
- back up rate: 15 breaths/min
- back up inspiration:expiration ratio: 1:3

+ Q 123

Next question >

Textbooks

High-yield textbook

Extended textbook

Links

British Thoracic Society 12 4

2016 BTS/ICS Guidelines for the Ventilatory Management of Acute Hypercapnic Respiratory Failure in Adults

Suggest link Report broken link

Media

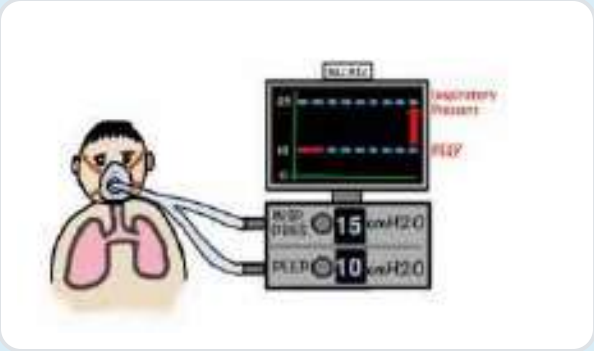

CPAP and Non-Invasive Ventilation in 5 minutes

Nick Smith - YouTube 31 2

Clinical Skills: BiPAP and CPAP

Osmosis - YouTube 3 7

Report broken media

Score: **17.8%**

1	✗
2	✗
3	✗
4	✗
5	✗
6	✗
7	✗
8	✗
9	✓
10	✓
11	✗
12	✗
13	✗
14	✓
15	✗
16	✓
17	✗

18	✗
19	✗
20	✗
21	✓
22	✓
23	✗
24	✗
25	✗
26	✗
27	✓
28	✗
29	✗
30	✓
31	✓
32	✗
33	✗
34	✗
35	✗
36	✗
37	✗
38	✗
39	✗
40	-
41	✗
42	✗
43	✗
44	✗
45	✓
46	✗
47	✗
48	✗
49	✗
50	✗
51	✗
52	✗
53	✗

54	✗
55	✗
56	✗
57	✗
58	✗
59	✗
60	✗
61	✗
62	✗
63	✗
64	✗
65	✗
66	✗
67	✓
68	✗
69	✓
70	✗
71	✗
72	✓
73	✗
74	✗
75	-

All contents of this site are © 2024 Passmedicine Limited

Back to top

A 69-year-old man with a history of rheumatoid arthritis well controlled on methotrexate presents with gradual pain and swelling in his wrists and ankles.

The pain is described as a dull ache that is intermittent, often worse in the evenings. There is associated swelling which can sometimes feel warm. He has tried regular paracetamol but this has had limited effect.

He also describes a chronic cough and shortness of breath on exertion for the past 6 months that he has not mentioned to his GP. There has been no haemoptysis and he denies any fevers. His wife has noticed that he has been losing weight recently.

He has a past medical history of rheumatoid arthritis, hypertension, hypercholesterolaemia and type 2 diabetes mellitus. He currently takes methotrexate weekly, folic acid 5mg weekly, ramipril 5mg, simvastatin 20mg at night, metformin 500mg three times a day and paracetamol 1g four times daily.

He is a retired accountant and a current smoker with a 50 pack year smoking history. He drinks approximately 30 units of beer a week. He denies any recent foreign travel.

On examination, he is cachectic and short of breath on exertion. His pulse is 80/min and regular, blood pressure 140/93 mmHg, oxygen saturations of 93% on air. He has marked fingernail clubbing. Examination of his wrists reveals slightly swollen and tender joints. Swan neck and ulnar deviation deformities are noted in both hands. Other than his wrists, no other joint abnormalities are detected. Examination of the peripheral nervous system is normal.

Examination of his chest is normal with no focal consolidation.

Initial bloods are as follows:

Na+	134 mmol/L
K+	3.9 mmol/L
Urea	7.8 mmol/L
Creatinine	105 µmol/L
Hb	100 g/L
WBC	6.0x10^9/L
Platelets	200x10^9/L

LFTs	Normal
Serum uric acid	410 µmol/L
CRP	12 mg/L

Chest X-ray reveals a discrete opacification at the periphery of the right middle lobe.

What is the most likely underlying diagnosis?

- Methotrexate induced pulmonary fibrosis
- Bronchogenic carcinoma
- Caplan's syndrome
- Chronic obstructive pulmonary disease
- Pneumonia

Submit answer

Reference ranges

Score: **20.4%**

1 ✗
2 ✗
3 ✗
4 ✗
5 ✗
6 ✗
7 ✗
8 ✗
9 ✓
10 ✓

11	✗
12	✗
13	✗
14	✓
15	✗
16	✓
17	✗
18	✗
19	✗
20	✗
21	✓
22	✓
23	✗
24	✗
25	✗
26	✗
27	✓
28	✗
29	✗
30	✓
31	✓
32	✗
33	✗
34	✗
35	✗
36	✗
37	✗
38	✗
39	✗
40	-
41	✗
42	✗
43	✗
44	✗
45	✓
46	✗

47	✕
48	✕
49	✕
50	✕
51	-
52	-
53	-
54	-
55	-
56	-
57	-
58	-
59	-
60	-
61	-
62	-
63	-
64	-

All contents of this site are © 2024 Passmedicine Limited

A 69-year-old man with a history of rheumatoid arthritis well controlled on methotrexate presents with gradual pain and swelling in his wrists and ankles.

The pain is described as a dull ache that is intermittent, often worse in the evenings. There is associated swelling which can sometimes feel warm. He has tried regular paracetamol but this has had limited effect.

He also describes a chronic cough and shortness of breath on exertion for the past 6 months that he has not mentioned to his GP. There has been no haemoptysis and he denies any fevers. His wife has noticed that he has been losing weight recently.

He has a past medical history of rheumatoid arthritis, hypertension, hypercholesterolaemia and type 2 diabetes mellitus. He currently takes methotrexate weekly, folic acid 5mg weekly, ramipril 5mg, simvastatin 20mg at night, metformin 500mg three times a day and paracetamol 1g four times daily.

He is a retired accountant and a current smoker with a 50 pack year smoking history. He drinks approximately 30 units of beer a week. He denies any recent foreign travel.

On examination, he is cachectic and short of breath on exertion. His pulse is 80/min and regular, blood pressure 140/93 mmHg, oxygen saturations of 93% on air. He has marked fingernail clubbing. Examination of his wrists reveals slightly swollen and tender joints. Swan neck and ulnar deviation deformities are noted in both hands. Other than his wrists, no other joint abnormalities are detected. Examination of the peripheral nervous system is normal.

Examination of his chest is normal with no focal consolidation.

Initial bloods are as follows:

Na+	134 mmol/L
K+	3.9 mmol/L
Urea	7.8 mmol/L
Creatinine	105 µmol/L
Hb	100 g/L
WBC	6.0x10^9/L
Platelets	200x10^9/L

LFTs	Normal
Serum uric acid	410 μmol/L
CRP	12 mg/L

Chest X-ray reveals a discrete opacification at the periphery of the right middle lobe.

What is the most likely underlying diagnosis?

Methotrexate induced pulmonary fibrosis	12%
Bronchogenic carcinoma	55%
Caplan's syndrome	32%
Chronic obstructive pulmonary disease	1%
Pneumonia	0%

This man has a strong smoking history, chronic cough, weight loss and an abnormal chest x-ray. He also has symptoms suggestive of hypertrophic pulmonary osteoarthropathy which is associated with bronchogenic carcinoma in 90% of cases. His case would warrant urgent investigation.

Pneumonia is unlikely in the context of normal inflammatory markers

Methotrexate-induced fibrosis is unlikely in view of the chest x-ray findings and normal auscultation of the chest.

COPD may be a concomitant diagnosis in a man with such an extensive smoking history, but the presence of weight loss and hypertrophic pulmonary osteoarthropathy should raise suspicions of the more pressing diagnosis of malignancy.

Caplan's syndrome is an interstitial lung disease described in coal miners with rheumatoid arthritis. Chest x-ray usually demonstrates multiple nodules often at the lung peripheries.

Discuss (4) Improve

Next question

Lung cancer: referral

The 2015 NICE cancer referral guidelines gave the following advice:

Refer people using a suspected cancer pathway referral (for an appointment within 2 weeks) for lung cancer if they:

- have chest x-ray findings that suggest lung cancer
- are aged 40 and over with unexplained haemoptysis

Offer an urgent chest x-ray (to be performed within 2 weeks) to assess for lung cancer in people aged 40 and over if they have 2 or more of the following unexplained symptoms, or if they have ever smoked and have 1 or more of the following unexplained symptoms:

- cough
- fatigue
- shortness of breath
- chest pain
- weight loss
- appetite loss

Consider an urgent chest x-ray (to be performed within 2 weeks) to assess for lung cancer in people aged 40 and over with any of the following:

- persistent or recurrent chest infection
- finger clubbing
- supraclavicular lymphadenopathy or persistent cervical lymphadenopathy
- chest signs consistent with lung cancer
- thrombocytosis

AI + Q 123

Next question ›

Textbooks

High-yield textbook

Extended textbook

Links

NICE

2015 Lung cancer referral guidelines

7 9

Suggest link

Report broken link

Score: **17.8%**

1	✗
2	✗
3	✗
4	✗
5	✗
6	✗
7	✗
8	✗
9	✓
10	✓
11	✗
12	✗
13	✗
14	✓
15	✗
16	✓
17	✗
18	✗
19	✗
20	✗

21	✓
22	✓
23	✗
24	✗
25	✗
26	✗
27	✓
28	✗
29	✗
30	✓
31	✓
32	✗
33	✗
34	✗
35	✗
36	✗
37	✗
38	✗
39	✗
40	-
41	✗
42	✗
43	✗
44	✗
45	✓
46	✗
47	✗
48	✗
49	✗
50	✗
51	✗
52	✗
53	✗
54	✗
55	✗
56	✗

57	✗
58	✗
59	✗
60	✗
61	✗
62	✗
63	✗
64	✗
65	✗
66	✗
67	✓
68	✗
69	✓
70	✗
71	✗
72	✓
73	✗
74	✗
75	-

All contents of this site are © 2024 Passmedicine Limited

You are asked to review the results of a long term oxygen therapy (LTOT) assessment for a 74-year-old female. She has a past medical history of COPD. She has developed dyspnoea at rest.

Results of the LTOT assessment are as follows:

ABG on air:

PaO2	7.1 kPa
PCO2	5.1 kPa
pH	7.41
HCO3	26

ABG after 1 litre of O2 via a nasal cannula:

PaO2	9.3 kPa
PCO2	6.5 kPa
pH	7.33
HCO3	26

The patient feels less short of breath at the end of the trial.

You decide that further medical optimisation and reassessment of arterial blood gas in 4 weeks is required.

She returns to the clinic in 4 weeks time. Her COPD appears to be stable and the medical management is optimised with salbutamol, ipratropium and carbocysteine.

A repeat LTOT assessment is as follows:

ABG on air:

PaO2	6.9 kPa
PCO2	5.0 kPa
pH	7.42
HCO3	26

ABG after 1 litre of O2 via a nasal cannula:

PaO2	9.5 kPa
PCO2	6.6 kPa
pH	7.32
HCO3	26

How will you manage this patient?

- LTOT with nocturnal BiPAP ×
- LTOT ×
- LTOT with nocturnal CPAP ×
- Decline LTOT ×
- Palliation of breathlessness with morphine ×

Submit answer

Reference ranges

Score: **20.4%**

1 ×
2 ×
3 ×
4 ×
5 ×
6 ×
7 ×
8 ×

9	✓
10	✓
11	✗
12	✗
13	✗
14	✓
15	✗
16	✓
17	✗
18	✗
19	✗
20	✗
21	✓
22	✓
23	✗
24	✗
25	✗
26	✗
27	✓
28	✗
29	✗
30	✓
31	✓
32	✗
33	✗
34	✗
35	✗
36	✗
37	✗
38	✗
39	✗
40	-
41	✗
42	✗
43	✗
44	✗

45	✓
46	✗
47	✗
48	✗
49	✗
50	✗
51	-
52	-
53	-
54	-
55	-
56	-
57	-
58	-
59	-
60	-
61	-
62	-
63	-
64	-
65	-

All contents of this site are © 2024 Passmedicine Limited

You are asked to review the results of a long term oxygen therapy (LTOT) assessment for a 74-year-old female. She has a past medical history of COPD. She has developed dyspnoea at rest.

Results of the LTOT assessment are as follows:

ABG on air:

PaO2	7.1 kPa
PCO2	5.1 kPa
pH	7.41
HCO3	26

ABG after 1 litre of O2 via a nasal cannula:

PaO2	9.3 kPa
PCO2	6.5 kPa
pH	7.33
HCO3	26

The patient feels less short of breath at the end of the trial.

You decide that further medical optimisation and reassessment of arterial blood gas in 4 weeks is required.

She returns to the clinic in 4 weeks time. Her COPD appears to be stable and the medical management is optimised with salbutamol, ipratropium and carbocysteine.

A repeat LTOT assessment is as follows:

ABG on air:

PaO2	6.9 kPa
PCO2	5.0 kPa
pH	7.42
HCO3	26

ABG after 1 litre of O2 via a nasal cannula:

PaO2	9.5 kPa
PCO2	6.6 kPa
pH	7.32
HCO3	26

How will you manage this patient?

LTOT with nocturnal BiPAP	51%
LTOT	12%
LTOT with nocturnal CPAP	11%
Decline LTOT	22%
Palliation of breathlessness with morphine	4%

Patients who develop a respiratory acidosis and/or a rise in PaCO2 of >1 kPa (7.5 mmHg) during an LTOT assessment on two repeated occasions, while apparently clinically stable, should only have domiciliary oxygen ordered in conjunction with nocturnal ventilatory support

Important for me Less important

The ABG on room air meets the criteria for LTOT as the PaO2 is < 7.3 kPa. After a 1 hour trial of low flow oxygen, the patients symptoms have improved, and his PaO2 has significantly improved. However it is important to note that his PCO2 has significantly increased resulting in a respiratory acidosis.

Patients who develop a respiratory acidosis and/or a rise in PaCO2 of >1 kPa (7.5 mmHg) during an LTOT assessment may have clinically unstable disease. These patients should undergo further medical optimisation and be reassessed after 4 weeks.

The patient is medically optimised and returns after 4 weeks for further LTOT assessment. This again demonstrates a respiratory acidosis with oxygen therapy. Patients who develop a respiratory acidosis and/or a rise in PaCO2 of >1 kPa (7.5 mmHg) during an LTOT assessment on two repeated occasions, while apparently clinically stable, should only have domiciliary oxygen ordered in

conjunction with nocturnal ventilatory support. BiPAP is the modality of choice for treating CO2 retention.

Discuss (5) Improve

Next question

COPD: long-term oxygen therapy

The 2018 NICE guidelines on COPD clearly define which patients should be assessed for and offered long-term oxygen therapy (LTOT). Patients who receive LTOT should breathe supplementary oxygen for at least 15 hours a day. Oxygen concentrators are used to provide a fixed supply for LTOT.

Assess patients if any of the following:

- very severe airflow obstruction (FEV1 < 30% predicted). Assessment should be 'considered' for patients with severe airflow obstruction (FEV1 30-49% predicted)
- cyanosis
- polycythaemia
- peripheral oedema
- raised jugular venous pressure
- oxygen saturations less than or equal to 92% on room air

Assessment is done by measuring arterial blood gases on 2 occasions at least 3 weeks apart in patients with stable COPD on optimal management.

Offer LTOT to patients with a pO2 of < 7.3 kPa or to those with a pO2 of 7.3 - 8 kPa and one of the following:

- secondary polycythaemia
- peripheral oedema
- pulmonary hypertension

In terms of smoking, NICE advise the following:

- do not offer LTOT to people who continue to smoke despite being offered smoking cessation advice and treatment, and referral to specialist stop smoking services.

NICE suggest that a structured risk assessment is carried out before offering LTOT, including:

- the risks of falls from tripping over the equipment

- the risks of burns and fires, and the increased risk of these for people who live in homes where someone smokes (including e-cigarettes)

+ Q 123

Next question >

B I A

Textbooks

High-yield textbook

Extended textbook

Links

NICE 17 6

2018 COPD guidelines

Suggest link Report broken link

Score: **17.8%**

1	✗
2	✗
3	✗
4	✗
5	✗
6	✗
7	✗

8	✗
9	✓
10	✓
11	✗
12	✗
13	✗
14	✓
15	✗
16	✓
17	✗
18	✗
19	✗
20	✗
21	✓
22	✓
23	✗
24	✗
25	✗
26	✗
27	✓
28	✗
29	✗
30	✓
31	✓
32	✗
33	✗
34	✗
35	✗
36	✗
37	✗
38	✗
39	✗
40	-
41	✗
42	✗
43	✗

44	✗
45	✓
46	✗
47	✗
48	✗
49	✗
50	✗
51	✗
52	✗
53	✗
54	✗
55	✗
56	✗
57	✗
58	✗
59	✗
60	✗
61	✗
62	✗
63	✗
64	✗
65	✗
66	✗
67	✓
68	✗
69	✓
70	✗
71	✗
72	✓
73	✗
74	✗
75	-

All contents of this site are © 2024 Passmedicine Limited

Back to top

A 67-year-old man presents to the emergency department with a 24-hour history of shortness of breath. Also, he complains of a worsening cough with green sputum. He has a 20 pack-year smoking history and drinks 10 units of alcohol a week. He has a past medical history of COPD, for which he takes inhaled corticosteroids, formoterol and salbutamol.

On auscultation of his chest, there are crackles at the right base, no wheezes. He has a respiratory rate of 23 breaths per minute, a heart rate of 98bpm, BP is 115/62mmHg, SpO2 is 91% on 4L through a 28% Venturi mask, and he is afebrile.

A chest X-ray shows right lower zone consolidation.

An arterial blood gas shows the following:

HCO3	28	(22-26 meq/L)
pH	7.37	(7.35 - 7.45)
pCO2	6.2	(4.5 - 6.0 kPa)
pO2	9.8	(10 - 14 kPa)

You have prescribed appropriate IV fluids and administered IV co-amoxiclav and clarithromycin.

Which of the following is the most appropriate additional treatment?

- BIPAP
- Decrease oxygen
- Increase oxygen
- Prednisolone
- Prednisolone and increase oxygen

Submit answer

Reference ranges

Score: **20.4%**

1	✗
2	✗
3	✗
4	✗
5	✗
6	✗
7	✗
8	✗
9	✓
10	✓
11	✗
12	✗
13	✗
14	✓
15	✗
16	✓
17	✗
18	✗
19	✗
20	✗
21	✓
22	✓
23	✗
24	✗
25	✗
26	✗
27	✓
28	✗
29	✗
30	✓
31	✓
32	✗

33	✗
34	✗
35	✗
36	✗
37	✗
38	✗
39	✗
40	-
41	✗
42	✗
43	✗
44	✗
45	✓
46	✗
47	✗
48	✗
49	✗
50	✗
51	-
52	-
53	-
54	-
55	-
56	-
57	-
58	-
59	-
60	-
61	-
62	-
63	-
64	-
65	-
66	-

All contents of this site are © 2024 Passmedicine Limited

Back to top

A 67-year-old man presents to the emergency department with a 24-hour history of shortness of breath. Also, he complains of a worsening cough with green sputum. He has a 20 pack-year smoking history and drinks 10 units of alcohol a week. He has a past medical history of COPD, for which he takes inhaled corticosteroids, formoterol and salbutamol.

On auscultation of his chest, there are crackles at the right base, no wheezes. He has a respiratory rate of 23 breaths per minute, a heart rate of 98bpm, BP is 115/62mmHg, SpO2 is 91% on 4L through a 28% Venturi mask, and he is afebrile.

A chest X-ray shows right lower zone consolidation.

An arterial blood gas shows the following:

HCO3	28	(22-26 meq/L)
pH	7.37	(7.35 - 7.45)
pCO2	6.2	(4.5 - 6.0 kPa)
pO2	9.8	(10 - 14 kPa)

You have prescribed appropriate IV fluids and administered IV co-amoxiclav and clarithromycin.

Which of the following is the most appropriate additional treatment?

- BIPAP 23%
- Decrease oxygen 18%
- Increase oxygen 6%
- Prednisolone 45%
- Prednisolone and increase oxygen 8%

Patients diagnosed with pneumonia who have COPD should be given corticosteroids even if no evidence of the COPD being exacerbated

Important for me Less important

This man is suffering from community-acquired pneumonia (CAP). Patients diagnosed with pneumonia who have COPD should be given corticosteroids even if no evidence of the COPD being exacerbated.

We do not routinely give non-invasive ventilation (NIV) or continuous positive airways pressure (CPAP) support in patients with respiratory failure due to CAP, though it ought to be considered if there is evidence of type 2 respiratory failure.

If not critically ill and history of moderate-severe COPD or other condition predisposing to hypercapnia (e.g. neuromuscular disease) then aim for 88-92% with a 28% Venturi mask initially. Then do a blood gas:

- If pH<7.35 and pCO2 >6KPa then consider NIV
- If pH>7.35 and pCO2 >6KPa then continue with 88-92% with a repeat in 30-60mins
- If pH>7.35 and pCO2 <6KPa titrate O2 to sats 94-98% with a repeat in 30-60mins

Decreasing his oxygen supply would not be appropriate as the single best answer, as his oxygen sats are in an appropriate range and he also requires corticosteroids.

Essentially, this man likely has a degree of chronic CO2 retention, as indicated by the fact that he has a compensatory metabolic alkalosis which has managed to maintain his pH within a normal range. Thus increasing his oxygen at this point is not necessary, as he may well be relying on his low O2 to drive his respiratory rate, and a target of 88-92% is satisfactory. As he is not acidotic NIV is not indicated at present.

Discuss (5) Improve

Next question

Pneumonia: assessment and management

Primary care setting

NICE recommends that patients should initially be assessed in primary care using the CRB65 criteria:

Criterion	Marker
C	Confusion (abbreviated mental test score <= 8/10)
R	Respiration rate >= 30/min
B	Blood pressure: systolic <= 90 mmHg and/or diastolic <= 60 mmHg
65	Aged >= 65 years

Patients are stratified for risk of death as follows:
- 0: low risk (less than 1% mortality risk)
    - NICE recommend that treatment at home should be considered (alongside clinical judgement)
- 1 or 2: intermediate risk (1-10% mortality risk)
    - NICE recommend that ' hospital assessment should be considered (particularly for people with a score of 2)'
- 3 or 4: high risk (more than 10% mortality risk)
    - NICE recommend urgent admission to hospital

NICE also mention point-of-care CRP test. This is currently not widely available but they make the following recommendation with reference to the use of antibiotic therapy:
- CRP < 20 mg/L - do not routinely offer antibiotic therapy
- CRP 20 - 100 mg/L - consider a delayed antibiotic prescription
- CRP > 100 mg/L - offer antibiotic therapy

Secondary care setting

Note that in hospital, once blood tests are available the CURB65, rather than the CRB65, can be used. This adds an extra criterion of urea > 7 mmol/L:

Criterion	Marker
C	Confusion (abbreviated mental test score <= 8/10)
U	urea > 7 mmol/L
R	Respiration rate >= 30/min

Criterion	Marker
B	Blood pressure: systolic <= 90 mmHg and/or diastolic <= 60 mmHg
65	Aged >= 65 years

NICE recommend, in conjunction with clinical judgement:

- consider home-based care for patients with a CURB65 score of 0 or 1 - low risk (less than 3% mortality risk)
- consider hospital-based care for patients with a CURB65 score of 2 or more - intermediate risk (3-15% mortality risk)
- consider intensive care assessment for patients with a CURB65 score of 3 or more - high risk (more than 15% mortality risk)

Investigations

- chest x-ray
- in intermediate or high-risk patients NICE recommend blood and sputum cultures, pneumococcal and legionella urinary antigen tests
- CRP monitoring is recommend for admitted patients to help determine response to treatment

Management of low-severity community acquired pneumonia

- amoxicillin is first-line
- if penicillin allergic then use a macrolide or tetracycline
- NICE now recommend a 5 day course of antibiotics for patients with low severity community acquired pneumonia

Management of moderate and high-severity community acquired pneumonia

- dual antibiotic therapy is recommended with amoxicillin and a macrolide
- a 7-10 day course is recommended
- NICE recommend considering a beta-lactamase stable penicillin such as co-amoxiclav, ceftriaxone or piperacillin with tazobactam and a macrolide in high-severity community acquired pneumonia

Discharge criteria and advice post-discharge

NICE recommend that patients are not routinely discharged if in the past 24 hours they have had 2 or more of the following findings:

- temperature higher than 37.5°C

- respiratory rate 24 breaths per minute or more
- heart rate over 100 beats per minute
- systolic blood pressure 90 mmHg or less
- oxygen saturation under 90% on room air
- abnormal mental status
- inability to eat without assistance.

They also recommend delaying discharge if the temperature is higher than 37.5°C.

NICE recommend that the following information is given to patients with pneumonia in terms of how quickly their symptoms should symptoms should resolve:

Time	Progress
1 week	Fever should have resolved
4 weeks	Chest pain and sputum production should have substantially reduced
6 weeks	Cough and breathlessness should have substantially reduced
3 months	Most symptoms should have resolved but fatigue may still be present
6 months	Most people will feel back to normal.

All cases of pneumonia should have a repeat chest X-ray at 6 weeks after clinical resolution to ensure that the consolidation has resolved and there is no underlying secondary abnormalities (e.g. a lung tumour).

AI + Q 123

Next question >

Textbooks

High-yield textbook

Extended textbook

Links

NICE

2014 Pneumonia in adults: diagnosis and management

16 11

Clinical Knowledge Summaries

Community-acquired pneumonia

14 7

MDCalc

CURB-65 scoring tool

17 5

Suggest link

Report broken link

Media

Pneumonia

Osmosis - YouTube 4 0

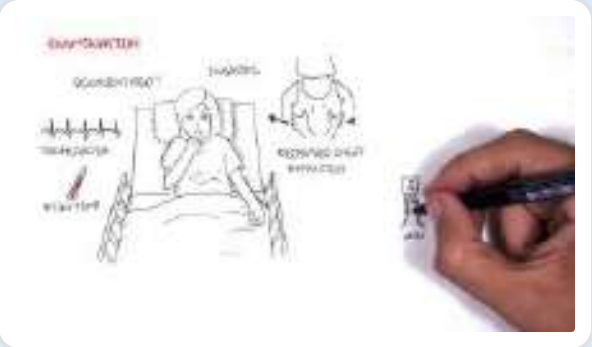

Community Acquired Pneumonia

Armando Hasudungan - YouTube 3 0

Report broken media

Score: **17.8%**

1	✗
2	✗
3	✗
4	✗
5	✗
6	✗
7	✗
8	✗
9	✓
10	✓
11	✗
12	✗
13	✗
14	✓
15	✗
16	✓
17	✗
18	✗
19	✗
20	✗
21	✓
22	✓
23	✗
24	✗
25	✗
26	✗
27	✓
28	✗
29	✗
30	✓
31	✓
32	✗
33	✗

34	✗
35	✗
36	✗
37	✗
38	✗
39	✗
40	-
41	✗
42	✗
43	✗
44	✗
45	✓
46	✗
47	✗
48	✗
49	✗
50	✗
51	✗
52	✗
53	✗
54	✗
55	✗
56	✗
57	✗
58	✗
59	✗
60	✗
61	✗
62	✗
63	✗
64	✗
65	✗
66	✗
67	✓
68	✗
69	✓

70	✗
71	✗
72	✓
73	✗
74	✗
75	-

All contents of this site are © 2024 Passmedicine Limited

A 59-year-old man is investigated for increasing shortness-of-breath. This has been getting progressively worse for the past 6 months and is associated with a dry cough. He has received two courses of antibiotics from his GP which only temporarily improved his symptoms. He was diagnosed with asthma as a child but has not had to use an inhaler since he was around 10-years-old. He stopped smoking 20 years ago.

On examination he is noted to have scattered crackles bilaterally, predominantly in the bases. Oxygen saturations are 96% on room air. Pulse, blood pressure and temperature are normal.

Spirometry is arranged:

FEV1	2.2 L (predicted 3.8 L)
FVC	2.7 L (predicted 4.5 L)
FEV1/FVC	81% (normal > 75%)

A chest x-ray is arranged:

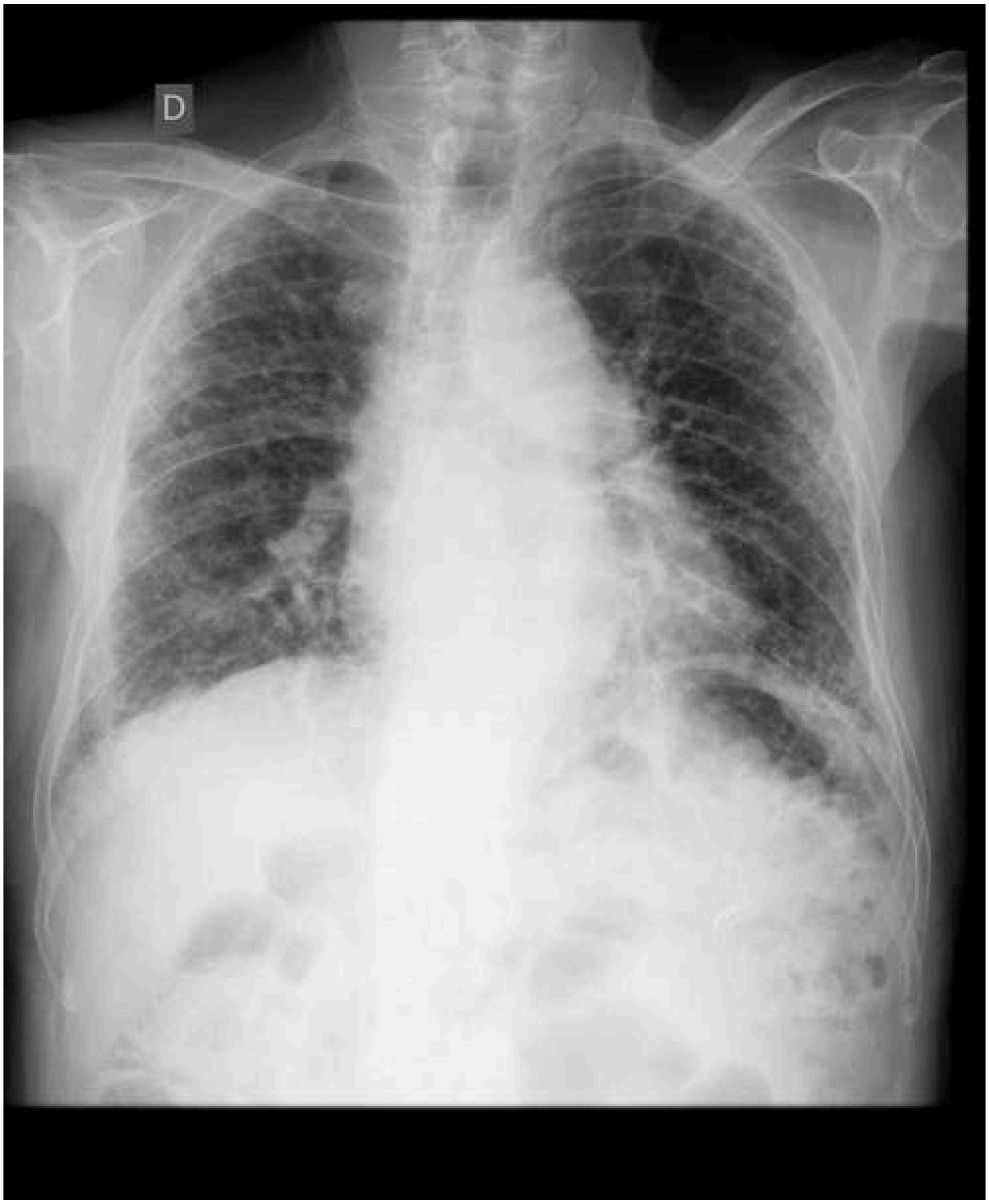

© Image used on license from Radiopaedia

Which one of the following interventions is most likely to be beneficial?

- Bosentan
- Rotation of prophylactic antibiotic + postural drainage
- Bronchodilator therapy
- Prednisolone
- Pirfenidone

Submit answer

Reference ranges

Score: **20.4%**

1	✗
2	✗
3	✗
4	✗
5	✗
6	✗
7	✗
8	✗
9	✓
10	✓
11	✗
12	✗
13	✗
14	✓
15	✗
16	✓
17	✗
18	✗
19	✗
20	✗
21	✓
22	✓
23	✗
24	✗
25	✗
26	✗
27	✓
28	✗
29	✗

✓
✓
✗
✗
✗
✗
✗
✗
✗
✗
-
✗
✗
✗
✗
✓
✗
✗
✗
✗
✗
-
-
-
-
-
-
-
-
-
-
-
-
-
-
-
-
-

All contents of this site are © 2024 Passmedicine Limited

A 59-year-old man is investigated for increasing shortness-of-breath. This has been getting progressively worse for the past 6 months and is associated with a dry cough. He has received two courses of antibiotics from his GP which only temporarily improved his symptoms. He was diagnosed with asthma as a child but has not had to use an inhaler since he was around 10-years-old. He stopped smoking 20 years ago.

On examination he is noted to have scattered crackles bilaterally, predominantly in the bases. Oxygen saturations are 96% on room air. Pulse, blood pressure and temperature are normal.

Spirometry is arranged:

FEV1	2.2 L (predicted 3.8 L)
FVC	2.7 L (predicted 4.5 L)
FEV1/FVC	81% (normal > 75%)

A chest x-ray is arranged:

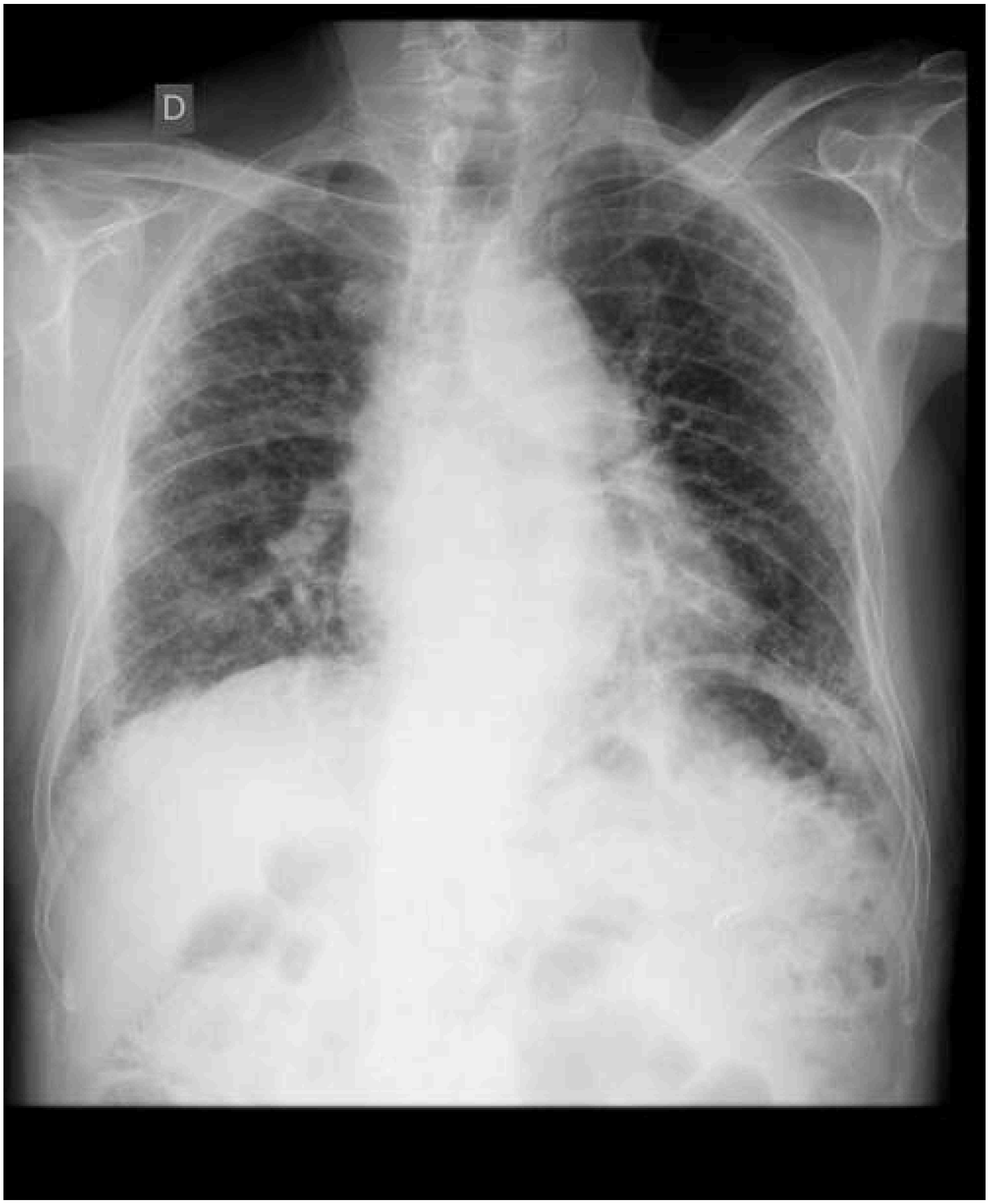

© Image used on license from Radiopaedia

Which one of the following interventions is most likely to be beneficial?

Bosentan	4%
Rotation of prophylactic antibiotic + postural drainage	7%
Bronchodilator therapy	3%
Prednisolone	11%
Pirfenidone	76%

The spirometry shows a restrictive picture consistent with pulmonary fibrosis. The chest x-ray is also consistent with this diagnosis, showing sub-pleural reticular opacities that increase from the

apex to the bases of the lungs.

Pirfenidone is currently the only drug recommended by NICE for the treatment of idiopathic pulmonary fibrosis.

Discuss (5) Improve

Next question

Idiopathic pulmonary fibrosis

Idiopathic pulmonary fibrosis (IPF, previously termed cryptogenic fibrosing alveolitis) is a chronic lung condition characterised by progressive fibrosis of the interstitium of the lungs. Whilst there are many causes of lung fibrosis (e.g. medications, connective tissue disease, asbestos) the term IPF is reserved when no underlying cause exists.

IPF is typically seen in patients aged 50-70 years and is twice as common in men.

Features

- progressive exertional dyspnoea
- bibasal fine end-inspiratory crepitations on auscultation
- dry cough
- clubbing

Diagnosis

- spirometry: classically a restrictive picture (FEV1 normal/decreased, FVC decreased, FEV1/FVC increased)
- impaired gas exchange: reduced transfer factor (TLCO)
- imaging: bilateral interstitial shadowing (typically small, irregular, peripheral opacities - 'ground-glass' - later progressing to 'honeycombing') may be seen on a chest x-ray but high-resolution CT scanning is the investigation of choice and required to make a diagnosis of IPF
- ANA positive in 30%, rheumatoid factor positive in 10% but this does not necessarily mean that the fibrosis is secondary to a connective tissue disease. Titres are usually low

Management

- pulmonary rehabilitation
- very few medications have been shown to give any benefit in IPF. There is some evidence that pirfenidone (an antifibrotic agent) may be useful in selected patients (see NICE guidelines)
- many patients will require supplementary oxygen and eventually a lung transplant

Prognosis

- poor, average life expectancy is around 3-4 years

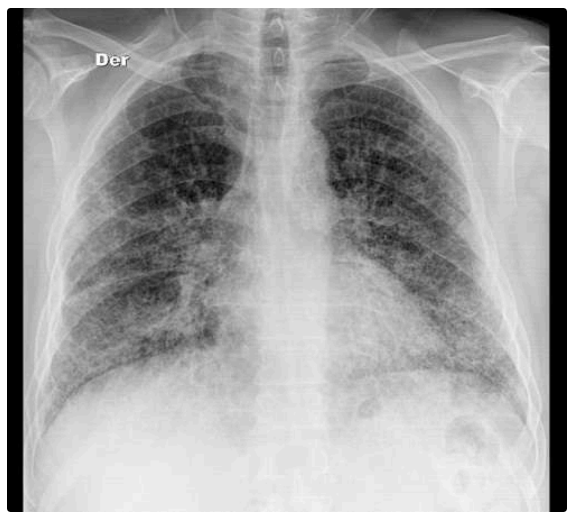

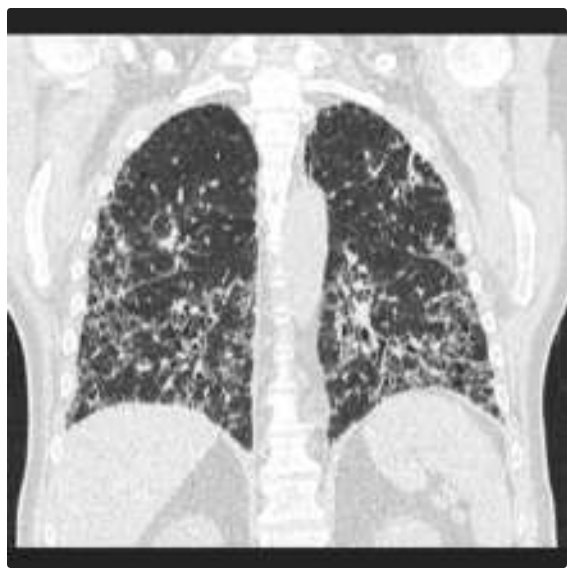

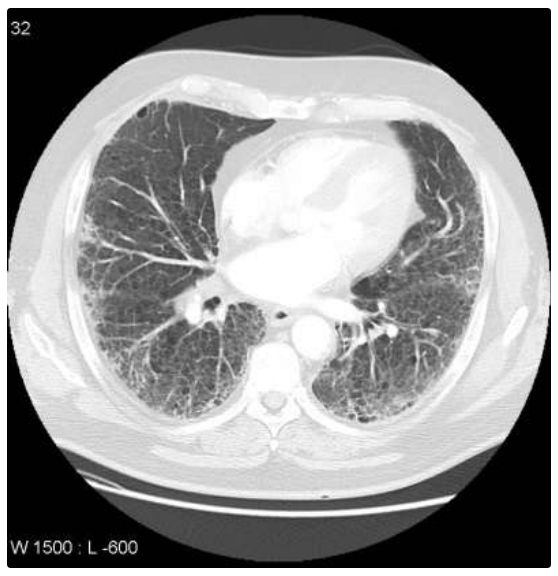

123

Next question >

Textbooks

High-yield textbook

Extended textbook

Links

Royal College of Physicians 13 10

Update in diagnosis and management of interstitial lung disease

NICE 11 6

2013 Idiopathic pulmonary fibrosis guidelines

Suggest link

Report broken link

Media

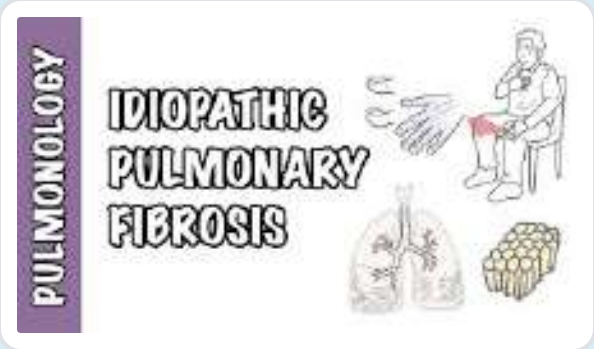

Idiopathic pulmonary fibrosis

Armando Hasudungan - YouTube 6 0

Interstitial Lung Disease (ILD) - Classification, pathophysiology, signs and symptoms

Armando Hasudungan - YouTube 5 0

Idiopathic pulmonary fibrosis

Osmosis - YouTube 4 0

Report broken media

Score: **17.8%**

1 ✗
2 ✗
3 ✗
4 ✗
5 ✗
6 ✗
7 ✗
8 ✗
9 ✓

10	✓
11	✗
12	✗
13	✗
14	✓
15	✗
16	✓
17	✗
18	✗
19	✗
20	✗
21	✓
22	✓
23	✗
24	✗
25	✗
26	✗
27	✓
28	✗
29	✗
30	✓
31	✓
32	✗
33	✗
34	✗
35	✗
36	✗
37	✗
38	✗
39	✗
40	-
41	✗
42	✗
43	✗
44	✗
45	✓

46 ✗
47 ✗
48 ✗
49 ✗
50 ✗
51 ✗
52 ✗
53 ✗
54 ✗
55 ✗
56 ✗
57 ✗
58 ✗
59 ✗
60 ✗
61 ✗
62 ✗
63 ✗
64 ✗
65 ✗
66 ✗
67 ✓
68 ✗
69 ✓
70 ✗
71 ✗
72 ✓
73 ✗
74 ✗
75 -

All contents of this site are © 2024 Passmedicine Limited

A 45-year-old man presents to the emergency department with a two-week history of a dry cough, fever and retrosternal discomfort. He has a past medical history of HIV and is poorly compliant with anti-retroviral medications. He has recently returned from a holiday in Mississippi.

Observations:

- Heart rate 95 beats per minute
- Blood pressure 101/65 mmHg
- Respiratory rate 24/minute
- Spo2 93% on room air
- Temperature 37.3C

The examination is unremarkable.

A chest x-ray demonstrates multifocal consolidation that extends to the periphery of the lungs.

Sputum microscopy reveals yeasts.

What organism is most likely responsible for this presentation?

- *Coccidioides posadasii*
- *Histoplasma capsulatum*
- *Legionella pneumophila*
- *Pseudomonas aeruginosa*
- *Streptococcus pneumoniae*

Submit answer

Reference ranges

Score: **20.4%**

1	✗
2	✗
3	✗
4	✗
5	✗
6	✗
7	✗
8	✗
9	✓
10	✓
11	✗
12	✗
13	✗
14	✓
15	✗
16	✓
17	✗
18	✗
19	✗
20	✗
21	✓
22	✓
23	✗
24	✗
25	✗
26	✗
27	✓
28	✗
29	✗
30	✓
31	✓
32	✗
33	✗
34	✗

35	✗
36	✗
37	✗
38	✗
39	✗
40	-
41	✗
42	✗
43	✗
44	✗
45	✓
46	✗
47	✗
48	✗
49	✗
50	✗
51	-
52	-
53	-
54	-
55	-
56	-
57	-
58	-
59	-
60	-
61	-
62	-
63	-
64	-
65	-
66	-
67	-
68	-

All contents of this site are © 2024 Passmedicine Limited

Back to top

A 45-year-old man presents to the emergency department with a two-week history of a dry cough, fever and retrosternal discomfort. He has a past medical history of HIV and is poorly compliant with anti-retroviral medications. He has recently returned from a holiday in Mississippi.

Observations:

- Heart rate 95 beats per minute
- Blood pressure 101/65 mmHg
- Respiratory rate 24/minute
- Spo2 93% on room air
- Temperature 37.3C

The examination is unremarkable.

A chest x-ray demonstrates multifocal consolidation that extends to the periphery of the lungs.

Sputum microscopy reveals yeasts.

What organism is most likely responsible for this presentation?

- *Coccidioides posadasii* 12%
- *Histoplasma capsulatum* 80%
- *Legionella pneumophila* 3%
- *Pseudomonas aeruginosa* 3%
- *Streptococcus pneumoniae* 2%

Mississippi and Ohio River valleys → ?histoplasmosis

Important for me Less important

Histoplasma capsulatum is the correct answer. The patient presents with a dry cough, retrosternal discomfort, fever and chest x-ray evidence of multifocal pneumonia after travelling from a region where histoplasmosis is endemic. Yeasts identified on sputum microscopy are also

suggestive of a fungal rather than bacterial cause. Severe histoplasmosis is more common in immunocompromised patients. His history of poor compliance with HIV medications suggests he is at further risk of developing severe fungal infections. Histoplasmosis is often a self-limiting illness in an immunocompetent individual.

Coccidioides posadasii is incorrect. This causes coccidioidomycosis, another endemic mycosis. While infection with this fungal organism can cause respiratory failure and multifocal consolidation in patients with HIV, it is not endemic to Mississippi. It is found in more arid regions including southern California, southern Nevada, Arizona, New Mexico, Utah and western Texas. it is also found in parts of South America and Central America.

Legionella pneumophila is incorrect. This is a cause of a bacterial atypical pneumonia. It is typically transmitted by inhaling contaminated water droplets and so outbreaks have been linked to swimming pools and air conditioning systems. It is not necessarily endemic to Mississippi and sputum microscopy would not demonstrate a yeast, which implies a fungal infection.

Pseudomonas aeruginosa is incorrect. This is another potential cause of pneumonia in a patient with HIV and probable low CD4 count. However, yeasts would not be seen on sputum microscopy and this indicates a fungal infection. *Pseudomonas* infections are also more common in patients with pre-existing lung disease and indwelling vascular access.

Streptococcus pneumoniae is incorrect. This is one of the most common causes of pneumonia. However, this typically causes lobar rather than multifocal pneumonia. Additionally, the sputum sample may confirm that organism rather than grow a yeast.

Discuss | Improve

Next question

Histoplasmosis

Histoplasmosis is due to the fungus *Histoplasma capsulatum*. It is most commonly encountered in the Mississippi and Ohio River valleys.

Features
- URTI symptoms
- retrosternal pain

Management
- amphotericin or itraconazole are the pharmacological agents of choice for histoplasmosis

123

Next question

Textbooks

High-yield textbook

Extended textbook

Score: **17.8%**

1	✗
2	✗
3	✗
4	✗
5	✗
6	✗
7	✗
8	✗
9	✓
10	✓
11	✗
12	✗
13	✗
14	✓
15	✗

16	✓
17	✗
18	✗
19	✗
20	✗
21	✓
22	✓
23	✗
24	✗
25	✗
26	✗
27	✓
28	✗
29	✗
30	✓
31	✓
32	✗
33	✗
34	✗
35	✗
36	✗
37	✗
38	✗
39	✗
40	-
41	✗
42	✗
43	✗
44	✗
45	✓
46	✗
47	✗
48	✗
49	✗
50	✗
51	✗

52	✗
53	✗
54	✗
55	✗
56	✗
57	✗
58	✗
59	✗
60	✗
61	✗
62	✗
63	✗
64	✗
65	✗
66	✗
67	✓
68	✗
69	✓
70	✗
71	✗
72	✓
73	✗
74	✗
75	-

All contents of this site are © 2024 Passmedicine Limited

Back to top

A 68-year-old woman is admitted to the Emergency Department with shortness of breath. A chest x-ray is taken as part of the initial investigations.

© Image used on license from Radiopaedia

Based on the chest x-ray, what is the most likely diagnosis?

- Multiple pulmonary emboli
- Tuberculosis
- Multiple lung abscesses
- Bronchiectasis
- Lung metastases

Submit answer

Reference ranges

Score: **20.4%**

1	✗
2	✗
3	✗
4	✗
5	✗
6	✗
7	✗
8	✗
9	✓
10	✓
11	✗
12	✗
13	✗
14	✓
15	✗
16	✓
17	✗
18	✗
19	✗
20	✗
21	✓
22	✓
23	✗
24	✗
25	✗
26	✗
27	✓
28	✗
29	✗
30	✓

31	✓
32	✗
33	✗
34	✗
35	✗
36	✗
37	✗
38	✗
39	✗
40	-
41	✗
42	✗
43	✗
44	✗
45	✓
46	✗
47	✗
48	✗
49	✗
50	✗
51	-
52	-
53	-
54	-
55	-
56	-
57	-
58	-
59	-
60	-
61	-
62	-
63	-
64	-
65	-
66	-
67	-
68	-

69	-

All contents of this site are © 2024 Passmedicine Limited

A 68-year-old woman is admitted to the Emergency Department with shortness of breath. A chest x-ray is taken as part of the initial investigations.

© Image used on license from Radiopaedia

Based on the chest x-ray, what is the most likely diagnosis?

Multiple pulmonary emboli	1%
Tuberculosis	3%
Multiple lung abscesses	3%
Bronchiectasis	1%
Lung metastases	91%

The multiple rounded lesions are highly suggestive of lung metastases.

Chest x-ray: white lung lesions

There are numerous causes of white shadowing in the lungs including:

- consolidation
- pleural effusion
- collapse
- pneumonectomy
- specific lesions e.g. tumours
- fluid e.g. pulmonary oedema

If there is a 'white-out' of a hemithorax it is useful to assess the position of the trachea - is it central, pulled or pushed from the side of opacification.

Trachea pulled toward the white-out	Trachea central	Trachea pushed away from the white-out
Pneumonectomy Complete lung collapse e.g. endobronchial intubation Pulmonary hypoplasia	Consolidation Pulmonary oedema (usually bilateral) Mesothelioma	Pleural effusion Diaphragmatic hernia Large thoracic mass

© Image used on license from Radiopaedia

Lung collapse - note how the trachea is pulled towards the side of the white-out

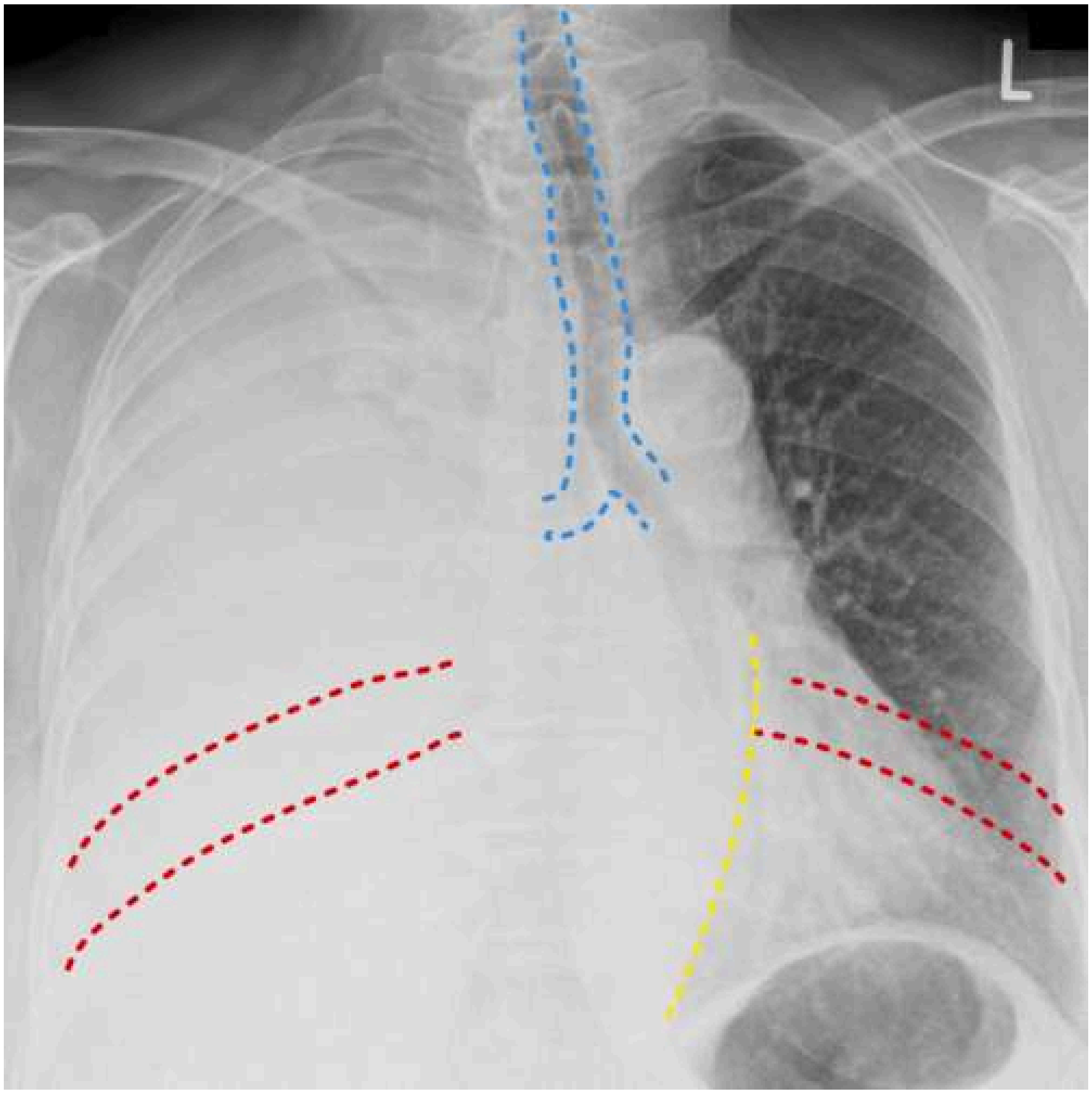

© Image used on license from Radiopaedia

Pleural effusion - note how the trachea (blue) is pushed away the side of the white-out. The other signs of a positive mass effect include leftward bowing of the azygo-oesophageal recess (yellow) and splaying of the ribs on the right (red)

For more information check out the link to the superb Radiology Masterclass website.

123

Next question >

Textbooks

High-yield textbook

Extended textbook

Links

Wiki Radiography 13 4

Example of right upper lobe consolidation

Radiology Masterclass 42 6

Fantastic radiology teaching website

Suggest link

Report broken link

Score: **17.8%**

1	✗
2	✗
3	✗
4	✗
5	✗
6	✗
7	✗
8	✗
9	✓
10	✓
11	✗
12	✗
13	✗
14	✓
15	✗
16	✓
17	✗
18	✗
19	✗
20	✗
21	✓
22	✓
23	✗
24	✗
25	✗
26	✗
27	✓
28	✗
29	✗
30	✓
31	✓
32	✗
33	✗
34	✗
35	✗

36	✗
37	✗
38	✗
39	✗
40	-
41	✗
42	✗
43	✗
44	✗
45	✓
46	✗
47	✗
48	✗
49	✗
50	✗
51	✗
52	✗
53	✗
54	✗
55	✗
56	✗
57	✗
58	✗
59	✗
60	✗
61	✗
62	✗
63	✗
64	✗
65	✗
66	✗
67	✓
68	✗
69	✓
70	✗
71	✗

72	✓
73	✗
74	✗
75	-

All contents of this site are © 2024 Passmedicine Limited

A 50-year-old female patient presents to the respiratory outpatient clinic for her asthma review.

Unfortunately, she has been admitted to hospital three times in the last year with asthma exacerbations, requiring 2-3 days in hospital but never requiring intubation or intensive care admission. This is on a background of multiple admissions to hospitals in previous years.

On review, she reports wheeze associated with dyspnoea on most days and this is usually triggered by exertion. There is a non-productive cough most mornings which settles throughout the course of the day. There is no history of allergic rhinitis, eczema or other medical problems. She is a lifelong non-smoker.

Current asthma therapy is high dose inhaled fluticasone propionate plus salmeterol 2 puffs twice daily, prednisolone 10mg once daily and inhaled salbutamol as required. She has been taking regular prednisolone 10mg for the last eighteen months.

On examination, observations revealed a respiratory rate of 14/min, oxygen saturation 98% on room air, heart rate 80/min regular, blood pressure 130/70 mmHg and a temperature of 36.8ºC. There is no clubbing, cervical lymphadenopathy or elevation of the jugular venous pressure. Auscultation of the chest revealed dual heart sounds with no murmurs and some mild expiratory wheeze in the upper zones. The calves were soft and non-tender, with no pedal oedema.

You had reviewed this patient during her most recent exacerbation and had arranged some outpatient tests, the results of which are shown below:

Hb	140 g/l	Na^+	138 mmol/l
Platelets	$350 * 10^9/l$	K^+	3.4 mmol/l
WBC	$8 * 10^9/l$	Urea	5 mmol/l
Neuts	$4.5 * 10^9/l$	Creatinine	70 µmol/l
Lymphs	$1.0 * 10^9/l$	CRP	7 mg/l
Eosin	$2.5 * 10^9/l$		

Fraction of exhaled nitric oxide	65 parts per billion (upper limit of normal 50 ppb)

Which of the following would be the most appropriate management for this patient?

- Add in mepolizumab
- Start a course of voriconazole
- Increase dose of prednisolone to 20mg once daily
- Start home nebulisers
- High resolution computed tomography of the thorax (HRCT)

Submit answer

Reference ranges

Score: **20.4%**

1	✗
2	✗
3	✗
4	✗
5	✗
6	✗
7	✗
8	✗
9	✓
10	✓
11	✗
12	✗
13	✗
14	✓
15	✗
16	✓
17	✗
18	✗

19	✗
20	✗
21	✓
22	✓
23	✗
24	✗
25	✗
26	✗
27	✓
28	✗
29	✗
30	✓
31	✓
32	✗
33	✗
34	✗
35	✗
36	✗
37	✗
38	✗
39	✗
40	-
41	✗
42	✗
43	✗
44	✗
45	✓
46	✗
47	✗
48	✗
49	✗
50	✗
51	-
52	-
53	-
54	-
55	-

56 -
57 -
58 -
59 -
60 -
61 -
62 -
63 -
64 -
65 -
66 -
67 -
68 -
69 -
70 -

All contents of this site are © 2024 Passmedicine Limited
Back to top

A 50-year-old female patient presents to the respiratory outpatient clinic for her asthma review.

Unfortunately, she has been admitted to hospital three times in the last year with asthma exacerbations, requiring 2-3 days in hospital but never requiring intubation or intensive care admission. This is on a background of multiple admissions to hospitals in previous years.

On review, she reports wheeze associated with dyspnoea on most days and this is usually triggered by exertion. There is a non-productive cough most mornings which settles throughout the course of the day. There is no history of allergic rhinitis, eczema or other medical problems. She is a lifelong non-smoker.

Current asthma therapy is high dose inhaled fluticasone propionate plus salmeterol 2 puffs twice daily, prednisolone 10mg once daily and inhaled salbutamol as required. She has been taking regular prednisolone 10mg for the last eighteen months.

On examination, observations revealed a respiratory rate of 14/min, oxygen saturation 98% on room air, heart rate 80/min regular, blood pressure 130/70 mmHg and a temperature of 36.8°C. There is no clubbing, cervical lymphadenopathy or elevation of the jugular venous pressure. Auscultation of the chest revealed dual heart sounds with no murmurs and some mild expiratory wheeze in the upper zones. The calves were soft and non-tender, with no pedal oedema.

You had reviewed this patient during her most recent exacerbation and had arranged some outpatient tests, the results of which are shown below:

Hb	140 g/l	Na^+	138 mmol/l
Platelets	350 * 10^9/l	K^+	3.4 mmol/l
WBC	8 * 10^9/l	Urea	5 mmol/l
Neuts	4.5 * 10^9/l	Creatinine	70 µmol/l
Lymphs	1.0 * 10^9/l	CRP	7 mg/l
Eosin	2.5 * 10^9/l		

Fraction of exhaled nitric oxide	65 parts per billion (upper limit of normal 50 ppb)

Which of the following would be the most appropriate management for this patient?

Add in mepolizumab	66%
Start a course of voriconazole	9%
Increase dose of prednisolone to 20mg once daily	10%
Start home nebulisers	2%
High resolution computed tomography of the thorax (HRCT)	14%

Mepolizumab and other anti-IL-5 therapies can be used in adults with eosinophilic asthma

Important for me Less important

This patient has inadequately controlled asthma as evidenced by the three admissions to hospital and ongoing cough, wheeze and dyspnoea. There is a serum eosinophilia and elevated fraction of exhaled nitric oxide (FENO), both suggesting eosinophilic inflammation as an important driver of this patient's asthma. Such patients are eligible for anti-interleukin-5 therapy such as mepolizumab.

Mepolizumab administered either intravenously or subcutaneously has been shown to significantly reduce asthma exacerbations and is particularly useful in patients on long-term steroid therapy.

There are several inflammatory phenotypes in asthma most commonly described as eosinophilic, neutrophilic, mixed, and paucigranulocytic. The presence of eosinophilic inflammation can be demonstrated by one or more of the following:

- Sputum Eosinophils 3% or more
- FENO of 50 ppb or more
- Eosinophil count of 0.3X109/L or higher
- Prompt deterioration of asthma control after a 25% or less reduction in inhaled corticosteroid dose

Studies have shown an association between higher levels of FENO and eosinophilic airway inflammation, although the mechanism by which this occurs is still unclear.

Option A - the correct answer

Option B - there is insufficient evidence to support a diagnosis of allergic bronchopulmonary aspergillosis (ABPA) and therefore a course of voriconazole is not indicated

Option C - Another advantage of mepolizumab if that is has been shown to improve asthma symptoms to such an extent that steroid-dependent patients can actually cease their oral

corticosteroid therapy. Given the significant side effects long-term corticosteroid therapy can have, increasing the steroid dose further is not the most appropriate management step, especially when there is a treatment that specifically targets this patient's asthma phenotype

Option D - home nebulisers would not treat the underlying problem of eosinophilic asthma

Option E - There is no indication for HRCT in this case.

Discuss (6) Improve

Next question

Asthma: management in adults

In 2024 NICE, the British Thoracic Society and SIGN produced joint guidelines on the management of asthma following many years of conflicting guidelines. The new guidelines represent a major step change in the management of asthma is both diagnosed and treated.

For many years patients with asthma were started on a short-acting beta-2 agonist (SABA) inhaler before 'stepping up' to a regular inhaled corticosteroid with a SABA as required. The new guidelines now advocate the use of combined inhalers (ICS + long-acting beta-2 agonist) as reliever therapy or regularly, depending on the severity of asthma. Given the prevalence of asthma, it is likely that doctors will have to deal with patients on 'conventional' asthma treatments for many years to come. The joint guidelines therefore include guidance on how to manage these patients if their current treatment is controlling their symptoms sufficiently.

Management of adult patients aged children aged ≥ 12 years with newly diagnosed asthma

Step 1 NICE

- a low-dose inhaled corticosteroid (ICS)/formoterol combination inhaler to be taken as needed for symptom relief
  - this is termed anti-inflammatory reliever (AIR) therapy
- if the patient presents highly symptomatic (for example, regular nocturnal waking) or with a severe exacerbation:
  - start treatment with low-dose MART (maintenance and reliever therapy, see below)
  - treat the acute symptoms as appropriate (e.g. a course of oral corticosteroids may be indicated)

Step 2 NICE

- a low-dose MART
    - MART describes using an inhaled corticosteroid (ICS)/formoterol combination inhaler for daily maintenance therapy and the relief of symptoms as needed, i.e. regularly and as required

Step 3

- a moderate-dose MART

Step 4

- check the fractional exhaled nitric oxide (FeNO) level if available, and the blood eosinophil count NICE
    - if either of these is raised, refer to a specialist in asthma care
    - if neither FeNO nor eosinophil count is raised, consider a trial of either a leukotriene receptor antagonist (LTRA) or a long-acting muscarinic receptor antagonist (LAMA) used in addition to moderate-dose MART
    - if control has not improved, stop the LTRA or LAMA and start a trial of the alternative medicine (LTRA or LAMA)

Step 5

- refer people to a specialist in asthma care when asthma is not controlled despite treatment with moderate-dose MART, and trials of an LTRA and a LAMA

Transferring people aged 12 and over from other treatment pathways

There will be many people whose asthma was managed according to the previous guidelines that present with uncontrolled asthmatic symptoms. The guidelines give advice on how these people should be switched: NICE

Existing asthma treatment	New asthma treatment
SABA as required only	Low-dose ICS/formoterol combination inhaler used as needed (as-needed AIR therapy)

Existing asthma treatment	New asthma treatment
SABA as required + regular low-dose ICS SABA as required + regular low-dose ICS/LABA SABA as required + regular low-dose ICS + LTRA SABA as required + regular low-dose ICS/LABA + LTRA	Regular low-dose regular ICS/formoterol combination inhaler (MART therapy)
SABA as required + regular moderate-dose ICS SABA as required + regular moderate-dose ICS/LABA SABA as required + regular moderate-dose ICS + LTRA or LAMA SABA as required + regular moderate-dose ICS/LABA + LTRA or LAMA	Regular moderate-dose MART therapy
Treatment regime containing a high-dose ICS	Refer to a respiratory specialist

123

Next question

Textbooks

High-yield textbook

Extended textbook

Links

NICE

0 0

2024 Asthma: diagnosis, monitoring and chronic asthma management (BTS, NICE, SIGN)

Suggest link

Report broken link

Media

Asthma

MedFlix - YouTube 2 0

Inhaler and Nebuliser Explanation

Oxford Medical Education - YouTube 5 1

Report broken media

Score: **17.8%**

1 ✗
2 ✗
3 ✗
4 ✗
5 ✗
6 ✗
7 ✗
8 ✗
9 ✓
10 ✓

11	✗
12	✗
13	✗
14	✓
15	✗
16	✓
17	✗
18	✗
19	✗
20	✗
21	✓
22	✓
23	✗
24	✗
25	✗
26	✗
27	✓
28	✗
29	✗
30	✓
31	✓
32	✗
33	✗
34	✗
35	✗
36	✗
37	✗
38	✗
39	✗
40	-
41	✗
42	✗
43	✗
44	✗
45	✓
46	✗

47	✗
48	✗
49	✗
50	✗
51	✗
52	✗
53	✗
54	✗
55	✗
56	✗
57	✗
58	✗
59	✗
60	✗
61	✗
62	✗
63	✗
64	✗
65	✗
66	✗
67	✓
68	✗
69	✓
70	✗
71	✗
72	✓
73	✗
74	✗
75	-

All contents of this site are © 2024 Passmedicine Limited

Back to top

A 41-year-old woman is seen in the respiratory clinic with a 4-month history of a productive cough and shortness of breath on exertion. There is no history of fever or weight loss although she does describe feeling more fatigued. Her past medical history includes coeliac disease and she smokes 10 cigarettes/day.

Her observations are recorded as follows:

- Temperature 36.1ºC
- Heart rate 87bpm
- Blood pressure 114/67mmHg
- Respiratory rate 15 breaths/min
- Saturations 94% on room air

On examination, there is evidence of finger clubbing. On auscultation, bilateral coarse crackles are heard. Heart sounds are normal and her abdominal examination is unremarkable.

A high resolution computed tomography (HRCT) chest is requested:

© Image used on license from Radiopaedia

What is the most likely diagnosis?

- *Mycobacterium tuberculosis*
- Bronchiectasis

- Chronic obstructive pulmonary disease ×
- Pneumocystis jiroveci pneumonia ×
- Pulmonary fibrosis ×

Submit answer

Reference ranges

Score: **20.4%**

1	✗
2	✗
3	✗
4	✗
5	✗
6	✗
7	✗
8	✗
9	✓
10	✓
11	✗
12	✗
13	✗
14	✓
15	✗
16	✓
17	✗
18	✗
19	✗
20	✗
21	✓

22	✓
23	✗
24	✗
25	✗
26	✗
27	✓
28	✗
29	✗
30	✓
31	✓
32	✗
33	✗
34	✗
35	✗
36	✗
37	✗
38	✗
39	✗
40	-
41	✗
42	✗
43	✗
44	✗
45	✓
46	✗
47	✗
48	✗
49	✗
50	✗
51	-
52	-
53	-
54	-
55	-
56	-
57	-
58	-

59	-
60	-
61	-
62	-
63	-
64	-
65	-
66	-
67	-
68	-
69	-
70	-
71	-

All contents of this site are © 2024 Passmedicine Limited

Back to top

A 41-year-old woman is seen in the respiratory clinic with a 4-month history of a productive cough and shortness of breath on exertion. There is no history of fever or weight loss although she does describe feeling more fatigued. Her past medical history includes coeliac disease and she smokes 10 cigarettes/day.

Her observations are recorded as follows:

- Temperature 36.1ºC
- Heart rate 87bpm
- Blood pressure 114/67mmHg
- Respiratory rate 15 breaths/min
- Saturations 94% on room air

On examination, there is evidence of finger clubbing. On auscultation, bilateral coarse crackles are heard. Heart sounds are normal and her abdominal examination is unremarkable.

A high resolution computed tomography (HRCT) chest is requested:

© Image used on license from Radiopaedia

What is the most likely diagnosis?

Mycobacterium tuberculosis	1%
Bronchiectasis	82%

Chronic obstructive pulmonary disease 2%

Pneumocystis jiroveci pneumonia 1%

Pulmonary fibrosis 13%

The diagnosis here is bronchiectasis. Bronchiectasis is the term given to a respiratory condition characterised by the permanent dilatation of the airways. This transverse slice of a CT chest shows multiple dilated bronchi, in keeping with the diagnosis. Causes of bronchiectasis include chronic infection and inflammation for example cystic fibrosis or following treatment for mycobacterium tuberculosis. This patient has had recurrent respiratory tract infections which may be involved in the pathogenesis of bronchiectasis in this patient. Symptoms include a persistent productive cough, shortness of breath and haemoptysis. Coarse crackles may be heard on auscultation and finger clubbing may be present.

Mycobacterium tuberculosis is a bacterial infection characterised by fever, lethargy and a productive cough. Constitutional symptoms such as weight loss and night sweats may also be seen. Whilst chronic inflammation secondary to *Mycobacterium tuberculosis* is a cause of bronchiectasis it is unlikely to be the current diagnosis as this patient has no history of fever or constitutional symptoms.

Chronic obstructive pulmonary disease (COPD) is most commonly secondary to tobacco use and a history of regular smoking can increase the likelihood of the disease. Examination findings tend to include wheeze rather than coarse crackles and COPD is not a cause of finger clubbing, suggesting an alternative diagnosis. Findings in keeping with COPD on a CT scan vary from person to person and include features such as bronchial wall thickening, air-space enlargement and bullae formation.

Pneumocystis jiroveci pneumonia is a serious fungal infection characterised by fever, cough, shortness of breath, chest pain and fatigue. It is most commonly seen in patients with immunosuppression. Autoimmune conditions are associated with coeliac disease, but coeliac disease itself should not give rise to significant immunosuppression.

Pulmonary fibrosis presents as progressive shortness of breath and a dry cough. It is also a cause of finger clubbing. Pulmonary fibrosis can be diagnosed on a CT scan by the presence of the characteristic honeycomb appearance which is not seen here.

Discuss (4) | Improve

Next question

Bronchiectasis: features

Bronchiectasis describes a permanent dilatation of the airways secondary to chronic infection or inflammation. There are a wide variety of causes are listed below:

Features

- persistent productive cough. Large volumes of sputum may be expectorated
- dyspnoea
- haemoptysis

Signs

- abnormal chest auscultation
    - coarse crackles
    - wheeze
- clubbing may be present

123

Next question

Textbooks

High-yield textbook

Extended textbook

Media

[Bronchiectasis - causes, pathophysiology, signs and symptoms, investigations and treatment]

Armando Hasudungan - YouTube 2 0

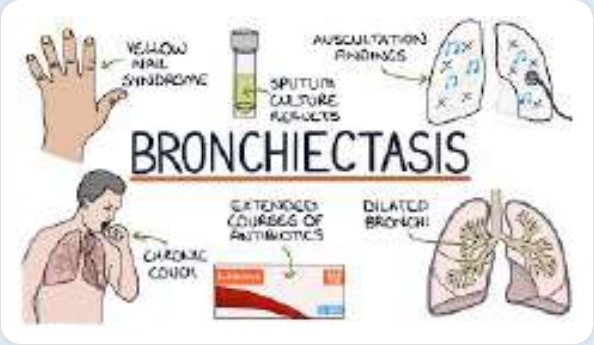

[Bronchiectasis]

Zero To Finals - YouTube 0 0

Report broken media

Score: **17.8%**

1	✗
2	✗
3	✗
4	✗
5	✗
6	✗
7	✗
8	✗
9	✓
10	✓
11	✗
12	✗
13	✗
14	✓
15	✗

16	✓
17	✗
18	✗
19	✗
20	✗
21	✓
22	✓
23	✗
24	✗
25	✗
26	✗
27	✓
28	✗
29	✗
30	✓
31	✓
32	✗
33	✗
34	✗
35	✗
36	✗
37	✗
38	✗
39	✗
40	-
41	✗
42	✗
43	✗
44	✗
45	✓
46	✗
47	✗
48	✗
49	✗
50	✗
51	✗

52	✗
53	✗
54	✗
55	✗
56	✗
57	✗
58	✗
59	✗
60	✗
61	✗
62	✗
63	✗
64	✗
65	✗
66	✗
67	✓
68	✗
69	✓
70	✗
71	✗
72	✓
73	✗
74	✗
75	-

All contents of this site are © 2024 Passmedicine Limited

A 65-year-old man is seen in the respiratory clinic for a follow-up appointment of his chronic obstructive pulmonary disease (COPD). At his last appointment, his medications were escalated to regular inhaled Spiriva (tiotropium bromide), Symbicort (budesonide and formoterol), and salbutamol, as required. He reports ongoing shortness of breath at rest and on exertion that is limiting his activities of daily living. He has had 2 exacerbations in the last year and he has been an ex-smoker for 6 months.

On examination, he is tachypnoeic with saturations of 92% on air. On auscultation, there is an audible wheeze bilaterally and normal heart sounds. His calves are soft and non-tender with no evidence of oedema.

Arterial blood gas:

pH	7.35	(7.35 - 7.45)
PaO2	8.2 kPa	(11 - 13)
PaCO2	5.1 kPa	(4.7 - 6.0)
Haemoglobin	135 g/L	(135 - 180)

FEV1	< 50% predicted

What is the most appropriate addition to the long-term management of this patient?

- Long-term oxygen therapy
- Montelukast
- Nebulised salbutamol
- Omalizumab
- Roflumilast

Submit answer

Reference ranges

Score: **20.4%**

1	✗
2	✗
3	✗
4	✗
5	✗
6	✗
7	✗
8	✗
9	✓
10	✓
11	✗
12	✗
13	✗
14	✓
15	✗
16	✓
17	✗
18	✗
19	✗
20	✗
21	✓
22	✓
23	✗
24	✗
25	✗
26	✗
27	✓
28	✗
29	✗
30	✓

31	✓
32	✗
33	✗
34	✗
35	✗
36	✗
37	✗
38	✗
39	✗
40	-
41	✗
42	✗
43	✗
44	✗
45	✓
46	✗
47	✗
48	✗
49	✗
50	✗
51	-
52	-
53	-
54	-
55	-
56	-
57	-
58	-
59	-
60	-
61	-
62	-
63	-
64	-
65	-
66	-
67	-
68	-

69 -
70 -
71 -
72 -

All contents of this site are © 2024 Passmedicine Limited
Back to top

A 65-year-old man is seen in the respiratory clinic for a follow-up appointment of his chronic obstructive pulmonary disease (COPD). At his last appointment, his medications were escalated to regular inhaled Spiriva (tiotropium bromide), Symbicort (budesonide and formoterol), and salbutamol, as required. He reports ongoing shortness of breath at rest and on exertion that is limiting his activities of daily living. He has had 2 exacerbations in the last year and he has been an ex-smoker for 6 months.

On examination, he is tachypnoeic with saturations of 92% on air. On auscultation, there is an audible wheeze bilaterally and normal heart sounds. His calves are soft and non-tender with no evidence of oedema.

Arterial blood gas:

pH	7.35	(7.35 - 7.45)
PaO2	8.2 kPa	(11 - 13)
PaCO2	5.1 kPa	(4.7 - 6.0)
Haemoglobin	135 g/L	(135 - 180)

FEV1	< 50% predicted

What is the most appropriate addition to the long-term management of this patient?

- Long-term oxygen therapy 19%
- Montelukast 9%
- Nebulised salbutamol 3%
- Omalizumab 4%
- Roflumilast 65%

Roflumilast should be used in COPD for patients who are losing control on triple inhaled therapy

Important for me   Less important

This patient has poorly controlled COPD, as seen by his persistent symptoms of shortness of breath despite increasing his regular medication regime. In patients who continue to have persistent symptoms despite a long-acting muscarinic antagonist, beta-agonist and inhaled corticosteroid, roflumilast can be tried. **Roflumilast** is a phosphodiesterase inhibitor recommended by NICE as an option for treating severe chronic obstructive pulmonary disease if the following criteria are met:

- Severe disease is defined as a forced expiratory volume in 1 second (FEV1) after a bronchodilator of less than 50% of predicted normal.

AND

- The person has had 2 or more exacerbations in the previous 12 months despite triple inhaled therapy with a long-acting muscarinic antagonist, a long-acting beta-2 agonist and an inhaled corticosteroid.

Long-term oxygen therapy is indicated for patients with COPD if the following criteria are met:

- Resting PaO_2 ≤7.3-kPa

OR

- Resting PaO_2 ≤8-kPa with evidence of peripheral oedema, polycythaemia (haematocrit ≥55%) or pulmonary hypertension.

This patient has a PaO_2 of 8.2kPa, making long-term oxygen therapy currently inappropriate.

Montelukast is a leukotriene receptor antagonist that is used in the management of asthma. It is not routinely used in the management of COPD.

Nebulised salbutamol may help alleviate symptoms in patients with COPD. However, salbutamol is a short-acting beta-agonist and nebulised salbutamol will only provide short-term symptomatic relief and does not help with the long-term management of symptoms.

Omalizumab is a monoclonal antibody used in the treatment of persistent allergic asthma. It works by reducing the levels of IgE and subsequent inflammation. It is not used in the treatment of severe COPD.

Discuss Improve

Drugs used in respiratory medicine

Drug	Mechanism of action	Notes
Salbutamol	Beta receptor agonist	• Short-acting inhaled bronchodilator. Relaxes bronchial smooth muscle through effects on beta 2 receptors • Used in asthma and chronic obstructive pulmonary disease (COPD). • Salmeterol has similar effects but is long-acting
Corticosteroids	Anti-inflammatory	• Inhaled corticosteroids are used as maintenance therapy • Oral or intravenous corticosteroids are used following an acute exacerbation of asthma or COPD
Ipratropium	Blocks the muscarinic acetylcholine receptors	• Short-acting inhaled bronchodilator. Relaxes bronchial smooth muscle • Used primarily in COPD • Tiotropium has similar effects but is long-acting
Methylxanthines (e.g. theophylline)	Non-specific inhibitor of phosphodiesterase resulting in an increase in cAMP	• Given orally or intravenously • Has a narrow therapeutic index
Monteleukast, zafirlukast	Blocks leukotriene receptors	• Usually taken orally • Useful in aspirin-induced asthma

Textbooks

High-yield textbook

Extended textbook

Score: **17.8%**

1	✗
2	✗
3	✗
4	✗
5	✗
6	✗
7	✗
8	✗
9	✓
10	✓
11	✗
12	✗
13	✗
14	✓
15	✗
16	✓
17	✗
18	✗
19	✗

20	✗
21	✓
22	✓
23	✗
24	✗
25	✗
26	✗
27	✓
28	✗
29	✗
30	✓
31	✓
32	✗
33	✗
34	✗
35	✗
36	✗
37	✗
38	✗
39	✗
40	-
41	✗
42	✗
43	✗
44	✗
45	✓
46	✗
47	✗
48	✗
49	✗
50	✗
51	✗
52	✗
53	✗
54	✗
55	✗

56	✗
57	✗
58	✗
59	✗
60	✗
61	✗
62	✗
63	✗
64	✗
65	✗
66	✗
67	✓
68	✗
69	✓
70	✗
71	✗
72	✓
73	✗
74	✗
75	-

All contents of this site are © 2024 Passmedicine Limited

Back to top

A 75-year-old man presents to the emergency department with hemoptysis. He has a past medical history of hepatitis C. He declined anti-viral therapy.

On examination, he has a saddle nose deformity. There is a non-blanching rash on his lower limbs.

Blood tests:

Hb	88 g/L	Male: (135-180) Female: (115 - 160)
Platelets	489 * 10^9/L	(150 - 400)
WBC	8.2 * 10^9/L	(4.0 - 11.0)
Na^+	138 mmol/L	(135 - 145)
K^+	4.2 mmol/L	(3.5 - 5.0)
Urea	18.2 mmol/L	(2.0 - 7.0)
Creatinine	155 µmol/L	(55 - 120)
CRP	151 mg/L	(< 5)

Urinalysis:

Blood	+
Protein	+++

Plain radiography of the chest demonstrates bilateral infiltrates.

Given the probable diagnosis, what test is most likely to be positive?

- Anti glomerular basement membrane antibody (anti-GBM)
- C-ANCA
- Cryoglobulins
- Double-stranded DNA (dsDNA)

P-ANCA

Submit answer

Reference ranges

Score: **20.4%**

1	✗
2	✗
3	✗
4	✗
5	✗
6	✗
7	✗
8	✗
9	✓
10	✓
11	✗
12	✗
13	✗
14	✓
15	✗
16	✓
17	✗
18	✗
19	✗
20	✗
21	✓
22	✓
23	✗
24	✗
25	✗

26	✗
27	✓
28	✗
29	✗
30	✓
31	✓
32	✗
33	✗
34	✗
35	✗
36	✗
37	✗
38	✗
39	✗
40	-
41	✗
42	✗
43	✗
44	✗
45	✓
46	✗
47	✗
48	✗
49	✗
50	✗
51	-
52	-
53	-
54	-
55	-
56	-
57	-
58	-
59	-
60	-
61	-
62	-

63 -
64 -
65 -
66 -
67 -
68 -
69 -
70 -
71 -
72 -
73 -

All contents of this site are © 2024 Passmedicine Limited

A 75-year-old man presents to the emergency department with hemoptysis. He has a past medical history of hepatitis C. He declined anti-viral therapy.

On examination, he has a saddle nose deformity. There is a non-blanching rash on his lower limbs.

Blood tests:

Hb	88 g/L	Male: (135-180) Female: (115 - 160)
Platelets	489 * 10^9/L	(150 - 400)
WBC	8.2 * 10^9/L	(4.0 - 11.0)
Na^+	138 mmol/L	(135 - 145)
K^+	4.2 mmol/L	(3.5 - 5.0)
Urea	18.2 mmol/L	(2.0 - 7.0)
Creatinine	155 µmol/L	(55 - 120)
CRP	151 mg/L	(< 5)

Urinalysis:

Blood	+
Protein	+++

Plain radiography of the chest demonstrates bilateral infiltrates.

Given the probable diagnosis, what test is most likely to be positive?

- Anti glomerular basement membrane antibody (anti-GBM) 5%
- C-ANCA 62%
- Cryoglobulins 21%
- Double-stranded DNA (dsDNA) 1%

P-ANCA 11%

Granulomatosis with polyangiitis - cANCA positive

Important for me Less important

C-ANCA is correct. The patient has a multisystem disease characterized by haemoptysis, saddle nose deformity, likely pulmonary haemorrhage (infiltrates, haemoptysis, anaemia) and an acute kidney injury with haematoproteinuria. The likely diagnosis is granulomatosis with polyangiitis (GPA). GPA is an ANCA-associated vasculitis that is most commonly associated with cANCA.

Anti glomerular basement membrane antibody (anti-GBM) is incorrect. This can also cause a pulmonary-renal syndrome with pulmonary haemorrhage and rapidly progressive glomerulonephritis. However, it is not associated with the ENT features that are seen in GPA i.e. saddle nose deformity, as seen in this case. Rarely, the two disorders can co-exist but the more likely scenario is that cANCA will be positive rather than an anti-GBM antibody.

Cryoglobulins are incorrect. Hepatitis C infection would put the patient at risk of cryoglobulinaemia, which can cause rash and renal impairment. However, it is less likely to cause pulmonary haemorrhage and is not associated with ENT involvement, wich is present in this case.

Double-stranded DNA (dsDNA) is incorrect. This is a specific antibody associated with systemic lupus erythematosus. SLE is typically associated with younger women rather than older men. Additionally, ENT involvement is not typical and pulmonary haemorrhage is rarer than in ANCA vasculitis.

pANCA is incorrect. This is more commonly associated with microscopic polyangiitis. This typically caused pulmonary and renal vasculitis but is discriminated from GPA by lack of ENT involvement in most cases. It may also be positive in a variety of other conditions including inflammatory bowel disease and primary sclerosing cholangitis. In general, a positive pANCA with negative MPO/PR3 has a poor positive predictive value for vasculitis.

Discuss (2) Improve

Next question

Granulomatosis with polyangiitis

Granulomatosis with polyangiitis is now the preferred term for Wegener's granulomatosis. It is an autoimmune condition associated with a necrotizing granulomatous vasculitis, affecting both the

upper and lower respiratory tract as well as the kidneys.

Features
- upper respiratory tract: epistaxis, sinusitis, nasal crusting
- lower respiratory tract: dyspnoea, haemoptysis
- rapidly progressive glomerulonephritis ('pauci-immune', 80% of patients)
- saddle-shape nose deformity
- also: vasculitic rash, eye involvement (e.g. proptosis), cranial nerve lesions

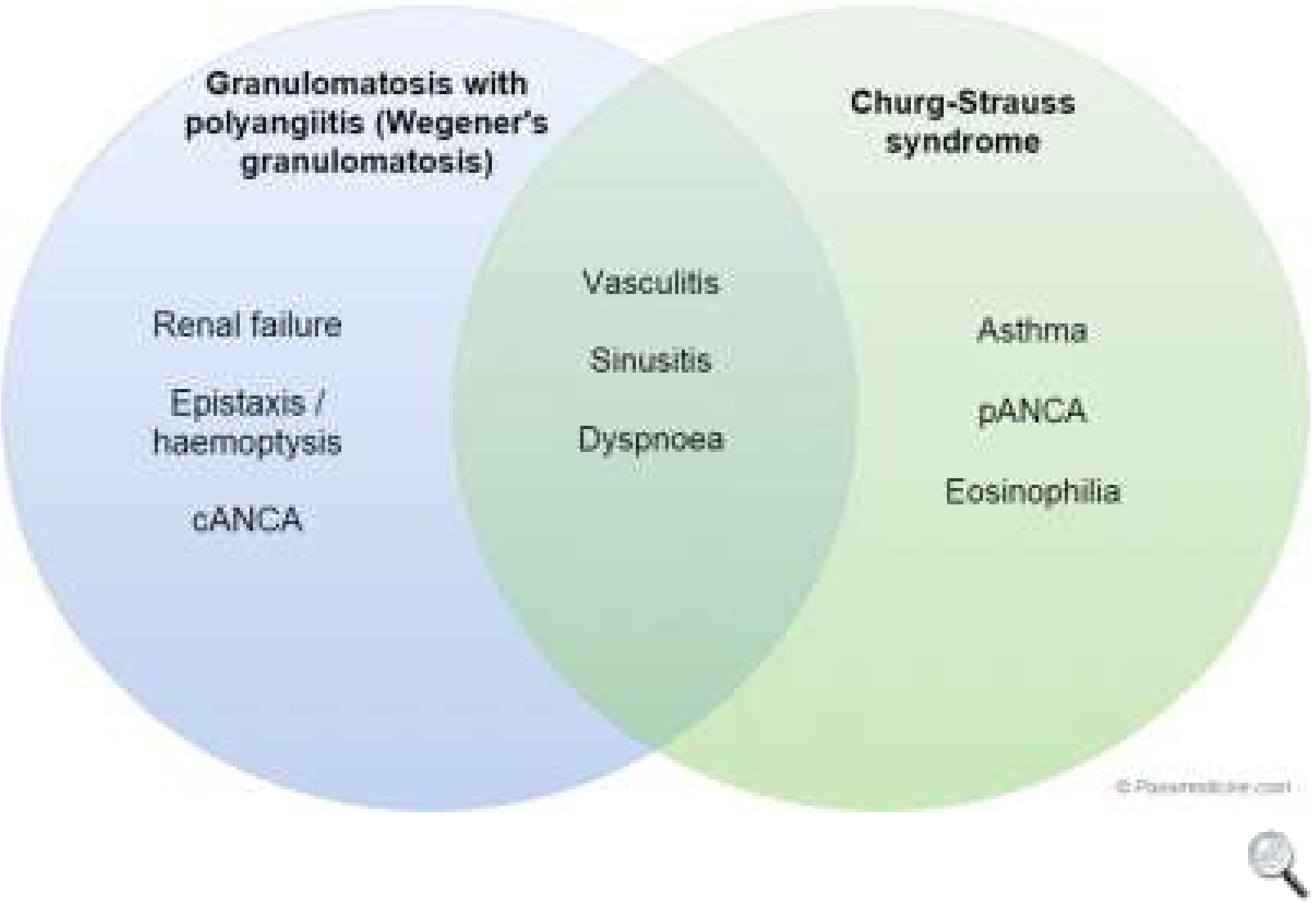

Comparison of granulomatosis with polyangiitis and Churg-Strauss syndrome

Investigations
- cANCA positive in > 90%, pANCA positive in 25%
- chest x-ray: wide variety of presentations, including cavitating lesions
- renal biopsy: epithelial crescents in Bowman's capsule

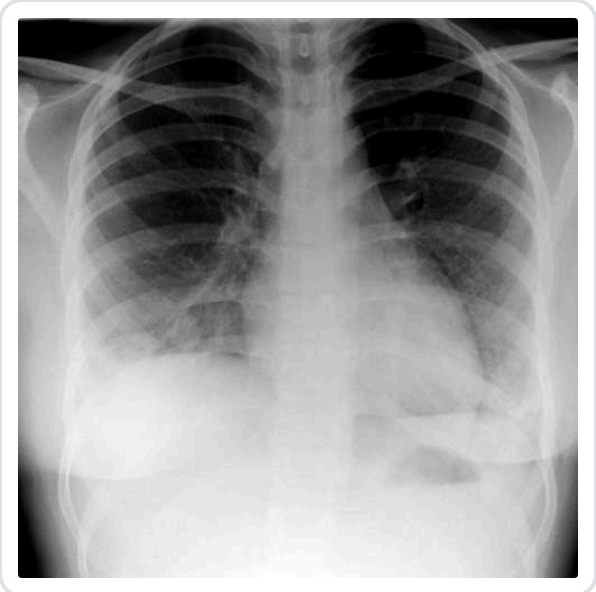
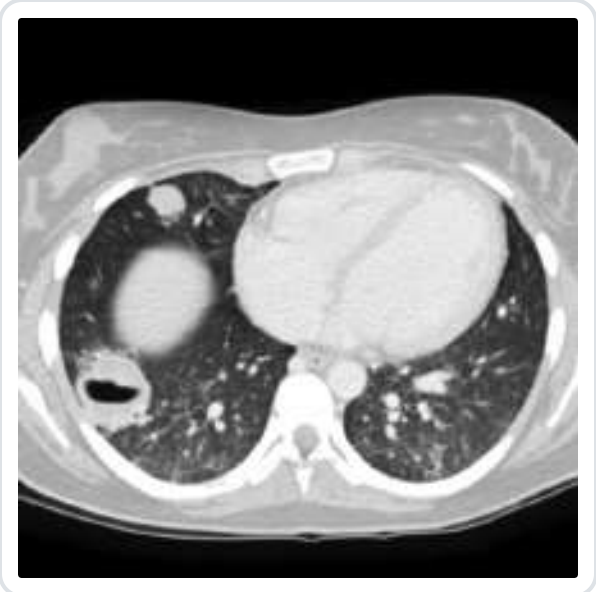

Management
- steroids
- cyclophosphamide (90% response)
- plasma exchange
- median survival = 8-9 years

123

Next question

Textbooks

High-yield textbook

Extended textbook

Media

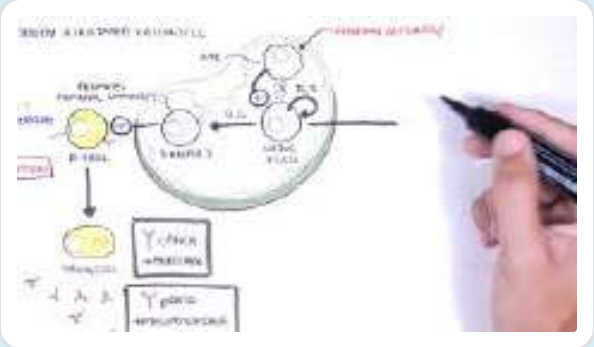

[ANCA (Anti-Neutrophil Cytoplasmic Antibody) Associated Vasculitis - Causes, Pathophysiology, Types]

Armando Hasudungan - YouTube

5 1

[Granulomatosis with polyangiitis]

Armando Hasudungan - YouTube

5 2

Report broken media

Score: **17.8%**

1	✗
2	✗
3	✗
4	✗
5	✗
6	✗
7	✗
8	✗
9	✓
10	✓
11	✗
12	✗
13	✗
14	✓
15	✗
16	✓
17	✗
18	✗
19	✗
20	✗
21	✓
22	✓
23	✗
24	✗
25	✗
26	✗
27	✓
28	✗
29	✗
30	✓
31	✓
32	✗
33	✗
34	✗

35	✗
36	✗
37	✗
38	✗
39	✗
40	-
41	✗
42	✗
43	✗
44	✗
45	✓
46	✗
47	✗
48	✗
49	✗
50	✗
51	✗
52	✗
53	✗
54	✗
55	✗
56	✗
57	✗
58	✗
59	✗
60	✗
61	✗
62	✗
63	✗
64	✗
65	✗
66	✗
67	✓
68	✗
69	✓
70	✗

71	✗
72	✓
73	✗
74	✗
75	-

All contents of this site are © 2024 Passmedicine Limited

An 11-year-old girl presents with a productive cough and fever. A chest x-ray is taken:

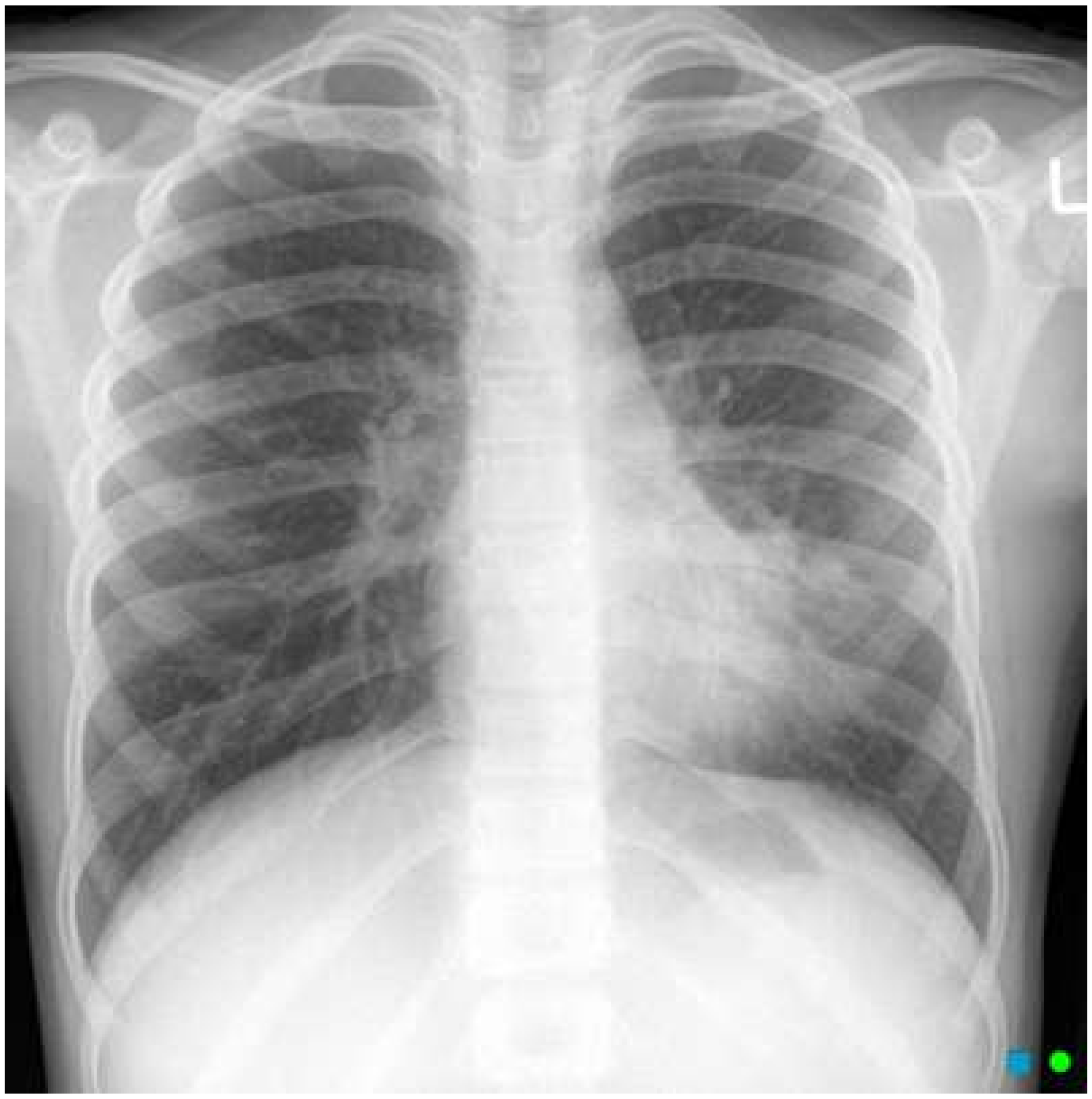

© Image used on license from Radiopaedia

What is the main finding on the x-ray?

- Bilateral pneumothoraces
- Left lingual consolidation
- Dilated cardiomyopathy with pulmonary oedema
- Left humeral head fracture
- Left middle lobe consolidation

Submit answer

Reference ranges

Score: **20.4%**

1	✗
2	✗
3	✗
4	✗
5	✗
6	✗
7	✗
8	✗
9	✓
10	✓
11	✗
12	✗
13	✗
14	✓
15	✗
16	✓
17	✗
18	✗
19	✗
20	✗
21	✓
22	✓
23	✗
24	✗
25	✗
26	✗
27	✓
28	✗
29	✗
30	✓

31	✓
32	✗
33	✗
34	✗
35	✗
36	✗
37	✗
38	✗
39	✗
40	-
41	✗
42	✗
43	✗
44	✗
45	✓
46	✗
47	✗
48	✗
49	✗
50	✗
51	-
52	-
53	-
54	-
55	-
56	-
57	-
58	-
59	-
60	-
61	-
62	-
63	-
64	-
65	-
66	-
67	-
68	-

69 -
70 -
71 -
72 -
73 -
74 -

All contents of this site are © 2024 Passmedicine Limited

An 11-year-old girl presents with a productive cough and fever. A chest x-ray is taken:

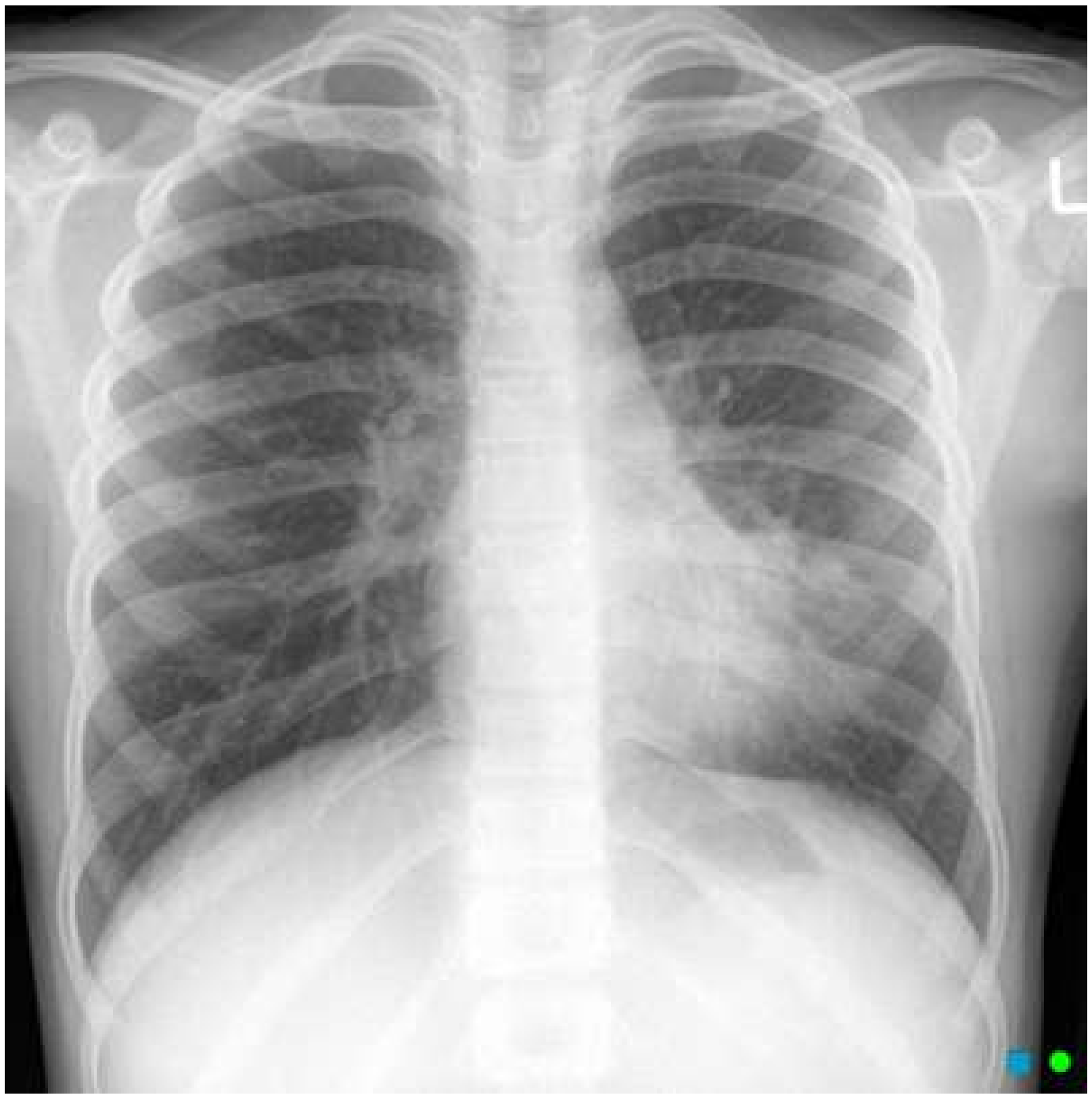

© Image used on license from Radiopaedia

What is the main finding on the x-ray?

- Bilateral pneumothoraces 7%
- Left lingual consolidation 67%
- Dilated cardiomyopathy with pulmonary oedema 2%
- Left humeral head fracture 2%
- Left middle lobe consolidation 22%

The loss of the left heart border is a classic sign of left lingual consolidation. There is no left middle lobe!

Chest x-ray: white lung lesions

There are numerous causes of white shadowing in the lungs including:

- consolidation
- pleural effusion
- collapse
- pneumonectomy
- specific lesions e.g. tumours
- fluid e.g. pulmonary oedema

If there is a 'white-out' of a hemithorax it is useful to assess the position of the trachea - is it central, pulled or pushed from the side of opacification.

Trachea pulled toward the white-out	**Trachea central**	**Trachea pushed away from the white-out**
Pneumonectomy Complete lung collapse e.g. endobronchial intubation Pulmonary hypoplasia	Consolidation Pulmonary oedema (usually bilateral) Mesothelioma	Pleural effusion Diaphragmatic hernia Large thoracic mass

© Image used on license from Radiopaedia

Lung collapse - note how the trachea is pulled towards the side of the white-out

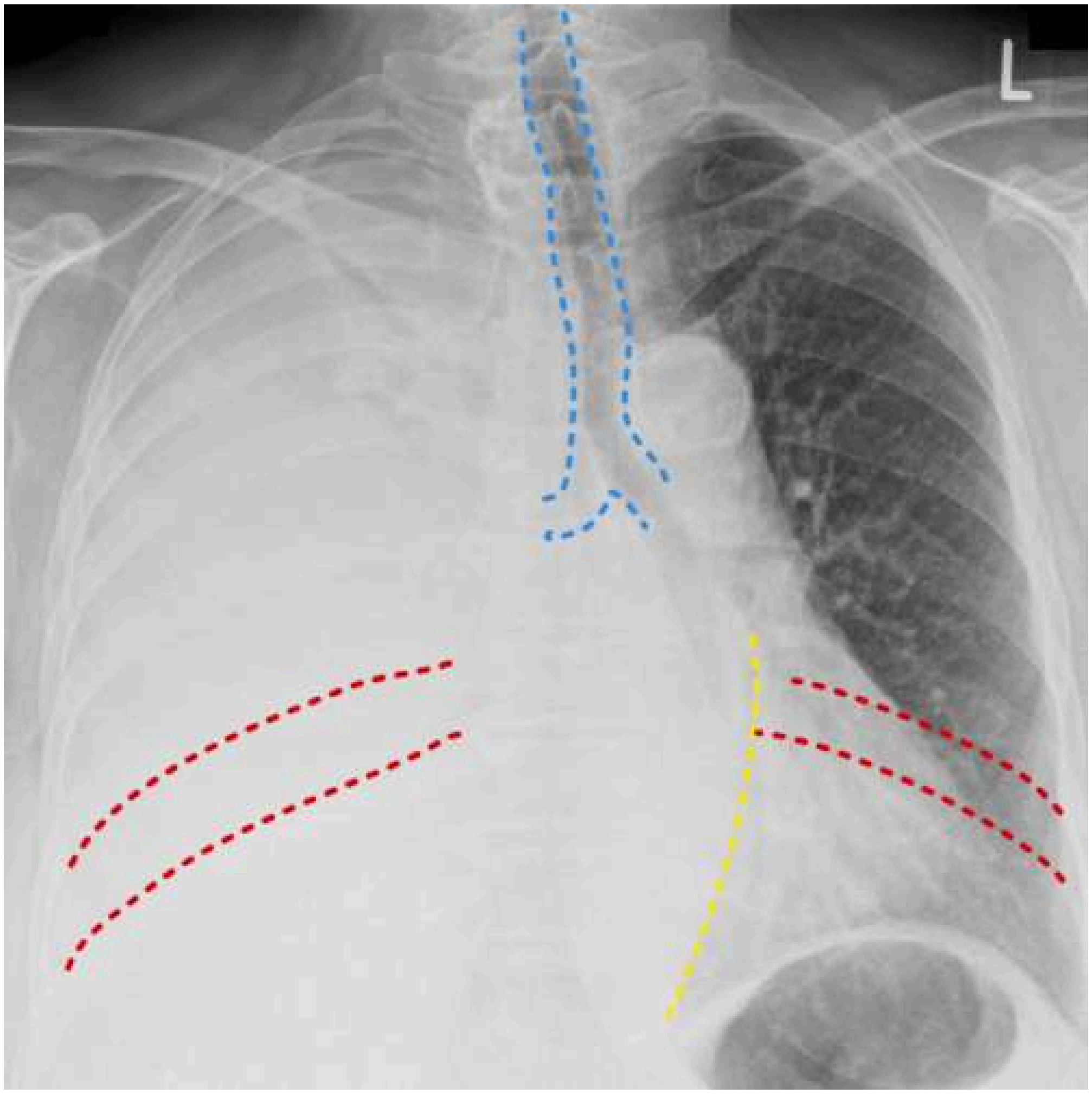

© Image used on license from Radiopaedia

Pleural effusion - note how the trachea (blue) is pushed away the side of the white-out. The other signs of a positive mass effect include leftward bowing of the azygo-oesophageal recess (yellow) and splaying of the ribs on the right (red)

For more information check out the link to the superb Radiology Masterclass website.

123

Next question >

Textbooks

High-yield textbook

Extended textbook

Links

Wiki Radiography 13 4

Example of right upper lobe consolidation

Radiology Masterclass 42 6

Fantastic radiology teaching website

Suggest link Report broken link

Score: **17.8%**

1	✗
2	✗
3	✗
4	✗
5	✗
6	✗
7	✗
8	✗
9	✓
10	✓
11	✗
12	✗
13	✗
14	✓
15	✗
16	✓
17	✗
18	✗
19	✗
20	✗
21	✓
22	✓
23	✗
24	✗
25	✗
26	✗
27	✓
28	✗
29	✗
30	✓
31	✓
32	✗
33	✗
34	✗
35	✗

36	✗
37	✗
38	✗
39	✗
40	-
41	✗
42	✗
43	✗
44	✗
45	✓
46	✗
47	✗
48	✗
49	✗
50	✗
51	✗
52	✗
53	✗
54	✗
55	✗
56	✗
57	✗
58	✗
59	✗
60	✗
61	✗
62	✗
63	✗
64	✗
65	✗
66	✗
67	✓
68	✗
69	✓
70	✗
71	✗

72	✓
73	✗
74	✗
75	-

All contents of this site are © 2024 Passmedicine Limited

A 56-year-old man presents to the Medical Admissions unit with a two-week history of a productive cough. His past medical history is significant for type 2 diabetes mellitus. He reports that he developed a cough productive of green sputum shortly after returning from a business trip to the United States. He also complains of persistent retrosternal pain for the last ten days. He has completed a course of doxycycline prescribed by his GP, to little symptomatic benefit.

Alongside routine blood tests, he provides a sputum sample for culture, with provisional results as follows:

Sputum culture	Fungal spores seen - full speciation awaited

Based on the likely diagnosis, what is the most appropriate management option?

- Co-trimoxazole
- Co-trimoxazole + prednisolone
- Dapsone
- Itraconazole
- Voriconazole

Submit answer

Reference ranges

Score: **20.4%**

1 ✗
2 ✗
3 ✗

4	✗
5	✗
6	✗
7	✗
8	✗
9	✓
10	✓
11	✗
12	✗
13	✗
14	✓
15	✗
16	✓
17	✗
18	✗
19	✗
20	✗
21	✓
22	✓
23	✗
24	✗
25	✗
26	✗
27	✓
28	✗
29	✗
30	✓
31	✓
32	✗
33	✗
34	✗
35	✗
36	✗
37	✗
38	✗
39	✗

40	-
41	✗
42	✗
43	✗
44	✗
45	✓
46	✗
47	✗
48	✗
49	✗
50	✗
51	-
52	-
53	-
54	-
55	-
56	-
57	-
58	-
59	-
60	-
61	-
62	-
63	-
64	-
65	-
66	-
67	-
68	-
69	-
70	-
71	-
72	-
73	-
74	-
75	-

All contents of this site are © 2024 Passmedicine Limited

Back to top

A 56-year-old man presents to the Medical Admissions unit with a two-week history of a productive cough. His past medical history is significant for type 2 diabetes mellitus. He reports that he developed a cough productive of green sputum shortly after returning from a business trip to the United States. He also complains of persistent retrosternal pain for the last ten days. He has completed a course of doxycycline prescribed by his GP, to little symptomatic benefit.

Alongside routine blood tests, he provides a sputum sample for culture, with provisional results as follows:

Sputum culture	Fungal spores seen - full speciation awaited

Based on the likely diagnosis, what is the most appropriate management option?

Co-trimoxazole	9%
Co-trimoxazole + prednisolone	12%
Dapsone	2%
Itraconazole	62%
Voriconazole	16%

Amphotericin or itraconazole are the pharmacological agents of choice for histoplasmosis

Important for me Less important

The correct answer is **itraconazole**. This patient has a likely diagnosis of histoplasmosis. This is based on the presence of retrosternal pain alongside symptoms of a respiratory tract infection, combined with a history of recent travel to the United States, where the causative pathogen *Histoplasma capsulatum* is endemic, in parts. Further weight is given to the diagnosis of histoplasmosis by the presence of fungal spores in sputum culture. Of the options provided, only itraconazole is a typical first-line treatment of histoplasmosis.

Co-trimoxazole is incorrect. This would be an appropriate initial management option for *Pneumocystis jirovecii* pneumonia (PJP). This would tend to appear in question stems as a cause for hypoxia with exertional desaturation in immunosuppressed patients, rather than with a productive

cough and retrosternal pain. Diagnosis tends to be confirmed on bronchoalveolar lavage rather than sputum culture.

Co-trimoxazole + prednisolone is incorrect as this would tend to be a regime used for PJP with severe hypoxia rather than histoplasmosis.

Dapsone is incorrect, as this tends to be used as a second-line agent for PJP if co-trimoxazole is ineffective or contraindicated, rather than treatment for histoplasmosis.

Voriconazole is incorrect. Although from the same class of drugs as itraconazole, voriconazole is more conventionally used for the treatment of invasive aspergillosis, or its prevention, for example in allogeneic stem cell transplant recipients. It is not typically used as a first-line treatment option for histoplasmosis.

Discuss (2) Improve

Next question

Histoplasmosis

Histoplasmosis is due to the fungus *Histoplasma capsulatum*. It is most commonly encountered in the Mississippi and Ohio River valleys.

Features
- URTI symptoms
- retrosternal pain

Management
- amphotericin or itraconazole are the pharmacological agents of choice for histoplasmosis

123

Next question

Textbooks

High-yield textbook

Extended textbook

Score: **15.3%**

1	✗
2	✗
3	✗
4	✗
5	✗
6	✗
7	✗
8	✗
9	✓
10	✓
11	✗
12	✗
13	✗
14	✓
15	✗
16	✓
17	✗
18	✗
19	✗
20	✗
21	✓
22	✓
23	✗
24	✗

25	✗
26	✗
27	✓
28	✗
29	✗
30	✓
31	✓
32	✗
33	✗
34	✗
35	✗
36	✗
37	✗
38	✗
39	✗
40	-
41	✗
42	✗
43	✗
44	✗
45	✓
46	✗
47	✗
48	✗
49	✗
50	✗
51	✗
52	✗
53	✗
54	✗
55	✗
56	✗
57	✗
58	✗
59	✗
60	✗

61	✗
62	✗
63	✗
64	✗
65	✗
66	✗
67	✓
68	✗
69	✓
70	✗
71	✗
72	✓
73	✗
74	✗
75	✗
76	✗
77	✗
78	-
79	✗
80	✗
81	✓
82	✗
83	✗
84	✗
85	✗
86	✗
87	✗
88	✗
89	✗
90	✓
91	✗
92	✗
93	✗
94	✗
95	✗
96	✗

97 ✗
98 ✗
99 ✗
100 ✗

All contents of this site are © 2024 Passmedicine Limited

Back to top

A 21-year-old man is admitted to the specialist burns unit with severe burns following a house fire. He is haemodynamically stable and receives IV fluids and oxygen, although does not require intubation. Three days after his admission, he develops acute-onset shortness of breath. The only past medical history reported was hay-fever as a child and his mother has relapsing-remitting multiple sclerosis. He smoked 1-2 roll-up cigarettes per week and did not drink any alcohol.

His observations include a respiratory rate of 28 breaths per minute, oxygen saturations of 91% on 12L of oxygen, a heart rate of 112 beats per minute and blood pressure of 114/78 mmHg. His temperature was 36.9ºC. Examination revealed widespread crackles over both lung fields.

Chest x-ray reveals bilateral infiltrates.

What is the most likely diagnosis?

- Hospital-acquired pneumonia
- Pneumonitis
- Acute respiratory distress syndrome
- Renal failure
- Asthma attack

Submit answer

Reference ranges

Score: **17.8%**

1 ✗
2 ✗

3	✗
4	✗
5	✗
6	✗
7	✗
8	✗
9	✓
10	✓
11	✗
12	✗
13	✗
14	✓
15	✗
16	✓
17	✗
18	✗
19	✗
20	✗
21	✓
22	✓
23	✗
24	✗
25	✗
26	✗
27	✓
28	✗
29	✗
30	✓
31	✓
32	✗
33	✗
34	✗
35	✗
36	✗
37	✗
38	✗

39	✗
40	-
41	✗
42	✗
43	✗
44	✗
45	✓
46	✗
47	✗
48	✗
49	✗
50	✗
51	✗
52	✗
53	✗
54	✗
55	✗
56	✗
57	✗
58	✗
59	✗
60	✗
61	✗
62	✗
63	✗
64	✗
65	✗
66	✗
67	✓
68	✗
69	✓
70	✗
71	✗
72	✓
73	✗
74	✗

75 -
76 -

All contents of this site are © 2024 Passmedicine Limited

A 21-year-old man is admitted to the specialist burns unit with severe burns following a house fire. He is haemodynamically stable and receives IV fluids and oxygen, although does not require intubation. Three days after his admission, he develops acute-onset shortness of breath. The only past medical history reported was hay-fever as a child and his mother has relapsing-remitting multiple sclerosis. He smoked 1-2 roll-up cigarettes per week and did not drink any alcohol.

His observations include a respiratory rate of 28 breaths per minute, oxygen saturations of 91% on 12L of oxygen, a heart rate of 112 beats per minute and blood pressure of 114/78 mmHg. His temperature was 36.9ºC. Examination revealed widespread crackles over both lung fields.

Chest x-ray reveals bilateral infiltrates.

What is the most likely diagnosis?

Hospital-acquired pneumonia	3%
Pneumonitis	10%
Acute respiratory distress syndrome	87%
Renal failure	0%
Asthma attack	0%

The correct answer is **Acute respiratory distress syndrome (ARDS)**. This patient presents with the classical features of ARDS following a major burn injury, which is a well-known precipitating factor. The diagnosis is supported by the acute onset of respiratory symptoms, bilateral infiltrates on chest x-ray, and hypoxaemia (requiring high-flow oxygen to maintain saturations above 90%) occurring within a week of the initial insult. The patient meets the Berlin criteria for ARDS, which includes timing within 7 days of a known clinical insult, bilateral opacities not fully explained by effusions or collapse, and respiratory failure not fully explained by cardiac failure or fluid overload.

Hospital-acquired pneumonia is incorrect because although this can occur in burns patients due to immunosuppression, the bilateral nature of the infiltrates and the timing (3 days) would be unusual. Hospital-acquired pneumonia typically presents after 48 hours of admission with unilateral changes initially, and often includes pyrexia and purulent sputum, which are not present here.

Pneumonitis is incorrect as this term typically refers to inflammation of lung tissue from non-infectious causes such as chemical injury or autoimmune conditions. While smoke inhalation can cause chemical pneumonitis, this would have been evident from admission rather than developing after three days.

Renal failure is incorrect as while this can occur in burns patients due to fluid loss and myoglobinuria, it would not explain the respiratory symptoms and chest x-ray findings. Whilst pulmonary oedema can occur in renal failure, the acute onset and bilateral infiltrates are more consistent with ARDS.

Asthma attack is incorrect because despite the patient's history of atopy (hay fever), the presentation is not consistent with acute asthma. Asthma typically presents with wheeze rather than crackles, and the chest x-ray would not show bilateral infiltrates. Additionally, asthma would be unlikely to develop acutely in this setting without a clear trigger.

Discuss (8) Improve

Next question

Acute respiratory distress syndrome

Acute respiratory distress syndrome (ARDS) is caused by the increased permeability of alveolar capillaries leading to fluid accumulation in the alveoli, i.e. non-cardiogenic pulmonary oedema. It is a serious condition that has a mortality of around 40% and is associated with significant morbidity in those who survive.

Causes

- infection: sepsis, pneumonia
- massive blood transfusion
- trauma
- smoke inhalation
- acute pancreatitis
- Covid-19
- cardio-pulmonary bypass

Clinical features are typically of an acute onset and severe:

- dyspnoea
- elevated respiratory rate
- bilateral lung crackles

- low oxygen saturations

A chest x-ray and arterial blood gases are the key investigations.

Criteria (American-European Consensus Conference)

- acute onset (within 1 week of a known risk factor)
- pulmonary oedema: bilateral infiltrates on chest x-ray ('not fully explained by effusions, lobar/lung collapse or nodules)
- non-cardiogenic (pulmonary artery wedge pressure needed if doubt)
- pO_2/FiO_2 < 40kPa (300 mmHg)

Management

- due to the severity of the condition patients are generally managed in ITU
- oxygenation/ventilation to treat the hypoxaemia
- general organ support e.g. vasopressors as needed
- treatment of the underlying cause e.g. antibiotics for sepsis
- certain strategies such as prone positioning and muscle relaxation have been shown to improve outcome in ARDS

AI + Q 123

Next question >

Textbooks

High-yield textbook

Extended textbook

Links

Royal College of Physicians 6 6

2011 Acute lung injury review

Radiopaedia

13 4

Acute respiratory distress syndrome

Suggest link

Report broken link

Media

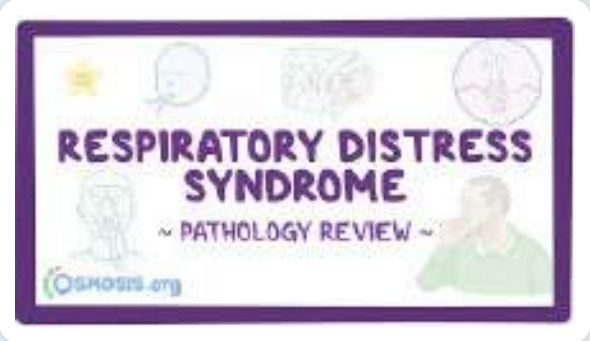

Respiratory distress syndrome

Osmosis - YouTube 8 1

Report broken media

Score: **15.3%**

1 ✗
2 ✗
3 ✗
4 ✗
5 ✗
6 ✗
7 ✗
8 ✗
9 ✓
10 ✓
11 ✗
12 ✗
13 ✗
14 ✓
15 ✗

16	✓
17	✗
18	✗
19	✗
20	✗
21	✓
22	✓
23	✗
24	✗
25	✗
26	✗
27	✓
28	✗
29	✗
30	✓
31	✓
32	✗
33	✗
34	✗
35	✗
36	✗
37	✗
38	✗
39	✗
40	-
41	✗
42	✗
43	✗
44	✗
45	✓
46	✗
47	✗
48	✗
49	✗
50	✗
51	✗

52	✗
53	✗
54	✗
55	✗
56	✗
57	✗
58	✗
59	✗
60	✗
61	✗
62	✗
63	✗
64	✗
65	✗
66	✗
67	✓
68	✗
69	✓
70	✗
71	✗
72	✓
73	✗
74	✗
75	✗
76	✗
77	✗
78	-
79	✗
80	✗
81	✓
82	✗
83	✗
84	✗
85	✗
86	✗
87	✗

88	✗
89	✗
90	✓
91	✗
92	✗
93	✗
94	✗
95	✗
96	✗
97	✗
98	✗
99	✗
100	✗

All contents of this site are © 2024 Passmedicine Limited

Back to top

A 52-year-old gentleman presents to the respiratory clinic with shortness of breath and a dry cough. He has noticed his symptoms getting progressively worse over months. He has a past medical history of hypertension and depression. He takes only ramipril and has no allergies. On examination, he has bilateral inspiratory crackles at both lung bases. A chest X-ray demonstrates extensive pleural plaques. He has worked as an electrician 20 years ago and believes that he may have had asbestos exposure. A diagnosis of asbestosis with extensive pleural plaques is suspected. What is his pulmonary function tests likely to show?

- FEV1 to FVC ratio >0.7
- FEV1 to FVC ratio <0.7
- Normal ratio of FEV1 to FVC and normal FEV1
- FEV1 to FVC ratio <0.7 but improves with inhaled steroids
- FEV1 to FVC ratio <0.7 but improves with inhaled salbutamol

Submit answer

Reference ranges

Score: **17.8%**

1 ✕
2 ✕
3 ✕
4 ✕
5 ✕
6 ✕
7 ✕

8	✗
9	✓
10	✓
11	✗
12	✗
13	✗
14	✓
15	✗
16	✓
17	✗
18	✗
19	✗
20	✗
21	✓
22	✓
23	✗
24	✗
25	✗
26	✗
27	✓
28	✗
29	✗
30	✓
31	✓
32	✗
33	✗
34	✗
35	✗
36	✗
37	✗
38	✗
39	✗
40	-
41	✗
42	✗
43	✗

44	✗
45	✓
46	✗
47	✗
48	✗
49	✗
50	✗
51	✗
52	✗
53	✗
54	✗
55	✗
56	✗
57	✗
58	✗
59	✗
60	✗
61	✗
62	✗
63	✗
64	✗
65	✗
66	✗
67	✓
68	✗
69	✓
70	✗
71	✗
72	✓
73	✗
74	✗
75	-
76	-
77	-

All contents of this site are © 2024 Passmedicine Limited

A 52-year-old gentleman presents to the respiratory clinic with shortness of breath and a dry cough. He has noticed his symptoms getting progressively worse over months. He has a past medical history of hypertension and depression. He takes only ramipril and has no allergies. On examination, he has bilateral inspiratory crackles at both lung bases. A chest X-ray demonstrates extensive pleural plaques. He has worked as an electrician 20 years ago and believes that he may have had asbestos exposure. A diagnosis of asbestosis with extensive pleural plaques is suspected. What is his pulmonary function tests likely to show?

FEV1 to FVC ratio >0.7	75%
FEV1 to FVC ratio <0.7	7%
Normal ratio of FEV1 to FVC and normal FEV1	15%
FEV1 to FVC ratio <0.7 but improves with inhaled steroids	2%
FEV1 to FVC ratio <0.7 but improves with inhaled salbutamol	1%

The correct answer is FEV1 to FVC ratio >0.7, which would be in keeping with a restrictive pattern if the FEV1 compared to expected was also reduced. In asbestosis, there is restriction of lung expansion due to pleural disease, limiting expansion of lung volume as the plaques are not as expansile as pulmonary tissue. This stops the lungs from fully expanding leading to a restrictive picture on spirometry. Obstructive patterns, with a decreased ratio of FEV1 to FVC would be associated with COPD and asthma.

Discuss (1) Improve

Next question

Asbestos and the lung

Asbestos can cause a variety of lung diseases from benign pleural plaques to mesothelioma.

Pleural plaques

Pleural plaques are benign and do not undergo malignant change. They, therefore don't require any follow-up. They are the most common form of asbestos-related lung disease and generally occur after a latent period of 20-40 years.

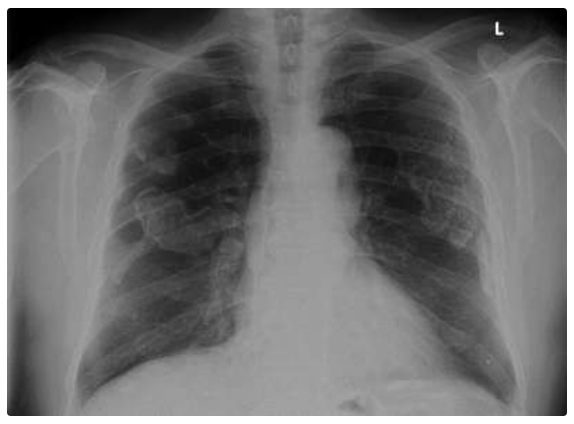

Pleural thickening

Asbestos exposure may cause diffuse pleural thickening in a similar pattern to that seen following an empyema or haemothorax. The underlying pathophysiology is not fully understood.

Asbestosis

The severity of asbestosis is related to the length of exposure. This is in contrast to mesothelioma where even very limited exposure can cause disease. The latent period is typically 15-30 years. Asbestosis typically causes lower lobe fibrosis.

Features

- dyspnoea and reduced exercise tolerance
- clubbing
- bilateral end-inspiratory crackles
- lung function tests show a restrictive pattern with reduced gas transfer

It is treated conservatively - no interventions offer a significant benefit.

Mesothelioma

Mesothelioma is a malignant disease of the pleura. Crocidolite (blue) asbestos is the most dangerous form.

Possible features

- progressive shortness-of-breath
- chest pain
- pleural effusion

Patients are usually offered palliative chemotherapy and there is also a limited role for surgery and radiotherapy. Unfortunately, the prognosis is very poor, with a median survival from diagnosis of 8-14 months.

Lung cancer

Whilst mesothelioma is in some ways synonymous with asbestos, lung cancer is actually the most common form of cancer associated with asbestos exposure. It also has a synergistic effect with cigarette smoke in terms of the increased risk. Therefore, smoking cessation is very important as the risk of lung cancer in smokers who have a history of asbestos exposure is very high.

+ Q 123

Next question

Textbooks

High-yield textbook

Extended textbook

Score: **15.3%**

1	✗
2	✗
3	✗
4	✗
5	✗
6	✗
7	✗
8	✗
9	✓
10	✓
11	✗
12	✗
13	✗
14	✓
15	✗
16	✓
17	✗
18	✗
19	✗
20	✗
21	✓
22	✓
23	✗
24	✗
25	✗
26	✗
27	✓
28	✗
29	✗
30	✓
31	✓
32	✗
33	✗
34	✗
35	✗

36	✗
37	✗
38	✗
39	✗
40	-
41	✗
42	✗
43	✗
44	✗
45	✓
46	✗
47	✗
48	✗
49	✗
50	✗
51	✗
52	✗
53	✗
54	✗
55	✗
56	✗
57	✗
58	✗
59	✗
60	✗
61	✗
62	✗
63	✗
64	✗
65	✗
66	✗
67	✓
68	✗
69	✓
70	✗
71	✗

72	✓
73	✗
74	✗
75	✗
76	✗
77	✗
78	-
79	✗
80	✗
81	✓
82	✗
83	✗
84	✗
85	✗
86	✗
87	✗
88	✗
89	✗
90	✓
91	✗
92	✗
93	✗
94	✗
95	✗
96	✗
97	✗
98	✗
99	✗
100	✗

All contents of this site are © 2024 Passmedicine Limited

Back to top

A 24-year-old woman attends the respiratory clinic for a review of her asthma treatment. The patient reported that overall, her symptoms of asthma had been well controlled in the 6 months since her last review. She had not suffered any significant exacerbations of her asthma in that time and felt she was required to use her salbutamol inhaler only around once per week (which represented a significant improvement over her normal control). The patient also reported that she was now 3 months pregnant, and had just had an unremarkable 12-week ultrasound. While she had not been planning to have a baby, the patient reported being very happy about it, and she was keen to maximise her health during this time.

The patient had a long-standing diagnosis of asthma, with her first presentations during early childhood. While the illness had only caused mild symptoms between the ages of 10 and 15 years, the patient had suffered several severe exacerbations of asthma in her late teenage years, coinciding with the time when the patient had become a regular smoker. The patient did not report any other significant on-going health problems or past medical history. In particular, she denied a history of seizures, high blood pressure or mental health problems.

The patient's current asthma treatment was a salmeterol-fluticasone combination inhaler (Seretide Accuhaler 250), one puff twice daily. She was also prescribed a metered-dose salbutamol inhaler for use as required. The patient had no history of drug allergies.

The patient reported that she continued to be a regular cigarette smoker. Since finding out she was pregnant, she had managed to reduce her regular intake to 12 cigarettes per day, reduced from her previous typical intake of 20 cigarettes per day. The patient was motivated to use her pregnancy as a motivating factor to stop smoking permanently, and during the clinic asked about medication to assist her with quitting.

What is the appropriate drug treatment strategy to assist this patient to stop smoking?

- Nicotine replacement patch with short-acting nicotine replacement
- Varenicline
- No drug treatment options available
- Bupropion
- Nicotine replacement patch only

Submit answer

Reference ranges

Score: **17.8%**

1	✗
2	✗
3	✗
4	✗
5	✗
6	✗
7	✗
8	✗
9	✓
10	✓
11	✗
12	✗
13	✗
14	✓
15	✗
16	✓
17	✗
18	✗
19	✗
20	✗
21	✓
22	✓
23	✗
24	✗
25	✗
26	✗

27	✓
28	✗
29	✗
30	✓
31	✓
32	✗
33	✗
34	✗
35	✗
36	✗
37	✗
38	✗
39	✗
40	-
41	✗
42	✗
43	✗
44	✗
45	✓
46	✗
47	✗
48	✗
49	✗
50	✗
51	✗
52	✗
53	✗
54	✗
55	✗
56	✗
57	✗
58	✗
59	✗
60	✗
61	✗
62	✗

63	✗
64	✗
65	✗
66	✗
67	✓
68	✗
69	✓
70	✗
71	✗
72	✓
73	✗
74	✗
75	-
76	-
77	-
78	-

All contents of this site are © 2024 Passmedicine Limited

Back to top

A 24-year-old woman attends the respiratory clinic for a review of her asthma treatment. The patient reported that overall, her symptoms of asthma had been well controlled in the 6 months since her last review. She had not suffered any significant exacerbations of her asthma in that time and felt she was required to use her salbutamol inhaler only around once per week (which represented a significant improvement over her normal control). The patient also reported that she was now 3 months pregnant, and had just had an unremarkable 12-week ultrasound. While she had not been planning to have a baby, the patient reported being very happy about it, and she was keen to maximise her health during this time.

The patient had a long-standing diagnosis of asthma, with her first presentations during early childhood. While the illness had only caused mild symptoms between the ages of 10 and 15 years, the patient had suffered several severe exacerbations of asthma in her late teenage years, coinciding with the time when the patient had become a regular smoker. The patient did not report any other significant on-going health problems or past medical history. In particular, she denied a history of seizures, high blood pressure or mental health problems.

The patient's current asthma treatment was a salmeterol-fluticasone combination inhaler (Seretide Accuhaler 250), one puff twice daily. She was also prescribed a metered-dose salbutamol inhaler for use as required. The patient had no history of drug allergies.

The patient reported that she continued to be a regular cigarette smoker. Since finding out she was pregnant, she had managed to reduce her regular intake to 12 cigarettes per day, reduced from her previous typical intake of 20 cigarettes per day. The patient was motivated to use her pregnancy as a motivating factor to stop smoking permanently, and during the clinic asked about medication to assist her with quitting.

What is the appropriate drug treatment strategy to assist this patient to stop smoking?

- Nicotine replacement patch with short-acting nicotine replacement
- Varenicline
- No drug treatment options available
- Bupropion
- Nicotine replacement patch only

Submit answer

Reference ranges

Score: **15.3%**

1	✗
2	✗
3	✗
4	✗
5	✗
6	✗
7	✗
8	✗
9	✓
10	✓
11	✗
12	✗
13	✗
14	✓
15	✗
16	✓
17	✗
18	✗
19	✗
20	✗
21	✓
22	✓
23	✗
24	✗
25	✗
26	✗

27	✓
28	✗
29	✗
30	✓
31	✓
32	✗
33	✗
34	✗
35	✗
36	✗
37	✗
38	✗
39	✗
40	-
41	✗
42	✗
43	✗
44	✗
45	✓
46	✗
47	✗
48	✗
49	✗
50	✗
51	✗
52	✗
53	✗
54	✗
55	✗
56	✗
57	✗
58	✗
59	✗
60	✗
61	✗
62	✗

63	✗
64	✗
65	✗
66	✗
67	✓
68	✗
69	✓
70	✗
71	✗
72	✓
73	✗
74	✗
75	✗
76	✗
77	✗
78	-
79	✗
80	✗
81	✓
82	✗
83	✗
84	✗
85	✗
86	✗
87	✗
88	✗
89	✗
90	✓
91	✗
92	✗
93	✗
94	✗
95	✗
96	✗
97	✗
98	✗

99 ✕

100 ✕

All contents of this site are © 2024 Passmedicine Limited

A 33-year-old woman with a three-year history of extremely difficult to control asthma and allergic rhinitis was admitted to the intensive care unit having been deteriorating at home for several weeks Blood tests from a GP consultation last week were available:

Hb	121 g/l(115 - 165)
Platelets	135 * 10^9/l(150 - 400)
WBC	11.8 * 10^9/l(4.0 - 11.0)
Neuts	7.6 * 10^9/l(1.5 - 7.0)
Lymphs	0.9 * 10^9/l(1.5 - 4.0)
Eosin	3.03 * 10^9/l(0.04 - 0.4)
Serum CRP	103 mg/l(<10)
c-ANCA	negative
p-ANCA	positive
PR3	5U/ml(<10)
MPO	100U/ml(<10)

What is the most likely diagnosis?

- Anti-glomerular basement antibody (anti-GBM) disease
- Legionnaires' disease
- Eosinophilic granulomatosis with polyangiitis
- Microscopic polyangiitis
- Granulomatosis with polyangiitis

Submit answer

Reference ranges

Score: **17.8%**

1	✗
2	✗
3	✗
4	✗
5	✗
6	✗
7	✗
8	✗
9	✓
10	✓
11	✗
12	✗
13	✗
14	✓
15	✗
16	✓
17	✗
18	✗
19	✗
20	✗
21	✓
22	✓
23	✗
24	✗
25	✗
26	✗
27	✓
28	✗
29	✗
30	✓
31	✓
32	✗
33	✗
34	✗

35	✗
36	✗
37	✗
38	✗
39	✗
40	-
41	✗
42	✗
43	✗
44	✗
45	✓
46	✗
47	✗
48	✗
49	✗
50	✗
51	✗
52	✗
53	✗
54	✗
55	✗
56	✗
57	✗
58	✗
59	✗
60	✗
61	✗
62	✗
63	✗
64	✗
65	✗
66	✗
67	✓
68	✗
69	✓
70	✗

71	✗
72	✓
73	✗
74	✗
75	-
76	-
77	-
78	-
79	-

All contents of this site are © 2024 Passmedicine Limited

A 33-year-old woman with a three-year history of extremely difficult to control asthma and allergic rhinitis was admitted to the intensive care unit having been deteriorating at home for several weeks Blood tests from a GP consultation last week were available:

Hb	121 g/l(115 - 165)
Platelets	135 * 10^9/l(150 - 400)
WBC	11.8 * 10^9/l(4.0 - 11.0)
Neuts	7.6 * 10^9/l(1.5 - 7.0)
Lymphs	0.9 * 10^9/l(1.5 - 4.0)
Eosin	3.03 * 10^9/l(0.04 - 0.4)
Serum CRP	103 mg/l(<10)
c-ANCA	negative
p-ANCA	positive
PR3	5U/ml(<10)
MPO	100U/ml(<10)

What is the most likely diagnosis?

- Anti-glomerular basement antibody (anti-GBM) disease 1%
- Legionnaires' disease 0%
- Eosinophilic granulomatosis with polyangiitis 91%
- Microscopic polyangiitis 4%
- Granulomatosis with polyangiitis 4%

Eosinophilic granulomatosis with polyangiitis is a necrotizing small vessel vasculitis

Important for me Less important

The most likely diagnosis is eosinophilic granulomatosis with polyangiitis (EGPA), which tends to progress through three phases: atopy (asthma, rhinitis, sinusitis), eosinophilia >10% (often with

pulmonary infiltrates), and necrotizing multi-system small vessel vasculitis. pANCA is positive in 40-70% of patients with eosinophilic granulomatosis with polyangiitis.

In contrast, patients with microscopic polyangiitis tend to have diffuse alveolar haemorrhage rather than nasal or asthma symptoms as the scenario depicted. Similarly, patients with granulomatosis with polyangiitis (Wegener's syndrome) tend not to have asthma as a feature and have predominantly positive cANCA. Patients with anti-glomerular basement antibody (anti-GBM) disease present with symptoms of pulmonary/renal involvement include haematuria, shortness of breath, cough, and expectoration of material that ranges from blood-streaked sputum to massive haemoptysis. The presence of anti-GBM antibodies is pathognomonic. Legionnaires disease is a form of pneumonia caused by *Legionella pneumophila* and negative to both cANCA and pANCA.

Discuss (2) Improve

Next question

Eosinophilic granulomatosis with polyangiitis (Churg-Strauss syndrome)

Eosinophilic granulomatosis with polyangiitis (EGPA) is now the preferred term for **Churg-Strauss syndrome**. It is an ANCA associated small-medium vessel vasculitis.

Features

- asthma
- blood eosinophilia (e.g. > 10%)
- paranasal sinusitis
- mononeuritis multiplex
- pANCA positive in 60%

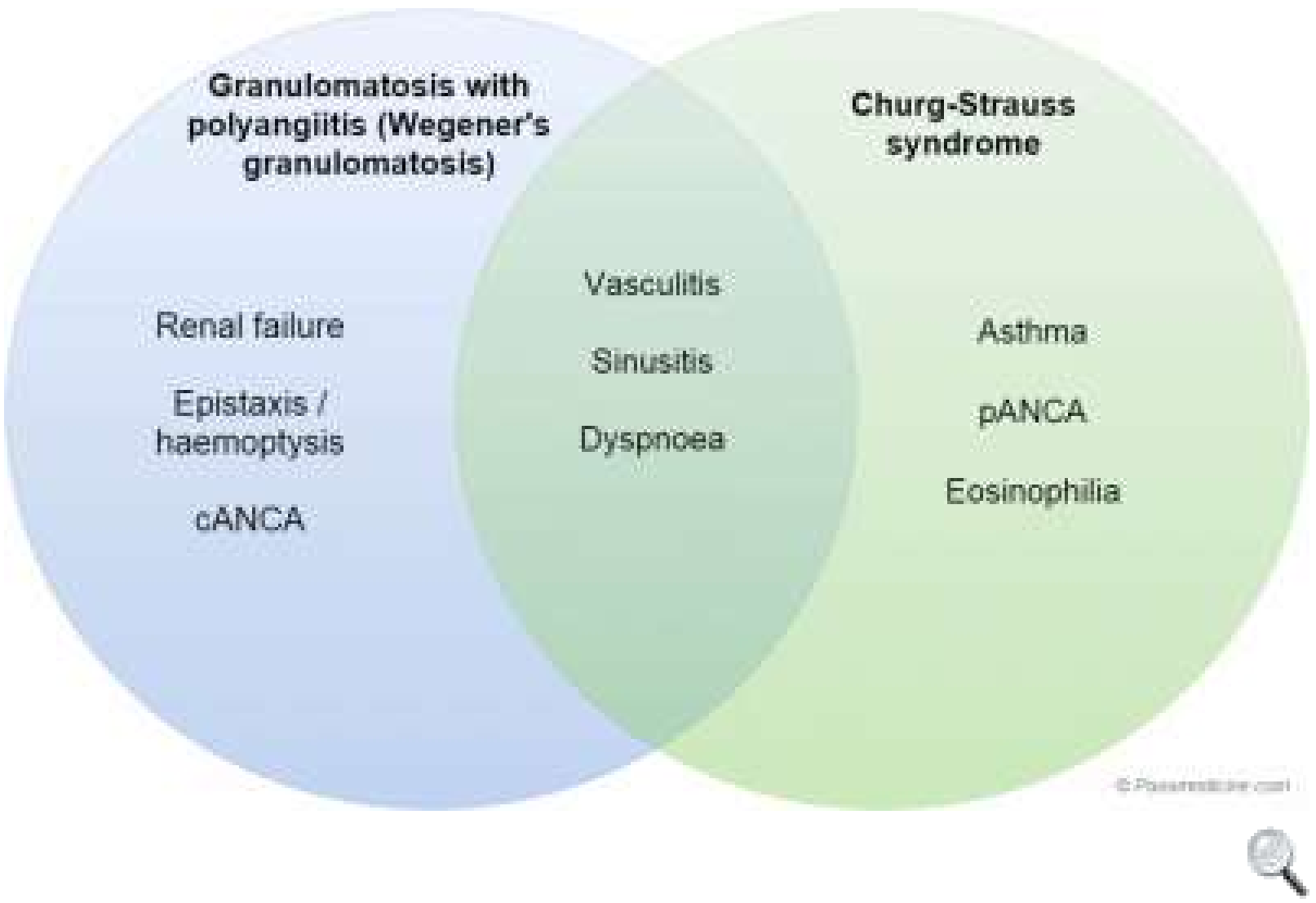

Comparison of granulomatosis with polyangiitis and Churg-Strauss syndrome

Leukotriene receptor antagonists may precipitate the disease.

123

Next question

Textbooks

High-yield textbook

Extended textbook

Media

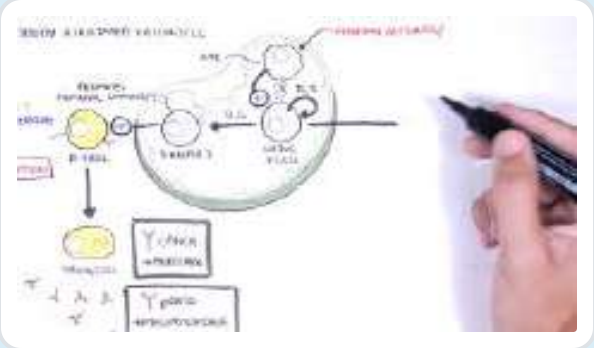

ANCA (Anti-Neutrophil Cytoplasmic Antibody) Associated Vasculitis - Causes, Pathophysiology, Types

Armando Hasudungan - YouTube 3 3

Report broken media

Score: **15.3%**

1 ✗

2	✗
3	✗
4	✗
5	✗
6	✗
7	✗
8	✗
9	✓
10	✓
11	✗
12	✗
13	✗
14	✓
15	✗
16	✓
17	✗
18	✗
19	✗
20	✗
21	✓
22	✓
23	✗
24	✗
25	✗
26	✗
27	✓
28	✗
29	✗
30	✓
31	✓
32	✗
33	✗
34	✗
35	✗
36	✗
37	✗

38	✗
39	✗
40	-
41	✗
42	✗
43	✗
44	✗
45	✓
46	✗
47	✗
48	✗
49	✗
50	✗
51	✗
52	✗
53	✗
54	✗
55	✗
56	✗
57	✗
58	✗
59	✗
60	✗
61	✗
62	✗
63	✗
64	✗
65	✗
66	✗
67	✓
68	✗
69	✓
70	✗
71	✗
72	✓
73	✗

74	✗
75	✗
76	✗
77	✗
78	-
79	✗
80	✗
81	✓
82	✗
83	✗
84	✗
85	✗
86	✗
87	✗
88	✗
89	✗
90	✓
91	✗
92	✗
93	✗
94	✗
95	✗
96	✗
97	✗
98	✗
99	✗
100	✗

All contents of this site are © 2024 Passmedicine Limited

A 60-year-old man is admitted with an infective exacerbation of COPD. He normally has a productive cough but has been bringing up large quantities of sputum and estimates about 1 cup of yellow sputum with streaks of blood being produced a day.

He takes steroid nose drops and had endoscopic surgery for recurrent sinusitis 5 years ago. He lives alone independently and drives a car. He can usually walk 50-100 metres on the flat.

He arrives to the emergency department in extremis. There is accessory muscle use and widespread coarse crepitations in both lungs. His heart sounds are normal with no signs of cardiac failure. He is started on antibiotics, steroids, aminophylline and back to back nebulisers. He continues to produce lots of phlegm and the nurses suction to clear a yellow mucoid substance from his mouth. He responds to commands, his eyes open to voice. and he is talking in normal words but his thoughts are incoherent. He is started on non invsaive ventilation and tolerates the mask. He continues to cough producing a 20ml plug of sputum with dried clot whilst given his first nebuliser. The respiratory registrar decides that NIV should be stopped.

Na^+	139 mmol/l
K^+	4.2 mmol/l
Urea	4.3 mmol/l
Creatinine	76 µmol/l
CRP	189 mmol mg/l

Hb	90 g/l
Platelets	$178 * 10^9$/l
WBC	$23 * 10^9$/l

ABG	(in air)
pH	7.39
pCO2	7.37 kPa
pO2	6.9 kPa
HCO3	25 mmol/l
Lactate	2.3 mmol/l

Chest x-ray	bilateral alveolar shadowing

Which contraindication to non invasive ventilation is present in this case?

- Copious secretions ×
- Not on maximal medical therapy ×
- Endoscopic sinus surgery ×
- Level of consciousness ×
- Lack of consent ×

Submit answer

Reference ranges

Score: **17.8%**

1	✗
2	✗
3	✗
4	✗
5	✗
6	✗
7	✗
8	✗
9	✓
10	✓
11	✗
12	✗
13	✗
14	✓
15	✗

16	✓
17	✗
18	✗
19	✗
20	✗
21	✓
22	✓
23	✗
24	✗
25	✗
26	✗
27	✓
28	✗
29	✗
30	✓
31	✓
32	✗
33	✗
34	✗
35	✗
36	✗
37	✗
38	✗
39	✗
40	-
41	✗
42	✗
43	✗
44	✗
45	✓
46	✗
47	✗
48	✗
49	✗
50	✗
51	✗

52	✗
53	✗
54	✗
55	✗
56	✗
57	✗
58	✗
59	✗
60	✗
61	✗
62	✗
63	✗
64	✗
65	✗
66	✗
67	✓
68	✗
69	✓
70	✗
71	✗
72	✓
73	✗
74	✗
75	-
76	-
77	-
78	-
79	-
80	-

All contents of this site are © 2024 Passmedicine Limited

Back to top

A 60-year-old man is admitted with an infective exacerbation of COPD. He normally has a productive cough but has been bringing up large quantities of sputum and estimates about 1 cup of yellow sputum with streaks of blood being produced a day.

He takes steroid nose drops and had endoscopic surgery for recurrent sinusitis 5 years ago. He lives alone independently and drives a car. He can usually walk 50-100 metres on the flat.

He arrives to the emergency department in extremis. There is accessory muscle use and widespread coarse crepitations in both lungs. His heart sounds are normal with no signs of cardiac failure. He is started on antibiotics, steroids, aminophylline and back to back nebulisers. He continues to produce lots of phlegm and the nurses suction to clear a yellow mucoid substance from his mouth. He responds to commands, his eyes open to voice. and he is talking in normal words but his thoughts are incoherent. He is started on non invsaive ventilation and tolerates the mask. He continues to cough producing a 20ml plug of sputum with dried clot whilst given his first nebuliser. The respiratory registrar decides that NIV should be stopped.

Na^+	139 mmol/l
K^+	4.2 mmol/l
Urea	4.3 mmol/l
Creatinine	76 µmol/l
CRP	189 mmol mg/l

Hb	90 g/l
Platelets	$178 * 10^9/l$
WBC	$23 * 10^9/l$

ABG	(in air)
pH	7.39
pCO2	7.37 kPa
pO2	6.9 kPa
HCO3	25 mmol/l
Lactate	2.3 mmol/l

Chest x-ray	bilateral alveolar shadowing

Which contraindication to non invasive ventilation is present in this case?

- Copious secretions 62%
- Not on maximal medical therapy 2%
- Endoscopic sinus surgery 10%
- Level of consciousness 25%
- Lack of consent 1%

Copious secretions are a contraindication to non-invasive ventilation

Important for me Less important

There are many contraindications to non invasive ventilation that must be carefully considered. Patients must be awake and able to protect their airway which this man although drowsy should be able to achieve with a Glasgow Coma Score of 13. The patient is on maximal medical therapy and there are few additional agents that would be helpful. His ENT surgery is important but some years ago and there is no head or neck trauma present which would be a contraindication. The gentleman is coughing up large volumes of sputum/secretions and this could pose a compromise to his airway. It is difficult to understand if he has capacity from the question but given his good premorbid function, active treatment would likely be in his best interests.

Discuss (5) Improve

Next question

Non-invasive ventilation

The British Thoracic Society (BTS) published guidelines in 2002 on the use of non-invasive ventilation in acute respiratory failure. Following these the Royal College of Physicians published guidelines in 2008.

Non-invasive ventilation - key indications

- COPD with respiratory acidosis pH 7.25-7.35
  - the BTS guidelines state that NIV can be used in patients who are more acidotic (i.e. pH < 7.25) but that a greater degree of monitoring is required (e.g. HDU) and a lower

threshold for intubation and ventilation should be used

- type II respiratory failure secondary to chest wall deformity, neuromuscular disease or obstructive sleep apnoea
- cardiogenic pulmonary oedema unresponsive to CPAP
- weaning from tracheal intubation

Recommended initial settings for bi-level pressure support in COPD

- Expiratory Positive Airway Pressure (EPAP): 4-5 cm H2O
- Inspiratory Positive Airway Pressure (IPAP): RCP advocate 10 cm H20 whilst BTS suggest 12-15 cm H2O
- back up rate: 15 breaths/min
- back up inspiration:expiration ratio: 1:3

+ Q 123

Next question

Textbooks

High-yield textbook

Extended textbook

Links

British Thoracic Society 12 4

2016 BTS/ICS Guidelines for the Ventilatory Management of Acute Hypercapnic Respiratory Failure in Adults

Suggest link Report broken link

Media

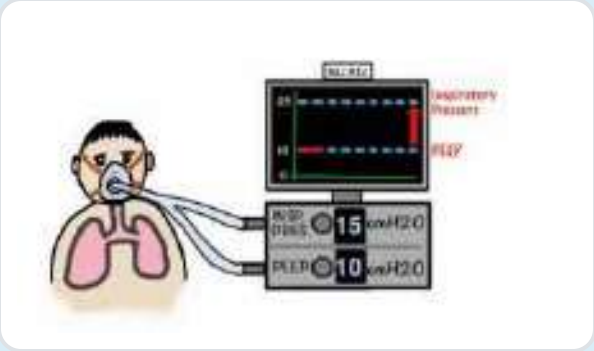

CPAP and Non-Invasive Ventilation in 5 minutes

Nick Smith - YouTube 31 2

Clinical Skills: BiPAP and CPAP

Osmosis - YouTube 3 7

Report broken media

Score: **15.3%**

1	✗
2	✗
3	✗
4	✗
5	✗
6	✗
7	✗
8	✗
9	✓
10	✓
11	✗
12	✗
13	✗
14	✓
15	✗
16	✓
17	✗

18	✗
19	✗
20	✗
21	✓
22	✓
23	✗
24	✗
25	✗
26	✗
27	✓
28	✗
29	✗
30	✓
31	✓
32	✗
33	✗
34	✗
35	✗
36	✗
37	✗
38	✗
39	✗
40	-
41	✗
42	✗
43	✗
44	✗
45	✓
46	✗
47	✗
48	✗
49	✗
50	✗
51	✗
52	✗
53	✗

54	✗
55	✗
56	✗
57	✗
58	✗
59	✗
60	✗
61	✗
62	✗
63	✗
64	✗
65	✗
66	✗
67	✓
68	✗
69	✓
70	✗
71	✗
72	✓
73	✗
74	✗
75	✗
76	✗
77	✗
78	-
79	✗
80	✗
81	✓
82	✗
83	✗
84	✗
85	✗
86	✗
87	✗
88	✗
89	✗

90	✓
91	✗
92	✗
93	✗
94	✗
95	✗
96	✗
97	✗
98	✗
99	✗
100	✗

All contents of this site are © 2024 Passmedicine Limited

Back to top

A 52-year-old gentleman is admitted to hospital with a cough and fever. He has been unwell for a week with high temperatures, coughing rusty coloured sputum as well as small amounts of blood. He has no significant past medical history but smokes ten cigarettes per day. A chest X-ray shows right sided lower lobe consolidation with a pleural effusion. An aspirate demonstrates low pH raising the suspicion of empyema and a chest drain is requested under ultrasound guidance. What factor may help predict drainage success or failure?

- Protein level of pleural fluid
- Echogenicity on US
- pH of pleural fluid
- Presence of associated consolidation
- Septation density on ultrasound

Submit answer

Reference ranges

Score: **17.8%**

1 ×
2 ×
3 ×
4 ×
5 ×
6 ×
7 ×
8 ×

9	✓
10	✓
11	✗
12	✗
13	✗
14	✓
15	✗
16	✓
17	✗
18	✗
19	✗
20	✗
21	✓
22	✓
23	✗
24	✗
25	✗
26	✗
27	✓
28	✗
29	✗
30	✓
31	✓
32	✗
33	✗
34	✗
35	✗
36	✗
37	✗
38	✗
39	✗
40	-
41	✗
42	✗
43	✗
44	✗

45	✓
46	✗
47	✗
48	✗
49	✗
50	✗
51	✗
52	✗
53	✗
54	✗
55	✗
56	✗
57	✗
58	✗
59	✗
60	✗
61	✗
62	✗
63	✗
64	✗
65	✗
66	✗
67	✓
68	✗
69	✓
70	✗
71	✗
72	✓
73	✗
74	✗
75	-
76	-
77	-
78	-
79	-
80	-
81	-

All contents of this site are © 2024 Passmedicine Limited

A 52-year-old gentleman is admitted to hospital with a cough and fever. He has been unwell for a week with high temperatures, coughing rusty coloured sputum as well as small amounts of blood. He has no significant past medical history but smokes ten cigarettes per day. A chest X-ray shows right sided lower lobe consolidation with a pleural effusion. An aspirate demonstrates low pH raising the suspicion of empyema and a chest drain is requested under ultrasound guidance. What factor may help predict drainage success or failure?

Protein level of pleural fluid	4%
Echogenicity on US	13%
pH of pleural fluid	18%
Presence of associated consolidation	2%
Septation density on ultrasound	63%

The correct answer is septation density on ultrasound. This is a patient with a possible empyema or parapneumonic effusion. The presence of low pH in the effusion makes the former more likely. The presence of septation density indicates various pockets within the effusion indicating that even if a drain accesses any pocket in particular, it may fail in draining all of the effusion. Protein level helps determine if an effusion is a transudate or an exudate, whilst a low pH is most useful in determining the risk of empyema. Consolidation may imply ongoing pneumonia and may suggest a cause of the effusion.

Discuss (4) Improve

Next question

Pleural effusion: investigation and management

The British Thoracic Society (BTS) produced guidelines in 2010 covering the investigation of patients with a pleural effusion.

Imaging

- posterioranterior (PA) chest x-rays should be performed in all patients
- ultrasound is recommended: it increases the likelihood of successful pleural aspiration and is sensitive for detecting pleural fluid septations
- contrast CT is now increasingly performed to investigate the underlying cause, particularly for exudative effusions

Pleural aspiration
- as above, ultrasound is recommended to reduce the complication rate
- a 21G needle and 50ml syringe should be used
- fluid should be sent for pH, protein, lactate dehydrogenase (LDH), cytology and microbiology

Light's criteria was developed in 1972 to help distinguish between a transudate and an exudate. The BTS recommend using the criteria for borderline cases:
- exudates have a protein level of >30 g/L, transudates have a protein level of <30 g/L
- if the protein level is between 25-35 g/L, Light's criteria should be applied. An exudate is likely if at least one of the following criteria are met:
    - pleural fluid protein divided by serum protein >0.5
    - pleural fluid LDH divided by serum LDH >0.6
    - pleural fluid LDH more than two-thirds the upper limits of normal serum LDH

Other characteristic pleural fluid findings:
- low glucose: rheumatoid arthritis, tuberculosis
- raised amylase: pancreatitis, oesophageal perforation
- heavy blood staining: mesothelioma, pulmonary embolism, tuberculosis

Pleural infection

All patients with a pleural effusion in association with sepsis or a pneumonic illness require diagnostic pleural fluid sampling
- if the fluid is purulent or turbid/cloudy a chest tube should be placed to allow drainage
- if the fluid is clear but the **pH is less than 7.2 in patients with suspected pleural infection a chest tube should be placed**

Management of recurrent pleural effusion

Options for managing patients with recurrent pleural effusions include:

- recurrent aspiration
- pleurodesis
- indwelling pleural catheter
- drug management to alleviate symptoms e.g. opioids to relieve dyspnoea

123

Next question

Textbooks

High-yield textbook

Extended textbook

Links

British Thoracic Society 17 14

2023 Pleural disease guidelines

Royal College of Physicians 13 7

2012 Pleural infection review

Suggest link Report broken link

Media

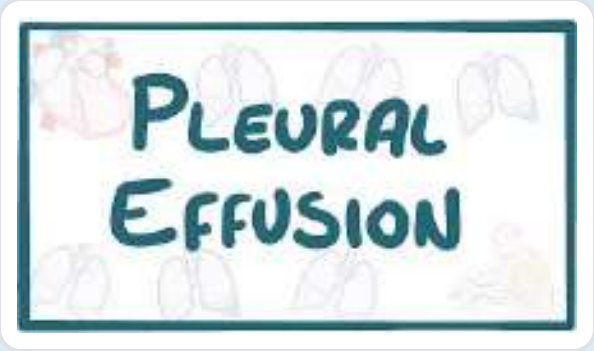

[Pleural effusion]

Osmosis - YouTube 8 1

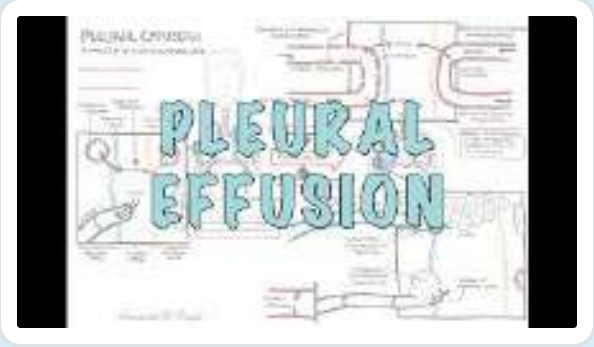

[Pleural effusion]

Armando Hasudungan - YouTube 6 1

Report broken media

Score: **15.3%**

1	✗
2	✗
3	✗
4	✗
5	✗
6	✗
7	✗
8	✗
9	✓
10	✓
11	✗
12	✗
13	✗
14	✓
15	✗
16	✓
17	✗

18	✗
19	✗
20	✗
21	✓
22	✓
23	✗
24	✗
25	✗
26	✗
27	✓
28	✗
29	✗
30	✓
31	✓
32	✗
33	✗
34	✗
35	✗
36	✗
37	✗
38	✗
39	✗
40	-
41	✗
42	✗
43	✗
44	✗
45	✓
46	✗
47	✗
48	✗
49	✗
50	✗
51	✗
52	✗
53	✗

54	✗
55	✗
56	✗
57	✗
58	✗
59	✗
60	✗
61	✗
62	✗
63	✗
64	✗
65	✗
66	✗
67	✓
68	✗
69	✓
70	✗
71	✗
72	✓
73	✗
74	✗
75	✗
76	✗
77	✗
78	-
79	✗
80	✗
81	✓
82	✗
83	✗
84	✗
85	✗
86	✗
87	✗
88	✗
89	✗

90	✓
91	✗
92	✗
93	✗
94	✗
95	✗
96	✗
97	✗
98	✗
99	✗
100	✗

All contents of this site are © 2024 Passmedicine Limited

Back to top

You arrange a long term oxygen therapy (LTOT) assessment for a 69-year-old man. He has a past medical history of COPD. He has developed dyspnoea at rest.

Results of the LTOT assessment are as follows:

ABG on air:

PaO2	7.1 kPa
PCO2	5.1 kPa
pH	7.41
HCO3	26 mmol/l

ABG after 1 litre of O2 via a nasal cannula:

PaO2	9.3 kPa
PCO2	6.5 kPa
pH	7.33
HCO3	26 mmol/l

The patient feels less short of breath at the end of the trial.

How will you manage this patient?

- Provide LTOT
- Decline LTOT
- Further medical optimisation and reassess after 4 weeks
- BiPAP
- CPAP

Submit answer

Reference ranges

Score: **17.8%**

1	✗
2	✗
3	✗
4	✗
5	✗
6	✗
7	✗
8	✗
9	✓
10	✓
11	✗
12	✗
13	✗
14	✓
15	✗
16	✓
17	✗
18	✗
19	✗
20	✗
21	✓
22	✓
23	✗
24	✗
25	✗
26	✗
27	✓
28	✗
29	✗
30	✓

31	✓
32	✗
33	✗
34	✗
35	✗
36	✗
37	✗
38	✗
39	✗
40	-
41	✗
42	✗
43	✗
44	✗
45	✓
46	✗
47	✗
48	✗
49	✗
50	✗
51	✗
52	✗
53	✗
54	✗
55	✗
56	✗
57	✗
58	✗
59	✗
60	✗
61	✗
62	✗
63	✗
64	✗
65	✗
66	✗

67	✓
68	✗
69	✓
70	✗
71	✗
72	✓
73	✗
74	✗
75	-
76	-
77	-
78	-
79	-
80	-
81	-
82	-

All contents of this site are © 2024 Passmedicine Limited

You arrange a long term oxygen therapy (LTOT) assessment for a 69-year-old man. He has a past medical history of COPD. He has developed dyspnoea at rest.

Results of the LTOT assessment are as follows:

ABG on air:

PaO2	7.1 kPa
PCO2	5.1 kPa
pH	7.41
HCO3	26 mmol/l

ABG after 1 litre of O2 via a nasal cannula:

PaO2	9.3 kPa
PCO2	6.5 kPa
pH	7.33
HCO3	26 mmol/l

The patient feels less short of breath at the end of the trial.

How will you manage this patient?

- Provide LTOT 20%
- Decline LTOT 9%
- Further medical optimisation and reassess after 4 weeks 38%
- BiPAP 29%
- CPAP 4%

Patients who develop a respiratory acidosis and/or a rise in $PaCO_2$ of >1 kPa (7.5 mmHg) during an LTOT assessment may have clinically unstable disease. These patients should undergo further medical optimisation and be reassessed after 4 weeks

Important for me Less important

The ABG on room air meets the criteria for LTOT as the PaO_2 is < 7.3 kPa. After a 1 hour trial of low flow oxygen, the patients symptoms have improved, and his PaO_2 has significantly improved. However it is important to note that his PCO_2 has significantly increased resulting in a respiratory acidosis.

Patients who develop a respiratory acidosis and/or a rise in $PaCO_2$ of >1 kPa (7.5 mmHg) during an LTOT assessment may have clinically unstable disease. These patients should undergo further medical optimisation and be reassessed after 4 weeks.

Discuss (7) Improve

Next question

COPD: long-term oxygen therapy

The 2018 NICE guidelines on COPD clearly define which patients should be assessed for and offered long-term oxygen therapy (LTOT). Patients who receive LTOT should breathe supplementary oxygen for at least 15 hours a day. Oxygen concentrators are used to provide a fixed supply for LTOT.

Assess patients if any of the following:

- very severe airflow obstruction (FEV1 < 30% predicted). Assessment should be 'considered' for patients with severe airflow obstruction (FEV1 30-49% predicted)
- cyanosis
- polycythaemia
- peripheral oedema
- raised jugular venous pressure
- oxygen saturations less than or equal to 92% on room air

Assessment is done by measuring arterial blood gases on 2 occasions at least 3 weeks apart in patients with stable COPD on optimal management.

Offer LTOT to patients with a pO_2 of < 7.3 kPa or to those with a pO_2 of 7.3 - 8 kPa and one of the following:

- secondary polycythaemia

- peripheral oedema
- pulmonary hypertension

In terms of smoking, NICE advise the following:

- do not offer LTOT to people who continue to smoke despite being offered smoking cessation advice and treatment, and referral to specialist stop smoking services.

NICE suggest that a structured risk assessment is carried out before offering LTOT, including:

- the risks of falls from tripping over the equipment
- the risks of burns and fires, and the increased risk of these for people who live in homes where someone smokes (including e-cigarettes)

+ Q 123

Next question ›

Textbooks

High-yield textbook

Extended textbook

Links

NICE

2018 COPD guidelines

17 6

Suggest link

Report broken link

Score: **15.3%**

1	✗
2	✗
3	✗
4	✗
5	✗
6	✗
7	✗
8	✗
9	✓
10	✓
11	✗
12	✗
13	✗
14	✓
15	✗
16	✓
17	✗
18	✗
19	✗
20	✗
21	✓
22	✓
23	✗
24	✗
25	✗
26	✗
27	✓
28	✗
29	✗
30	✓
31	✓
32	✗
33	✗
34	✗

35	✗
36	✗
37	✗
38	✗
39	✗
40	-
41	✗
42	✗
43	✗
44	✗
45	✓
46	✗
47	✗
48	✗
49	✗
50	✗
51	✗
52	✗
53	✗
54	✗
55	✗
56	✗
57	✗
58	✗
59	✗
60	✗
61	✗
62	✗
63	✗
64	✗
65	✗
66	✗
67	✓
68	✗
69	✓
70	✗

71	✗
72	✓
73	✗
74	✗
75	✗
76	✗
77	✗
78	-
79	✗
80	✗
81	✓
82	✗
83	✗
84	✗
85	✗
86	✗
87	✗
88	✗
89	✗
90	✓
91	✗
92	✗
93	✗
94	✗
95	✗
96	✗
97	✗
98	✗
99	✗
100	✗

All contents of this site are © 2024 Passmedicine Limited

Back to top

A 55-year-old male presents to the emergency department with worsening cough and breathlessness over the past three weeks. He reports a productive cough with haemoptysis and admits to fevers and weight loss over this time.

Past medical history is significant for type 2 diabetes mellitus. He currently smokes 20 cigarettes per day and drinks approximately 60 units per week.

Examination reveals on unkempt, cachectic man with bronchial breath sounds in the right upper zone.

Chest X-Ray is reported as having right upper lobe consolidation with a 'bulging fissure sign'

What is the most likely causative organism?

- *Klebsiella pneumonia*
- *Mycobacterium tuberculosis*
- *Aspergillus fumigatus*
- *Staphylococcus aureus*
- *Streptococcus pneumoniae*

Submit answer

Reference ranges

Score: **17.8%**

1 ✕
2 ✕

3	✗
4	✗
5	✗
6	✗
7	✗
8	✗
9	✓
10	✓
11	✗
12	✗
13	✗
14	✓
15	✗
16	✓
17	✗
18	✗
19	✗
20	✗
21	✓
22	✓
23	✗
24	✗
25	✗
26	✗
27	✓
28	✗
29	✗
30	✓
31	✓
32	✗
33	✗
34	✗
35	✗
36	✗
37	✗
38	✗

39	✗
40	-
41	✗
42	✗
43	✗
44	✗
45	✓
46	✗
47	✗
48	✗
49	✗
50	✗
51	✗
52	✗
53	✗
54	✗
55	✗
56	✗
57	✗
58	✗
59	✗
60	✗
61	✗
62	✗
63	✗
64	✗
65	✗
66	✗
67	✓
68	✗
69	✓
70	✗
71	✗
72	✓
73	✗
74	✗

75	-
76	-
77	-
78	-
79	-
80	-
81	-
82	-
83	-

All contents of this site are © 2024 Passmedicine Limited

A 55-year-old male presents to the emergency department with worsening cough and breathlessness over the past three weeks. He reports a productive cough with haemoptysis and admits to fevers and weight loss over this time.

Past medical history is significant for type 2 diabetes mellitus. He currently smokes 20 cigarettes per day and drinks approximately 60 units per week.

Examination reveals on unkempt, cachectic man with bronchial breath sounds in the right upper zone.

Chest X-Ray is reported as having right upper lobe consolidation with a 'bulging fissure sign'

What is the most likely causative organism?

Klebsiella pneumonia	73%
Mycobacterium tuberculosis	13%
Aspergillus fumigatus	10%
Staphylococcus aureus	2%
Streptococcus pneumoniae	2%

The bulging fissure sign is classical of Klebsiella pneumonia

Important for me Less important

The bulging fissure sign is an increasingly rare but classical feature of *Klebsiella pneumonia*. It is due to large volumes of consolidation (typically in the right upper lobe) causing displacement of the adjacent fissure.
Other features in the question to support a diagnosis of *Klebsiella pneumonia* include a history of alcohol excess and haemoptysis, often described as 'red currant jelly sputum'.

Whilst tuberculosis is an important differential to consider but seldom causes such dense consolidation to cause this sign. Radiologically, tuberculosis and aspergillosis usually appear as cavities. Klebsiella can also cause an isolated cavitating pneumonia.

Both *Streptococcal pneumoniae* and *Staphylococcus aureus* appear radiologically as the bulging fissure sign, other features in the question would be present to point you towards this diagnosis. Questions relating to *Streptococcal pneumoniae* will often describe a cough productive of rusty-coloured sputum and often a proceeding herpes labialis. Questions relating to *Staphylococcus aureus* will commonly report a proceeding flu-like illness with subsequent rapid deterioration into a bacterial pneumonia.

Discuss (4) | Improve

Next question

Chest x-ray: cavitating lung lesion

Differential

- abscess (Staph aureus, Klebsiella and *Pseudomonas*)
- squamous cell lung cancer
- tuberculosis
- Wegener's granulomatosis
- pulmonary embolism
- rheumatoid arthritis
- aspergillosis, histoplasmosis, coccidioidomycosis

Next question

Textbooks

High-yield textbook

Extended textbook

Links

British Institute of Radiology 4 0

Unofficial guide to radiology

Radiopaedia 0 1

Pulmonary Cavity

Suggest link Report broken link

Score: **15.3%**

1	✗
2	✗
3	✗
4	✗
5	✗
6	✗
7	✗
8	✗
9	✓
10	✓
11	✗
12	✗
13	✗
14	✓
15	✗
16	✓
17	✗
18	✗
19	✗
20	✗
21	✓

22	✓
23	✗
24	✗
25	✗
26	✗
27	✓
28	✗
29	✗
30	✓
31	✓
32	✗
33	✗
34	✗
35	✗
36	✗
37	✗
38	✗
39	✗
40	-
41	✗
42	✗
43	✗
44	✗
45	✓
46	✗
47	✗
48	✗
49	✗
50	✗
51	✗
52	✗
53	✗
54	✗
55	✗
56	✗
57	✗

58	✗
59	✗
60	✗
61	✗
62	✗
63	✗
64	✗
65	✗
66	✗
67	✓
68	✗
69	✓
70	✗
71	✗
72	✓
73	✗
74	✗
75	✗
76	✗
77	✗
78	-
79	✗
80	✗
81	✓
82	✗
83	✗
84	✗
85	✗
86	✗
87	✗
88	✗
89	✗
90	✓
91	✗
92	✗
93	✗

94 ✕
95 ✕
96 ✕
97 ✕
98 ✕
99 ✕
100 ✕

All contents of this site are © 2024 Passmedicine Limited
Back to top

A 60-year-old gentleman is seen by his general practitioner 3 weeks after a recent infective exacerbation of COPD. He is currently well but concerned that this is his second exacerbation during this winter season.
He is currently managed on fostair, tiotropium and as required salbutamol. He currently has a mild cough but is well and has attended his recent COPD review.

Today, his chest is clear with no wheeze or crepitations. The JVP is not raised and there is no oedema. His oxygen saturations are 94% in air and he has a respiratory rate of 22 breaths per minute.

He is currently well and able to do his gardening and walks the dog up to half a mile each day. He does not get breathlessness at night and has been discharged from chest physio who are happy with his current performance.

FEV1 (% predicted)	40%
FVC (% predicted)	80%
Chest x-ray	several bullae noted, hyperexpanded chest with no consolidation
ECG	sinus rhythm, right bundle branch block

What intervention should be added to his current management?

- Furosemide
- Long term home oxygen
- Home nebulisers
- Roflumilast
- Pulmonary rehabilitation

Submit answer

Reference ranges

Score: **17.8%**

1	✗
2	✗
3	✗
4	✗
5	✗
6	✗
7	✗
8	✗
9	✓
10	✓
11	✗
12	✗
13	✗
14	✓
15	✗
16	✓
17	✗
18	✗
19	✗
20	✗
21	✓
22	✓
23	✗
24	✗
25	✗
26	✗
27	✓
28	✗
29	✗
30	✓

31	✓
32	✗
33	✗
34	✗
35	✗
36	✗
37	✗
38	✗
39	✗
40	-
41	✗
42	✗
43	✗
44	✗
45	✓
46	✗
47	✗
48	✗
49	✗
50	✗
51	✗
52	✗
53	✗
54	✗
55	✗
56	✗
57	✗
58	✗
59	✗
60	✗
61	✗
62	✗
63	✗
64	✗
65	✗
66	✗

67	✓
68	✗
69	✓
70	✗
71	✗
72	✓
73	✗
74	✗
75	-
76	-
77	-
78	-
79	-
80	-
81	-
82	-
83	-
84	-

All contents of this site are © 2024 Passmedicine Limited

Back to top

A 60-year-old gentleman is seen by his general practitioner 3 weeks after a recent infective exacerbation of COPD. He is currently well but concerned that this is his second exacerbation during this winter season.
He is currently managed on fostair, tiotropium and as required salbutamol. He currently has a mild cough but is well and has attended his recent COPD review.

Today, his chest is clear with no wheeze or crepitations. The JVP is not raised and there is no oedema. His oxygen saturations are 94% in air and he has a respiratory rate of 22 breaths per minute.

He is currently well and able to do his gardening and walks the dog up to half a mile each day. He does not get breathlessness at night and has been discharged from chest physio who are happy with his current performance.

FEV1 (% predicted)	40%
FVC (% predicted)	80%
Chest x-ray	several bullae noted, hyperexpanded chest with no consolidation
ECG	sinus rhythm, right bundle branch block

What intervention should be added to his current management?

- Furosemide 1%
- Long term home oxygen 7%
- Home nebulisers 5%
- Roflumilast 57%
- Pulmonary rehabilitation 31%

Oral PDE-4 inhibitors such as roflumilast reduce the risk of COPD exacerbations in patients with severe COPD and a history of frequent COPD exacerbations

Important for me Less important

This is a gentleman with COPD and two recent exacerbations. He shows no signs of cor pulmonale or fluid overload and would therefore not benefit from a loop diuretic. Home nebulisers and pulmonary rehabilitation can be beneficial in severe symptomatic COPD but this patient is currently well and maintaining regular exertion without difficulty. Likewise, he is not hypoxic and there are no signs of cor pulmonale so he would not be a candidate for long term home oxygen. This leaves roflumilast as the answer, this is a phosphodiesterase-4 inhibitor that is recommended in COPD patients on maximal medical therapy with FEV1 <50% and had more than one exacerbation as per recent GOLD guidance.

Discuss (8) | Improve

Next question >

COPD: stable management

NICE updated its guidelines on the management of chronic obstructive pulmonary disease (COPD) in 2018.

General management

- >smoking cessation advice: including offering nicotine replacement therapy, varenicline or bupropion
- annual influenza vaccination
- one-off pneumococcal vaccination
- pulmonary rehabilitation to all people who view themselves as functionally disabled by COPD (usually Medical Research Council [MRC] grade 3 and above)

Bronchodilator therapy

- a short-acting beta2-agonist (SABA) or short-acting muscarinic antagonist (SAMA) is first-line treatment
- for patients who remain breathless or have exacerbations despite using short-acting bronchodilators the next step is determined by whether the patient has '*asthmatic features/features suggesting steroid responsiveness*'

There are a number of criteria NICE suggest to determine whether a patient has asthmatic/steroid responsive features:

- any previous, secure diagnosis of asthma or of atopy
- a higher blood eosinophil count - note that NICE recommend a full blood count for all patients as part of the work-up
- substantial variation in FEV1 over time (at least 400 ml)
- substantial diurnal variation in peak expiratory flow (at least 20%)

Interestingly NICE do not recommend formal reversibility testing as one of the criteria. In the guidelines they state that *'routine spirometric reversibility testing is not necessary as part of the diagnostic process or to plan initial therapy with bronchodilators or corticosteroids. It may be unhelpful or misleading...'*. They then go on to discuss why they have reached this conclusion. Please see the guidelines for more details.

No asthmatic features/features suggesting steroid responsiveness

- add a long-acting beta2-agonist (LABA) + long-acting muscarinic antagonist (LAMA)
  - if already taking a SAMA, discontinue and switch to a SABA

Asthmatic features/features suggesting steroid responsiveness

- LABA + inhaled corticosteroid (ICS)
- if patients remain breathless or have exacerbations offer triple therapy i.e. LAMA + LABA + ICS
  - if already taking a SAMA, discontinue and switch to a SABA
- NICE recommend the use of combined inhalers where possible

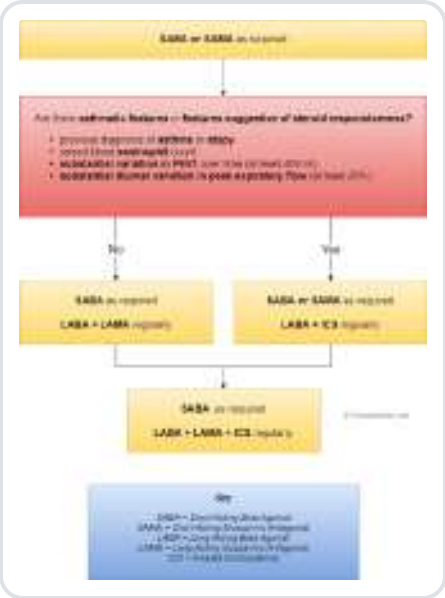

Oral theophylline

- NICE only recommends theophylline after trials of short and long-acting bronchodilators or to people who cannot used inhaled therapy
- the dose should be reduced if macrolide or fluoroquinolone antibiotics are co-prescribed

Oral prophylactic antibiotic therapy

- azithromycin prophylaxis is recommended in select patients
- patients should not smoke, have optimised standard treatments and continue to have exacerbations
- other prerequisites include a CT thorax (to exclude bronchiectasis) and sputum culture (to exclude atypical infections and tuberculosis)
- LFTs and an ECG to exclude QT prolongation should also be done as azithromycin can prolong the QT interval

Standby medication: NICE recommend offering a short course of oral corticosteroids and oral

antibiotics to keep at home if: NICE

- have had an exacerbation within the last year
- understand how to take the medication, and are aware of associated risks and benefits
- know to when to seek help and when to ask for replacements once medication has been used

Mucolytics

- should be 'considered' in patients with a chronic productive cough and continued if symptoms improve

Phosphodiesterase-4 (PDE-4) inhibitors NICE

- oral PDE-4 inhibitors such as roflumilast reduce the risk of COPD exacerbations in patients with severe COPD and a history of frequent COPD exacerbations
- NICE recommend if:
  - the disease is severe, defined as a forced expiratory volume in 1 second (FEV1) after a bronchodilator of less than 50% of predicted normal, and
  - the person has had 2 or more exacerbations in the previous 12 months despite triple inhaled therapy with a long-acting muscarinic antagonist, a long-acting beta-2 agonist and an inhaled corticosteroid

Cor pulmonale

- features include peripheral oedema, raised jugular venous pressure, systolic parasternal heave, loud P2
- use a loop diuretic for oedema, consider long-term oxygen therapy
- ACE-inhibitors, calcium channel blockers and alpha blockers are not recommended by NICE

Factors which may improve survival in patients with stable COPD

- smoking cessation - the single most important intervention in patients who are still smoking
- long term oxygen therapy in patients who fit criteria
- lung volume reduction surgery in selected patients

AI + Q 123

Next question >

Textbooks

High-yield textbook

Extended textbook

Links

Global Initiative for Chronic Obstructive Lung Disease 14 31

GOLD criteria 2017

NICE 33 29

2018 COPD guidelines

NICE 15 10

Roflumilast NICE recommendations

NICE 65 18

2018 COPD management diagram

Suggest link

Report broken link

Media

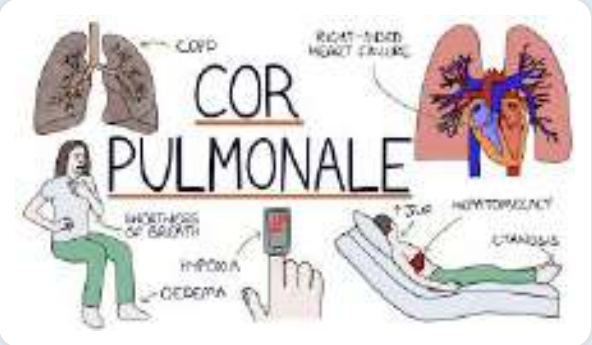

Cor pulmonale

Zero To Finals - YouTube 5 0

Chronic bronchitis

Osmosis - YouTube 3 0

Cor pulmonale

Osmosis - YouTube 1 0

Understanding COPD

Armando Hasudungan - YouTube 0 0

All about COPD (for Medical Students)

MedFlix - YouTube 3 1

Report broken media

Score: **15.3%**

1 ✗
2 ✗
3 ✗
4 ✗
5 ✗
6 ✗
7 ✗
8 ✗
9 ✓

10	✓
11	✗
12	✗
13	✗
14	✓
15	✗
16	✓
17	✗
18	✗
19	✗
20	✗
21	✓
22	✓
23	✗
24	✗
25	✗
26	✗
27	✓
28	✗
29	✗
30	✓
31	✓
32	✗
33	✗
34	✗
35	✗
36	✗
37	✗
38	✗
39	✗
40	-
41	✗
42	✗
43	✗
44	✗
45	✓

46	✗
47	✗
48	✗
49	✗
50	✗
51	✗
52	✗
53	✗
54	✗
55	✗
56	✗
57	✗
58	✗
59	✗
60	✗
61	✗
62	✗
63	✗
64	✗
65	✗
66	✗
67	✓
68	✗
69	✓
70	✗
71	✗
72	✓
73	✗
74	✗
75	✗
76	✗
77	✗
78	-
79	✗
80	✗
81	✓

82	✗
83	✗
84	✗
85	✗
86	✗
87	✗
88	✗
89	✗
90	✓
91	✗
92	✗
93	✗
94	✗
95	✗
96	✗
97	✗
98	✗
99	✗
100	✗

All contents of this site are © 2024 Passmedicine Limited

Back to top

A 73-year-old gentleman presents to oncology clinic with a two-week history of shortness of breath. He has a background of mesothelioma diagnosed two years ago. He has noticed that he has been finding it more difficult to walk distances without developing shortness of breath, and today struggled to make it into the clinic from the car-park, 200 yards away. He denies having a cough or fever but has been feeling more tired lately. Saturations are 95% whilst breathing room and his blood pressure, temperature, heart rate and respiratory rate are all within normal parameters.

A chest X-ray is done which demonstrates a right-sided pleural effusion. He is admitted to hospital and a chest drain is inserted, draining three litres of blood-stained fluid in two hours. He becomes increasingly short of breath and starts to cough. He denies any chest pain. On examination, he is uncomfortable and breathing 4L of oxygen via a non-rebreather mask. There are bilateral crepitations in his chest.

	25/11/16 16:31	25/11/16 14:18
Saturations	91%	95%
Respiratory rate	22/min	18/min
Blood pressure	131/81mmHg	139/85mmHg
Heart rate	101/min	71/min
Temperature	37.0°C	37.1°C

What is the likely diagnosis?

- Empyema
- Iatrogenic chest infection
- Re-expansion pulmonary oedema
- Pneumothorax
- PE

Submit answer

Reference ranges

Score: **17.8%**

1	✗
2	✗
3	✗
4	✗
5	✗
6	✗
7	✗
8	✗
9	✓
10	✓
11	✗
12	✗
13	✗
14	✓
15	✗
16	✓
17	✗
18	✗
19	✗
20	✗
21	✓
22	✓
23	✗
24	✗
25	✗
26	✗
27	✓
28	✗
29	✗
30	✓

31	✓
32	✗
33	✗
34	✗
35	✗
36	✗
37	✗
38	✗
39	✗
40	-
41	✗
42	✗
43	✗
44	✗
45	✓
46	✗
47	✗
48	✗
49	✗
50	✗
51	✗
52	✗
53	✗
54	✗
55	✗
56	✗
57	✗
58	✗
59	✗
60	✗
61	✗
62	✗
63	✗
64	✗
65	✗
66	✗

67	✓
68	✗
69	✓
70	✗
71	✗
72	✓
73	✗
74	✗
75	-
76	-
77	-
78	-
79	-
80	-
81	-
82	-
83	-
84	-
85	-

All contents of this site are © 2024 Passmedicine Limited

A 73-year-old gentleman presents to oncology clinic with a two-week history of shortness of breath. He has a background of mesothelioma diagnosed two years ago. He has noticed that he has been finding it more difficult to walk distances without developing shortness of breath, and today struggled to make it into the clinic from the car-park, 200 yards away. He denies having a cough or fever but has been feeling more tired lately. Saturations are 95% whilst breathing room and his blood pressure, temperature, heart rate and respiratory rate are all within normal parameters.

A chest X-ray is done which demonstrates a right-sided pleural effusion. He is admitted to hospital and a chest drain is inserted, draining three litres of blood-stained fluid in two hours. He becomes increasingly short of breath and starts to cough. He denies any chest pain. On examination, he is uncomfortable and breathing 4L of oxygen via a non-rebreather mask. There are bilateral crepitations in his chest.

	25/11/16 16:31	25/11/16 14:18
Saturations	91%	95%
Respiratory rate	22/min	18/min
Blood pressure	131/81mmHg	139/85mmHg
Heart rate	101/min	71/min
Temperature	37.0°C	37.1°C

What is the likely diagnosis?

- Empyema 2%
- Iatrogenic chest infection 1%
- Re-expansion pulmonary oedema 88%
- Pneumothorax 7%
- PE 2%

The correct answer is re-expansion pulmonary oedema. This is a potentially life-threatening condition which can occur when a large volume of fluid or air is rapidly drained, as has happened

with this patient. It is suggested by sudden onset of shortness of breath, cough and hypoxaemia following chest drain insertion. Empyema is unlikely given the absence of fever and no evidence of it on the original chest X-ray. Again, the absence of a fever makes iatrogenic infection less likely, and the timing is too early for infection. Pneumothorax is possible, but the examination demonstrates crepitations rather than any clinical evidence of pneumothorax. A PE is also possible given the history of malignancy and tachycardia and cannot be excluded clinically, but given the timing of the chest drain and the volume taken, re-expansion pulmonary oedema is more likely.

Source:

Givertz, Michael M. 'Noncardiogenic Pulmonary Edema.' Ed. Stephen S. Gottlieb. UpToDate. N.p., 22 Sept. 2015.

Discuss (7) | Improve

Next question >

Pleural effusion: investigation and management

The British Thoracic Society (BTS) produced guidelines in 2010 covering the investigation of patients with a pleural effusion.

Imaging

- posterioranterior (PA) chest x-rays should be performed in all patients
- ultrasound is recommended: it increases the likelihood of successful pleural aspiration and is sensitive for detecting pleural fluid septations
- contrast CT is now increasingly performed to investigate the underlying cause, particularly for exudative effusions

Pleural aspiration

- as above, ultrasound is recommended to reduce the complication rate
- a 21G needle and 50ml syringe should be used

- fluid should be sent for pH, protein, lactate dehydrogenase (LDH), cytology and microbiology

Light's criteria was developed in 1972 to help distinguish between a transudate and an exudate. The BTS recommend using the criteria for borderline cases:

- exudates have a protein level of >30 g/L, transudates have a protein level of <30 g/L
- if the protein level is between 25-35 g/L, Light's criteria should be applied. An exudate is likely if at least one of the following criteria are met:
  - pleural fluid protein divided by serum protein >0.5
  - pleural fluid LDH divided by serum LDH >0.6
  - pleural fluid LDH more than two-thirds the upper limits of normal serum LDH

Other characteristic pleural fluid findings:

- low glucose: rheumatoid arthritis, tuberculosis
- raised amylase: pancreatitis, oesophageal perforation
- heavy blood staining: mesothelioma, pulmonary embolism, tuberculosis

Pleural infection

All patients with a pleural effusion in association with sepsis or a pneumonic illness require diagnostic pleural fluid sampling

- if the fluid is purulent or turbid/cloudy a chest tube should be placed to allow drainage
- if the fluid is clear but the **pH is less than 7.2 in patients with suspected pleural infection a chest tube should be placed**

Management of recurrent pleural effusion

Options for managing patients with recurrent pleural effusions include:

- recurrent aspiration
- pleurodesis
- indwelling pleural catheter
- drug management to alleviate symptoms e.g. opioids to relieve dyspnoea

+ Q 123

Next question >

Textbooks

High-yield textbook

Extended textbook

Links

British Thoracic Society 17 14

2023 Pleural disease guidelines

Royal College of Physicians 13 7

2012 Pleural infection review

Suggest link Report broken link

Media

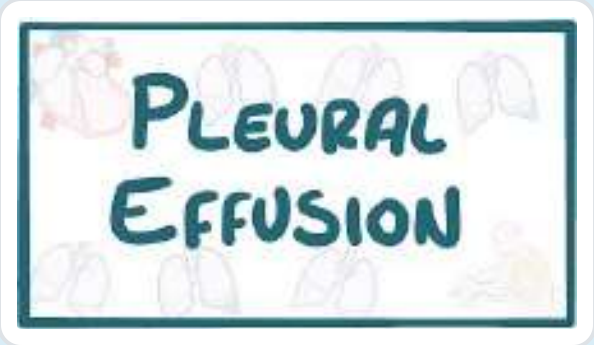

Pleural effusion

Osmosis - YouTube 8 1

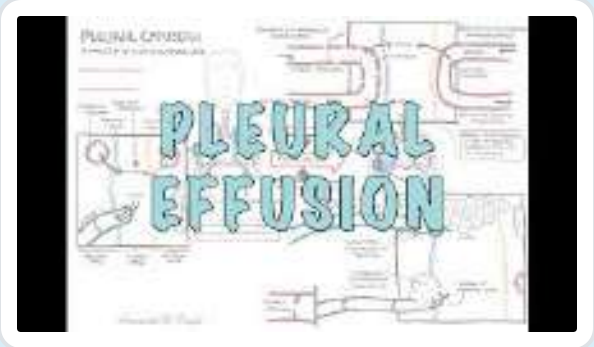

Pleural effusion

Armando Hasudungan - YouTube 6 1

Report broken media

Score: **15.3%**

1	✗
2	✗
3	✗
4	✗
5	✗
6	✗
7	✗
8	✗
9	✓
10	✓
11	✗
12	✗
13	✗
14	✓
15	✗
16	✓
17	✗
18	✗
19	✗
20	✗
21	✓
22	✓
23	✗
24	✗
25	✗
26	✗
27	✓
28	✗
29	✗
30	✓
31	✓

32	✗
33	✗
34	✗
35	✗
36	✗
37	✗
38	✗
39	✗
40	-
41	✗
42	✗
43	✗
44	✗
45	✓
46	✗
47	✗
48	✗
49	✗
50	✗
51	✗
52	✗
53	✗
54	✗
55	✗
56	✗
57	✗
58	✗
59	✗
60	✗
61	✗
62	✗
63	✗
64	✗
65	✗
66	✗
67	✓

68	✗
69	✓
70	✗
71	✗
72	✓
73	✗
74	✗
75	✗
76	✗
77	✗
78	-
79	✗
80	✗
81	✓
82	✗
83	✗
84	✗
85	✗
86	✗
87	✗
88	✗
89	✗
90	✓
91	✗
92	✗
93	✗
94	✗
95	✗
96	✗
97	✗
98	✗
99	✗
100	✗

All contents of this site are © 2024 Passmedicine Limited

A 26 year old asthmatic woman is admitted to hospital following a deliberate overdose of her usual theophylline tablets.

Which one of the following may be a complication of theophylline toxicity?

- Hypoglycaemia
- Atrioventricular nodal blockade
- Bronchoconstriction
- Increased myocardial contractility
- Hyperkalaemia

Submit answer

Reference ranges

Score: **17.8%**

1	✗
2	✗
3	✗
4	✗
5	✗
6	✗
7	✗
8	✗
9	✓
10	✓

11	✗
12	✗
13	✗
14	✓
15	✗
16	✓
17	✗
18	✗
19	✗
20	✗
21	✓
22	✓
23	✗
24	✗
25	✗
26	✗
27	✓
28	✗
29	✗
30	✓
31	✓
32	✗
33	✗
34	✗
35	✗
36	✗
37	✗
38	✗
39	✗
40	-
41	✗
42	✗
43	✗
44	✗
45	✓
46	✗

47	✗
48	✗
49	✗
50	✗
51	✗
52	✗
53	✗
54	✗
55	✗
56	✗
57	✗
58	✗
59	✗
60	✗
61	✗
62	✗
63	✗
64	✗
65	✗
66	✗
67	✓
68	✗
69	✓
70	✗
71	✗
72	✓
73	✗
74	✗
75	-
76	-
77	-
78	-
79	-
80	-
81	-
82	-
83	-

84 -
85 -
86 -

All contents of this site are © 2024 Passmedicine Limited

Back to top

A 26 year old asthmatic woman is admitted to hospital following a deliberate overdose of her usual theophylline tablets.

Which one of the following may be a complication of theophylline toxicity?

Hypoglycaemia	8%
Atrioventricular nodal blockade	36%
Bronchoconstriction	4%
Increased myocardial contractility	37%
Hyperkalaemia	16%

Theophylline poisoning presents with hypokalaemia, hyperglycaemia, tachycardia and increased myocardial contractility

Important for me Less important

Theophylline is a methylxanthine derivative drug which is structurally and clinically similar to caffeine. Aminophylline is the name given to theophylline when it is ligand bound to the chemical ethylenediamine which increases water solubility and hence aminophylline tends to be the intravenous form. Methylxanthine derivatives are used clinically for the treatment of bronchoconstriction in asthma, chronic obstructive pulmonary disease and in neonatal apnoea. They work in a two-fold fashion; firstly they inhibit the family of metabolic enzymes, the phosphodiesterases which increase levels of cyclic adenosine monophosphate and dampens the inflammatory cytokine cascade, and secondly they are competitive antagonists at the endogenous adenosine receptors located in the central nervous system, heart and lungs.

Inhibition of various phosphodiesterases causes a reduction in the circulating population of inflammatory cytokines and also increases cardiovascular and peripheral blood flow. Due to increased metabolism, hypokalaemia is common and gluconeogenesis and glycogenolysis is stimulated causing a rise in the plasma glucose load.

Competitive antagonism at the adenosine receptor causes roughly the opposite effects of adenosine. Whereas this drug is used clinically to slow the heart rate and block transmission at the AV node, theophyllines cause tachycardia and an increase in AV conduction, cardiac automaticity

and an increase in myocardial contractility, ultimately leading to an increased cardiac output with hypertension and flushing. Inhibition of adenosine receptors in bronchioles causes relaxation and improved airflow, and in the central nervous system leads to agitation, headache, anxiety, tremor and insomnia.

Other symptoms of methylxanthine toxicity include extreme nausea and vomiting, pancreatitis, gastroesophageal irritation, psychiatric symptoms and seizures. Tachyarrhythmias may deteriorate into ventricular rhythms quickly which may be fatal. Competing metabolic acidosis and respiratory alkalosis may cause a mixed arterial blood gas picture and many electrolyte disturbances can occur but an unexplained hyperglycaemia with a hypokalaemia is very suggestive of theophylline toxicity. Theophylline has a narrow window of therapeutic efficacy and patients may become toxic rapidly if drugs which inhibit their metabolism are given concurrently, particularly antibiotics such as macrolides or fluoroquinolones.
Management of theophylline toxicity is largely supportive with seizures controlled by benzodiazepines or intubation. Phenytoin is best avoided as it can worsen arrhythmia. Electrolyte abnormalities must be corrected, particularly hypokalaemia and hypomagnesaemia. Hypertension and tachycardia may respond to beta-blockers but beware of making the situation worse in an asthmatic patient. Verapamil is an alternative. Ventricular rhythms should be electrically cardioverted.

Theophyllines are one of the few drugs which are highly adsorbed by activated charcoal and this should be considered even beyond an hour after ingestion due to the extended release nature of most preparations and the drugs slowing of gastric emptying

Discuss (8) | Improve

Next question

Theophylline

Theophylline, like caffeine, is one of the naturally occurring methylxanthines. The main use of theophyllines in clinical medicine is as a bronchodilator in the management of asthma and COPD

The exact mechanism of action has yet to be discovered. One theory suggests theophyllines may be a non-specific inhibitor of phosphodiesterase resulting in an increase in cAMP. Other proposed mechanisms include antagonism of adenosine and prostaglandin inhibition

Theophylline poisoning

Features

- acidosis, hypokalaemia
- vomiting
- tachycardia, arrhythmias
- seizures

Management

- consider gastric lavage if <1 hour prior to ingestion
- activated charcoal
- whole-bowel irrigation can be performed if theophylline is sustained release form
- charcoal haemoperfusion is preferable to haemodialysis

AI + Q 123

Next question >

Textbooks

High-yield textbook

Extended textbook

Score: **15.3%**

1 ✗
2 ✗
3 ✗
4 ✗
5 ✗

6	✗
7	✗
8	✗
9	✓
10	✓
11	✗
12	✗
13	✗
14	✓
15	✗
16	✓
17	✗
18	✗
19	✗
20	✗
21	✓
22	✓
23	✗
24	✗
25	✗
26	✗
27	✓
28	✗
29	✗
30	✓
31	✓
32	✗
33	✗
34	✗
35	✗
36	✗
37	✗
38	✗
39	✗
40	-
41	✗

42	✗
43	✗
44	✗
45	✓
46	✗
47	✗
48	✗
49	✗
50	✗
51	✗
52	✗
53	✗
54	✗
55	✗
56	✗
57	✗
58	✗
59	✗
60	✗
61	✗
62	✗
63	✗
64	✗
65	✗
66	✗
67	✓
68	✗
69	✓
70	✗
71	✗
72	✓
73	✗
74	✗
75	✗
76	✗
77	✗

78	-
79	✗
80	✗
81	✓
82	✗
83	✗
84	✗
85	✗
86	✗
87	✗
88	✗
89	✗
90	✓
91	✗
92	✗
93	✗
94	✗
95	✗
96	✗
97	✗
98	✗
99	✗
100	✗

All contents of this site are © 2024 Passmedicine Limited

Back to top

A 53-year-old man with known interstitial lung disease presents with worsening of his shortness of breath, fevers and night sweats. He is an immigrant from Pakistan and has previously worked on quarry sites extracting silica from sand. He stopped due to shortness of breath and moved to the UK five years ago.

He does not work and can usually walk 100 metres before he becomes breathless but this has reduced to 10 metres over the past two weeks. He has a cough with phlegm but no haemoptysis and feels weak. He was well 1-2 months prior when he visited his home town in Pakistan and he does not recall meeting any ill contacts but reports that he took a number of long train journeys on public trains there.

On examination, he has crepitations in both lungs which are best heard at the apices. He is saturating at 92% on 2 litres of nasal cannulae. He is thin with a body mass index of 21. His JVP is not visible and there is no oedema in the calves.

Na^+	139 mmol/l
K^+	3.9 mmol/l
Urea	7.6 mmol/l
Creatinine	132 mmol/l

Hb	115 g/l
Platelets	$378 * 10^9/l$
WBC	$11.9 * 10^9/l$
Neuts	$9.8 * 10^9/l$
Eosin	$0.1 * 10^9/l$
D-dimer	elevated

Interferon-gamma release assay	positive
Sputum	gram stain negative, cultures awaited
ECG	sinus, p-pulmonale
Blood cultures	awaited
CXR	cavitating disease with reticulonodular pattern predominantly upper lobe

High-resolution CT chest	ground glass changes and honeycomb lung appearance, 2cm cavity seen in the left upper lobe with background emphysematous change

What is the likely diagnosis?

- Cor pulmonale
- Influenza
- Pulmonary embolism
- Tuberculosis
- Lower respiratory tract infection

Submit answer

Reference ranges

Score: **17.8%**

1 ✗
2 ✗
3 ✗
4 ✗
5 ✗
6 ✗
7 ✗
8 ✗
9 ✓
10 ✓
11 ✗
12 ✗
13 ✗
14 ✓

15	✗
16	✓
17	✗
18	✗
19	✗
20	✗
21	✓
22	✓
23	✗
24	✗
25	✗
26	✗
27	✓
28	✗
29	✗
30	✓
31	✓
32	✗
33	✗
34	✗
35	✗
36	✗
37	✗
38	✗
39	✗
40	-
41	✗
42	✗
43	✗
44	✗
45	✓
46	✗
47	✗
48	✗
49	✗
50	✗

51	✗
52	✗
53	✗
54	✗
55	✗
56	✗
57	✗
58	✗
59	✗
60	✗
61	✗
62	✗
63	✗
64	✗
65	✗
66	✗
67	✓
68	✗
69	✓
70	✗
71	✗
72	✓
73	✗
74	✗
75	-
76	-
77	-
78	-
79	-
80	-
81	-
82	-
83	-
84	-
85	-
86	-
87	-

All contents of this site are © 2024 Passmedicine Limited

A 53-year-old man with known interstitial lung disease presents with worsening of his shortness of breath, fevers and night sweats. He is an immigrant from Pakistan and has previously worked on quarry sites extracting silica from sand. He stopped due to shortness of breath and moved to the UK five years ago.

He does not work and can usually walk 100 metres before he becomes breathless but this has reduced to 10 metres over the past two weeks. He has a cough with phlegm but no haemoptysis and feels weak. He was well 1-2 months prior when he visited his home town in Pakistan and he does not recall meeting any ill contacts but reports that he took a number of long train journeys on public trains there.

On examination, he has crepitations in both lungs which are best heard at the apices. He is saturating at 92% on 2 litres of nasal cannulae. He is thin with a body mass index of 21. His JVP is not visible and there is no oedema in the calves.

Na^+	139 mmol/l
K^+	3.9 mmol/l
Urea	7.6 mmol/l
Creatinine	132 mmol/l

Hb	115 g/l
Platelets	$378 * 10^9/l$
WBC	$11.9 * 10^9/l$
Neuts	$9.8 * 10^9/l$
Eosin	$0.1 * 10^9/l$
D-dimer	elevated

Interferon-gamma release assay	positive
Sputum	gram stain negative, cultures awaited
ECG	sinus, p-pulmonale
Blood cultures	awaited
CXR	cavitating disease with reticulonodular pattern predominantly upper lobe

High-resolution CT chest	ground glass changes and honeycomb lung appearance, 2cm cavity seen in the left upper lobe with background emphysematous change

What is the likely diagnosis?

Cor pulmonale	6%
Influenza	1%
Pulmonary embolism	3%
Tuberculosis	90%
Lower respiratory tract infection	1%

Silicosis increases susceptibility to tuberculosis

Important for me Less important

This gentleman with previous silica exposure likely has silicosis. He has recent travel on long distance train journeys and pulmonary embolism is possible. However, he has more systemic symptoms with weight loss and night sweats and has been to the Indian subcontinent where tuberculosis is prevalent. His IGRA test is positive suggesting exposure and he has cavitating disease on his CXR/CT scan. He could have a lower respiratory tract infection or influenza but the presentation is usually more acute. Cor pulmonale is the development of right-sided heart failure on the background of chronic respiratory distress and this is usually more gradual. Patients with silicosis are at higher risk of tuberculosis infection that is more severe and extensive than for other people and is termed silicotuberculosis.

Discuss (5) Improve

Next question

Silicosis

Silicosis is a fibrosing lung disease caused by the inhalation of fine particles of crystalline silicon dioxide (silica). It is a risk factor for developing tuberculosis (silica is toxic to macrophages).

Occupations at risk of silicosis

- mining

- slate works
- foundries
- potteries

Features
- upper zone fibrosing lung disease
- 'egg-shell' calcification of the hilar lymph nodes

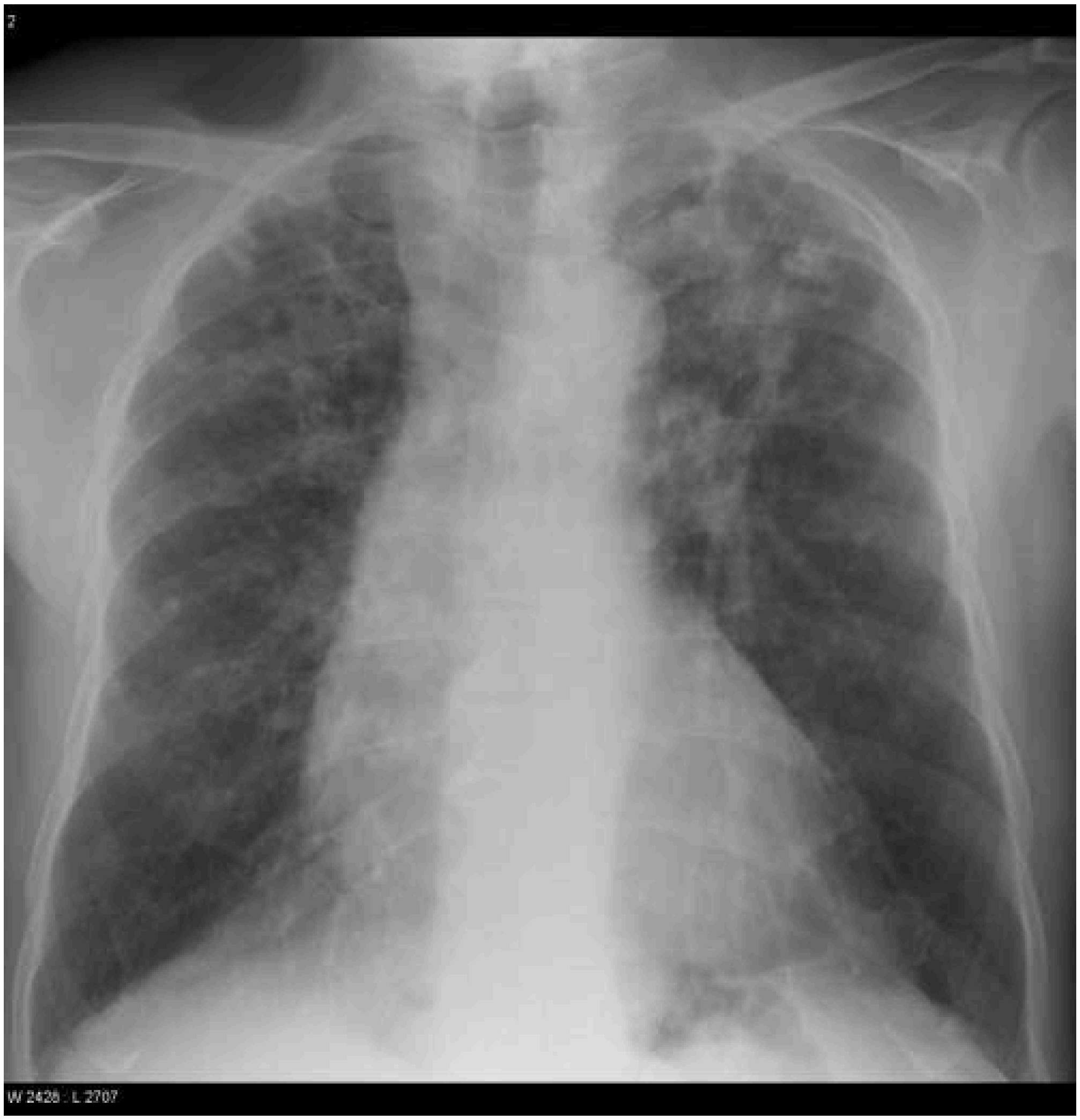

© Image used on license from Radiopaedia

Chest x-ray from a patient with silicosis. Note the bilateral diffuse upper lobe reticular shadowing superimposed with occasional scattered mass like opacities. These features are in keeping with silicosis and progressive massive fibrosis (PMF)

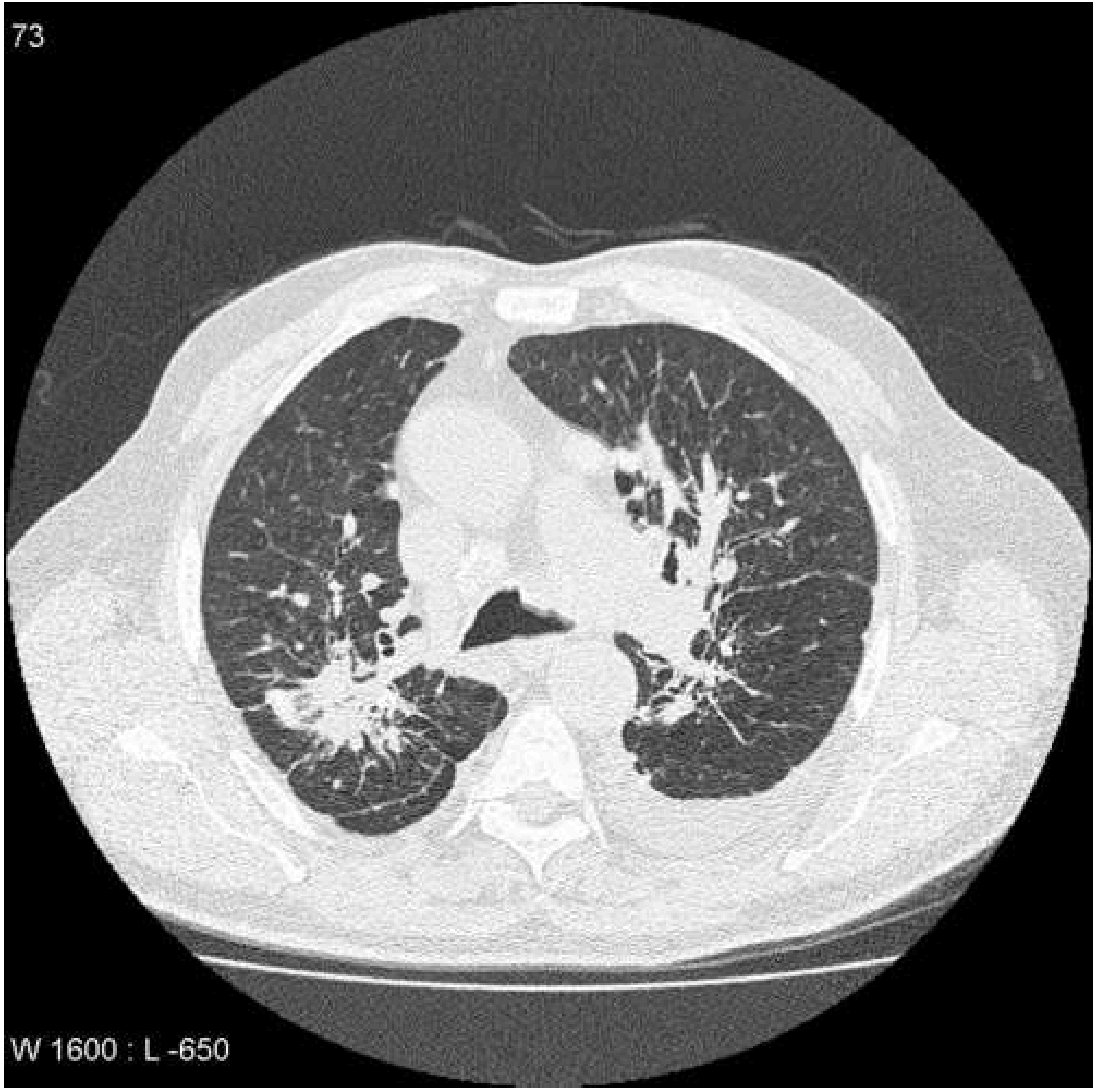

© Image used on license from Radiopaedia

CT scan from a patient with silicosis showing upper zone predominant mass-like scarring with calcification and volume loss. Hilar and mediastinal lymph node calcification also noted. No cavitary changes are seen. There is a left pleural effusion.

123

Next question

Textbooks

High-yield textbook

Extended textbook

Score: **15.3%**

1	✗
2	✗
3	✗
4	✗
5	✗
6	✗
7	✗
8	✗
9	✓
10	✓
11	✗
12	✗
13	✗
14	✓
15	✗
16	✓
17	✗
18	✗
19	✗
20	✗
21	✓
22	✓
23	✗
24	✗
25	✗
26	✗
27	✓
28	✗
29	✗

30	✓
31	✓
32	✗
33	✗
34	✗
35	✗
36	✗
37	✗
38	✗
39	✗
40	-
41	✗
42	✗
43	✗
44	✗
45	✓
46	✗
47	✗
48	✗
49	✗
50	✗
51	✗
52	✗
53	✗
54	✗
55	✗
56	✗
57	✗
58	✗
59	✗
60	✗
61	✗
62	✗
63	✗
64	✗
65	✗

66	✗
67	✓
68	✗
69	✓
70	✗
71	✗
72	✓
73	✗
74	✗
75	✗
76	✗
77	✗
78	-
79	✗
80	✗
81	✓
82	✗
83	✗
84	✗
85	✗
86	✗
87	✗
88	✗
89	✗
90	✓
91	✗
92	✗
93	✗
94	✗
95	✗
96	✗
97	✗
98	✗
99	✗
100	✗

All contents of this site are © 2024 Passmedicine Limited

A 74-year-old man is admitted to the hospital with a 2-month history of progressive dyspnoea and weight loss. He has also noted a cough productive of purulent phlegm, with occasional flecks of dark red blood. His only medical history is of type 2 diabetes for which he takes oral therapies. He is an ex-smoker of 40 pack years.

His observations reveal a heart rate of 80/min, blood pressure of 130/85 mmHg, temperature 37.4ºC, respiratory rate of 24 breaths per minute and oxygen saturation of 94% whilst breathing 4 litres/min via nasal cannula.

Laboratory results are shown below:

Hb	120 g/L	Male: (135-180) Female: (115 - 160)
Platelets	410 * 10^9/L	(150 - 400)
WBC	12.5 * 10^9/L	(4.0 - 11.0)
Na^+	130 mmol/L	(135 - 145)
K^+	3.9 mmol/L	(3.5 - 5.0)
Urea	6.7 mmol/L	(2.0 - 7.0)
Creatinine	78 µmol/L	(55 - 120)
Calcium	2.75 mmol/L	(2.1-2.6)
Phosphate	0.81 mmol/L	(0.8-1.4)
Parathyroid hormone	1.0 pmol/L	(1.6 - 7.2)
CRP	90 mg/L	(< 5)

His chest radiograph is shown below:

© Image used on license from Radiopaedia

What is the next most appropriate test for this patient?

- Bronchoscopy
- CT chest
- Ultrasound-guided pleural aspiration
- Sputum microscopy, sensitivity and culture (MC&S)
- Technetium sesta-methoxyisobutylisonitrile (sestamibi) imaging

Submit answer

Reference ranges

Score: **17.8%**

1 ✗
2 ✗

3	✗
4	✗
5	✗
6	✗
7	✗
8	✗
9	✓
10	✓
11	✗
12	✗
13	✗
14	✓
15	✗
16	✓
17	✗
18	✗
19	✗
20	✗
21	✓
22	✓
23	✗
24	✗
25	✗
26	✗
27	✓
28	✗
29	✗
30	✓
31	✓
32	✗
33	✗
34	✗
35	✗
36	✗
37	✗
38	✗

39	✗
40	-
41	✗
42	✗
43	✗
44	✗
45	✓
46	✗
47	✗
48	✗
49	✗
50	✗
51	✗
52	✗
53	✗
54	✗
55	✗
56	✗
57	✗
58	✗
59	✗
60	✗
61	✗
62	✗
63	✗
64	✗
65	✗
66	✗
67	✓
68	✗
69	✓
70	✗
71	✗
72	✓
73	✗
74	✗

75 -
76 -
77 -
78 -
79 -
80 -
81 -
82 -
83 -
84 -
85 -
86 -
87 -
88 -

All contents of this site are © 2024 Passmedicine Limited

Back to top

A 74-year-old man is admitted to the hospital with a 2-month history of progressive dyspnoea and weight loss. He has also noted a cough productive of purulent phlegm, with occasional flecks of dark red blood. His only medical history is of type 2 diabetes for which he takes oral therapies. He is an ex-smoker of 40 pack years.

His observations reveal a heart rate of 80/min, blood pressure of 130/85 mmHg, temperature 37.4ºC, respiratory rate of 24 breaths per minute and oxygen saturation of 94% whilst breathing 4 litres/min via nasal cannula.

Laboratory results are shown below:

Hb	120 g/L	Male: (135-180) Female: (115 - 160)
Platelets	410 * 10^9/L	(150 - 400)
WBC	12.5 * 10^9/L	(4.0 - 11.0)
Na^+	130 mmol/L	(135 - 145)
K^+	3.9 mmol/L	(3.5 - 5.0)
Urea	6.7 mmol/L	(2.0 - 7.0)
Creatinine	78 µmol/L	(55 - 120)
Calcium	2.75 mmol/L	(2.1-2.6)
Phosphate	0.81 mmol/L	(0.8-1.4)
Parathyroid hormone	1.0 pmol/L	(1.6 - 7.2)
CRP	90 mg/L	(< 5)

His chest radiograph is shown below:

© Image used on license from Radiopaedia

What is the next most appropriate test for this patient?

Bronchoscopy	4%
CT chest	19%
Ultrasound-guided pleural aspiration	75%
Sputum microscopy, sensitivity and culture (MC&S)	1%
Technetium sesta-methoxyisobutylisonitrile (sestamibi) imaging	1%

This man's chest x-ray shows a unilateral left-sided pleural effusion. The history of weight loss and haemoptysis in a smoker raises concern for an underlying malignancy. Infection is a possibility given his elevated CRP and borderline pyrexia however the hypercalcemia makes malignancy more likely. The most appropriate next test for this man is an ultrasound-guided aspiration of the pleural fluid to both ascertain a diagnosis and to alleviate his symptoms of dyspnoea. The pleural fluid should be tested for biochemistry (including pH, protein, glucose and LDH), microbiology and cytology.

A CT chest will form part of this man's diagnostic tests however a pleural aspiration will both add diagnostic value and alleviate his symptoms in the first instance.

If the cytology yielded from a pleural aspiration is non-diagnostic or insufficient, then a bronchoscopy could be considered. A CT scan of the chest would be required in advance of

pursuing a bronchoscopy.

Technetium sestamibi scan is a nuclear medicine imaging technique that helps to localise parathyroid adenomas. Although this man is hypercalcemic, his parathyroid hormone levels are appropriately suppressed thus there is no evidence of hyperparathyroidism.

Sputum microscopy, culture and sensitivity (MC&S) would be a reasonable test to perform however the concern based on the imaging and clinical syndrome is of malignancy. Sputum MC&S is an essential test when diagnosing respiratory infection but will not diagnose the pleural effusion found on this man's chest radiograph.

Discuss (2) Improve

Next question

Pleural effusion: investigation and management

The British Thoracic Society (BTS) produced guidelines in 2010 covering the investigation of patients with a pleural effusion.

Imaging

- posterioranterior (PA) chest x-rays should be performed in all patients
- ultrasound is recommended: it increases the likelihood of successful pleural aspiration and is sensitive for detecting pleural fluid septations
- contrast CT is now increasingly performed to investigate the underlying cause, particularly for exudative effusions

Pleural aspiration

- as above, ultrasound is recommended to reduce the complication rate
- a 21G needle and 50ml syringe should be used
- fluid should be sent for pH, protein, lactate dehydrogenase (LDH), cytology and microbiology

Light's criteria was developed in 1972 to help distinguish between a transudate and an exudate.

The BTS recommend using the criteria for borderline cases:

- exudates have a protein level of >30 g/L, transudates have a protein level of <30 g/L
- if the protein level is between 25-35 g/L, Light's criteria should be applied. An exudate is likely if at least one of the following criteria are met:
    - pleural fluid protein divided by serum protein >0.5
    - pleural fluid LDH divided by serum LDH >0.6
    - pleural fluid LDH more than two-thirds the upper limits of normal serum LDH

Other characteristic pleural fluid findings:

- low glucose: rheumatoid arthritis, tuberculosis
- raised amylase: pancreatitis, oesophageal perforation
- heavy blood staining: mesothelioma, pulmonary embolism, tuberculosis

Pleural infection

All patients with a pleural effusion in association with sepsis or a pneumonic illness require diagnostic pleural fluid sampling

- if the fluid is purulent or turbid/cloudy a chest tube should be placed to allow drainage
- if the fluid is clear but the **pH is less than 7.2 in patients with suspected pleural infection a chest tube should be placed**

Management of recurrent pleural effusion

Options for managing patients with recurrent pleural effusions include:

- recurrent aspiration
- pleurodesis
- indwelling pleural catheter
- drug management to alleviate symptoms e.g. opioids to relieve dyspnoea

+ Q 123

Next question >

Textbooks

High-yield textbook

Extended textbook

Links

British Thoracic Society 17 14

2023 Pleural disease guidelines

Royal College of Physicians 13 7

2012 Pleural infection review

Suggest link | Report broken link

Media

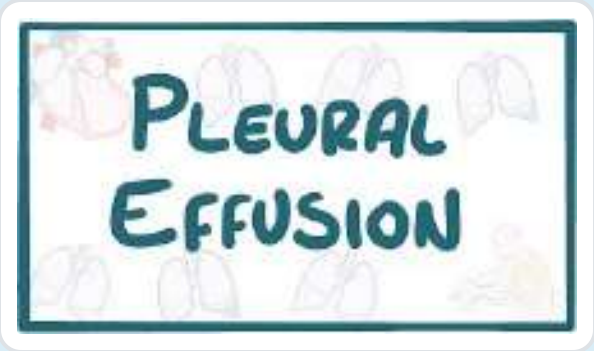

Pleural effusion

Osmosis - YouTube 8 1

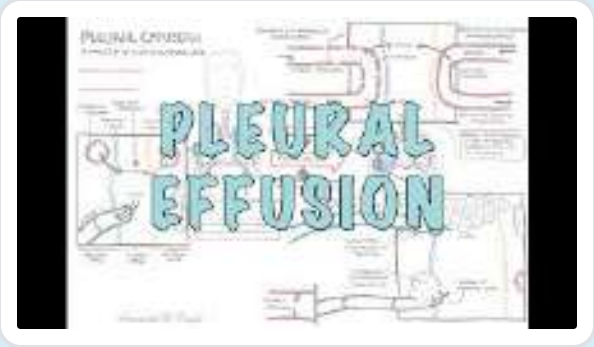

Pleural effusion

Armando Hasudungan - YouTube 6 1

Report broken media

Score: **15.3%**

1	✗
2	✗
3	✗
4	✗
5	✗
6	✗
7	✗
8	✗
9	✓
10	✓
11	✗
12	✗
13	✗
14	✓
15	✗
16	✓
17	✗
18	✗
19	✗
20	✗
21	✓
22	✓
23	✗
24	✗
25	✗
26	✗
27	✓
28	✗
29	✗
30	✓
31	✓
32	✗
33	✗
34	✗

35	✗
36	✗
37	✗
38	✗
39	✗
40	-
41	✗
42	✗
43	✗
44	✗
45	✓
46	✗
47	✗
48	✗
49	✗
50	✗
51	✗
52	✗
53	✗
54	✗
55	✗
56	✗
57	✗
58	✗
59	✗
60	✗
61	✗
62	✗
63	✗
64	✗
65	✗
66	✗
67	✓
68	✗
69	✓
70	✗

71	✗
72	✓
73	✗
74	✗
75	✗
76	✗
77	✗
78	-
79	✗
80	✗
81	✓
82	✗
83	✗
84	✗
85	✗
86	✗
87	✗
88	✗
89	✗
90	✓
91	✗
92	✗
93	✗
94	✗
95	✗
96	✗
97	✗
98	✗
99	✗
100	✗

All contents of this site are © 2024 Passmedicine Limited

Back to top

A 58-year-old man presents to the emergency department with a three-day history of sharp chest pain. He denies any shortness of breath. His pain is worse on deep inspiration and has not improved with paracetamol. He has no other symptoms. He has a past medical history of COPD and uses regular combination inhalers with salbutamol inhalers when he becomes short of breath. He has not recently had an exacerbation and he has never been admitted to ITU or had invasive ventilation. Examination demonstrates no abnormalities; the chest is clear on auscultation and vital parameters are within normal range. A chest X-ray demonstrates a <1cm right-sided pneumothorax. He is treated with high flow oxygen. What is the benefit of oxygen In the treatment of a pneumothorax?

- Maintaining pressure inside alveoli to prevent further expansion of pneumothorax
- Exchange of nitrogen for oxygen allowing quicker resorption of the pneumothorax
- Prophylactic treatment if suddenly becomes hypoxic
- There is no indication for oxygen
- Symptomatic relief

Submit answer

Reference ranges

Score: **17.8%**

1 ✕
2 ✕
3 ✕
4 ✕
5 ✕

6	✗
7	✗
8	✗
9	✓
10	✓
11	✗
12	✗
13	✗
14	✓
15	✗
16	✓
17	✗
18	✗
19	✗
20	✗
21	✓
22	✓
23	✗
24	✗
25	✗
26	✗
27	✓
28	✗
29	✗
30	✓
31	✓
32	✗
33	✗
34	✗
35	✗
36	✗
37	✗
38	✗
39	✗
40	-
41	✗

42	✗
43	✗
44	✗
45	✓
46	✗
47	✗
48	✗
49	✗
50	✗
51	✗
52	✗
53	✗
54	✗
55	✗
56	✗
57	✗
58	✗
59	✗
60	✗
61	✗
62	✗
63	✗
64	✗
65	✗
66	✗
67	✓
68	✗
69	✓
70	✗
71	✗
72	✓
73	✗
74	✗
75	-
76	-
77	-

78 -
79 -
80 -
81 -
82 -
83 -
84 -
85 -
86 -
87 -
88 -
89 -

All contents of this site are © 2024 Passmedicine Limited

A 58-year-old man presents to the emergency department with a three-day history of sharp chest pain. He denies any shortness of breath. His pain is worse on deep inspiration and has not improved with paracetamol. He has no other symptoms. He has a past medical history of COPD and uses regular combination inhalers with salbutamol inhalers when he becomes short of breath. He has not recently had an exacerbation and he has never been admitted to ITU or had invasive ventilation. Examination demonstrates no abnormalities; the chest is clear on auscultation and vital parameters are within normal range. A chest X-ray demonstrates a <1cm right-sided pneumothorax. He is treated with high flow oxygen. What is the benefit of oxygen In the treatment of a pneumothorax?

Maintaining pressure inside alveoli to prevent further expansion of pneumothorax	34%
Exchange of nitrogen for oxygen allowing quicker resorption of the pneumothorax	38%
Prophylactic treatment if suddenly becomes hypoxic	3%
There is no indication for oxygen	14%
Symptomatic relief	11%

The correct answer is the exchange of nitrogen for oxygen allowing quicker resorption. Patients who are diagnosed with a pneumothorax should be given high-flow oxygen as it allows the exchange of nitrogen from the air trapped forming the pneumothorax with the additionally inspired oxygen from given to the patient. This exchange increases the oxygen content of the pneumothorax whilst decreasing the nitrogen concentration. Oxygen is more readily absorbed, and therefore the pneumothorax resolves more quickly.

Discuss (11) Improve

Next question

Pneumothorax: management

The British Thoracic Society (BTS) published updated guidelines for the management of spontaneous pneumothorax in 2023.

The updated guidelines put less emphasis on the size of the pneumothorax and more emphasis on whether the patient is symptomatic and the presence of high-risk characteristics.

Decision algorithm

The first step is assessing whether the patient is symptomatic

- the BTS define minimal symptoms as '*no significant pain or breathlessness and no physiological compromise*'
- no or minimal symptoms → conservative care, regardless of pneumothorax size
- symptomatic → assess for high-risk characteristics

If a pneumothorax is symptomatic, the next step is assessment for high-risk characteristics

- high-risk characteristics are defined as follows:
  - haemodynamic compromise (suggesting a tension pneumothorax)
  - significant hypoxia
  - bilateral pneumothorax
  - underlying lung disease
  - ≥ 50 years of age with significant smoking history
  - haemothorax
- if no high-risk characteristics are present, and it is safe to intervene, then there is a choice of intervention:
  - conservative care
  - ambulatory device
  - needle aspiration
- if high-risk characteristics are present, and it is safe to intervene → chest drain

How is safety or intervention determined?

- before a needle aspiration/chest drain insertion, the safety of intervention should be assessed
- this depends on the clinical context, but is usually:
  - 2cm laterally or apically on chest x-ray, or
  - any size on CT scan which can be safely accessed with radiological support

Management options

Conservative care

- patients with a primary spontaneous pneumothorax that is managed conservatively should be reviewed every 2-4 days as an outpatient
- patients with a secondary spontaneous pneumothorax that is managed conservatively should be monitored as an inpatient
- if stable, follow-up in the outpatients department in 2-4 weeks

Ambulatory care

- an example of an ambulatory device is the Rocketµ Pleural Vent„
- it includes an 8FG catheter mounted on an 18G needle and a pigtail catheter to minimize the risk of occlusion
- ambulatory devices typically have a one-way valve and vent to prevent air and fluid return to the pleural space while allowing for controlled escape of air and drainage of fluid
- many devices also have an indication diaphragm that signals when the catheter tip enters the pleural space and continues to fluctuate with respiration, aiding in the assessment of pneumothorax resolution

Needle aspiration

- a chest drain should be inserted if needle aspiration of a pneumothorax is unsuccessful
- if resolved, discharge and follow-up in the outpatients department in 2-4 weeks

Chest drain insertion

- daily review as an inpatient
- remove drain when resolved
- discharge and follow-up in the outpatients department in 2-4 weeks

Persistentent / recurrent pneumothorax

If a patient has a persistent air leak or insufficient lung reexpansion despite chest drain insertion,

or the patient has recurrent pneumothoraces, then video-assisted thoracoscopic surgery (VATS) should be considered to allow for mechanical/chemical pleurodesis +/- bullectomy.

Discharge advice

Smoking

- patients should be advised to avoid smoking to reduce the risk of further episodes - the lifetime risk of developing a pneumothorax in healthy smoking men is around 10% compared with around 0.1% in non-smoking men

Fitness to fly

- absolute contraindication, the CAA suggest patients may travel 2 weeks after successful drainage if there is no residual air. The British Thoracic Society used to recommend not travelling by air for a period of 6 weeks but this has now been changed to 1 week post check x-ray

Scuba diving

- the BTS guidelines state: '*Diving should be permanently avoided unless the patient has undergone bilateral surgical pleurectomy and has normal lung function and chest CT scan postoperatively.*'

Image gallery

123

Next question

Textbooks

High-yield textbook

Extended textbook

Links

British Thoracic Society 👍 30 👎 26

2023 Pleural disease guidelines

Suggest link

Report broken link

Media

How to identify pneumothorax on a chest X-ray

Medmastery - YouTube 👍 30 👎 1

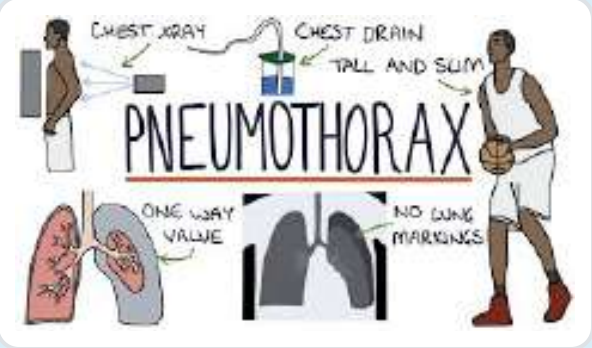

Pneumothorax

Zero To Finals - YouTube 👍 9 👎 1

Pneumothorax

Osmosis - YouTube 👍 6 👎 1

Needle Aspiration of Pneumothorax

NEJM - YouTube 10 6

Report broken media

Score: **15.3%**

1	✗
2	✗
3	✗
4	✗
5	✗
6	✗
7	✗
8	✗
9	✓
10	✓
11	✗
12	✗
13	✗
14	✓
15	✗
16	✓
17	✗
18	✗
19	✗
20	✗
21	✓
22	✓
23	✗
24	✗

25	✗
26	✗
27	✓
28	✗
29	✗
30	✓
31	✓
32	✗
33	✗
34	✗
35	✗
36	✗
37	✗
38	✗
39	✗
40	-
41	✗
42	✗
43	✗
44	✗
45	✓
46	✗
47	✗
48	✗
49	✗
50	✗
51	✗
52	✗
53	✗
54	✗
55	✗
56	✗
57	✗
58	✗
59	✗
60	✗

61	✗
62	✗
63	✗
64	✗
65	✗
66	✗
67	✓
68	✗
69	✓
70	✗
71	✗
72	✓
73	✗
74	✗
75	✗
76	✗
77	✗
78	-
79	✗
80	✗
81	✓
82	✗
83	✗
84	✗
85	✗
86	✗
87	✗
88	✗
89	✗
90	✓
91	✗
92	✗
93	✗
94	✗
95	✗
96	✗

97 ✗

98 ✗

99 ✗

100 ✗

All contents of this site are © 2024 Passmedicine Limited

A 35-year-old man presents with a chronic productive cough which has been affecting him for several years. He has no other past medical history apart from recurrent otitis media as a child. He takes no regular medications. He has never smoked and has no history of passive smoking and works as a solicitor. He has no pets at home and has no mould that he is aware of. On examination there is finger clubbing, he appears underweight, there are coarse late-inspiratory crepitations and a mild wheeze. Also, his heart sounds are louder on the right side, and his apex beat is also only present on the right. What further investigation would most likely confirm the diagnosis?

- Immunological testing for Aspergillus fumigatus specific IgE
- CFTR gene testing
- Sputum MCS
- Sputum Zeil-Neilsen staining and microscopy.
- Ciliary function tests

Submit answer

Reference ranges

Score: **17.8%**

1 ✕
2 ✕
3 ✕
4 ✕
5 ✕
6 ✕
7 ✕

8	✗
9	✓
10	✓
11	✗
12	✗
13	✗
14	✓
15	✗
16	✓
17	✗
18	✗
19	✗
20	✗
21	✓
22	✓
23	✗
24	✗
25	✗
26	✗
27	✓
28	✗
29	✗
30	✓
31	✓
32	✗
33	✗
34	✗
35	✗
36	✗
37	✗
38	✗
39	✗
40	-
41	✗
42	✗
43	✗

44	✗
45	✓
46	✗
47	✗
48	✗
49	✗
50	✗
51	✗
52	✗
53	✗
54	✗
55	✗
56	✗
57	✗
58	✗
59	✗
60	✗
61	✗
62	✗
63	✗
64	✗
65	✗
66	✗
67	✓
68	✗
69	✓
70	✗
71	✗
72	✓
73	✗
74	✗
75	-
76	-
77	-
78	-
79	-
80	-

81	-
82	-
83	-
84	-
85	-
86	-
87	-
88	-
89	-
90	-

All contents of this site are © 2024 Passmedicine Limited

Back to top

A 35-year-old man presents with a chronic productive cough which has been affecting him for several years. He has no other past medical history apart from recurrent otitis media as a child. He takes no regular medications. He has never smoked and has no history of passive smoking and works as a solicitor. He has no pets at home and has no mould that he is aware of. On examination there is finger clubbing, he appears underweight, there are coarse late-inspiratory crepitations and a mild wheeze. Also, his heart sounds are louder on the right side, and his apex beat is also only present on the right. What further investigation would most likely confirm the diagnosis?

- Immunological testing for Aspergillus fumigatus specific IgE — 4%
- CFTR gene testing — 28%
- Sputum MCS — 1%
- Sputum Zeil-Neilsen staining and microscopy. — 2%
- Ciliary function tests — 66%

The correct answer is ciliary function tests. This would confirm a diagnosis of primary ciliary dyskinesia. Ciliary function is commonly tested by the use of saccharin. Saccharin is placed 1cm behind the inferior turbinate and the test is positive if the patient does not taste sweetness within 20min. This is because if cilia work normally they will sweep the sweet saccharin inwards, allowing the patient to taste it.

Cilia line the upper respiratory tract, including the eustachian tubes, and moves normally in a coordinated fashion to help clear mucous, secretions and debris. In ciliary dyskinesis there is less movement or it is less coordinated. For this patient there is first a clear history and signs of bronchiectasis with chronic productive cough, bilateral late inspiratory crepitations and clubbing. But the history of otitis media, young patient and indications dextrocardia are all suggestive of primary ciliary dyskinesis. Cystic fibrosis is less likely due to the absence of gastrointestinal symptoms and signs, there is no travel history, heamoptysis or other factors to suggest TB, and there is no history of asthma making fungal infection and immunological response unlikely.

Discuss (3) Improve

Next question

Bronchiectasis: causes

Bronchiectasis describes a permanent dilatation of the airways secondary to chronic infection or inflammation. There are a wide variety of causes are listed below:

Causes
- post-infective: tuberculosis, measles, pertussis, pneumonia
- cystic fibrosis
- bronchial obstruction e.g. lung cancer/foreign body
- immune deficiency: selective IgA, hypogammaglobulinaemia
- allergic bronchopulmonary aspergillosis (ABPA)
- ciliary dyskinetic syndromes: Kartagener's syndrome, Young's syndrome
- yellow nail syndrome

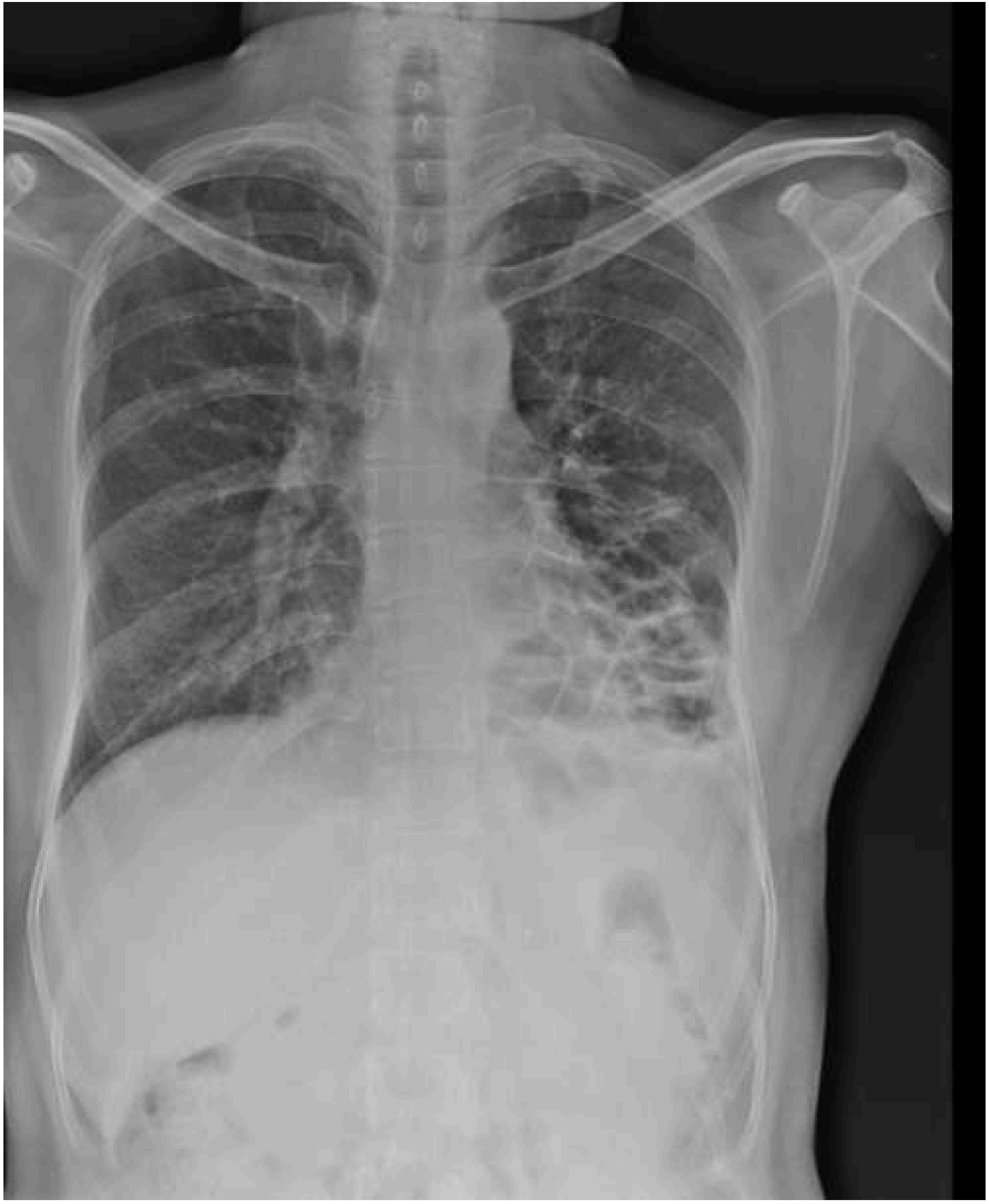

© Image used on license from Radiopaedia

Chest x-ray showing tramlines, most prominent in the left lower zone

© Image used on license from Radiopaedia

CT chest showing widespread tram-track and signet ring signs

123

Next question

Textbooks

High-yield textbook

Extended textbook

Links

British Thoracic Society 2 1

2018 Bronchiectasis guidelines

Suggest link

Report broken link

Media

Bronchiectasis - causes, pathophysiology, signs and symptoms, investigations and treatment

Armando Hasudungan - YouTube 3 0

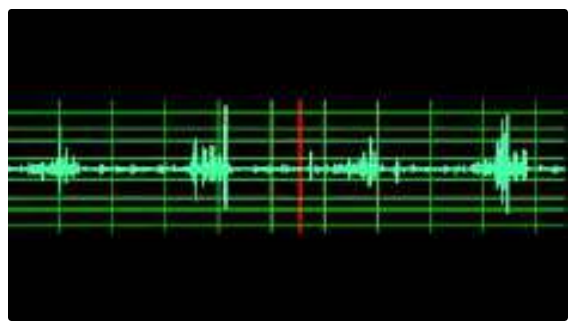

[Bronchiectasis crackles - REQUIRES HEADPHONES]

Thinklabs - YouTube

3 1

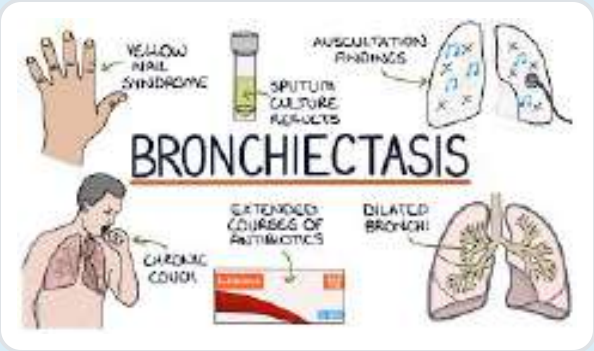

[Bronchiectasis]

Zero To Finals - YouTube

0 2

Report broken media

Score: **15.3%**

1	✗
2	✗
3	✗
4	✗
5	✗
6	✗
7	✗
8	✗
9	✓
10	✓
11	✗
12	✗
13	✗
14	✓
15	✗
16	✓
17	✗
18	✗
19	✗
20	✗
21	✓

22	✓
23	✗
24	✗
25	✗
26	✗
27	✓
28	✗
29	✗
30	✓
31	✓
32	✗
33	✗
34	✗
35	✗
36	✗
37	✗
38	✗
39	✗
40	-
41	✗
42	✗
43	✗
44	✗
45	✓
46	✗
47	✗
48	✗
49	✗
50	✗
51	✗
52	✗
53	✗
54	✗
55	✗
56	✗
57	✗

58	✗
59	✗
60	✗
61	✗
62	✗
63	✗
64	✗
65	✗
66	✗
67	✓
68	✗
69	✓
70	✗
71	✗
72	✓
73	✗
74	✗
75	✗
76	✗
77	✗
78	-
79	✗
80	✗
81	✓
82	✗
83	✗
84	✗
85	✗
86	✗
87	✗
88	✗
89	✗
90	✓
91	✗
92	✗
93	✗

94 ✕
95 ✕
96 ✕
97 ✕
98 ✕
99 ✕
100 ✕

All contents of this site are © 2024 Passmedicine Limited

A 32-year-old woman is reviewed in the respiratory clinic. She was admitted some 6 weeks earlier with acute severe asthma which required a period of ventilation. She is already treated with maximum dose salmeterol / fluticasone combination inhaler, montelukast and low dose oral corticosteroids, and a decision is made to start her on omalizumab.

Which of the following reflects the mode of action of omalizumab?

- Anti-IgE
- Anti-TNF
- Anti-IL6
- Anti-IL13
- Anti-IL22

Submit answer

Reference ranges

Score: **17.8%**

1	×
2	×
3	×
4	×
5	×
6	×
7	×
8	×

9	✓
10	✓
11	✗
12	✗
13	✗
14	✓
15	✗
16	✓
17	✗
18	✗
19	✗
20	✗
21	✓
22	✓
23	✗
24	✗
25	✗
26	✗
27	✓
28	✗
29	✗
30	✓
31	✓
32	✗
33	✗
34	✗
35	✗
36	✗
37	✗
38	✗
39	✗
40	-
41	✗
42	✗
43	✗
44	✗

45	✓
46	✗
47	✗
48	✗
49	✗
50	✗
51	✗
52	✗
53	✗
54	✗
55	✗
56	✗
57	✗
58	✗
59	✗
60	✗
61	✗
62	✗
63	✗
64	✗
65	✗
66	✗
67	✓
68	✗
69	✓
70	✗
71	✗
72	✓
73	✗
74	✗
75	-
76	-
77	-
78	-
79	-
80	-
81	-

82	-
83	-
84	-
85	-
86	-
87	-
88	-
89	-
90	-
91	-

All contents of this site are © 2024 Passmedicine Limited

A 32-year-old woman is reviewed in the respiratory clinic. She was admitted some 6 weeks earlier with acute severe asthma which required a period of ventilation. She is already treated with maximum dose salmeterol / fluticasone combination inhaler, montelukast and low dose oral corticosteroids, and a decision is made to start her on omalizumab.

Which of the following reflects the mode of action of omalizumab?

Anti-IgE	71%
Anti-TNF	6%
Anti-IL6	18%
Anti-IL13	3%
Anti-IL22	2%

Omalizumab is an anti-IgE monoclonal antibody recommended by NICE for patients with severe allergic asthma which is refractory to other treatments including multiple courses of oral corticosteroids per year. The manufacturer recommends that the drug is only used in patients who have a positive skin test to a recognised respiratory allergen.

Anti-TNF antibodies such as etanercept are used in the treatment of rheumatoid arthritis. Anti-IL6 antibodies such as tocilizumab are also used in the treatment of arthritis. Anti-IL13 and anti IL22 antibodies are both thought to target cytokines responsible for the development of asthma, and may play a role in combination therapy for the disease.

https://www.nice.org.uk/Guidance/TA278

Discuss (3) Improve

Next question

Asthma: management in adults

In 2024 NICE, the British Thoracic Society and SIGN produced joint guidelines on the management of asthma following many years of conflicting guidelines. The new guidelines represent a major step change in the management of asthma is both diagnosed and treated.

For many years patients with asthma were started on a short-acting beta-2 agonist (SABA) inhaler before 'stepping up' to a regular inhaled corticosteroid with a SABA as required. The new guidelines now advocate the use of combined inhalers (ICS + long-acting beta-2 agonist) as reliever therapy or regularly, depending on the severity of asthma. Given the prevalence of asthma, it is likely that doctors will have to deal with patients on 'conventional' asthma treatments for many years to come. The joint guidelines therefore include guidance on how to manage these patients if their current treatment is controlling their symptoms sufficiently.

Management of adult patients aged children aged ≥ 12 years with newly diagnosed asthma

Step 1 NICE

- a low-dose inhaled corticosteroid (ICS)/formoterol combination inhaler to be taken as needed for symptom relief
  - this is termed anti-inflammatory reliever (AIR) therapy
- if the patient presents highly symptomatic (for example, regular nocturnal waking) or with a severe exacerbation:
  - start treatment with low-dose MART (maintenance and reliever therapy, see below)
  - treat the acute symptoms as appropriate (e.g. a course of oral corticosteroids may be indicated)

Step 2 NICE

- a low-dose MART
  - MART describes using an inhaled corticosteroid (ICS)/formoterol combination inhaler for daily maintenance therapy and the relief of symptoms as needed, i.e. regularly and as required

Step 3

- a moderate-dose MART

Step 4

- check the fractional exhaled nitric oxide (FeNO) level if available, and the blood eosinophil count NICE
  - if either of these is raised, refer to a specialist in asthma care
  - if neither FeNO nor eosinophil count is raised, consider a trial of either a leukotriene receptor antagonist (LTRA) or a long-acting muscarinic receptor antagonist (LAMA) used in addition to moderate-dose MART

- if control has not improved, stop the LTRA or LAMA and start a trial of the alternative medicine (LTRA or LAMA)

Step 5

- refer people to a specialist in asthma care when asthma is not controlled despite treatment with moderate-dose MART, and trials of an LTRA and a LAMA



Transferring people aged 12 and over from other treatment pathways

There will be many people whose asthma was managed according to the previous guidelines that present with uncontrolled asthmatic symptoms. The guidelines give advice on how these people should be switched: NICE

Existing asthma treatment	New asthma treatment
SABA as required only	Low-dose ICS/formoterol combination inhaler used as needed (as-needed AIR therapy)
SABA as required + regular low-dose ICS SABA as required + regular low-dose ICS/LABA SABA as required + regular low-dose ICS + LTRA SABA as required + regular low-dose ICS/LABA + LTRA	Regular low-dose regular ICS/formoterol combination inhaler (MART therapy)
SABA as required + regular moderate-dose ICS SABA as required + regular moderate-dose ICS/LABA SABA as required + regular moderate-dose ICS + LTRA or LAMA SABA as required + regular moderate-dose ICS/LABA + LTRA or LAMA	Regular moderate-dose MART therapy

Existing asthma treatment	New asthma treatment
Treatment regime containing a high-dose ICS	Refer to a respiratory specialist

AI + Q 123

Next question >

B I A

Textbooks

High-yield textbook

Extended textbook

Links

NICE 0 0

2024 Asthma: diagnosis, monitoring and chronic asthma management (BTS, NICE, SIGN)

Suggest link Report broken link

Media

Asthma

MedFlix - YouTube 2 0

Inhaler and Nebuliser Explanation

Oxford Medical Education - YouTube 5 1

Report broken media

Score: **15.3%**

1	✗
2	✗
3	✗
4	✗
5	✗
6	✗
7	✗
8	✗
9	✓
10	✓
11	✗
12	✗
13	✗
14	✓
15	✗
16	✓
17	✗
18	✗
19	✗
20	✗
21	✓
22	✓
23	✗
24	✗

25	✗
26	✗
27	✓
28	✗
29	✗
30	✓
31	✓
32	✗
33	✗
34	✗
35	✗
36	✗
37	✗
38	✗
39	✗
40	-
41	✗
42	✗
43	✗
44	✗
45	✓
46	✗
47	✗
48	✗
49	✗
50	✗
51	✗
52	✗
53	✗
54	✗
55	✗
56	✗
57	✗
58	✗
59	✗
60	✗

61	✗
62	✗
63	✗
64	✗
65	✗
66	✗
67	✓
68	✗
69	✓
70	✗
71	✗
72	✓
73	✗
74	✗
75	✗
76	✗
77	✗
78	-
79	✗
80	✗
81	✓
82	✗
83	✗
84	✗
85	✗
86	✗
87	✗
88	✗
89	✗
90	✓
91	✗
92	✗
93	✗
94	✗
95	✗
96	✗

97 ✕
98 ✕
99 ✕
100 ✕

All contents of this site are © 2024 Passmedicine Limited

Back to top

A 51-year-old lady is admitted to the Medical Admissions Unit with a 2-week history of fever, breathlessness, lethargy and fatigue.

She has a history of poorly controlled asthma which has caused her to attend the Emergency Department five times over the past 2 years. She was reviewed by the respiratory team during her last admission and started on reducing dose oral prednisolone. However, she was unable to reduce her dose below 10mg per day due to recurrent breathlessness and wheeze.

She was reviewed again in the Respiratory Clinic 4 months ago and started on montelukast 10mg per day as a steroid-sparing therapy. Her prednisolone was subsequently reduced to 5mg per day and she reports that she had been well since then.

Her past medical history is otherwise remarkable for sinusitis and nasal polyposis. She has had several surgeries for the latter. Her current medications include Seretide 500/50 1 puff twice daily, montelukast 10mg once daily, prednisolone 5mg once daily and salbutamol via MDI as required. She is allergic to aspirin.

On examination, her temperature is 37.6ºC, her pulse is 98bpm and her blood pressure is 164/91mmHg. Her respiratory rate is 22/min and her oxygen saturations are 93% breathing room air. Her JVP is elevated at 5cm. Auscultation of the chest reveals diffuse polyphonic wheeze and bibasal crackles extending to the mid-zones. There is mild ankle oedema. Her abdomen is soft and non-tender.

Her initial investigations are as follows:

Hb	112 g/l	Na^+	136 mmol/l
Platelets	215 * 10^9/l	K^+	5.9 mmol/l
WBC	14.2 * 10^9/l	Urea	22.3 mmol/l
Neuts	8.4 * 10^9/l	Creatinine	484 µmol/l
Lymphs	2.1 * 10^9/l	CRP	107 mg/l
Eosin	3.4 * 10^9/l		

Urine dipstick	Blood +++ protein ++

What would be the most likely finding on renal biopsy?

- Mesangial hypercellularity
- Pauci-immune crescentic glomerulonephritis
- Podocyte fusion
- Thickened capillary walls with subepithelial deposits
- Diffuse proliferative glomerulonephritis

Submit answer

Reference ranges

Score: **17.8%**

1	✗
2	✗
3	✗
4	✗
5	✗
6	✗
7	✗
8	✗
9	✓
10	✓
11	✗
12	✗
13	✗
14	✓
15	✗
16	✓
17	✗
18	✗

19	✗
20	✗
21	✓
22	✓
23	✗
24	✗
25	✗
26	✗
27	✓
28	✗
29	✗
30	✓
31	✓
32	✗
33	✗
34	✗
35	✗
36	✗
37	✗
38	✗
39	✗
40	-
41	✗
42	✗
43	✗
44	✗
45	✓
46	✗
47	✗
48	✗
49	✗
50	✗
51	✗
52	✗
53	✗
54	✗

55	✗
56	✗
57	✗
58	✗
59	✗
60	✗
61	✗
62	✗
63	✗
64	✗
65	✗
66	✗
67	✓
68	✗
69	✓
70	✗
71	✗
72	✓
73	✗
74	✗
75	-
76	-
77	-
78	-
79	-
80	-
81	-
82	-
83	-
84	-
85	-
86	-
87	-
88	-
89	-
90	-
91	-
92	-

All contents of this site are © 2024 Passmedicine Limited

A 51-year-old lady is admitted to the Medical Admissions Unit with a 2-week history of fever, breathlessness, lethargy and fatigue.

She has a history of poorly controlled asthma which has caused her to attend the Emergency Department five times over the past 2 years. She was reviewed by the respiratory team during her last admission and started on reducing dose oral prednisolone. However, she was unable to reduce her dose below 10mg per day due to recurrent breathlessness and wheeze.

She was reviewed again in the Respiratory Clinic 4 months ago and started on montelukast 10mg per day as a steroid-sparing therapy. Her prednisolone was subsequently reduced to 5mg per day and she reports that she had been well since then.

Her past medical history is otherwise remarkable for sinusitis and nasal polyposis. She has had several surgeries for the latter. Her current medications include Seretide 500/50 1 puff twice daily, montelukast 10mg once daily, prednisolone 5mg once daily and salbutamol via MDI as required. She is allergic to aspirin.

On examination, her temperature is 37.6ºC, her pulse is 98bpm and her blood pressure is 164/91mmHg. Her respiratory rate is 22/min and her oxygen saturations are 93% breathing room air. Her JVP is elevated at 5cm. Auscultation of the chest reveals diffuse polyphonic wheeze and bibasal crackles extending to the mid-zones. There is mild ankle oedema. Her abdomen is soft and non-tender.

Her initial investigations are as follows:

Hb	112 g/l	Na^+	136 mmol/l
Platelets	215 * 10^9/l	K^+	5.9 mmol/l
WBC	14.2 * 10^9/l	Urea	22.3 mmol/l
Neuts	8.4 * 10^9/l	Creatinine	484 µmol/l
Lymphs	2.1 * 10^9/l	CRP	107 mg/l
Eosin	3.4 * 10^9/l		

Urine dipstick	Blood +++ protein ++

What would be the most likely finding on renal biopsy?

- Mesangial hypercellularity 5%
- Pauci-immune crescentic glomerulonephritis 71%
- Podocyte fusion 2%
- Thickened capillary walls with subepithelial deposits 10%
- Diffuse proliferative glomerulonephritis 12%

The patient has presented with worsening asthma, prominent peripheral blood eosinophilia, and acute kidney injury. This, in combination with the history of paranasal sinusitis, points towards a diagnosis of eosinophilic granulomatosis with polyangiitis (EGPA) or Churg-Strauss syndrome.

EGPA is a rare systemic necrotising vasculitis that affects small to medium-sized blood vessels. The natural history of the disease progresses through three distinct phases: a prodromal phase, characterised by asthma and paranasal sinusitis; an eosinophilic phase, with prominent peripheral blood eosinophilia and eosinophilic infiltration of various bodily tissues, and a final vasculitic phase. Vasculitic phenomena include skin rashes, peripheral neuropathy, and renal involvement; the latter is most commonly due to rapidly progressive glomerulonephritis (RPGN). RPGN is characterised histologically by the formation of epithelial crescents in the majority of glomeruli.

There is an association between the introduction of leukotriene receptor antagonists (LTRAs) and the onset of EGPA. The reason for this is unclear and various theories have been proposed. It has been suggested that some patients with difficult-to-control asthma may actually have a subclinical form of EGPA that is suppressed by repeated courses of corticosteroids. Instituting therapy with LTRAs allows tapering of corticosteroids and precipitates clinical disease.

The patient in the vignette may have had aspirin-sensitive asthma, in the which LTRAs have a prominent therapeutic role. There may also be a direct link between aspirin-sensitive asthma and EGPA.

Discuss (3) Improve

Next question

Eosinophilic granulomatosis with polyangiitis (Churg-Strauss syndrome)

Eosinophilic granulomatosis with polyangiitis (EGPA) is now the preferred term for **Churg-Strauss syndrome**. It is an ANCA associated small-medium vessel vasculitis.

Features

- asthma
- blood eosinophilia (e.g. > 10%)
- paranasal sinusitis
- mononeuritis multiplex
- pANCA positive in 60%

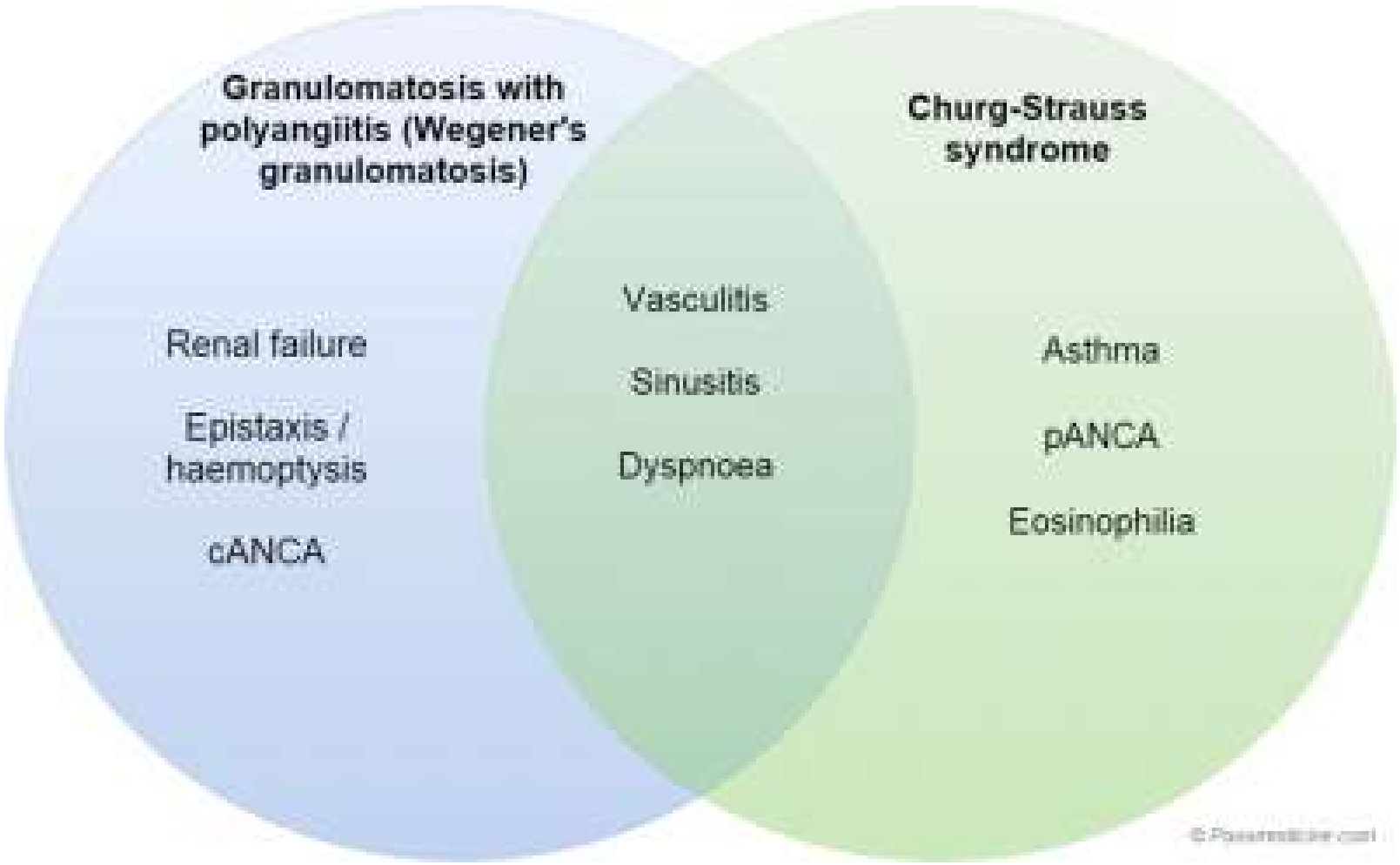

Comparison of granulomatosis with polyangiitis and Churg-Strauss syndrome

Leukotriene receptor antagonists may precipitate the disease.

123

Next question

Textbooks

High-yield textbook

Extended textbook

Media

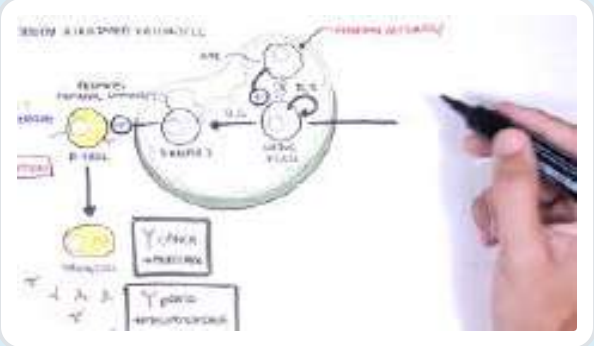

ANCA (Anti-Neutrophil Cytoplasmic Antibody) Associated Vasculitis - Causes, Pathophysiology, Types

Armando Hasudungan - YouTube

👍 3 👎 3

Report broken media

Score: **15.3%**

1	✗
2	✗
3	✗
4	✗
5	✗
6	✗
7	✗
8	✗
9	✓
10	✓
11	✗
12	✗
13	✗
14	✓
15	✗
16	✓
17	✗
18	✗
19	✗

20	✗
21	✓
22	✓
23	✗
24	✗
25	✗
26	✗
27	✓
28	✗
29	✗
30	✓
31	✓
32	✗
33	✗
34	✗
35	✗
36	✗
37	✗
38	✗
39	✗
40	-
41	✗
42	✗
43	✗
44	✗
45	✓
46	✗
47	✗
48	✗
49	✗
50	✗
51	✗
52	✗
53	✗
54	✗
55	✗

56	✗
57	✗
58	✗
59	✗
60	✗
61	✗
62	✗
63	✗
64	✗
65	✗
66	✗
67	✓
68	✗
69	✓
70	✗
71	✗
72	✓
73	✗
74	✗
75	✗
76	✗
77	✗
78	-
79	✗
80	✗
81	✓
82	✗
83	✗
84	✗
85	✗
86	✗
87	✗
88	✗
89	✗
90	✓
91	✗

92 ✕
93 ✕
94 ✕
95 ✕
96 ✕
97 ✕
98 ✕
99 ✕
100 ✕

All contents of this site are © 2024 Passmedicine Limited

Back to top

A 25-year-old man presents to the emergency department with a one-week history of cough, fever and shortness of breath. He has no past medical history and has never previously attended the hospital. He is orientated and responds to questioning appropriately. His respiratory rate is 14 breaths per minute, oxygen saturations are 98% on room air and his blood pressure is 115/65 mmHg.

He reports that he had a previous reaction to pivmecillinam aged 20, with the development of a widespread raised itchy rash.

Blood tests are taken with the following results:

Hb	123 g/L	(135-180)
Platelets	478 * 10^9/L	(150 - 400)
WBC	17 * 10^9/L	(4.0 - 11.0)
Na^+	137 mmol/L	(135 - 145)
K^+	4.2 mmol/L	(3.5 - 5.0)
Urea	4.5 mmol/L	(2.0 - 7.0)
Creatinine	85 µmol/L	(55 - 120)

A chest x-ray is taken, as shown below:

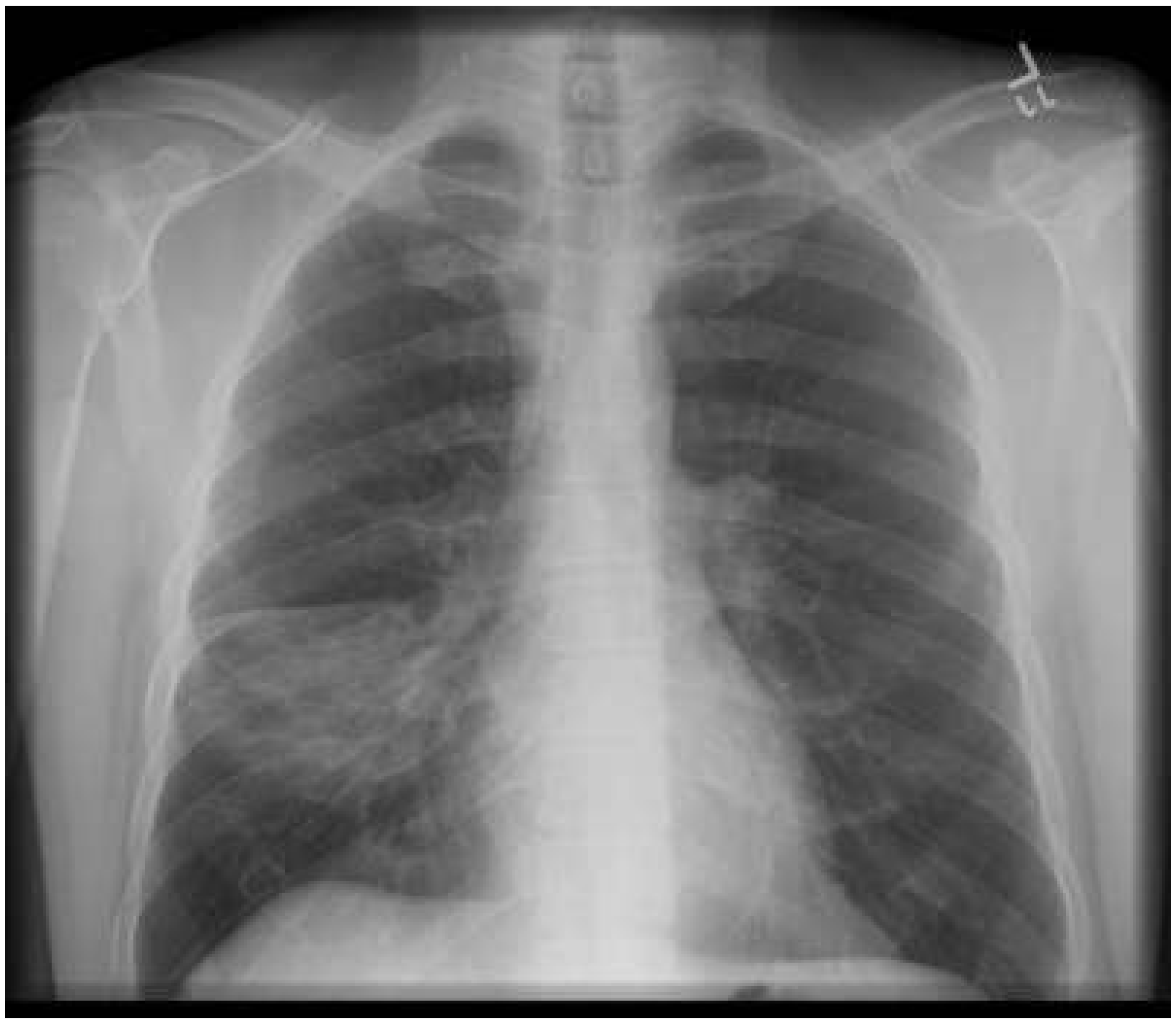

© Image used on license from Radiopaedia

What is the most appropriate management for this patient?

- Admit for IV amoxicillin and clarithromycin ×
- Admit for IV co-trimoxazole ×
- Admit for respiratory review ×
- Discharge with oral doxycycline ×
- Discharge with oral doxycycline and clarithromycin ×

Submit answer

Reference ranges

Score: **17.8%**

1	✗
2	✗
3	✗
4	✗
5	✗
6	✗
7	✗
8	✗
9	✓
10	✓
11	✗
12	✗
13	✗
14	✓
15	✗

16	✓
17	✗
18	✗
19	✗
20	✗
21	✓
22	✓
23	✗
24	✗
25	✗
26	✗
27	✓
28	✗
29	✗
30	✓
31	✓
32	✗
33	✗
34	✗
35	✗
36	✗
37	✗
38	✗
39	✗
40	-
41	✗
42	✗
43	✗
44	✗
45	✓
46	✗
47	✗
48	✗
49	✗
50	✗
51	✗

52	✗
53	✗
54	✗
55	✗
56	✗
57	✗
58	✗
59	✗
60	✗
61	✗
62	✗
63	✗
64	✗
65	✗
66	✗
67	✓
68	✗
69	✓
70	✗
71	✗
72	✓
73	✗
74	✗
75	-
76	-
77	-
78	-
79	-
80	-
81	-
82	-
83	-
84	-
85	-
86	-
87	-
88	-

89 -
90 -
91 -
92 -
93 -

All contents of this site are © 2024 Passmedicine Limited

A 25-year-old man presents to the emergency department with a one-week history of cough, fever and shortness of breath. He has no past medical history and has never previously attended the hospital. He is orientated and responds to questioning appropriately. His respiratory rate is 14 breaths per minute, oxygen saturations are 98% on room air and his blood pressure is 115/65 mmHg.

He reports that he had a previous reaction to pivmecillinam aged 20, with the development of a widespread raised itchy rash.

Blood tests are taken with the following results:

Hb	123 g/L	(135-180)
Platelets	478 * 10^9/L	(150 - 400)
WBC	17 * 10^9/L	(4.0 - 11.0)
Na^+	137 mmol/L	(135 - 145)
K^+	4.2 mmol/L	(3.5 - 5.0)
Urea	4.5 mmol/L	(2.0 - 7.0)
Creatinine	85 µmol/L	(55 - 120)

A chest x-ray is taken, as shown below:

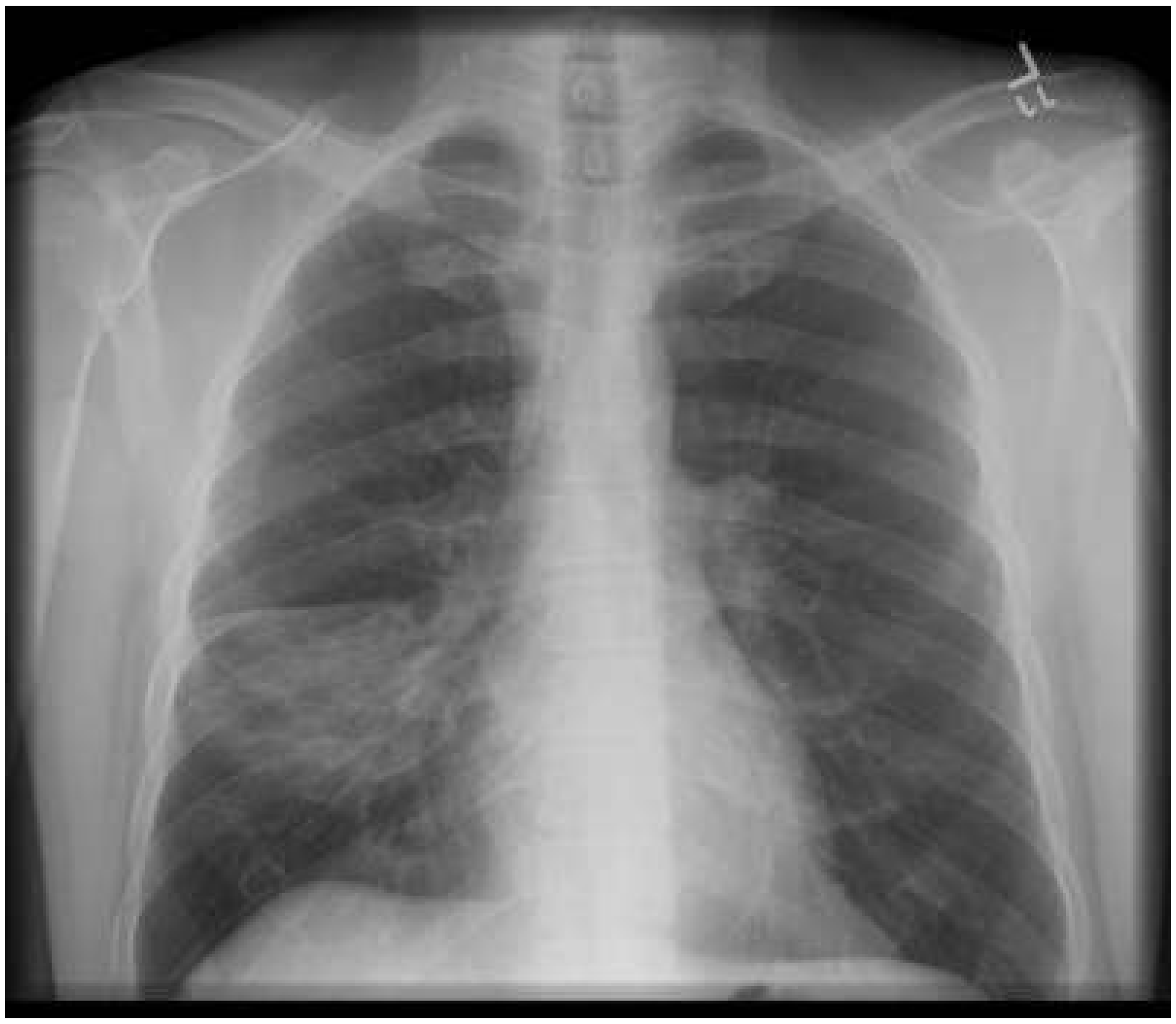

© Image used on license from Radiopaedia

What is the most appropriate management for this patient?

Option	Responses
Admit for IV amoxicillin and clarithromycin	5%
Admit for IV co-trimoxazole	3%
Admit for respiratory review	2%
Discharge with oral doxycycline	62%
Discharge with oral doxycycline and clarithromycin	28%

The chest x-ray shows an area of dense consolidation in the right mid-zone, typical of pneumonia, which is community-acquired in this case. The patient scores 0 on the CURB-65 score, which means that he is in a low-risk group with a 0.6% 30-day mortality, and can be managed as an outpatient with oral antibiotics given that there are no other concerning features.

The patient has had a previous urticarial reaction to pivmecillinam (which is a type of penicillin usually given for urinary tract infections), suggesting he is likely to have a type 1 allergic reaction to penicillin, and should not receive penicillin in the future.

Discharge with oral doxycycline is correct. NICE recommends that patients with penicillin allergies should be treated with either a macrolide (clarithromycin or azithromycin) or doxycycline.

Admit for IV amoxicillin and clarithromycin is incorrect. A patient might be admitted if they scored 2 or more on the CURB-65 score, or if there were other features giving cause for concern, which is not the case in this scenario. The patient should also not be given amoxicillin, which is a type of penicillin.

Admit for IV co-trimoxazole is incorrect. This antibiotic choice would be safe for this patient as it is not penicillin based but, as above, the patient does not require hospital admission. Co-trimoxazole is sometimes used for hospital-acquired pneumonia as it has a broader spectrum of activity but is not routinely used for community-acquired pneumonia.

Admit for respiratory review is incorrect. Although there is a significant area of consolidation on the chest x-ray, the patient is not compromised and does not require specialist respiratory input at this point. He would require a follow-up chest x-ray at 4-6 weeks to ensure that the consolidation has resolved.

Discharge with oral doxycycline and clarithromycin is incorrect. It would be reasonable to give the patient doxycycline alone, as per NICE guidelines for patients with penicillin allergies.

Clarithromycin is often added to provide cover for atypical organisms, such as *Legionella pneumophila* and *Mycoplasma pneumoniae* which are not treated by penicillin-based antibiotics. However, NICE recommends that atypical cover should only be prescribed for patients with moderate or severe community-acquired pneumonia, so it is not required in this patient.

Discuss | Improve

Next question

Pneumonia: assessment and management

Primary care setting

NICE recommends that patients should initially be assessed in primary care using the CRB65 criteria:

Criterion	Marker
C	Confusion (abbreviated mental test score <= 8/10)
R	Respiration rate >= 30/min
B	Blood pressure: systolic <= 90 mmHg and/or diastolic <= 60 mmHg
65	Aged >= 65 years

Patients are stratified for risk of death as follows:

- 0: low risk (less than 1% mortality risk)
  - NICE recommend that treatment at home should be considered (alongside clinical judgement)
- 1 or 2: intermediate risk (1-10% mortality risk)
  - NICE recommend that ' hospital assessment should be considered (particularly for people with a score of 2)'
- 3 or 4: high risk (more than 10% mortality risk)
  - NICE recommend urgent admission to hospital

NICE also mention point-of-care CRP test. This is currently not widely available but they make the following recommendation with reference to the use of antibiotic therapy:

- CRP < 20 mg/L - do not routinely offer antibiotic therapy

- CRP 20 - 100 mg/L - consider a delayed antibiotic prescription
- CRP > 100 mg/L - offer antibiotic therapy

Secondary care setting

Note that in hospital, once blood tests are available the CURB65, rather than the CRB65, can be used. This adds an extra criterion of urea > 7 mmol/L:

Criterion	Marker
C	Confusion (abbreviated mental test score <= 8/10)
U	urea > 7 mmol/L
R	Respiration rate >= 30/min
B	Blood pressure: systolic <= 90 mmHg and/or diastolic <= 60 mmHg
65	Aged >= 65 years

NICE recommend, in conjunction with clinical judgement:

- consider home-based care for patients with a CURB65 score of 0 or 1 - low risk (less than 3% mortality risk)
- consider hospital-based care for patients with a CURB65 score of 2 or more - intermediate risk (3-15% mortality risk)
- consider intensive care assessment for patients with a CURB65 score of 3 or more - high risk (more than 15% mortality risk)

Investigations

- chest x-ray
- in intermediate or high-risk patients NICE recommend blood and sputum cultures, pneumococcal and legionella urinary antigen tests
- CRP monitoring is recommend for admitted patients to help determine response to treatment

Management of low-severity community acquired pneumonia

- amoxicillin is first-line
- if penicillin allergic then use a macrolide or tetracycline
- NICE now recommend a 5 day course of antibiotics for patients with low severity community acquired pneumonia

Management of moderate and high-severity community acquired pneumonia

- dual antibiotic therapy is recommended with amoxicillin and a macrolide
- a 7-10 day course is recommended
- NICE recommend considering a beta-lactamase stable penicillin such as co-amoxiclav, ceftriaxone or piperacillin with tazobactam and a macrolide in high-severity community acquired pneumonia

Discharge criteria and advice post-discharge

NICE recommend that patients are not routinely discharged if in the past 24 hours they have had 2 or more of the following findings:

- temperature higher than 37.5°C
- respiratory rate 24 breaths per minute or more
- heart rate over 100 beats per minute
- systolic blood pressure 90 mmHg or less
- oxygen saturation under 90% on room air
- abnormal mental status
- inability to eat without assistance.

They also recommend delaying discharge if the temperature is higher than 37.5°C.

NICE recommend that the following information is given to patients with pneumonia in terms of how quickly their symptoms should symptoms should resolve:

Time	Progress
1 week	Fever should have resolved
4 weeks	Chest pain and sputum production should have substantially reduced
6 weeks	Cough and breathlessness should have substantially reduced
3 months	Most symptoms should have resolved but fatigue may still be present
6 months	Most people will feel back to normal.

All cases of pneumonia should have a repeat chest X-ray at 6 weeks after clinical resolution to ensure that the consolidation has resolved and there is no underlying secondary abnormalities (e.g. a lung tumour).

123

Next question

Textbooks

High-yield textbook

Extended textbook

Links

NICE 16 11

2014 Pneumonia in adults: diagnosis and management

Clinical Knowledge Summaries 14 7

Community-acquired pneumonia

MDCalc 17 5

CURB-65 scoring tool

Suggest link

Report broken link

Media

Pneumonia

Osmosis - YouTube 4 0

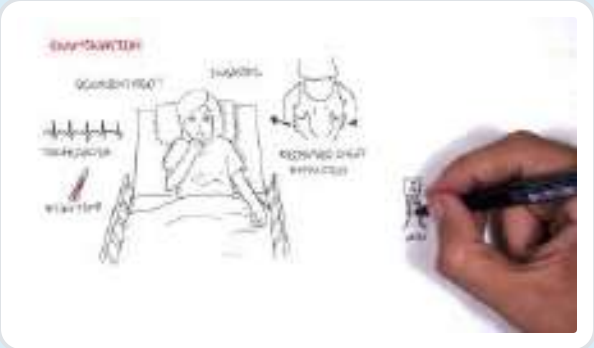

Community Acquired Pneumonia

Armando Hasudungan - YouTube 3 0

Report broken media

Score: **15.3%**

1	✗
2	✗
3	✗
4	✗
5	✗
6	✗
7	✗
8	✗
9	✓
10	✓
11	✗
12	✗
13	✗
14	✓
15	✗
16	✓
17	✗
18	✗
19	✗
20	✗
21	✓
22	✓

23	✗
24	✗
25	✗
26	✗
27	✓
28	✗
29	✗
30	✓
31	✓
32	✗
33	✗
34	✗
35	✗
36	✗
37	✗
38	✗
39	✗
40	-
41	✗
42	✗
43	✗
44	✗
45	✓
46	✗
47	✗
48	✗
49	✗
50	✗
51	✗
52	✗
53	✗
54	✗
55	✗
56	✗
57	✗
58	✗

59	✗
60	✗
61	✗
62	✗
63	✗
64	✗
65	✗
66	✗
67	✓
68	✗
69	✓
70	✗
71	✗
72	✓
73	✗
74	✗
75	✗
76	✗
77	✗
78	-
79	✗
80	✗
81	✓
82	✗
83	✗
84	✗
85	✗
86	✗
87	✗
88	✗
89	✗
90	✓
91	✗
92	✗
93	✗
94	✗

95	✕
96	✕
97	✕
98	✕
99	✕
100	✕

All contents of this site are © 2024 Passmedicine Limited

You are the admitting medical registrar and receive the following referral from your emergency department colleague.

A 30-year-old woman with asthma has presented with three days of increasing wheeze, dyspnea, productive cough and fevers. You are informed there is a leukocytosis and consolidation on the chest x-ray. The emergency department team have commenced antibiotics and referred for inpatient admission.

You obtain a further history. This patient was diagnosed with asthma in childhood but as an adult, she rarely required any use of her salbutamol inhaler and did not require follow up with a respiratory physician or general practitioner. However, over the last 18 months, she has been experiencing increasing wheezing and cough. Initially, this was a dry cough but has now become productive of brown sputum. There is no history of haemoptysis. This has been associated with malaise and weight loss. She was admitted to hospital with an asthma exacerbation two weeks ago and was discharged on a short course of prednisolone and started on a salmeterol-fluticasone combination inhaler. Following discharge, she initially felt improved but feels her symptoms have returned over the last few days. She denies missing any doses of her inhaled medication and uses a spacer. There is no history of chest pain or travel. She is a lifelong non-smoker and works full time as a computer programmer.

Past medical history includes allergic rhinitis, eczema and endometriosis.

Examination revealed a thin woman, with respiratory rate of 22/min, oxygen saturation 95% on air, blood pressure 100/60 mmHg, heart 90/min and temperature of 37.8ºC. There was diffuse expiratory wheeze and reduced breath sounds in the right upper zone of the anterior chest. Heart sounds were dual with no murmurs. The jugular venous pressure was not elevated. There was palpable cervical lymphadenopathy and no clubbing. Calves were soft, non-tender and there was no pedal oedema.

Hb	140 g/l	Na^+	138 mmol/l
Platelets	380 * 10^9/l	K^+	3.6 mmol/l
WBC	11 * 10^9/l	Urea	5 mmol/l
Neuts	9 * 10^9/l	Creatinine	70 µmol/l
Lymphs	1 * 10^9/l	CRP	20 mg/l
Eosin	1 * 10^9/l		

A chest x-ray shows a homogeneous triangular shaped opacity extending from the mediastinum

towards the right upper zone.

Which of the following are you most likely to find this patient?

- Elevated serum IgE levels
- Upper lobe bronchiectasis on high resolution computed tomography of the thorax
- A positive urinary *Streptococcus pneumoniae* antigen
- Sputum analysis staining positive for acid-fast bacilli
- No change in symptoms with a repeat course of prednisolone

Submit answer

Reference ranges

Score: **17.8%**

1	✗
2	✗
3	✗
4	✗
5	✗
6	✗
7	✗
8	✗
9	✓
10	✓
11	✗
12	✗
13	✗
14	✓

15	✗
16	✓
17	✗
18	✗
19	✗
20	✗
21	✓
22	✓
23	✗
24	✗
25	✗
26	✗
27	✓
28	✗
29	✗
30	✓
31	✓
32	✗
33	✗
34	✗
35	✗
36	✗
37	✗
38	✗
39	✗
40	-
41	✗
42	✗
43	✗
44	✗
45	✓
46	✗
47	✗
48	✗
49	✗
50	✗

51	✗
52	✗
53	✗
54	✗
55	✗
56	✗
57	✗
58	✗
59	✗
60	✗
61	✗
62	✗
63	✗
64	✗
65	✗
66	✗
67	✓
68	✗
69	✓
70	✗
71	✗
72	✓
73	✗
74	✗
75	-
76	-
77	-
78	-
79	-
80	-
81	-
82	-
83	-
84	-
85	-
86	-
87	-

88 -
89 -
90 -
91 -
92 -
93 -
94 -

All contents of this site are © 2024 Passmedicine Limited

You are the admitting medical registrar and receive the following referral from your emergency department colleague.

A 30-year-old woman with asthma has presented with three days of increasing wheeze, dyspnea, productive cough and fevers. You are informed there is a leukocytosis and consolidation on the chest x-ray. The emergency department team have commenced antibiotics and referred for inpatient admission.

You obtain a further history. This patient was diagnosed with asthma in childhood but as an adult, she rarely required any use of her salbutamol inhaler and did not require follow up with a respiratory physician or general practitioner. However, over the last 18 months, she has been experiencing increasing wheezing and cough. Initially, this was a dry cough but has now become productive of brown sputum. There is no history of haemoptysis. This has been associated with malaise and weight loss. She was admitted to hospital with an asthma exacerbation two weeks ago and was discharged on a short course of prednisolone and started on a salmeterol-fluticasone combination inhaler. Following discharge, she initially felt improved but feels her symptoms have returned over the last few days. She denies missing any doses of her inhaled medication and uses a spacer. There is no history of chest pain or travel. She is a lifelong non-smoker and works full time as a computer programmer.

Past medical history includes allergic rhinitis, eczema and endometriosis.

Examination revealed a thin woman, with respiratory rate of 22/min, oxygen saturation 95% on air, blood pressure 100/60 mmHg, heart 90/min and temperature of 37.8ºC. There was diffuse expiratory wheeze and reduced breath sounds in the right upper zone of the anterior chest. Heart sounds were dual with no murmurs. The jugular venous pressure was not elevated. There was palpable cervical lymphadenopathy and no clubbing. Calves were soft, non-tender and there was no pedal oedema.

Hb	140 g/l	Na^+	138 mmol/l
Platelets	380 * 10^9/l	K^+	3.6 mmol/l
WBC	11 * 10^9/l	Urea	5 mmol/l
Neuts	9 * 10^9/l	Creatinine	70 µmol/l
Lymphs	1 * 10^9/l	CRP	20 mg/l
Eosin	1 * 10^9/l		

A chest x-ray shows a homogeneous triangular shaped opacity extending from the mediastinum

towards the right upper zone.

Which of the following are you most likely to find this patient?

Elevated serum IgE levels	64%
Upper lobe bronchiectasis on high resolution computed tomography of the thorax	17%
A positive urinary *Streptococcus pneumoniae* antigen	4%
Sputum analysis staining positive for acid-fast bacilli	9%
No change in symptoms with a repeat course of prednisolone	6%

Consider allergic bronchopulmonary aspergillosis in asthma patients who have developed difficult to control symptoms and/or have become dependent on oral steroids

Important for me Less important

This patient has allergic bronchopulmonary Aspergillosis (ABPA) as evidenced by the development of inadequately controlled asthma, cough productive of brown sputum, malaise, weight loss and a homogeneous opacity on chest x-ray. Typically there is a serum eosinophilia but given the recent course of prednisolone, the eosinophil count may still be suppressed.

ABPA is a chronic hypersensitivity reaction that occurs in response to colonization of the lower airways with Aspergillus species. It occurs most commonly in patients with atopic asthma or cystic fibrosis (CF). The resulting inflammation can lead to the destruction of pulmonary parenchyma and bronchiectasis.

A diagnosis of ABPA is supported by:

- Symptoms as described above
- Serum eosinophilia in steroid naÃ¯ve patients and/or no history of recent steroid use
- Elevated total serum IgE level (>1000 iU/ml), positive serum Aspergillus precipitins (IgM, IgG and IgE antibodies to Aspergillus species)
- Sputum showing elevated eosinophil count and/or fungal mycelia with healthy cytoplasm (cf. dead mycelia devoid of cytoplasm seen in patients with Aspergilloma)
- Immediate skin test reactivity to Aspergillus antigens
- A massive homogeneous shadow without fissure displacement is the most common abnormality seen on a chest radiograph with ABPA
- The bronchiectasis seen in ABPA is typically central

Management is usually with prednisolone +/- azole class antifungals (e.g. Itra or Voriconazole)

Option A - the correct answer

Option B - central bronchiectasis is typically seen, rather than lobe specific

Option C - community acquired pneumonia is a valid differential but the history and investigations are in favour of ABPA. If there was a pneumonic process that has such a dense consolidation to give homogeneous opacity on chest x-ray, you would expect worse hypoxia and respiratory distress as seen in this patient.

Option D - *Mycobacterium tuberculosis* infection is unlikely given the absence of risk factors and the history/investigations makes the pre-test probability of ABPA much higher than *Mycobacterium tuberculosis*

Option E - prednisolone is the first line treatment for ABPA and patients may require multiple and/or prolonged courses. Azole anti-fungal therapy may also be added in order to decrease steroid burden and/or if there is a poor response to corticosteroid therapy.

Discuss (3) | Improve

Next question

Allergic bronchopulmonary aspergillosis

Allergic bronchopulmonary aspergillosis results from an allergy to *Aspergillus spores*. In the exam questions often give a history of bronchiectasis and eosinophilia.

Features

- bronchoconstriction: wheeze, cough, dyspnoea. Patients may have a previous label of asthma
- bronchiectasis (proximal)

Investigations

- eosinophilia
- flitting CXR changes
- positive radioallergosorbent (RAST) test to Aspergillus
- positive IgG precipitins (not as positive as in aspergilloma)
- raised IgE

Management

- oral glucocorticoids

- itraconazole is sometimes introduced as a second-line agent

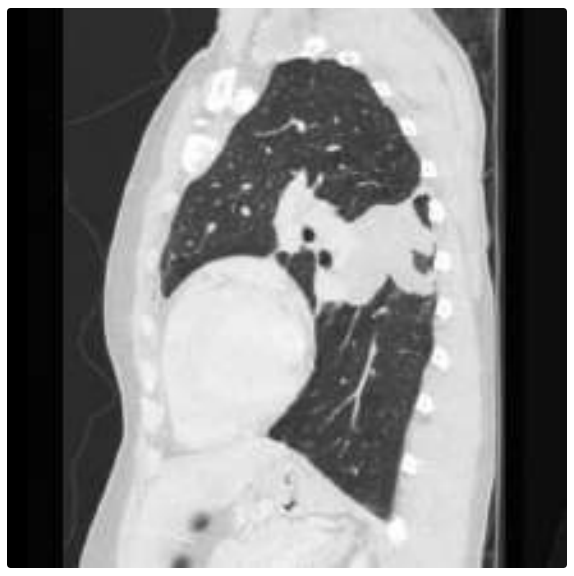

AI + Q 123

Next question

Textbooks

High-yield textbook

Extended textbook

Score: **15.3%**

1 ✕
2 ✕
3 ✕
4 ✕
5 ✕
6 ✕
7 ✕

8	✗
9	✓
10	✓
11	✗
12	✗
13	✗
14	✓
15	✗
16	✓
17	✗
18	✗
19	✗
20	✗
21	✓
22	✓
23	✗
24	✗
25	✗
26	✗
27	✓
28	✗
29	✗
30	✓
31	✓
32	✗
33	✗
34	✗
35	✗
36	✗
37	✗
38	✗
39	✗
40	-
41	✗
42	✗
43	✗

44	✗
45	✓
46	✗
47	✗
48	✗
49	✗
50	✗
51	✗
52	✗
53	✗
54	✗
55	✗
56	✗
57	✗
58	✗
59	✗
60	✗
61	✗
62	✗
63	✗
64	✗
65	✗
66	✗
67	✓
68	✗
69	✓
70	✗
71	✗
72	✓
73	✗
74	✗
75	✗
76	✗
77	✗
78	-
79	✗

80 ✗
81 ✓
82 ✗
83 ✗
84 ✗
85 ✗
86 ✗
87 ✗
88 ✗
89 ✗
90 ✓
91 ✗
92 ✗
93 ✗
94 ✗
95 ✗
96 ✗
97 ✗
98 ✗
99 ✗
100 ✗

All contents of this site are © 2024 Passmedicine Limited

Back to top

A 67-year-old gentleman presents with a three-day history of a productive cough. He complains that over the last two days he has been progressively more short of breath, He complains of feeling very weak and lethargic and on further questioning reports fevers and rigors. His wife brought him to the emergency department as she was concerned as he appeared to be deteriorating rapidly.

Observations are: heart rate 125 beats per minute, respiratory rate 32 breaths per minute, S_a0_2 90% on room air, temperature 38.9º, blood pressure is 130/84 mmHg.

He appears distressed but is not confused.

Initial investigations show:

Hb	134 g/l
Platelets	550 * 10^9/l
WBC	18 * 10^9/l

Na^+	141 mmol/l
K^+	3.7 mmol/l
Urea	9.2 mmol/l
Creatinine	130 µmol/l

Chest x-ray shows left lower zone consolidation.

From the above information, what is his CURB-65 score?

- 1
- 2
- 3
- 4
- 5

Submit answer

Reference ranges

Score: **17.8%**

1	✗
2	✗
3	✗
4	✗
5	✗
6	✗
7	✗
8	✗
9	✓
10	✓
11	✗
12	✗
13	✗
14	✓
15	✗
16	✓
17	✗
18	✗
19	✗
20	✗
21	✓
22	✓
23	✗
24	✗
25	✗
26	✗

27	✓
28	✗
29	✗
30	✓
31	✓
32	✗
33	✗
34	✗
35	✗
36	✗
37	✗
38	✗
39	✗
40	-
41	✗
42	✗
43	✗
44	✗
45	✓
46	✗
47	✗
48	✗
49	✗
50	✗
51	✗
52	✗
53	✗
54	✗
55	✗
56	✗
57	✗
58	✗
59	✗
60	✗
61	✗
62	✗

63	✗
64	✗
65	✗
66	✗
67	✓
68	✗
69	✓
70	✗
71	✗
72	✓
73	✗
74	✗
75	-
76	-
77	-
78	-
79	-
80	-
81	-
82	-
83	-
84	-
85	-
86	-
87	-
88	-
89	-
90	-
91	-
92	-
93	-
94	-
95	-

All contents of this site are © 2024 Passmedicine Limited
Back to top

A 67-year-old gentleman presents with a three-day history of a productive cough. He complains that over the last two days he has been progressively more short of breath, He complains of feeling very weak and lethargic and on further questioning reports fevers and rigors. His wife brought him to the emergency department as she was concerned as he appeared to be deteriorating rapidly.

Observations are: heart rate 125 beats per minute, respiratory rate 32 breaths per minute, S_a0_2 90% on room air, temperature 38.9º, blood pressure is 130/84 mmHg.

He appears distressed but is not confused.

Initial investigations show:

Hb	134 g/l
Platelets	550 * 10^9/l
WBC	18 * 10^9/l

Na^+	141 mmol/l
K^+	3.7 mmol/l
Urea	9.2 mmol/l
Creatinine	130 µmol/l

Chest x-ray shows left lower zone consolidation.

From the above information, what is his CURB-65 score?

1	0%
2	7%
3	81%
4	11%
5	1%

This patient has a community-acquired pneumonia which is a common presentation on the acute medical take (Incidence: 5-11/1000). Patients typically present with a productive cough, fevers, shortness of breath, anorexia, rigors and may report pleuritic chest pain and haemoptysis. Community-acquired pneumonia may be primary or secondary to underlying disease.

Discuss (2) Improve

Next question

Pneumonia: assessment and management

Primary care setting

NICE recommends that patients should initially be assessed in primary care using the CRB65 criteria:

Criterion	Marker
C	Confusion (abbreviated mental test score <= 8/10)
R	Respiration rate >= 30/min
B	Blood pressure: systolic <= 90 mmHg and/or diastolic <= 60 mmHg
65	Aged >= 65 years

Patients are stratified for risk of death as follows:

- 0: low risk (less than 1% mortality risk)
  - NICE recommend that treatment at home should be considered (alongside clinical judgement)
- 1 or 2: intermediate risk (1-10% mortality risk)
  - NICE recommend that ' hospital assessment should be considered (particularly for people with a score of 2)'
- 3 or 4: high risk (more than 10% mortality risk)
  - NICE recommend urgent admission to hospital

NICE also mention point-of-care CRP test. This is currently not widely available but they make the following recommendation with reference to the use of antibiotic therapy:

- CRP < 20 mg/L - do not routinely offer antibiotic therapy
- CRP 20 - 100 mg/L - consider a delayed antibiotic prescription
- CRP > 100 mg/L - offer antibiotic therapy

Secondary care setting

Note that in hospital, once blood tests are available the CURB65, rather than the CRB65, can be used. This adds an extra criterion of urea > 7 mmol/L:

Criterion	Marker
C	Confusion (abbreviated mental test score <= 8/10)
U	urea > 7 mmol/L
R	Respiration rate >= 30/min
B	Blood pressure: systolic <= 90 mmHg and/or diastolic <= 60 mmHg
65	Aged >= 65 years

NICE recommend, in conjunction with clinical judgement:

- consider home-based care for patients with a CURB65 score of 0 or 1 - low risk (less than 3% mortality risk)
- consider hospital-based care for patients with a CURB65 score of 2 or more - intermediate risk (3-15% mortality risk)
- consider intensive care assessment for patients with a CURB65 score of 3 or more - high risk (more than 15% mortality risk)

Investigations

- chest x-ray
- in intermediate or high-risk patients NICE recommend blood and sputum cultures, pneumococcal and legionella urinary antigen tests
- CRP monitoring is recommend for admitted patients to help determine response to treatment

Management of low-severity community acquired pneumonia

- amoxicillin is first-line
- if penicillin allergic then use a macrolide or tetracycline

- NICE now recommend a 5 day course of antibiotics for patients with low severity community acquired pneumonia

Management of moderate and high-severity community acquired pneumonia
- dual antibiotic therapy is recommended with amoxicillin and a macrolide
- a 7-10 day course is recommended
- NICE recommend considering a beta-lactamase stable penicillin such as co-amoxiclav, ceftriaxone or piperacillin with tazobactam and a macrolide in high-severity community acquired pneumonia

Discharge criteria and advice post-discharge

NICE recommend that patients are not routinely discharged if in the past 24 hours they have had 2 or more of the following findings:
- temperature higher than 37.5°C
- respiratory rate 24 breaths per minute or more
- heart rate over 100 beats per minute
- systolic blood pressure 90 mmHg or less
- oxygen saturation under 90% on room air
- abnormal mental status
- inability to eat without assistance.

They also recommend delaying discharge if the temperature is higher than 37.5°C.

NICE recommend that the following information is given to patients with pneumonia in terms of how quickly their symptoms should symptoms should resolve:

Time	Progress
1 week	Fever should have resolved
4 weeks	Chest pain and sputum production should have substantially reduced
6 weeks	Cough and breathlessness should have substantially reduced
3 months	Most symptoms should have resolved but fatigue may still be present
6 months	Most people will feel back to normal.

All cases of pneumonia should have a repeat chest X-ray at 6 weeks after clinical resolution to

ensure that the consolidation has resolved and there is no underlying secondary abnormalities (e.g. a lung tumour).

123

Next question

Textbooks

High-yield textbook

Extended textbook

Links

NICE 16 11

2014 Pneumonia in adults: diagnosis and management

Clinical Knowledge Summaries 14 7

Community-acquired pneumonia

MDCalc 17 5

CURB-65 scoring tool

Suggest link

Report broken link

Media

Pneumonia

Osmosis - YouTube 👍 4 👎 0

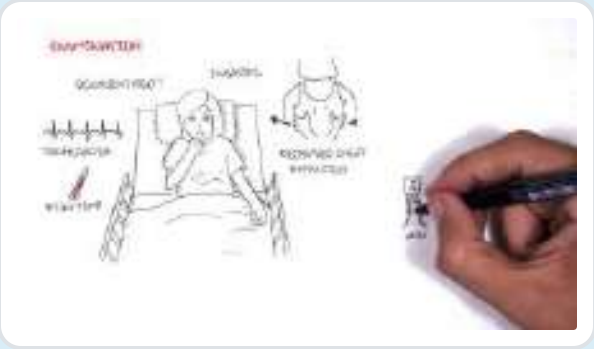

Community Acquired Pneumonia

Armando Hasudungan - YouTube 👍 3 👎 0

Report broken media

Score: **15.3%**

1	✗
2	✗
3	✗
4	✗
5	✗
6	✗
7	✗
8	✗
9	✓
10	✓
11	✗
12	✗
13	✗
14	✓
15	✗
16	✓
17	✗

18	✗
19	✗
20	✗
21	✓
22	✓
23	✗
24	✗
25	✗
26	✗
27	✓
28	✗
29	✗
30	✓
31	✓
32	✗
33	✗
34	✗
35	✗
36	✗
37	✗
38	✗
39	✗
40	-
41	✗
42	✗
43	✗
44	✗
45	✓
46	✗
47	✗
48	✗
49	✗
50	✗
51	✗
52	✗
53	✗

54	✗
55	✗
56	✗
57	✗
58	✗
59	✗
60	✗
61	✗
62	✗
63	✗
64	✗
65	✗
66	✗
67	✓
68	✗
69	✓
70	✗
71	✗
72	✓
73	✗
74	✗
75	✗
76	✗
77	✗
78	-
79	✗
80	✗
81	✓
82	✗
83	✗
84	✗
85	✗
86	✗
87	✗
88	✗
89	✗

90 ✓
91 ✗
92 ✗
93 ✗
94 ✗
95 ✗
96 ✗
97 ✗
98 ✗
99 ✗
100 ✗

All contents of this site are © 2024 Passmedicine Limited

A 49-year-old woman presents with a one-year history of joint pain and an intermittent purpuric rash. For the last 3 months, she feels more fatigued than usual with malaise, fever and intermittent abdominal pain. She had an appendectomy 10 years ago. Besides that, there is no past medical history of significance.

On clinical examination, the only abnormality is a purpuric rash involving her calves and thighs.

The results of initial investigations showed a normal full blood count, but impaired renal function with a plasma creatinine of 160 µmol/l.

Another set of investigations were ordered to reach a diagnosis:

Na+	135 mmol/l
K+	4 mmol/l
Creatinine	165 µmol/l
Urea	11 mmol/l
CRP	50 mg/l
ESR	70 mm/hr
Urine analysis	Protein +,RBCs ++
Rheumatoid factor	negative
C3 and C4 levels	normal
cANCA	positive
pANCA	positive
ANA	negative

Renal biopsy showed focal necrosis, crescent formation, and absence of immunoglobulin deposits on immunofluorescence.

What is the most likely diagnosis?

- Rheumatoid vasculitis
- Mixed cryoglobulinaemia

- Wegener's granulomatosis (WG)
- Microscopic polyangiitis (MPA)
- Systemic lupus erythematosus (SLE)

Submit answer

Reference ranges

Score: **17.8%**

1	✗
2	✗
3	✗
4	✗
5	✗
6	✗
7	✗
8	✗
9	✓
10	✓
11	✗
12	✗
13	✗
14	✓
15	✗
16	✓
17	✗
18	✗
19	✗
20	✗
21	✓

22	✓
23	✗
24	✗
25	✗
26	✗
27	✓
28	✗
29	✗
30	✓
31	✓
32	✗
33	✗
34	✗
35	✗
36	✗
37	✗
38	✗
39	✗
40	-
41	✗
42	✗
43	✗
44	✗
45	✓
46	✗
47	✗
48	✗
49	✗
50	✗
51	✗
52	✗
53	✗
54	✗
55	✗
56	✗
57	✗

58	✗
59	✗
60	✗
61	✗
62	✗
63	✗
64	✗
65	✗
66	✗
67	✓
68	✗
69	✓
70	✗
71	✗
72	✓
73	✗
74	✗
75	-
76	-
77	-
78	-
79	-
80	-
81	-
82	-
83	-
84	-
85	-
86	-
87	-
88	-
89	-
90	-
91	-
92	-
93	-
94	-
95	-

96 -

All contents of this site are © 2024 Passmedicine Limited

Back to top

A 49-year-old woman presents with a one-year history of joint pain and an intermittent purpuric rash. For the last 3 months, she feels more fatigued than usual with malaise, fever and intermittent abdominal pain. She had an appendectomy 10 years ago. Besides that, there is no past medical history of significance.

On clinical examination, the only abnormality is a purpuric rash involving her calves and thighs.

The results of initial investigations showed a normal full blood count, but impaired renal function with a plasma creatinine of 160 μmol/l.

Another set of investigations were ordered to reach a diagnosis:

Na+	135 mmol/l
K+	4 mmol/l
Creatinine	165 μmol/l
Urea	11 mmol/l
CRP	50 mg/l
ESR	70 mm/hr
Urine analysis	Protein +,RBCs ++
Rheumatoid factor	negative
C3 and C4 levels	normal
cANCA	positive
pANCA	positive
ANA	negative

Renal biopsy showed focal necrosis, crescent formation, and absence of immunoglobulin deposits on immunofluorescence.

What is the most likely diagnosis?

- Rheumatoid vasculitis 1%
- Mixed cryoglobulinaemia 11%

Wegener's granulomatosis (WG) 40%

Microscopic polyangiitis (MPA) 43%

Systemic lupus erythematosus (SLE) 4%

MPA is a systemic vasculitis affecting the small vessels including arterioles, capillaries, and venules. It usually presents with a long history of constitutional symptoms with multisystem involvement. Note that cANCA and pANCA could be useful in differentiating WG from MPA but not always.

SLE would be unlikely with a negative ANA, and pauci-immune glomerulonephritis.

WG is unlikely with the absence of upper and lower airway involvement. Also, the absence of granuloma formation in the kidneys would not favour it.

Usually, rheumatoid vasculitis would be clinically apparent because it develops on a background of severe rheumatoid disease. Also, the rheumatoid factor would be very high, with low C3 and C4.

Mixed cryoglobulinaemia characteristically would have a positive rheumatoid factor. Glomerulonephritis has distinctive features, being characterized by marked deposition of immunoglobulin and complement. C4 would be markedly low in 90% of patients due to classical pathway activation by cryoglobulins. This is in contrast to MPA where the complement levels would be normal or even elevated as an acute phase response.

Discuss (3) | Improve

Next question

Microscopic polyangiitis

Microscopic polyangiitis is a small-vessel ANCA vasculitis.

Features

- renal impairment: raised creatinine, haematuria, proteinuria
- fever
- other systemic symptoms: lethargy, myalgia, weight loss
- rash: palpable purpura
- cough, dyspnoea, haemoptysis
- mononeuritis multiplex

Investigations

- pANCA (against MPO) - positive in 50-75%
- cANCA (against PR3) - positive in 40%

AI + Q 123

Next question

Textbooks

High-yield textbook

Extended textbook

Media

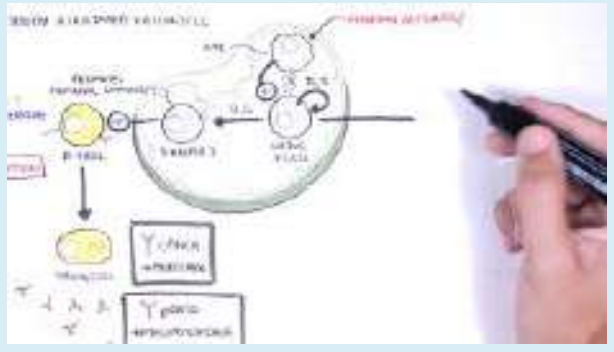

ANCA (Anti-Neutrophil Cytoplasmic Antibody) Associated Vasculitis - Causes, Pathophysiology, Types

Armando Hasudungan - YouTube 4 1

Report broken media

Score: **15.3%**

1 ✗
2 ✗

3	✗
4	✗
5	✗
6	✗
7	✗
8	✗
9	✓
10	✓
11	✗
12	✗
13	✗
14	✓
15	✗
16	✓
17	✗
18	✗
19	✗
20	✗
21	✓
22	✓
23	✗
24	✗
25	✗
26	✗
27	✓
28	✗
29	✗
30	✓
31	✓
32	✗
33	✗
34	✗
35	✗
36	✗
37	✗
38	✗

39	✗
40	-
41	✗
42	✗
43	✗
44	✗
45	✓
46	✗
47	✗
48	✗
49	✗
50	✗
51	✗
52	✗
53	✗
54	✗
55	✗
56	✗
57	✗
58	✗
59	✗
60	✗
61	✗
62	✗
63	✗
64	✗
65	✗
66	✗
67	✓
68	✗
69	✓
70	✗
71	✗
72	✓
73	✗
74	✗

75	✗
76	✗
77	✗
78	-
79	✗
80	✗
81	✓
82	✗
83	✗
84	✗
85	✗
86	✗
87	✗
88	✗
89	✗
90	✓
91	✗
92	✗
93	✗
94	✗
95	✗
96	✗
97	✗
98	✗
99	✗
100	✗

All contents of this site are © 2024 Passmedicine Limited

A 40-year-old man attends the emergency department with a 3-day history of worsening respiratory symptoms. The patient reported that his initial symptoms had included a runny nose, sore throat and myalgia. Subsequently, he developed a persistent dry cough and had experienced mild shortness of breath on exertion, for example after climbing a flight of stairs. The patient had not measured his temperature at home but recalled that, at times, he had felt extremely hot and sweaty. The patient denied any other symptoms, including a cough productive of sputum or blood, abdominal symptoms or chest pain.

The patient reported having just returned from a 2 week holiday in Egypt. The majority of the patient's trip had been based in large towns and cities; however, the patient had also participated in a 4-day 'camel trek' through the desert. On direct questioning, the patient reported having drunk camel milk offered to him by his guides, which he did not think had been pasteurised or otherwise processed prior to consumption. The patient had not knowingly spent time around any unwell individuals and had not sought medical advice while overseas. Prior to this holiday, the patient had not travelled outside of the UK for several years.

The patient was in generally good health, with no active chronic medical problems. The patient's only previous attendance at the emergency department was 5 years previously when he had treated for a broken ankle sustained when playing football. The patient took no regular medications and had no known allergies to medications. The patient did not regularly consume alcohol or recreational drugs but did smoke 5-10 cigarettes per day.

General examination of the patient showed a middle-aged man who appeared flushed in the face and unwell. Examination of the respiratory system demonstrated normal air entry and resonance to both lung fields, with no significant added sounds on auscultation. With the patient at rest, there were no signs of respiratory distress. Examination of the cardiovascular and abdominal systems demonstrated no significant abnormality. There was no notable rashes and no signs of peripheral deep vein thrombosis.

Heart rate	92 beats / minute
Respiratory rate	18 respirations / minute
Blood pressure	125 / 76 mmHg
Oxygen saturations	95 %
Glasgow coma scale score	15
Temperature	38.2 °C

Haemoglobin	135 g / dL
White cell count	3.7 x 10>3 / microlitre
Neutrophils	2.5 x 10>3 / microlitre (reference 1.8-7.8)
Lymphocytes	1.0 x 10>3 / microlitre (reference 1.5-4.0)
Platelets	123 x 10>3 / microlitre
Urea	6.1 mmol / L
Creatinine	82 micromol / L
Alkaline phosphatase	154 U / L (reference 35-100)
ALT	72 U / L (reference 3-36)
Bilirubin	23 micromol / L (reference < 26)
Chest x-ray	clear lung fields, no pneumothorax

What is the likely pathogen responsible for the patient's illness?

- MERS coronavirus
- Dengue virus
- West Nile virus
- Junin virus
- Ebola virus

Submit answer

Reference ranges

Score: **17.8%**

1 ✗
2 ✗

3	✗
4	✗
5	✗
6	✗
7	✗
8	✗
9	✓
10	✓
11	✗
12	✗
13	✗
14	✓
15	✗
16	✓
17	✗
18	✗
19	✗
20	✗
21	✓
22	✓
23	✗
24	✗
25	✗
26	✗
27	✓
28	✗
29	✗
30	✓
31	✓
32	✗
33	✗
34	✗
35	✗
36	✗
37	✗
38	✗

39	✗
40	-
41	✗
42	✗
43	✗
44	✗
45	✓
46	✗
47	✗
48	✗
49	✗
50	✗
51	✗
52	✗
53	✗
54	✗
55	✗
56	✗
57	✗
58	✗
59	✗
60	✗
61	✗
62	✗
63	✗
64	✗
65	✗
66	✗
67	✓
68	✗
69	✓
70	✗
71	✗
72	✓
73	✗
74	✗

75	-
76	-
77	-
78	-
79	-
80	-
81	-
82	-
83	-
84	-
85	-
86	-
87	-
88	-
89	-
90	-
91	-
92	-
93	-
94	-
95	-
96	-
97	-

All contents of this site are © 2024 Passmedicine Limited

Back to top

A 40-year-old man attends the emergency department with a 3-day history of worsening respiratory symptoms. The patient reported that his initial symptoms had included a runny nose, sore throat and myalgia. Subsequently, he developed a persistent dry cough and had experienced mild shortness of breath on exertion, for example after climbing a flight of stairs. The patient had not measured his temperature at home but recalled that, at times, he had felt extremely hot and sweaty. The patient denied any other symptoms, including a cough productive of sputum or blood, abdominal symptoms or chest pain.

The patient reported having just returned from a 2 week holiday in Egypt. The majority of the patient's trip had been based in large towns and cities; however, the patient had also participated in a 4-day 'camel trek' through the desert. On direct questioning, the patient reported having drunk camel milk offered to him by his guides, which he did not think had been pasteurised or otherwise processed prior to consumption. The patient had not knowingly spent time around any unwell individuals and had not sought medical advice while overseas. Prior to this holiday, the patient had not travelled outside of the UK for several years.

The patient was in generally good health, with no active chronic medical problems. The patient's only previous attendance at the emergency department was 5 years previously when he had treated for a broken ankle sustained when playing football. The patient took no regular medications and had no known allergies to medications. The patient did not regularly consume alcohol or recreational drugs but did smoke 5-10 cigarettes per day.

General examination of the patient showed a middle-aged man who appeared flushed in the face and unwell. Examination of the respiratory system demonstrated normal air entry and resonance to both lung fields, with no significant added sounds on auscultation. With the patient at rest, there were no signs of respiratory distress. Examination of the cardiovascular and abdominal systems demonstrated no significant abnormality. There was no notable rashes and no signs of peripheral deep vein thrombosis.

Heart rate	92 beats / minute
Respiratory rate	18 respirations / minute
Blood pressure	125 / 76 mmHg
Oxygen saturations	95 %
Glasgow coma scale score	15
Temperature	38.2 ºC

Haemoglobin	135 g / dL
White cell count	3.7 x 10>3 / microlitre
Neutrophils	2.5 x 10>3 / microlitre (reference 1.8-7.8)
Lymphocytes	1.0 x 10>3 / microlitre (reference 1.5-4.0)
Platelets	123 x 10>3 / microlitre
Urea	6.1 mmol / L
Creatinine	82 micromol / L
Alkaline phosphatase	154 U / L (reference 35-100)
ALT	72 U / L (reference 3-36)
Bilirubin	23 micromol / L (reference < 26)
Chest x-ray	clear lung fields, no pneumothorax

What is the likely pathogen responsible for the patient's illness?

- MERS coronavirus — 68%
- Dengue virus — 6%
- West Nile virus — 22%
- Junin virus — 3%
- Ebola virus — 2%

The patient's presentation is consistent with Middle East respiratory syndrome (MERS), caused by the betacoronavirus MERS-CoV. Dromedary camels are the primary animal host for MERS-CoV, with human transmission occurring secondary to close contact with camels, or the consumption of unpasteurised camel milk or undercooked camel meat. However, human-to-human transition via respiratory droplets is responsible for the majority of cases of MERS, particularly in the healthcare setting. At the present time, MERS-CoV is limited to the Arabian Peninsula and its surrounding countries, although due to an incubation period of 2-14 days travellers returning from this region may present with MERS in other parts of the world.

The clinical syndrome of MERS is varied, ranging from very only mild symptoms through to life-threatening multi-organ failure. The patient in the question has typical blood results for MERS, including lymphocytopenia, thrombocytopenia and deranged liver function tests. The diagnosis of MERS can be confirmed by reverse transcriptase polymerase chain reaction analysis of respiratory tract secretions to identify MERS-CoV RNA. No specific treatment for MERS-CoV infection is

available. Individuals developing significant complications (or those at high-risk of doing so) require admission to hospital for supportive care.

The pathogens included as incorrect answers to the question either are not endemic in the region the patient had travelled or have clinical presentations dissimilar to that described in the question.

Shalhoub S, Omrani A. Middle East respiratory syndrome. BMJ 2016;355:i5281.

Discuss (16) Improve

Next question

Middle East respiratory syndrome

Middle East respiratory syndrome (MERS) is caused by the betacoronavirus MERS-CoV.

At the present time, MERS-CoV is limited to the Arabian Peninsula and its surrounding countries, although due to an incubation period of 2-14 days travellers returning from this region may present with MERS in other parts of the world.

Contact with camels (including camel products such as milk) is a significant risk factor for MERS-CoV.

The clinical syndrome of MERS is varied, ranging from very only mild symptoms through to life-threatening multi-organ failure.

123

Next question

Textbooks

High-yield textbook

Extended textbook

Media

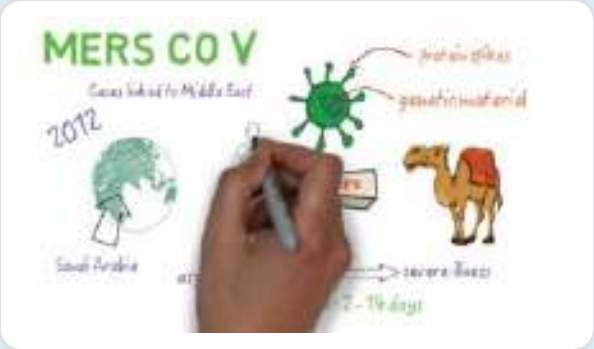

MERS CoV - An overview

Let's Learn About Bugs - YouTube 👍 3 👎 1

Report broken media

Score: **15.3%**

1	✗
2	✗
3	✗
4	✗
5	✗
6	✗
7	✗
8	✗
9	✓
10	✓
11	✗
12	✗
13	✗
14	✓
15	✗
16	✓
17	✗

18	✗
19	✗
20	✗
21	✓
22	✓
23	✗
24	✗
25	✗
26	✗
27	✓
28	✗
29	✗
30	✓
31	✓
32	✗
33	✗
34	✗
35	✗
36	✗
37	✗
38	✗
39	✗
40	-
41	✗
42	✗
43	✗
44	✗
45	✓
46	✗
47	✗
48	✗
49	✗
50	✗
51	✗
52	✗
53	✗

54	✗
55	✗
56	✗
57	✗
58	✗
59	✗
60	✗
61	✗
62	✗
63	✗
64	✗
65	✗
66	✗
67	✓
68	✗
69	✓
70	✗
71	✗
72	✓
73	✗
74	✗
75	✗
76	✗
77	✗
78	-
79	✗
80	✗
81	✓
82	✗
83	✗
84	✗
85	✗
86	✗
87	✗
88	✗
89	✗

90 ✓
91 ✗
92 ✗
93 ✗
94 ✗
95 ✗
96 ✗
97 ✗
98 ✗
99 ✗
100 ✗

All contents of this site are © 2024 Passmedicine Limited

A 73-year-old is referred to the pulmonary hypertension team after undergoing an echocardiogram. She had initially been admitted after a 4-day history of exertional dyspnoea. A chest x-ray revealed bilateral pulmonary oedema. She demonstrated acute ischaemic changes on her ECG. Her past medical history includes type 2 diabetes mellitus, hypertension, hypercholesterolaemia and a previous NSTEMI in 2010. An echocardiogram demonstrated moderate to severe LV dysfunction, with a pulmonary arterial pressure of 83 mmHg (normal <25 mmHg). What is the most appropriate next diagnostic investigation?

- No further investigations for pulmonary hypertension
- V/Q scan
- CTPA
- Right and left heart catheterisation
- Lung function tests

Submit answer

Reference ranges

Score: **17.8%**

1 ✗
2 ✗
3 ✗
4 ✗
5 ✗
6 ✗
7 ✗

8	✗
9	✓
10	✓
11	✗
12	✗
13	✗
14	✓
15	✗
16	✓
17	✗
18	✗
19	✗
20	✗
21	✓
22	✓
23	✗
24	✗
25	✗
26	✗
27	✓
28	✗
29	✗
30	✓
31	✓
32	✗
33	✗
34	✗
35	✗
36	✗
37	✗
38	✗
39	✗
40	-
41	✗
42	✗
43	✗

44	✗
45	✓
46	✗
47	✗
48	✗
49	✗
50	✗
51	✗
52	✗
53	✗
54	✗
55	✗
56	✗
57	✗
58	✗
59	✗
60	✗
61	✗
62	✗
63	✗
64	✗
65	✗
66	✗
67	✓
68	✗
69	✓
70	✗
71	✗
72	✓
73	✗
74	✗
75	-
76	-
77	-
78	-
79	-
80	-

81	-
82	-
83	-
84	-
85	-
86	-
87	-
88	-
89	-
90	-
91	-
92	-
93	-
94	-
95	-
96	-
97	-
98	-

All contents of this site are © 2024 Passmedicine Limited

A 73-year-old is referred to the pulmonary hypertension team after undergoing an echocardiogram. She had initially been admitted after a 4-day history of exertional dyspnoea. A chest x-ray revealed bilateral pulmonary oedema. She demonstrated acute ischaemic changes on her ECG. Her past medical history includes type 2 diabetes mellitus, hypertension, hypercholesterolaemia and a previous NSTEMI in 2010. An echocardiogram demonstrated moderate to severe LV dysfunction, with a pulmonary arterial pressure of 83 mmHg (normal <25 mmHg). What is the most appropriate next diagnostic investigation?

No further investigations for pulmonary hypertension	19%
V/Q scan	3%
CTPA	10%
Right and left heart catheterisation	64%
Lung function tests	4%

Pulmonary hypertension is divided according to the World Health Organisation (WHO) into five classes based on aetiology:

- I pulmonary arterial hypertension
- II pulmonary hypertension secondary to left heart disease
- III pulmonary hypertension secondary to lung disease
- IV pulmonary hypertension secondary to chronic thromboembolic disease
- V pulmonary hypertension with unclear causes

This patient has sufficient left-sided heart disease to explain her pulmonary hypertension and is hence a group 2 pulmonary hypertension patient. No further investigations are required. Treatment of pulmonary hypertension, in this case, is dependent on optimising left ventricular failure.

Discuss (9) | Improve

Next question

Pulmonary hypertension: causes and classification

Pulmonary hypertension may be defined as a sustained elevation in mean pulmonary arterial pressure of greater than 20 mmHg at rest. It has recently been reclassified by the WHO:

Group 1: Pulmonary arterial hypertension (PAH)
- idiopathic*
- familial
- associated conditions: collagen vascular disease, congenital heart disease with systemic to pulmonary shunts, HIV**, drugs and toxins, sickle cell disease
- persistent pulmonary hypertension of the newborn

Group 2: Pulmonary hypertension with left heart disease
- left-sided atrial, ventricular or valvular disease such as left ventricular systolic and diastolic dysfunction, mitral stenosis and mitral regurgitation

Group 3: Pulmonary hypertension secondary to lung disease/hypoxia
- COPD
- interstitial lung disease
- sleep apnoea
- high altitude

Group 4: Pulmonary hypertension due to thromboembolic disease

Group 5: Miscellaneous conditions
- lymphangiomatosis e.g. secondary to carcinomatosis or sarcoidosis

*previously termed primary pulmonary hypertension
**the mechanism by which HIV infection produces pulmonary hypertension remains unknown

123

Next question

Textbooks

High-yield textbook

Extended textbook

Links

Medcomic 8 3

Pulmonary hypertension

Suggest link Report broken link

Media

Pulmonary hypertension

Osmosis - YouTube 5 0

Report broken media

Score: **15.3%**

1 ✗
2 ✗
3 ✗
4 ✗
5 ✗
6 ✗
7 ✗
8 ✗
9 ✓

10	✓
11	✗
12	✗
13	✗
14	✓
15	✗
16	✓
17	✗
18	✗
19	✗
20	✗
21	✓
22	✓
23	✗
24	✗
25	✗
26	✗
27	✓
28	✗
29	✗
30	✓
31	✓
32	✗
33	✗
34	✗
35	✗
36	✗
37	✗
38	✗
39	✗
40	-
41	✗
42	✗
43	✗
44	✗
45	✓

46	✗
47	✗
48	✗
49	✗
50	✗
51	✗
52	✗
53	✗
54	✗
55	✗
56	✗
57	✗
58	✗
59	✗
60	✗
61	✗
62	✗
63	✗
64	✗
65	✗
66	✗
67	✓
68	✗
69	✓
70	✗
71	✗
72	✓
73	✗
74	✗
75	✗
76	✗
77	✗
78	-
79	✗
80	✗
81	✓

82	✗
83	✗
84	✗
85	✗
86	✗
87	✗
88	✗
89	✗
90	✓
91	✗
92	✗
93	✗
94	✗
95	✗
96	✗
97	✗
98	✗
99	✗
100	✗

All contents of this site are © 2024 Passmedicine Limited

Back to top

A 67-year-old female patient presents to respiratory outpatients having been referred by her GP with increasing breathlessness. The referral letter mentions she has received 2 courses of antibiotics for chest infections in the last year and a 50 pack year smoking history. The patient complains of a productive cough with occasional streaks of blood but no history of weight loss. Her past medical history includes cardiac failure treated with enalapril, bisoprolol and furosemide, recurrent urinary tract infections treated with long-term nitrofurantoin and osteoarthritis treated with paracetamol and meptazinol. On examination, there is bilateral scattered coarse crepitations and finger clubbing.

Spirometry in clinic is as follows:

Forced vital capacity (FVC)	1.99L (72% predicted)
Forced expiratory volume in 1 second (FEV1)	1.20L (52% predicted)
FEV1/FVC ratio	0.60

What is the likely diagnosis?

- Bronchiectasis
- Chronic obstructive pulmonary disease
- Pulmonary fibrosis
- Squamous cell carcinoma
- Congestive cardiac failure

Submit answer

Reference ranges

Score: **17.8%**

1	✗
2	✗
3	✗
4	✗
5	✗
6	✗
7	✗
8	✗
9	✓
10	✓
11	✗
12	✗
13	✗
14	✓
15	✗
16	✓
17	✗
18	✗
19	✗
20	✗
21	✓
22	✓
23	✗
24	✗
25	✗
26	✗
27	✓
28	✗
29	✗
30	✓
31	✓
32	✗
33	✗
34	✗

35	✗
36	✗
37	✗
38	✗
39	✗
40	-
41	✗
42	✗
43	✗
44	✗
45	✓
46	✗
47	✗
48	✗
49	✗
50	✗
51	✗
52	✗
53	✗
54	✗
55	✗
56	✗
57	✗
58	✗
59	✗
60	✗
61	✗
62	✗
63	✗
64	✗
65	✗
66	✗
67	✓
68	✗
69	✓
70	✗

71	✗
72	✓
73	✗
74	✗
75	-
76	-
77	-
78	-
79	-
80	-
81	-
82	-
83	-
84	-
85	-
86	-
87	-
88	-
89	-
90	-
91	-
92	-
93	-
94	-
95	-
96	-
97	-
98	-
99	-

All contents of this site are © 2024 Passmedicine Limited

A 67-year-old female patient presents to respiratory outpatients having been referred by her GP with increasing breathlessness. The referral letter mentions she has received 2 courses of antibiotics for chest infections in the last year and a 50 pack year smoking history. The patient complains of a productive cough with occasional streaks of blood but no history of weight loss. Her past medical history includes cardiac failure treated with enalapril, bisoprolol and furosemide, recurrent urinary tract infections treated with long-term nitrofurantoin and osteoarthritis treated with paracetamol and meptazinol. On examination, there is bilateral scattered coarse crepitations and finger clubbing.

Spirometry in clinic is as follows:

Forced vital capacity (FVC)	1.99L (72% predicted)
Forced expiratory volume in 1 second (FEV1)	1.20L (52% predicted)
FEV1/FVC ratio	0.60

What is the likely diagnosis?

- Bronchiectasis 53%
- Chronic obstructive pulmonary disease 31%
- Pulmonary fibrosis 12%
- Squamous cell carcinoma 4%
- Congestive cardiac failure 1%

The spirometry results suggest an obstructive lung disease as FEV1/FVC ratio is < 0.7.

This patient is likely to have bronchiectasis given the obstructive spirometry, productive cough, coarse crepitations and history of recurrent chest infections.

Suspicion of pulmonary fibrosis is raised by long-term nitrofurantoin use but the history, examination and spirometry findings do not fit this diagnosis. Congestive cardiac failure may cause bilateral crepitations does not cause finger clubbing. A malignant diagnosis is less likely

given the absence of weight loss and bilateral signs. One would expect to find wheeze to support a diagnosis of chronic obstructive pulmonary disease.

Discuss (6) Improve

Next question

Bronchiectasis: causes

Bronchiectasis describes a permanent dilatation of the airways secondary to chronic infection or inflammation. There are a wide variety of causes are listed below:

Causes
- post-infective: tuberculosis, measles, pertussis, pneumonia
- cystic fibrosis
- bronchial obstruction e.g. lung cancer/foreign body
- immune deficiency: selective IgA, hypogammaglobulinaemia
- allergic bronchopulmonary aspergillosis (ABPA)
- ciliary dyskinetic syndromes: Kartagener's syndrome, Young's syndrome
- yellow nail syndrome

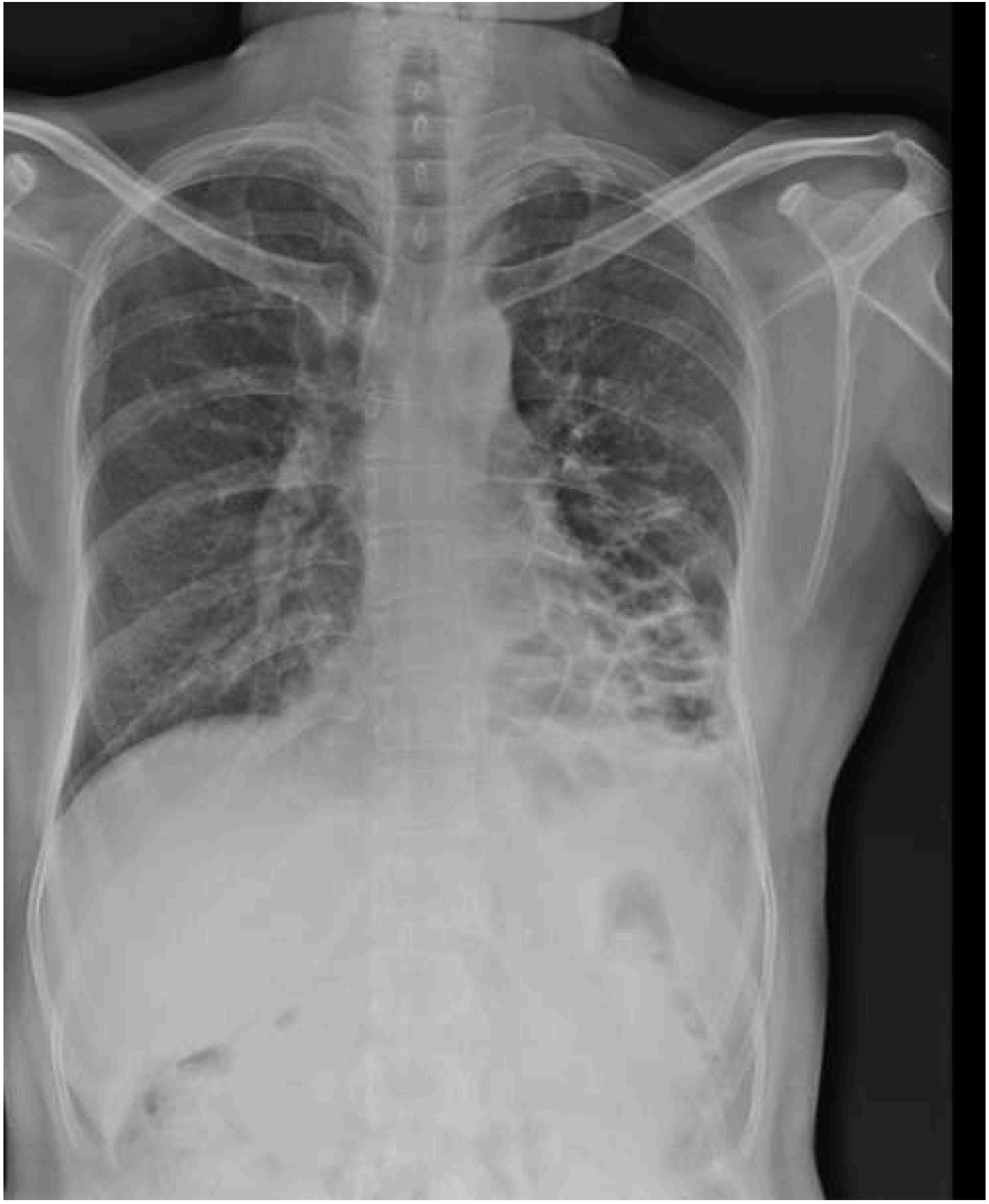

© Image used on license from Radiopaedia

Chest x-ray showing tramlines, most prominent in the left lower zone

© Image used on license from Radiopaedia

CT chest showing widespread tram-track and signet ring signs

123

Next question

Textbooks

High-yield textbook

Extended textbook

Links

British Thoracic Society 2 1

2018 Bronchiectasis guidelines

Suggest link Report broken link

Media

Bronchiectasis - causes, pathophysiology, signs and symptoms, investigations and treatment

Armando Hasudungan - YouTube 3 0

Bronchiectasis crackles - REQUIRES HEADPHONES

Thinklabs - YouTube 3 1

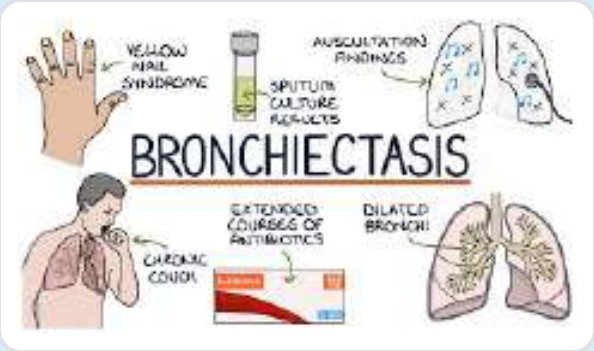

Bronchiectasis

Zero To Finals - YouTube 0 2

Report broken media

Score: **15.3%**

1	✗
2	✗
3	✗
4	✗
5	✗
6	✗
7	✗
8	✗
9	✓
10	✓
11	✗
12	✗
13	✗
14	✓
15	✗
16	✓
17	✗
18	✗
19	✗
20	✗
21	✓

22	✓
23	✗
24	✗
25	✗
26	✗
27	✓
28	✗
29	✗
30	✓
31	✓
32	✗
33	✗
34	✗
35	✗
36	✗
37	✗
38	✗
39	✗
40	-
41	✗
42	✗
43	✗
44	✗
45	✓
46	✗
47	✗
48	✗
49	✗
50	✗
51	✗
52	✗
53	✗
54	✗
55	✗
56	✗
57	✗

58	✗
59	✗
60	✗
61	✗
62	✗
63	✗
64	✗
65	✗
66	✗
67	✓
68	✗
69	✓
70	✗
71	✗
72	✓
73	✗
74	✗
75	✗
76	✗
77	✗
78	-
79	✗
80	✗
81	✓
82	✗
83	✗
84	✗
85	✗
86	✗
87	✗
88	✗
89	✗
90	✓
91	✗
92	✗
93	✗

94 ✕
95 ✕
96 ✕
97 ✕
98 ✕
99 ✕
100 ✕

All contents of this site are © 2024 Passmedicine Limited

Back to top

A 30-year-old man presents to the Emergency Department with severe shortness of breath, cough and ongoing weight loss. He has a past medical history of asthma and nasal polyps.

He has seen his general practitioner (GP) 3 times in the last 6 months for chest infections and been given antibiotics.

Given the likely underlying diagnosis, what would you expect to see on his blood results?

- Low lymphocyte count
- Iron deficiency anaemia
- Raised neutrophil count
- Raised eosinophil count
- Low platelet count

Submit answer

Reference ranges

Score: **17.8%**

1 ✗
2 ✗
3 ✗
4 ✗
5 ✗
6 ✗
7 ✗

8	✗
9	✓
10	✓
11	✗
12	✗
13	✗
14	✓
15	✗
16	✓
17	✗
18	✗
19	✗
20	✗
21	✓
22	✓
23	✗
24	✗
25	✗
26	✗
27	✓
28	✗
29	✗
30	✓
31	✓
32	✗
33	✗
34	✗
35	✗
36	✗
37	✗
38	✗
39	✗
40	-
41	✗
42	✗
43	✗

44	✗
45	✓
46	✗
47	✗
48	✗
49	✗
50	✗
51	✗
52	✗
53	✗
54	✗
55	✗
56	✗
57	✗
58	✗
59	✗
60	✗
61	✗
62	✗
63	✗
64	✗
65	✗
66	✗
67	✓
68	✗
69	✓
70	✗
71	✗
72	✓
73	✗
74	✗
75	-
76	-
77	-
78	-
79	-
80	-

81	-
82	-
83	-
84	-
85	-
86	-
87	-
88	-
89	-
90	-
91	-
92	-
93	-
94	-
95	-
96	-
97	-
98	-
99	-
100	-

All contents of this site are © 2024 Passmedicine Limited

A 30-year-old man presents to the Emergency Department with severe shortness of breath, cough and ongoing weight loss. He has a past medical history of asthma and nasal polyps.

He has seen his general practitioner (GP) 3 times in the last 6 months for chest infections and been given antibiotics.

Given the likely underlying diagnosis, what would you expect to see on his blood results?

Low lymphocyte count	4%
Iron deficiency anaemia	4%
Raised neutrophil count	2%
Raised eosinophil count	90%
Low platelet count	1%

Churg-Strauss syndrome - eosinophilia

Important for me Less important

Although a raised neutrophil count is a potential here, a raised eosinophil count is classical of Churg-Strauss, and is required for diagnosis. Nasal involvement is more commonly associated with Wegener's granulomatosis, but it is also seen in a variety of other vasculitides.

Churg-Strauss syndrome (also known as eosinophilic granulomatosis with polyangiitis) is a vasculitis that affects small and medium-sized blood vessels.

It is commonly seen in patients with a history of atopy. It is often described to occur in three stages - the allergic 'prodromal' stage, the eosinophilic stage and the final vasculitic stage.

The mainstay of treatment includes steroids and other immunosuppressant drugs.

Discuss (8) Improve

Next question

Eosinophilic granulomatosis with polyangiitis (Churg-Strauss syndrome)

Eosinophilic granulomatosis with polyangiitis (EGPA) is now the preferred term for **Churg-Strauss syndrome**. It is an ANCA associated small-medium vessel vasculitis.

Features
- asthma
- blood eosinophilia (e.g. > 10%)
- paranasal sinusitis
- mononeuritis multiplex
- pANCA positive in 60%

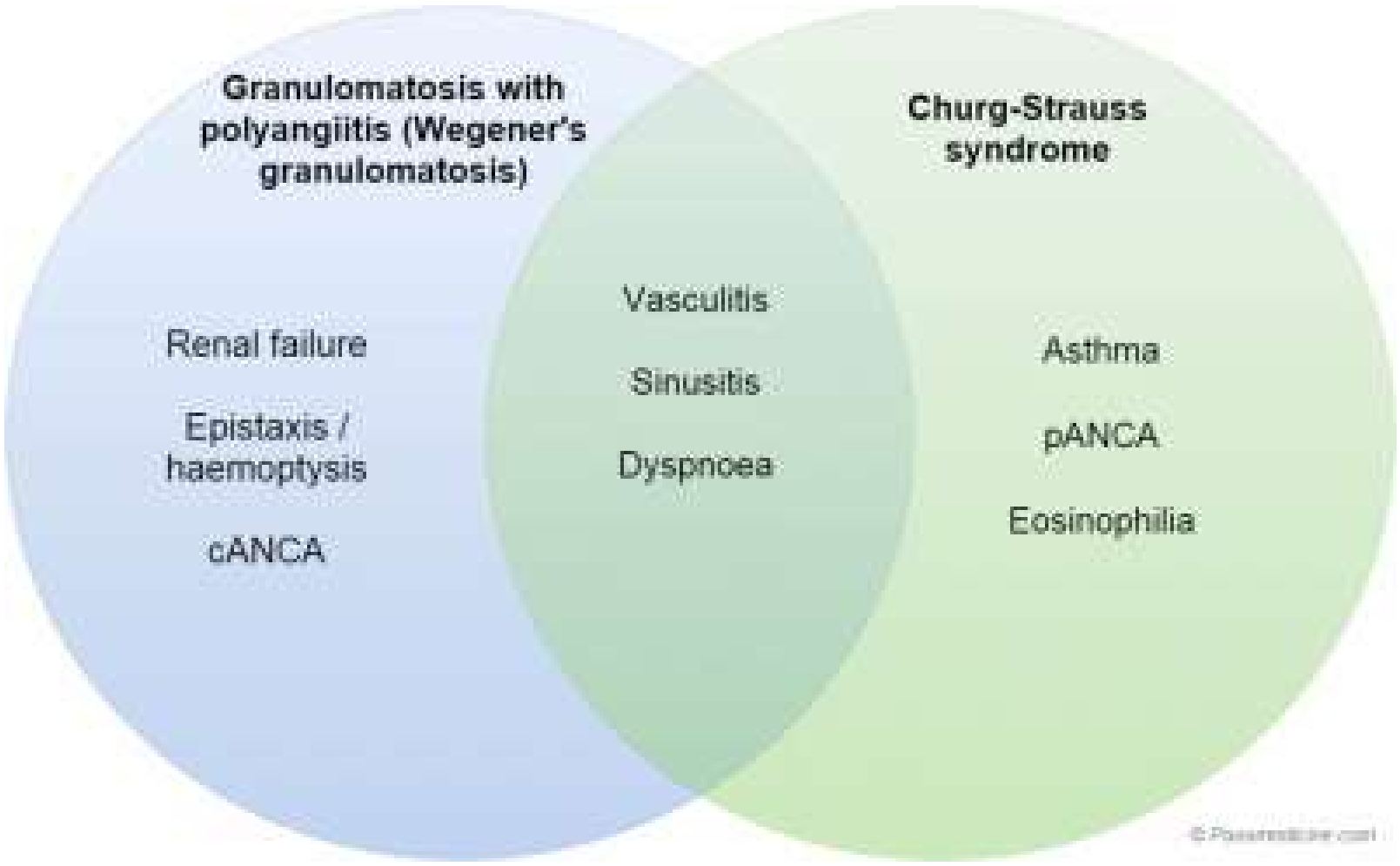

Comparison of granulomatosis with polyangiitis and Churg-Strauss syndrome

Leukotriene receptor antagonists may precipitate the disease.

123

Next question

Textbooks

High-yield textbook

Extended textbook

Media

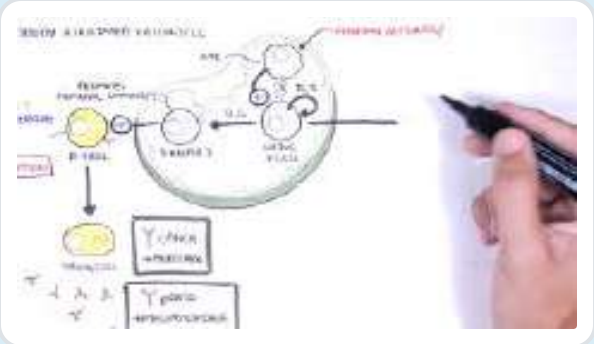

ANCA (Anti-Neutrophil Cytoplasmic Antibody) Associated Vasculitis - Causes, Pathophysiology, Types

Armando Hasudungan - YouTube 3 3

Report broken media

Score: **15.3%**

1	✗
2	✗
3	✗
4	✗
5	✗
6	✗
7	✗
8	✗
9	✓
10	✓
11	✗
12	✗
13	✗
14	✓

15	✗
16	✓
17	✗
18	✗
19	✗
20	✗
21	✓
22	✓
23	✗
24	✗
25	✗
26	✗
27	✓
28	✗
29	✗
30	✓
31	✓
32	✗
33	✗
34	✗
35	✗
36	✗
37	✗
38	✗
39	✗
40	-
41	✗
42	✗
43	✗
44	✗
45	✓
46	✗
47	✗
48	✗
49	✗
50	✗

51	✗
52	✗
53	✗
54	✗
55	✗
56	✗
57	✗
58	✗
59	✗
60	✗
61	✗
62	✗
63	✗
64	✗
65	✗
66	✗
67	✓
68	✗
69	✓
70	✗
71	✗
72	✓
73	✗
74	✗
75	✗
76	✗
77	✗
78	-
79	✗
80	✗
81	✓
82	✗
83	✗
84	✗
85	✗
86	✗

87	✗
88	✗
89	✗
90	✓
91	✗
92	✗
93	✗
94	✗
95	✗
96	✗
97	✗
98	✗
99	✗
100	✗

All contents of this site are © 2024 Passmedicine Limited

Back to top

A 22-year-old man presents to the emergency department with a worsening cough and shortness of breath over the past few days. He has no significant past medical history except for a known allergy to wasp stings and is not on any regular medication. Although he does not smoke himself, he works in an environment where others are often smoking around him.

On examination, he looks to be in respiratory distress, with tachypnoea, tachycardia and low-grade pyrexia. Peripheral oxygen saturations are 87% on air. Blood tests are performed:

Hb	112 g/L	Male: (135-180) Female: (115 - 160)
Platelets	185 * 10^9/L	(150 - 400)
WBC	13.3 * 10^9/L (22% eosinophils)	(4.0 - 11.0)
Urea	6.9 mmol/L	(2.0 - 7.0)
Creatinine	87 µmol/L	(55 - 120)

A chest X-ray is also performed, which demonstrates patchy mixed alveolar-interstitial infiltrates. The medical team are asked to review the patient and a bronchoalveolar lavage is conducted which demonstrates no signs of infection, but 56% eosinophils.

Given the likely diagnosis, which intervention is most appropriate initially?

- Albendazole
- Cyclophosphamide
- Itraconazole
- Methylprednisolone
- Plasma exchange

Submit answer

Reference ranges

Score: **0%**

1 -

All contents of this site are © 2024 Passmedicine Limited

A 22-year-old man presents to the emergency department with a worsening cough and shortness of breath over the past few days. He has no significant past medical history except for a known allergy to wasp stings and is not on any regular medication. Although he does not smoke himself, he works in an environment where others are often smoking around him.

On examination, he looks to be in respiratory distress, with tachypnoea, tachycardia and low-grade pyrexia. Peripheral oxygen saturations are 87% on air. Blood tests are performed:

Hb	112 g/L	Male: (135-180) Female: (115 - 160)
Platelets	185 * 10^9/L	(150 - 400)
WBC	13.3 * 10^9/L (22% eosinophils)	(4.0 - 11.0)
Urea	6.9 mmol/L	(2.0 - 7.0)
Creatinine	87 µmol/L	(55 - 120)

A chest X-ray is also performed, which demonstrates patchy mixed alveolar-interstitial infiltrates. The medical team are asked to review the patient and a bronchoalveolar lavage is conducted which demonstrates no signs of infection, but 56% eosinophils.

Given the likely diagnosis, which intervention is most appropriate initially?

- Albendazole 9%
- Cyclophosphamide 2%
- Itraconazole 15%
- Methylprednisolone 72%
- Plasma exchange 2%

Acute eosinophilic pneumonia is highly responsive to steroids

Important for me   Less important

The diagnosis here is the rare condition acute eosinophilic pneumonia. It is one of several conditions that cause pulmonary eosinophilia and is characterised by a cough, shortness of breath and sometimes a history of allergy. Being a smoker, or being exposed to second-hand smoke, is also thought to be a trigger. The key to diagnosis here is the patient's chest x-ray demonstrating patchy infiltrates, but crucially the bronchiolar lavage which shows a high eosinophil count. This condition is highly responsive to steroids and so methylprednisolone is the correct answer.

Albendazole is an antiparasitic medication. This may be indicated in Loeffler's syndrome - chest x-ray shadowing and blood eosinophilia sometimes due to parasites such as *Strongyloides stercoralis*. The history would have included more focus on a fever and night sweats, and parasites would have been identified during diagnosis.

Cyclophosphamide is an immunosuppressant, used in the management of cancers and autoimmune conditions. This would be indicated if the diagnosis were a rheumatological condition such as eosinophilic granulomatosis with polyangiitis. Similar features would be seen, but a history of asthma would be noted, as well as renal failure; this patient's renal function bloods were normal.

Itraconazole is an antifungal medication and may be used in the management of a differential, allergic bronchopulmonary aspergillosis (ABPA), characterised by asthma-like symptoms that do not respond to initial treatment. Eosinophilia is also seen, but a positive radioallergosorbent (RAST) test to *Aspergillus* should be demonstrated, which is not seen here. Oral steroids are actually used first-line, with itraconazole sometimes being used as an adjunct.

Plasma exchange does not play a role here. It may be used in the management of severe granulomatosis with polyangiitis, as well as a number of other conditions.

Discuss (6) | Improve

Next question

Pulmonary eosinophilia

Pulmonary eosinophilia describes a situation where there are increased numbers of eosinophils in the lung airways and parenchyma. This is generally associated with a blood eosinophilia.

Causes of pulmonary eosinophilia

- Churg-Strauss syndrome
- allergic bronchopulmonary aspergillosis (ABPA)
- Loffler's syndrome
- eosinophilic pneumonia
- hypereosinophilic syndrome

- tropical pulmonary eosinophilia
- drugs: nitrofurantoin, sulphonamides
- less common: Wegener's granulomatosis

Loffler's syndrome

- transient CXR shadowing and blood eosinophilia
- thought to be due to parasites such as *Ascaris lumbricoides* causing an alveolar reaction
- presents with a fever, cough and night sweats which often last for less than 2 weeks.
- generally a self-limiting disease

Acute eosinophilic pneumonia

- highly responsive to steroids

Tropical pulmonary eosinophilia

- associated with *Wuchereria bancrofti* infection

AI + Q 123

Next question >

Textbooks

High-yield textbook

Extended textbook

Score: **16%**

1 ✕

2	✗
3	✗
4	✗
5	✗
6	✗
7	✗
8	✗
9	✗
10	✗
11	✗
12	✓
13	✗
14	✗
15	✗
16	✗
17	✗
18	✗
19	✗
20	✗
21	✗
22	✗
23	✓
24	✗
25	✗
26	✗
27	✗
28	✗
29	✓
30	✗
31	✓
32	✗
33	✗
34	✗
35	✗
36	✓
37	✓

38	✗
39	✗
40	✗
41	✓
42	✗
43	✗
44	✗
45	✗
46	✗
47	✗
48	✗
49	✓
50	✗

All contents of this site are © 2024 Passmedicine Limited
Back to top

A 62-year-old gentleman comes to the respiratory clinic for review. He was seen by his GP after presenting with pleuritic chest pain and slight breathlessness. The GP was concerned and arranged for a chest X-ray which shows pleural plaques and a slight right-sided pleural effusion. He has a past medical history of type 2 diabetes, hypertension and angina. He takes ramipril, amlodipine, metformin and has a GTN spray for when he needs it. He worked as a plumber over 30 years ago. On examination he has clubbing and slightly reduced air entry in the right base of his lungs, with some dullness on percussion. A diagnosis of asbestosis is suspected. What feature of his history or examination is evidence towards poor prognosis?

- Comorbidity with ischaemic heart disease
- Shortness of breath
- Pleuritic pain
- Clubbing
- Male sex

Submit answer

Reference ranges

Score: **0%**

1 -
2 -

All contents of this site are © 2024 Passmedicine Limited

A 62-year-old gentleman comes to the respiratory clinic for review. He was seen by his GP after presenting with pleuritic chest pain and slight breathlessness. The GP was concerned and arranged for a chest X-ray which shows pleural plaques and a slight right-sided pleural effusion. He has a past medical history of type 2 diabetes, hypertension and angina. He takes ramipril, amlodipine, metformin and has a GTN spray for when he needs it. He worked as a plumber over 30 years ago. On examination he has clubbing and slightly reduced air entry in the right base of his lungs, with some dullness on percussion. A diagnosis of asbestosis is suspected. What feature of his history or examination is evidence towards poor prognosis?

Comorbidity with ischaemic heart disease	22%
Shortness of breath	10%
Pleuritic pain	14%
Clubbing	38%
Male sex	17%

The correct answer is clubbing. This is a patient who presents with pleuritic chest pain and shortness of breath with a history of possible asbestos exposure (plumbing). These are common findings on diagnosis and are not associated with a difference in prognosis. Clubbing, however, has been shown to be a poor prognostic indicator as it has been associated with progression to mesothelioma.

Discuss (8) Improve

Next question

Asbestos and the lung

Asbestos can cause a variety of lung diseases from benign pleural plaques to mesothelioma.

Pleural plaques

Pleural plaques are benign and do not undergo malignant change. They, therefore don't require any follow-up. They are the most common form of asbestos-related lung disease and generally occur after a latent period of 20-40 years.

Pleural thickening

Asbestos exposure may cause diffuse pleural thickening in a similar pattern to that seen following an empyema or haemothorax. The underlying pathophysiology is not fully understood.

Asbestosis

The severity of asbestosis is related to the length of exposure. This is in contrast to mesothelioma where even very limited exposure can cause disease. The latent period is typically 15-30 years. Asbestosis typically causes lower lobe fibrosis.

Features
- dyspnoea and reduced exercise tolerance
- clubbing
- bilateral end-inspiratory crackles
- lung function tests show a restrictive pattern with reduced gas transfer

It is treated conservatively - no interventions offer a significant benefit.

Mesothelioma

Mesothelioma is a malignant disease of the pleura. Crocidolite (blue) asbestos is the most dangerous form.

Possible features
- progressive shortness-of-breath
- chest pain
- pleural effusion

Patients are usually offered palliative chemotherapy and there is also a limited role for surgery and radiotherapy. Unfortunately, the prognosis is very poor, with a median survival from diagnosis of 8-14 months.

Lung cancer

Whilst mesothelioma is in some ways synonymous with asbestos, lung cancer is actually the most common form of cancer associated with asbestos exposure. It also has a synergistic effect with cigarette smoke in terms of the increased risk. Therefore, smoking cessation is very important as the risk of lung cancer in smokers who have a history of asbestos exposure is very high.

123

Next question

Textbooks

High-yield textbook

Extended textbook

Score: **16%**

1 ✗
2 ✗
3 ✗
4 ✗
5 ✗
6 ✗
7 ✗
8 ✗
9 ✗
10 ✗
11 ✗
12 ✓
13 ✗
14 ✗
15 ✗
16 ✗
17 ✗
18 ✗
19 ✗
20 ✗
21 ✗
22 ✗
23 ✓
24 ✗
25 ✗
26 ✗
27 ✗
28 ✗
29 ✓
30 ✗
31 ✓
32 ✗
33 ✗
34 ✗
35 ✗

36	✓
37	✓
38	✗
39	✗
40	✗
41	✓
42	✗
43	✗
44	✗
45	✗
46	✗
47	✗
48	✗
49	✓
50	✗

All contents of this site are © 2024 Passmedicine Limited

Back to top

A 24-year-old woman attends the respiratory clinic for a review of her asthma treatment. The patient reported that overall, her symptoms of asthma had been well controlled in the 6 months since her last review. She had not suffered any significant exacerbations of her asthma in that time and felt she was required to use her salbutamol inhaler only around once per week (which represented a significant improvement over her normal control). The patient also reported that she was now 3 months pregnant, and had just had an unremarkable 12-week ultrasound. While she had not been planning to have a baby, the patient reported being very happy about it, and she was keen to maximise her health during this time.

The patient had a long-standing diagnosis of asthma, with her first presentations during early childhood. While the illness had only caused mild symptoms between the ages of 10 and 15 years, the patient had suffered several severe exacerbations of asthma in her late teenage years, coinciding with the time when the patient had become a regular smoker. The patient did not report any other significant on-going health problems or past medical history. In particular, she denied a history of seizures, high blood pressure or mental health problems.

The patient's current asthma treatment was a salmeterol-fluticasone combination inhaler (Seretide Accuhaler 250), one puff twice daily. She was also prescribed a metered-dose salbutamol inhaler for use as required. The patient had no history of drug allergies.

The patient reported that she continued to be a regular cigarette smoker. Since finding out she was pregnant, she had managed to reduce her regular intake to 12 cigarettes per day, reduced from her previous typical intake of 20 cigarettes per day. The patient was motivated to use her pregnancy as a motivating factor to stop smoking permanently, and during the clinic asked about medication to assist her with quitting.

What is the appropriate drug treatment strategy to assist this patient to stop smoking?

- Nicotine replacement patch with short-acting nicotine replacement
- Varenicline
- No drug treatment options available
- Bupropion
- Nicotine replacement patch only

Submit answer

Reference ranges

Score: **0%**

1 -
2 -
3 -

All contents of this site are © 2024 Passmedicine Limited
Back to top

A 24-year-old woman attends the respiratory clinic for a review of her asthma treatment. The patient reported that overall, her symptoms of asthma had been well controlled in the 6 months since her last review. She had not suffered any significant exacerbations of her asthma in that time and felt she was required to use her salbutamol inhaler only around once per week (which represented a significant improvement over her normal control). The patient also reported that she was now 3 months pregnant, and had just had an unremarkable 12-week ultrasound. While she had not been planning to have a baby, the patient reported being very happy about it, and she was keen to maximise her health during this time.

The patient had a long-standing diagnosis of asthma, with her first presentations during early childhood. While the illness had only caused mild symptoms between the ages of 10 and 15 years, the patient had suffered several severe exacerbations of asthma in her late teenage years, coinciding with the time when the patient had become a regular smoker. The patient did not report any other significant on-going health problems or past medical history. In particular, she denied a history of seizures, high blood pressure or mental health problems.

The patient's current asthma treatment was a salmeterol-fluticasone combination inhaler (Seretide Accuhaler 250), one puff twice daily. She was also prescribed a metered-dose salbutamol inhaler for use as required. The patient had no history of drug allergies.

The patient reported that she continued to be a regular cigarette smoker. Since finding out she was pregnant, she had managed to reduce her regular intake to 12 cigarettes per day, reduced from her previous typical intake of 20 cigarettes per day. The patient was motivated to use her pregnancy as a motivating factor to stop smoking permanently, and during the clinic asked about medication to assist her with quitting.

What is the appropriate drug treatment strategy to assist this patient to stop smoking?

Nicotine replacement patch with short-acting nicotine replacement	34%
Varenicline	12%
No drug treatment options available	16%
Bupropion	8%
Nicotine replacement patch only	30%

The patient is motivated to stop smoking and this can be expected to have significant benefits, both for her own long-term health and for the health of her unborn fetus. The best drug treatment option available to her in pregnancy is combination nicotine replacement therapy, consisting of a long-acting nicotine replacement patch with a short-acting nicotine formulation (either oral or nasal spray) to help manage acute cravings. When used in individuals attempting to quit smoking, combination nicotine therapy has an absolute abstinence rate of 32 %, compared to 25 % for non-combination nicotine replacement.

Nicotine replacement therapy can be prescribed in pregnancy as systematic reviews do not show significant differences in serious adverse events between treatment and control groups in pregnancy. It is also clearly safer than tobacco smoke, which contains many toxins. The expert recommendation is for use of 16-hour nicotine patches in pregnancy, rather than 24-hour patches, to reduce unnecessary exposure to nicotine.

Varenicline is an oral nicotinic receptor partial agonist that binds less effectively than nicotine. The most significant unwanted effects of varenicline are nausea and a possible increased risk of suicidal thoughts, especially in individuals with mental health problems. Bupropion is an oral nicotinic receptor antagonist with dopaminergic and adrenergic actions. It is contraindicated in individuals with a history of seizures. The absolute abstinence rates of varenicline and bupropion are 34 % and 25 % respectively. Unwanted effects include increased blood pressure and psychological effects. The safety of both varenicline and bupropion in pregnancy is unknown; therefore, the use of these medications in pregnancy should be avoided.

Hartmann-Boyce J, Aveyard P. Drugs for smoking cessation. BMJ 2016;352:i571.

Discuss (8) | Improve

Next question

Smoking cessation

NICE released guidance in 2008 on the management of smoking cessation. General points include:

- patients should be offered nicotine replacement therapy (NRT), varenicline or bupropion - NICE state that clinicians should not favour one medication over another
- NRT, varenicline or bupropion should normally be prescribed as part of a commitment to stop smoking on or before a particular date (target stop date)
- prescription of NRT, varenicline or bupropion should be sufficient to last only until 2 weeks after the target stop date. Normally, this will be after 2 weeks of NRT therapy, and 3-4 weeks for varenicline and bupropion, to allow for the different methods of administration and mode

of action. Further prescriptions should be given only to people who have demonstrated that their quit attempt is continuing
- if unsuccessful using NRT, varenicline or bupropion, do not offer a repeat prescription within 6 months unless special circumstances have intervened
- do not offer NRT, varenicline or bupropion in any combination

Nicotine replacement therapy
- adverse effects include nausea & vomiting, headaches and flu-like symptoms
- NICE recommend offering a combination of nicotine patches and another form of NRT (such as gum, inhalator, lozenge or nasal spray) to people who show a high level of dependence on nicotine or who have found single forms of NRT inadequate in the past

Varenicline
- a nicotinic receptor partial agonist
- should be started 1 week before the patients target date to stop
- the recommended course of treatment is 12 weeks (but patients should be monitored regularly and treatment only continued if not smoking)
- has been shown in studies to be more effective than bupropion
- nausea is the most common adverse effect. Other common problems include headache, insomnia, abnormal dreams
- varenicline should be used with caution in patients with a history of depression or self-harm. There are ongoing studies looking at the risk of suicidal behaviour in patients taking varenicline
- contraindicated in pregnancy and breastfeeding

Bupropion
- a norepinephrine-dopamine reuptake inhibitor and nicotinic antagonist
  - unlike many antidepressants it has a minimal effect on serotonin
- should be started 1 to 2 weeks before the patient's target date to stop
- small risk of seizures (1 in 1,000)
- contraindicated in epilepsy, pregnancy and breast feeding. Having an eating disorder is a relative contraindication

Pregnant women

NICE recommended in 2010 that all pregnant women should be tested for smoking using carbon monoxide detectors, partly because '*some women find it difficult to say that they smoke because the pressure not to smoke during pregnancy is so intense.*'. All women who smoke, or have stopped smoking within the last 2 weeks, or those with a CO reading of 7 ppm or above should be referred to NHS Stop Smoking Services.

Interventions

- the first-line interventions in pregnancy should be cognitive behaviour therapy, motivational interviewing or structured self-help and support from NHS Stop Smoking Services
- the evidence for the use of NRT in pregnancy is mixed but it is often used if the above measures failure. There is no evidence that it affects the child's birthweight. Pregnant women should remove the patches before going to bed
- as mentioned above, varenicline and bupropion are contraindicated

123

Next question

Textbooks

High-yield textbook

Extended textbook

Links

NICE 13 14

2018 Stop smoking interventions and services

NICE 11 6

2010 Quitting smoking in pregnancy and following childbirth

Suggest link Report broken link

Media

[Tobacco Dependence]

Osmosis - YouTube 6 0

[2-Minute Neuroscience: Nicotine]

Neuroscientifically Challenged - YouTube 2 1

Report broken media

Score: **16%**

1	✗
2	✗
3	✗
4	✗
5	✗
6	✗
7	✗
8	✗
9	✗
10	✗
11	✗
12	✓
13	✗
14	✗
15	✗
16	✗
17	✗

18 ✗
19 ✗
20 ✗
21 ✗
22 ✗
23 ✓
24 ✗
25 ✗
26 ✗
27 ✗
28 ✗
29 ✓
30 ✗
31 ✓
32 ✗
33 ✗
34 ✗
35 ✗
36 ✓
37 ✓
38 ✗
39 ✗
40 ✗
41 ✓
42 ✗
43 ✗
44 ✗
45 ✗
46 ✗
47 ✗
48 ✗
49 ✓
50 ✗

All contents of this site are © 2024 Passmedicine Limited
Back to top

A 45-year-old male with long standing asthma presents to his specialist doctor complaining of recurrent chest infections over the last year. He has a productive cough most mornings of thick, brownish sputum for most days of the last year and he feels it is getting worse. He has been to his general practitioner on a number of occasions and been treated with oral antibiotics and steroids but with no significant impact on symptoms. His general practitioner has also stepped up his asthma treatment to regular use of a long-acting beta-2 adrenergic agonist and an inhaled steroid, which he feels may have made a slight difference. He denies any fevers or night sweats but has lost approximately two kilograms in weight over the last year. He was diagnosed with asthma as a teenager, takes his inhalers regularly and has never had any hospital admissions. He has no other medical conditions and takes no other medications other than over the counter vitamin supplements. He drinks a moderate amount of alcohol and does not smoke. He works as an economist and travels regularly to the middle east and china.

On examination, he is comfortable at rest. His respiratory rate is 16 breaths/min, his oxygen saturation 95% breathing room air and his chest is clear to auscultation. His heart rate is 65 beats/min and his heart sounds are normal. There is no palpable lymphadenopathy in the axillae or groin.

What is the most likely diagnosis?

- Cystic fibrosis
- Allergic broncho-pulmonary aspergillosis
- Tuberculosis
- Lung cancer
- Pseudomonas infection

Submit answer

Reference ranges

Score: **0%**

1	-
2	-
3	-
4	-

All contents of this site are © 2024 Passmedicine Limited

A 45-year-old male with long standing asthma presents to his specialist doctor complaining of recurrent chest infections over the last year. He has a productive cough most mornings of thick, brownish sputum for most days of the last year and he feels it is getting worse. He has been to his general practitioner on a number of occasions and been treated with oral antibiotics and steroids but with no significant impact on symptoms. His general practitioner has also stepped up his asthma treatment to regular use of a long-acting beta-2 adrenergic agonist and an inhaled steroid, which he feels may have made a slight difference. He denies any fevers or night sweats but has lost approximately two kilograms in weight over the last year. He was diagnosed with asthma as a teenager, takes his inhalers regularly and has never had any hospital admissions. He has no other medical conditions and takes no other medications other than over the counter vitamin supplements. He drinks a moderate amount of alcohol and does not smoke. He works as an economist and travels regularly to the middle east and china.

On examination, he is comfortable at rest. His respiratory rate is 16 breaths/min, his oxygen saturation 95% breathing room air and his chest is clear to auscultation. His heart rate is 65 beats/min and his heart sounds are normal. There is no palpable lymphadenopathy in the axillae or groin.

What is the most likely diagnosis?

Cystic fibrosis	10%
Allergic broncho-pulmonary aspergillosis	72%
Tuberculosis	7%
Lung cancer	2%
Pseudomonas infection	9%

This man's symptoms are suggestive of the development of bronchiectasis - thick sputum over a long period of time. There are many causes of bronchiectasis, most of which are unlikely in this case. The lack of risk factors or constitutional symptoms makes tuberculosis less likely. The worsening in asthma control (he has had to step up on his treatment) raises the possibility of ABPA (allergic bronchopulmonary aspergillosis), a diagnosis not often found in non-asthmatics. Investigation is with chest imaging and serum aspergillus precipitins levels. Treatment is with steroids and antifungals.

Discuss (6) Improve

Next question

Allergic bronchopulmonary aspergillosis

Allergic bronchopulmonary aspergillosis results from an allergy to *Aspergillus spores*. In the exam questions often give a history of bronchiectasis and eosinophilia.

Features
- bronchoconstriction: wheeze, cough, dyspnoea. Patients may have a previous label of asthma
- bronchiectasis (proximal)

Investigations
- eosinophilia
- flitting CXR changes
- positive radioallergosorbent (RAST) test to Aspergillus
- positive IgG precipitins (not as positive as in aspergilloma)
- raised IgE

Management
- oral glucocorticoids
- itraconazole is sometimes introduced as a second-line agent

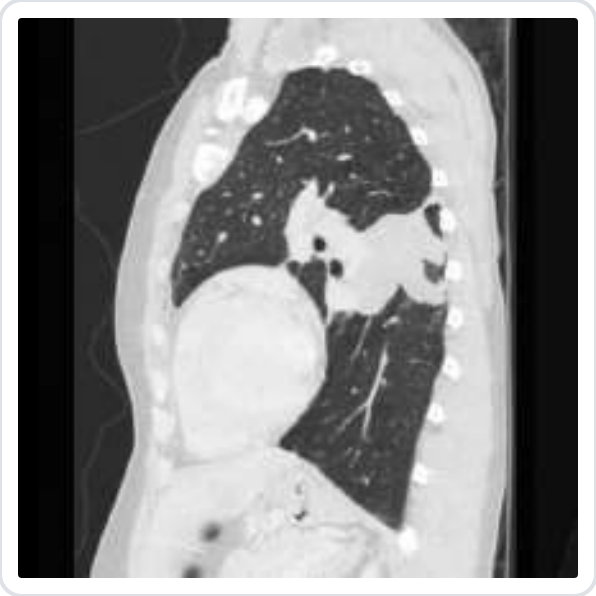

Next question

Textbooks

High-yield textbook

Extended textbook

Score: **16%**

1	✗
2	✗
3	✗
4	✗
5	✗
6	✗
7	✗
8	✗
9	✗
10	✗
11	✗
12	✓
13	✗
14	✗
15	✗
16	✗
17	✗
18	✗
19	✗
20	✗
21	✗

22	✗
23	✓
24	✗
25	✗
26	✗
27	✗
28	✗
29	✓
30	✗
31	✓
32	✗
33	✗
34	✗
35	✗
36	✓
37	✓
38	✗
39	✗
40	✗
41	✓
42	✗
43	✗
44	✗
45	✗
46	✗
47	✗
48	✗
49	✓
50	✗

All contents of this site are © 2024 Passmedicine Limited

Back to top

A 53 year-old businessman presents to the neurology clinic complaining of weakness and numbness affecting his left hand. One month ago he was irritated when he noticed that the little finger of his left hand was often getting caught when he tried to put his hand in his pocket. Since then he has noticed progressive difficulty using the left hand, associated with an unpleasant tingling sensation.

In the last two weeks he has also noticed difficulty walking, and has tripped over on several occasions. When driving he finds that his right foot often becomes stuck behind the accelerator pedal and he struggles to lift it out.

On examination, in the left hand sensation to pin-prick is diminished over the little finger and medial side of the ring finger, as well as the medial side of the palm. There is weakness of finger abduction and adduction, but thumb abduction is normal. On examination of the legs, you note diminished sensation over the lateral aspect of the right calf, as well as the dorsum of the right foot. When asked to walk on his heels, he finds it difficult to do so, and trips over the right foot.

Investigations are as follows:

Haemoglobin	14.2 g/dl
WCC	7.1 x10^9/l
Platelets	420 x10^9/l
ESR	65 mm/hr

Na^+	139 mmol/l
K^+	4.3 mmol/l
Urea	13.2 mmol/l
Creatinine	171 µmol/l
Corrected calcium	2.26 mmol/l

ANCA	Positive, with perinuclear staining pattern
PR3 antibodies	Negative
MPO antibodies	Positive

Urine dipstick	+++ blood, +++ protein

Urine microscopy	Red cell casts

Chest radiograph	Clear

What is the most likely diagnosis?

- Microscopic polyangiitis
- Polyarteritis nodosa
- Wegener's granulomatosis
- Diabetes mellitus
- Entrapment neuropathy

Submit answer

Reference ranges

Score: **0%**

1 -
2 -
3 -
4 -
5 -

All contents of this site are © 2024 Passmedicine Limited

A 53 year-old businessman presents to the neurology clinic complaining of weakness and numbness affecting his left hand. One month ago he was irritated when he noticed that the little finger of his left hand was often getting caught when he tried to put his hand in his pocket. Since then he has noticed progressive difficulty using the left hand, associated with an unpleasant tingling sensation.

In the last two weeks he has also noticed difficulty walking, and has tripped over on several occasions. When driving he finds that his right foot often becomes stuck behind the accelerator pedal and he struggles to lift it out.

On examination, in the left hand sensation to pin-prick is diminished over the little finger and medial side of the ring finger, as well as the medial side of the palm. There is weakness of finger abduction and adduction, but thumb abduction is normal. On examination of the legs, you note diminished sensation over the lateral aspect of the right calf, as well as the dorsum of the right foot. When asked to walk on his heels, he finds it difficult to do so, and trips over the right foot.

Investigations are as follows:

Haemoglobin	14.2 g/dl
WCC	7.1 x10^9/l
Platelets	420 x10^9/l
ESR	65 mm/hr

Na^+	139 mmol/l
K^+	4.3 mmol/l
Urea	13.2 mmol/l
Creatinine	171 µmol/l
Corrected calcium	2.26 mmol/l

ANCA	Positive, with perinuclear staining pattern
PR3 antibodies	Negative
MPO antibodies	Positive

Urine dipstick	+++ blood, +++ protein

Urine microscopy	Red cell casts

Chest radiograph	Clear

What is the most likely diagnosis?

Microscopic polyangiitis	53%
Polyarteritis nodosa	28%
Wegener's granulomatosis	17%
Diabetes mellitus	0%
Entrapment neuropathy	1%

This is mononeuritis multiplex with ulnar and common peroneal neuropathy. The causes of mononeuritis multiplex include vasculitis, diabetes, AIDS, amyloidosis, and rheumatoid arthritis.

The elevated urea and creatinine, haematuria with red cell casts, and proteinuria, all suggest glomerulonephritis. The combination of mononeuritis multiplex with glomerulonephritis strongly suggests systemic vasculitis. This is supported by the raised ESR.

Microscopic polyangiitis is a small-vessel vasculitis which is typically positive for p-ANCA, with antibodies against MPO (myeloperoxidase). Other features may include systemic symptoms such as fever, weight loss, and fatigue, as well as rash.

ANCA is negative in classic polyarteritis nodosa.

Wegeners granulomatosis often features upper airway disease, and is typically positive for c-ANCA, with antibodies against PR3.

Diabetes mellitus is a common cause of many peripheral neuropathies including mononeuritis multiplex, however there is nothing in the history to suggest this. Haematuria and red cell casts are not a typical feature of diabetic nephropathy, and neither is ANCA positivity.

Entrapment is a common cause of both ulnar and common peroneal neuropathy, but for both to occur simultaneously would be unusual.

Discuss (10) Improve

Next question

Microscopic polyangiitis

Microscopic polyangiitis is a small-vessel ANCA vasculitis.

Features

- renal impairment: raised creatinine, haematuria, proteinuria
- fever
- other systemic symptoms: lethargy, myalgia, weight loss
- rash: palpable purpura
- cough, dyspnoea, haemoptysis
- mononeuritis multiplex

Investigations

- pANCA (against MPO) - positive in 50-75%
- cANCA (against PR3) - positive in 40%

123

Next question

Textbooks

High-yield textbook

Extended textbook

Media

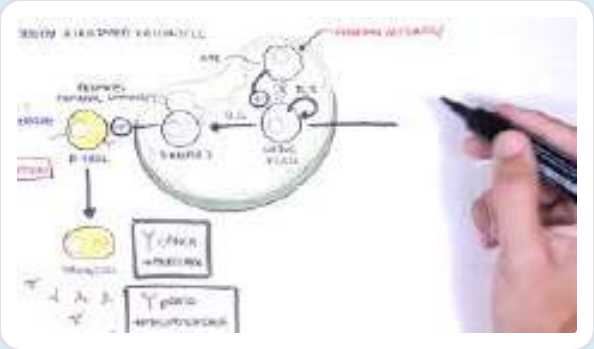

ANCA (Anti-Neutrophil Cytoplasmic Antibody) Associated Vasculitis - Causes, Pathophysiology, Types

Armando Hasudungan - YouTube 4 1

Report broken media

Score: **16%**

1 ✗
2 ✗
3 ✗
4 ✗
5 ✗
6 ✗
7 ✗
8 ✗
9 ✗
10 ✗
11 ✗
12 ✓
13 ✗
14 ✗
15 ✗
16 ✗
17 ✗
18 ✗
19 ✗
20 ✗
21 ✗
22 ✗

23	✓
24	✗
25	✗
26	✗
27	✗
28	✗
29	✓
30	✗
31	✓
32	✗
33	✗
34	✗
35	✗
36	✓
37	✓
38	✗
39	✗
40	✗
41	✓
42	✗
43	✗
44	✗
45	✗
46	✗
47	✗
48	✗
49	✓
50	✗

All contents of this site are © 2024 Passmedicine Limited

Back to top

A 75-year-old retired electrician presents with a 3-month history of progressive exertional dyspnoea, with associated chest pain. The chest pain is right-sided and is not worse on deep inspiration. He also describes intermittent haemoptysis and has noted 7kg of weight loss since the chest pain started.

A CT scan of his thorax is carried out, the images for which are given below:

© Image used on license from Radiopaedia

What is the most likely cause of this imaging appearance?

- Large cell carcinoma
- Mesothelioma
- Sarcoidosis
- Small cell lung cancer
- Tuberculosis

Submit answer

Reference ranges

Score: **0%**

1 -
2 -
3 -
4 -
5 -
6 -

All contents of this site are © 2024 Passmedicine Limited

A 75-year-old retired electrician presents with a 3-month history of progressive exertional dyspnoea, with associated chest pain. The chest pain is right-sided and is not worse on deep inspiration. He also describes intermittent haemoptysis and has noted 7kg of weight loss since the chest pain started.

A CT scan of his thorax is carried out, the images for which are given below:

© Image used on license from Radiopaedia

What is the most likely cause of this imaging appearance?

Large cell carcinoma	9%
Mesothelioma	71%
Sarcoidosis	1%
Small cell lung cancer	14%
Tuberculosis	4%

The CT shows concentric, nodular, pleural thickening. There also appears to be interlobular fissure pleural involvement. Pleural thickening can be due to a number of causes, one of which is **mesothelioma**. Other causes include pleural metastases, pleural lymphoma, chronic inflammation following empyema or recurrent pneumonia, and asbestos or silicosis-related lung disease. Pleural thickening can be differentiated from the appearance of a pleural effusion which is usually gravity dependent and crescent shaped.

Mesothelioma is a cancer of the mesothelial layer of the pleural cavity that is strongly associated with asbestos exposure, which may have occurred due to this man's previous occupation as an electrician.

Small cell lung cancer is typically seen as a solid nodule within the lung, often located centrally in the hilar or peri-hilar region. They readily metastasise but do not generally involve the pleura.

Large cell lung carcinoma would usually manifest as a large peripheral mass of solid attenuation and irregular margin. There is not usually pleural involvement.

Sarcoidosis may show peri-lymphatic nodular thickening primarily affecting the upper/mid zones, ground glass opacities, cysts, or evidence of pulmonary fibrosis. It would not cause pleural thickening.

CT findings in pulmonary **tuberculosis** often show similar patterns of disease as seen with chest x-rays, which would include fibronodular opacities in upper lobes with or without cavitation. Tuberculosis can involve the pleura but would present with a pleural effusion rather than pleural thickening as seen here.

Discuss (2) | Improve

Next question

Mesothelioma

Mesothelioma is a cancer of the mesothelial layer of the pleural cavity that is strongly associated with asbestos exposure. In a small percentage of cases, other mesothelial layers such as those in the abdomen may be affected.

Features
- Dyspnoea, weight loss, chest wall pain
- Clubbing
- 30% present as painless pleural effusion
- Only 20% have pre-existing asbestosis
- History of asbestos exposure in 85-90%, latent period of 30-40 years

Basics
- Malignancy of mesothelial cells of pleura
- Metastases to contralateral lung and peritoneum

- Right lung affected more often than left

Investigation/diagnosis
- suspicion is normally raised by a chest x-ray showing either a pleural effusion or pleural thickening
- the next step is normally a pleural CT
- if a pleural effusion is present fluid should be sent for MC&S, biochemistry and cytology (but cytology is only helpful in 20-30% of cases)
- local anaesthetic thoracoscopy is increasingly used to investigate cytology negative exudative effusions as it has a high diagnostic yield (around 95%)
- if an area of pleural nodularity is seen on CT then an image-guided pleural biopsy may be used

Management
- Symptomatic
- Industrial compensation
- Chemotherapy, Surgery if operable
- Prognosis poor, median survival 12 months

+ Q 123

Next question >

Textbooks

High-yield textbook

Extended textbook

Links

British Thoracic Society 1 2

2018 Investigation and Management of Pleural Mesothelioma

British Thoracic Society 5 0

2023 Pleural disease guidelines

Suggest link Report broken link

Media

Mesothelioma

Osmosis - YouTube 2 0

Report broken media

Score: **16%**

1 ✗
2 ✗
3 ✗
4 ✗
5 ✗
6 ✗
7 ✗

8	✗
9	✗
10	✗
11	✗
12	✓
13	✗
14	✗
15	✗
16	✗
17	✗
18	✗
19	✗
20	✗
21	✗
22	✗
23	✓
24	✗
25	✗
26	✗
27	✗
28	✗
29	✓
30	✗
31	✓
32	✗
33	✗
34	✗
35	✗
36	✓
37	✓
38	✗
39	✗
40	✗
41	✓
42	✗
43	✗

44	✗
45	✗
46	✗
47	✗
48	✗
49	✓
50	✗

All contents of this site are © 2024 Passmedicine Limited

Back to top

A 43-year-old Afro-Caribbean male presents with sudden onset palpitations and feeling generally unwell for 2 hours. An admission ECG in the emergency department demonstrates ventricular tachycardia. His heart rate is 80 beats/ minute with a blood pressure of 140/75mmHg. The patient is chemically cardioverted back to sinus rhythm with a single intravenous bolus of amiodarone. The patient was commenced on haemodialysis 9 months ago after developing end-stage renal failure over a course of 16 months with no conclusive underlying cause found for the deteriorating renal function. He also complains of a new dry cough over the past 18 months, weight loss of at least one and a half stone and general malaise, which he attributes to his deteriorating kidneys.

On examination, the patient has normal heart sounds with no additional murmurs. Auscultation of his chest demonstrates biapical find inspiratory crackles with no wheeze. Abdominal examination reveals a mild 2cm hepatomegaly with no splenomegaly. An arteriovenous fistula is noted in the left brachiocephalic region. No skin rashes are noted. An admission chest X-ray demonstrates no clear consolidation, reticular opacities in both apices and prominent bilateral hilar, with no cardiomegaly or tramlining.

Blood tests are as follows:

Hb	134 g/l
Platelets	292 * 10^9/l
WBC	12.5 * 10^9/l

Na^+	131 mmol/l
K^+	5.9 mmol/l
Urea	22.6 mmol/l
Creatinine	540 µmol/l

Bilirubin	17 µmol/l
ALP	55 u/l
ALT	70 u/l
CRP	12 mg/l
ACE (angiotensin converting enzyme)	negative

Pulmonary function tests: FVC 60% predicted FEV1 92% predicted

A bronchoalveolar lavage is performed, demonstrating lymphocytosis of 25%, CD4:CD8 ratio of 5:1, a transbronchial biopsy demonstrates non-caseating granulomas.

What is the underlying diagnosis?

- Human immunodeficiency virus (HIV)
- Miliary tuberculosis
- Amyloidosis
- Sarcoidosis
- Lymphoma

Submit answer

Reference ranges

Score: **0%**

1 -
2 -
3 -
4 -
5 -
6 -
7 -

All contents of this site are © 2024 Passmedicine Limited

Back to top

A 43-year-old Afro-Caribbean male presents with sudden onset palpitations and feeling generally unwell for 2 hours. An admission ECG in the emergency department demonstrates ventricular tachycardia. His heart rate is 80 beats/ minute with a blood pressure of 140/75mmHg. The patient is chemically cardioverted back to sinus rhythm with a single intravenous bolus of amiodarone. The patient was commenced on haemodialysis 9 months ago after developing end-stage renal failure over a course of 16 months with no conclusive underlying cause found for the deteriorating renal function. He also complains of a new dry cough over the past 18 months, weight loss of at least one and a half stone and general malaise, which he attributes to his deteriorating kidneys.

On examination, the patient has normal heart sounds with no additional murmurs. Auscultation of his chest demonstrates biapical find inspiratory crackles with no wheeze. Abdominal examination reveals a mild 2cm hepatomegaly with no splenomegaly. An arteriovenous fistula is noted in the left brachiocephalic region. No skin rashes are noted. An admission chest X-ray demonstrates no clear consolidation, reticular opacities in both apices and prominent bilateral hilar, with no cardiomegaly or tramlining.

Blood tests are as follows:

Hb	134 g/l
Platelets	292 * 10^9/l
WBC	12.5 * 10^9/l

Na^+	131 mmol/l
K^+	5.9 mmol/l
Urea	22.6 mmol/l
Creatinine	540 µmol/l

Bilirubin	17 µmol/l
ALP	55 u/l
ALT	70 u/l
CRP	12 mg/l
ACE (angiotensin converting enzyme)	negative

Pulmonary function tests: FVC 60% predicted FEV1 92% predicted

A bronchoalveolar lavage is performed, demonstrating lymphocytosis of 25%, CD4:CD8 ratio of 5:1, a transbronchial biopsy demonstrates non-caseating granulomas.

What is the underlying diagnosis?

Human immunodeficiency virus (HIV)	4%
Miliary tuberculosis	7%
Amyloidosis	17%
Sarcoidosis	70%
Lymphoma	3%

The patient has presented with multi-system disease with renal, cardiac, hepatic manifestations. In addition, the bihilar changes with apical interstitial changes, lymphocytosis, increased CD4:CD8 ratio and non-caseating granulomas on histopathology are strongly suggestive of sarcoidosis. A negative ACE is present in 25% of all patients with sarcoidosis, it has a poor negative predictive value. The most diagnostic test in differentiating against other multisystem disorders is histopathology in this case: Tb would produce caseating granulomas, lymphomas atypical lymphocytes and amyloid crossed beta sheets.

Discuss (6) Improve

Next question

Sarcoidosis: investigation

There is no one diagnostic test for sarcoidosis and hence diagnosis is still largely clinical. ACE levels have a sensitivity of 60% and specificity of 70% and are therefore not reliable in the diagnosis of sarcoidosis although they may have a role in monitoring disease activity. Routine bloods may show hypercalcaemia (seen in 10% if patients) and a raised ESR

A chest x-ray may show the following changes:
- stage 0 = normal
- stage 1 = bilateral hilar lymphadenopathy (BHL)
- stage 2 = BHL + interstitial infiltrates
- stage 3 = diffuse interstitial infiltrates only

- stage 4 = diffuse fibrosis

Other investigations
- spirometry: may show a restrictive defect
- tissue biopsy: non-caseating granulomas
- gallium-67 scan - not used routinely
- the Kveim test (where part of the spleen from a patient with known sarcoidosis is injected under the skin) is no longer performed due to concerns about cross-infection

123

Next question >

Textbooks

High-yield textbook

Extended textbook

Media

Sarcoidosis

Sarcoidosis - YouTube 7 0

Sarcoidosis

Osmosis - YouTube 4 0

Report broken media

Score: **16%**

1	✗
2	✗
3	✗
4	✗
5	✗
6	✗
7	✗
8	✗
9	✗
10	✗
11	✗
12	✓
13	✗
14	✗
15	✗
16	✗
17	✗
18	✗
19	✗
20	✗
21	✗

22	✗
23	✓
24	✗
25	✗
26	✗
27	✗
28	✗
29	✓
30	✗
31	✓
32	✗
33	✗
34	✗
35	✗
36	✓
37	✓
38	✗
39	✗
40	✗
41	✓
42	✗
43	✗
44	✗
45	✗
46	✗
47	✗
48	✗
49	✓
50	✗

All contents of this site are © 2024 Passmedicine Limited

Back to top

A 78-year-old man presents to the acute medical unit with severe back pain. He described the pain as sudden onset sharp pain which reached maximum severity within seconds.

Investigation results are as follows:

Chest x-ray	Blunting of the left costophrenic angle
Pleural sample	Bloody in appearance

What is the most useful pleural fluid marker to make a diagnosis of a haemothorax?

- pH
- Lactate
- Haematocrit
- Lactate dehydrogenase
- Triglyceride

Submit answer

Reference ranges

Score: **0%**

1 -
2 -
3 -
4 -
5 -

6 -
7 -
8 -

All contents of this site are © 2024 Passmedicine Limited Back to top

A 78-year-old man presents to the acute medical unit with severe back pain. He described the pain as sudden onset sharp pain which reached maximum severity within seconds.

Investigation results are as follows:

Chest x-ray	Blunting of the left costophrenic angle
Pleural sample	Bloody in appearance

What is the most useful pleural fluid marker to make a diagnosis of a haemothorax?

pH	7%
Lactate	4%
Haematocrit	63%
Lactate dehydrogenase	24%
Triglyceride	2%

If the pleural fluid appears bloody, a haematocrit can be obtained if there is doubt as to whether it is a haemothorax. If the haematocrit of the pleural fluid is more than half of the patient's peripheral blood haematocrit, the patient has a haemothorax

Important for me Less important

The clinical features are suggestive of an aortic dissection which is a well known cause of a haemothorax. If the pleural fluid appears bloody, a haematocrit can be obtained if there is doubt as to whether it is a haemothorax. If the haematocrit of the pleural fluid is more than half of the patient's peripheral blood haematocrit, the patient has a haemothorax.

Discuss (3) Improve

Next question

Pleural effusion: investigation and management

The British Thoracic Society (BTS) produced guidelines in 2010 covering the investigation of patients with a pleural effusion.

Imaging
- posterioranterior (PA) chest x-rays should be performed in all patients
- ultrasound is recommended: it increases the likelihood of successful pleural aspiration and is sensitive for detecting pleural fluid septations
- contrast CT is now increasingly performed to investigate the underlying cause, particularly for exudative effusions

Pleural aspiration
- as above, ultrasound is recommended to reduce the complication rate
- a 21G needle and 50ml syringe should be used
- fluid should be sent for pH, protein, lactate dehydrogenase (LDH), cytology and microbiology

Light's criteria was developed in 1972 to help distinguish between a transudate and an exudate. The BTS recommend using the criteria for borderline cases:
- exudates have a protein level of >30 g/L, transudates have a protein level of <30 g/L
- if the protein level is between 25-35 g/L, Light's criteria should be applied. An exudate is likely if at least one of the following criteria are met:
  - pleural fluid protein divided by serum protein >0.5
  - pleural fluid LDH divided by serum LDH >0.6
  - pleural fluid LDH more than two-thirds the upper limits of normal serum LDH

Other characteristic pleural fluid findings:
- low glucose: rheumatoid arthritis, tuberculosis
- raised amylase: pancreatitis, oesophageal perforation
- heavy blood staining: mesothelioma, pulmonary embolism, tuberculosis

Pleural infection

All patients with a pleural effusion in association with sepsis or a pneumonic illness require diagnostic pleural fluid sampling

- if the fluid is purulent or turbid/cloudy a chest tube should be placed to allow drainage
- if the fluid is clear but the **pH is less than 7.2 in patients with suspected pleural infection a chest tube should be placed**

Management of recurrent pleural effusion

Options for managing patients with recurrent pleural effusions include:

- recurrent aspiration
- pleurodesis
- indwelling pleural catheter
- drug management to alleviate symptoms e.g. opioids to relieve dyspnoea

+ Q 123

Next question

Textbooks

High-yield textbook

Extended textbook

Links

British Thoracic Society 17 14

2023 Pleural disease guidelines

Royal College of Physicians

13 7

2012 Pleural infection review

Suggest link | Report broken link

Media

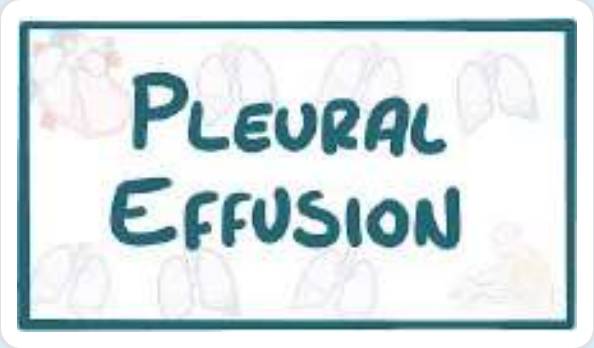

Pleural effusion

Osmosis - YouTube 8 1

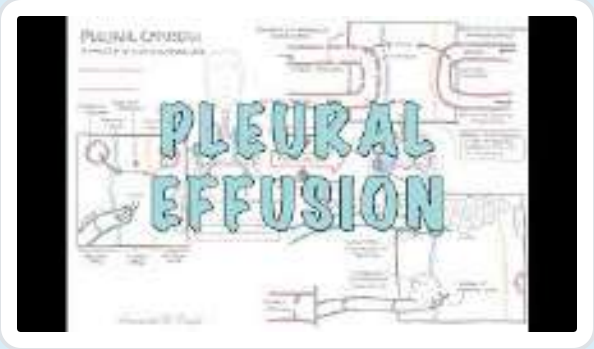

Pleural effusion

Armando Hasudungan - YouTube 6 1

Report broken media

Score: **16%**

1 ✗
2 ✗
3 ✗
4 ✗
5 ✗
6 ✗
7 ✗
8 ✗
9 ✗
10 ✗
11 ✗

12	✓
13	✗
14	✗
15	✗
16	✗
17	✗
18	✗
19	✗
20	✗
21	✗
22	✗
23	✓
24	✗
25	✗
26	✗
27	✗
28	✗
29	✓
30	✗
31	✓
32	✗
33	✗
34	✗
35	✗
36	✓
37	✓
38	✗
39	✗
40	✗
41	✓
42	✗
43	✗
44	✗
45	✗
46	✗
47	✗

48	✗
49	✓
50	✗

All contents of this site are © 2024 Passmedicine Limited

A 72-year-old man presented with shortness of breath and haemoptysis. His past medical history includes polymyalgia rheumatica and Paget's disease. He is very fit and active and is independent of activities of daily living. He drives and does his own shopping, and attends the gym twice a week alongside tai chi lessons.

A chest x-ray revealed a left-sided mass.

CT thorax, abdomen, pelvis: There is a 4cm solid mass left-sided left upper lobe lung mass causing airway compression and partial lobe collapse. There is no evidence of distant metastases.

A biopsy of the lesion confirms adenocarcinoma.

What would be the most appropriate management option for this patient?

- Chemotherapy
- Complete resection with lobectomy and adjuvant chemotherapy
- Complete resection with lobectomy and adjuvant radiotherapy
- Pneumonectomy with adjuvant chemo-radiotherapy
- Radiotherapy

Submit answer

Reference ranges

3 -
4 -
5 -
6 -
7 -
8 -
9 -

All contents of this site are © 2024 Passmedicine Limited

A 72-year-old man presented with shortness of breath and haemoptysis. His past medical history includes polymyalgia rheumatica and Paget's disease. He is very fit and active and is independent of activities of daily living. He drives and does his own shopping, and attends the gym twice a week alongside tai chi lessons.

A chest x-ray revealed a left-sided mass.

CT thorax, abdomen, pelvis: There is a 4cm solid mass left-sided left upper lobe lung mass causing airway compression and partial lobe collapse. There is no evidence of distant metastases.

A biopsy of the lesion confirms adenocarcinoma.

What would be the most appropriate management option for this patient?

Chemotherapy	3%
Complete resection with lobectomy and adjuvant chemotherapy	51%
Complete resection with lobectomy and adjuvant radiotherapy	30%
Pneumonectomy with adjuvant chemo-radiotherapy	12%
Radiotherapy	5%

Patients with stage I or II non-small cell lung cancer should be offered surgical resection if they are fit for surgery

Important for me   Less important

Complete resection with lobectomy and adjuvant chemotherapy is the correct answer. This patient has stage II lung cancer (i.e. it is between 4-5cm, there is no distant spread, but there is blockage of the airway causing partial lobe collapse). All patients with stage I or II lung cancers should be offered surgical resection and adjuvant chemotherapy. This is done with curative intent.

Complete resection with lobectomy and adjuvant radiotherapy is incorrect. Radiotherapy can be offered as a sole treatment for patients with stage I or II NSLC who are not fit for surgery, and this is offered with curative intent. It is generally not used as an adjuvant treatment alongside surgical resection unless the resection is incomplete.

Pneumonectomy with adjuvant chemo-radiotherapy is incorrect. A pneumonectomy would not be the best option here as the mass is confined to the left upper lobe, a lobectomy would be preferable to preserve as much lung tissue as possible for the patient.

Radiotherapy is incorrect. This could be offered with curative intent if the patient was not fit for surgery, but here we have an active and well patient who should be given the opportunity to discuss surgical resection.

Chemotherapy is incorrect. Chemotherapy could be offered to patients with stage III or IV disease. Our patient here has stage II disease and so should be offered surgery. Stage III disease may include spread to mediastinal lymph nodes, spread to another lobe in the same lung, and invasion of the oesophagus, aorta, and mediastinum, for example.

Discuss (2) Improve

Next question

Lung cancer: management

Around 13% of those diagnosed with cancer in the UK will have lung carcinoma. Of those diagnosed with lung cancer, approximately 75% will be found to have stage III/IV disease at presentation, which has huge implications on the management options available to these patients.

Lung cancer is histologically subdivided as follows:
- **Non-small cell carcinoma (NSCLC):** accounts for 85% of all lung cancers and can be further subdivided into squamous cell carcinoma, adenocarcinoma, and large cell carcinoma
- **Small cell carcinoma (SCLC):** accounts for 15% of all lung cancers. SCLC is typically more aggressive and carries a worse prognosis

The histological subtype is clinically important as the approach to management differs between NSCLC and SCLC. Treatment is also dependant upon the disease stage and patient fitness.

General management principles
- **Multi-disciplinary team (MDT):** All patients with suspected or confirmed lung cancer should be discussed at an MDT to formulate an effective treatment plan
- **Smoking Cessation:** For both subtypes of lung cancer, smoking cessation should be encouraged and supported. Patients should be informed that by stopping smoking they are

increasing their chances of successful treatment and survival. To help patients stop smoking offer nicotine replacement therapy and refer to smoking cessation services

NSCLC Management

Surgical resection:
- Lobectomy (with hilar and mediastinal lymph node resection/sampling) is first-line treatment for those with stage I or II cancer who are medically fit for surgery
- This surgery is done with curative intent

Radiotherapy:
- Is first-line for those with stage I-III disease who are not suitable for surgery.
- This treatment is given with curative intent.

Chemotherapy:
- Is offered to those with stage III or IV disease to improve survival and quality of life.
- First line regimes use a combination of:
  - Third-generation chemotherapy agent: e.g. docetaxel, paclitaxel or gemcitabine
  - Platinum agent: e.g. carboplatin or cisplatin

Combination therapy:
- Adjuvant chemotherapy should be offered to patients who have undergone a **complete resection**
- Adjuvant radiotherapy is offered to patients who have had a **incomplete resection** of their tumour
- All patients with stage I-III disease who are not suitable for surgery should be considered for chemoradiotherapy

SCLC Management

Surgery is rarely used and only considered in very early stage I disease - SCLC is disseminated at presentation in almost all patients. The majority of SCLC patients are treated with chemotherapy in combination with radiotherapy.

Limited-stage SCLC:
- Limited-stage disease is defined as SCLC without distant metastasis (T1-4, N0-3, M0).
- First-line treatment involves:

    - 4-6 cycles of Cisplatin-based combination chemotherapy
    - Concurrent or adjunct thoracic radiotherapy is only considered if there has been a good response to chemotherapy

Extensive-stage SCLC:

- Extensive-stage disease is defined as SCLC with distant metastasis (T1-4, N0-3, M1).
- First-line treatment involves:

+ Platinum-based combination therapy where the patient is reassessed for a response after each cycle (up to a maximum of 6 cycles)

- Concurrent or adjunct thoracic radiotherapy can be considered if there has been a good response to chemotherapy at both the primary and metastatic sites.

Relapse after initial treatment:

- For all stages of SCLC second-line therapy can be considered in those who have relapsed. This includes:
    - Further chemotherapy (maximum 6 cycles)
    - Palliative radiotherapy to control local symptoms

Palliative care

All patients with NSCLC and SCLC who cannot be offered curative treatment should be referred to palliative care. Therapy can involve:

- Palliative radiotherapy for symptom control
- Endobronchial stenting or debulking for bronchial obstruction
- Pleural drainage or aspiration for pleural effusion
- Dexamethasone therapy for those with symptomatic brain metastasis
- Opioid therapy to relieve cough and breathlessness

Complications

- **Local disease spread:** nerve palsy; superior vena cava obstruction and pericarditis
- **Metastatic spread:** Brain, spinal cord, bone, liver and adrenal glands are common sites

Prognosis

- SCLC has a worse prognosis when compared to NSCLC
- 5-year survival is around 10%

123

Next question >

Textbooks

High-yield textbook

Extended textbook

Links

Radiopaedia — 1 / 0

Lung cancer review

NICE — 0 / 0

2011 Lung cancer: diagnosis and management

Suggest link

Report broken link

Media

Lung cancer

MedFlix - YouTube — 2 / 0

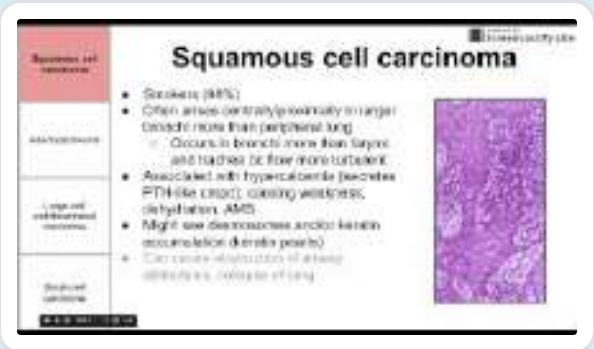

[Cancers of the lung]

MedLecturesMadeEasy - YouTube 👍 1 👎 1

[Lung Cancer: An Overview]

Oncology for Medical Students - YouTube 👍 1 👎 1

Report broken media

Score: **16%**

1	✗
2	✗
3	✗
4	✗
5	✗
6	✗
7	✗
8	✗
9	✗
10	✗
11	✗
12	✓
13	✗
14	✗
15	✗
16	✗
17	✗

18	✗
19	✗
20	✗
21	✗
22	✗
23	✓
24	✗
25	✗
26	✗
27	✗
28	✗
29	✓
30	✗
31	✓
32	✗
33	✗
34	✗
35	✗
36	✓
37	✓
38	✗
39	✗
40	✗
41	✓
42	✗
43	✗
44	✗
45	✗
46	✗
47	✗
48	✗
49	✓
50	✗

All contents of this site are © 2024 Passmedicine Limited

Back to top

A 52-year-old man presents to the emergency department with shortness of breath. This started recently following a flight from Australia. He is morbidly obese and has a past medical history of type two diabetes mellitus, high cholesterol, hypertension and a previous cholecystectomy. He denies any leg pain or swelling and denies any chest pain. Observations are stable, and an ECG demonstrates sinus rhythm. A chest X-ray is clear. He undergoes a CT pulmonary angiogram (CTPA) to exclude a pulmonary embolus (PE). The CTPA is reported as finding no evidence of PE but notes a 7mm pulmonary nodule in the left lower lobe.

How should the pulmonary nodule be investigated or monitored?

- Urgent CT-PET
- Urgent image-guided biopsy
- CT chest in three months
- CT chest in one year
- No further investigations needed

Submit answer

Reference ranges

Score: **0%**

1 -
2 -
3 -
4 -
5 -
6 -

7	-
8	-
9	-
10	-

All contents of this site are © 2024 Passmedicine Limited

A 52-year-old man presents to the emergency department with shortness of breath. This started recently following a flight from Australia. He is morbidly obese and has a past medical history of type two diabetes mellitus, high cholesterol, hypertension and a previous cholecystectomy. He denies any leg pain or swelling and denies any chest pain. Observations are stable, and an ECG demonstrates sinus rhythm. A chest X-ray is clear. He undergoes a CT pulmonary angiogram (CTPA) to exclude a pulmonary embolus (PE). The CTPA is reported as finding no evidence of PE but notes a 7mm pulmonary nodule in the left lower lobe.

How should the pulmonary nodule be investigated or monitored?

Urgent CT-PET	8%
Urgent image-guided biopsy	5%
CT chest in three months	63%
CT chest in one year	19%
No further investigations needed	5%

The correct answer is CT chest in three months. This is a pulmonary nodule which is larger than 5mm in size, and therefore has a significant potential of growing. Based on this, the British Thoracic Society (BTS) recommends surveillance. Only nodules which are greater than 8mm in diameter and have a greater than 10% risk of malignancy, as assessed by the Brock model (this can be accessed on the BTS website) should undergo PET-CT and then, based on outcomes, be assessed for obtaining a histological sample.

The timing of the follow-up CT is based on the nodule's size. A nodule of 5-6mm should be scanned at one year, whilst larger nodules should be scanned at three months (unless being otherwise investigated).

Discuss (5) Improve

Next question

Solitary lung nodule ★

BTS guidelines for lung nodules:

- Nodule <5mm, or clear benign features, or unsuitable for treatment: can be discharged
- Nodule =>8mm and high risk*: then CT-PET, and if CT-PET shows high uptake then biopsy
- Nodule 5-6mm, or =>8mm and low-risk*: then CT surveillance
- CT surveillance: if 5-6mm then at 1 year, if =>6 then in three months

*To determine the risk of malignancy following CT the BTS uses the Brock model

+ Q 123

Next question ›

Textbooks

High-yield textbook

Extended textbook

Score: **16%**

1 ✗
2 ✗
3 ✗
4 ✗
5 ✗

6	✗
7	✗
8	✗
9	✗
10	✗
11	✗
12	✓
13	✗
14	✗
15	✗
16	✗
17	✗
18	✗
19	✗
20	✗
21	✗
22	✗
23	✓
24	✗
25	✗
26	✗
27	✗
28	✗
29	✓
30	✗
31	✓
32	✗
33	✗
34	✗
35	✗
36	✓
37	✓
38	✗
39	✗
40	✗
41	✓

42	✗
43	✗
44	✗
45	✗
46	✗
47	✗
48	✗
49	✓
50	✗

All contents of this site are © 2024 Passmedicine Limited

A 60-year-old caucasian female attends the respiratory clinic for review, She has been referred by her GP after presenting complaining of a chronic cough which has persisted for 6 months. The cough is productive, however she denies any haemoptysis. The patient's husband has commented that she appears to have lost weight during this time period, and she admits to unintentionally going down a dress size.

Before the onset of her cough, the patient reports that she had been reasonably fit and well, walking half an hour every day. She has never smoked and does not have any underlying respiratory pathology. She denies any history of fever or night sweats and has recently traveled to Italy for a summer holiday where she visited a famous bird sanctuary.

You review her chest radiograph which was performed prior to the clinic. There is an increased opacity in the right upper lung field. You perform a number of further investigations detailed below:

Hb	140g/l	Na^+	138 mmol/l
Platelets	400 * 10^9/l	K^+	5.0 mmol/l
WBC	11.0 * 10^9/l	Urea	3.0 mmol/l
Neuts	6.6 * 10^9/l	Creatinine	89 µmol/l
Lymphs	2.0 * 10^9/l	CRP	18 mg/l
Eosin	0.01 * 10^9/l	IFNγ-release assay	Negative
Sputum MC&S	Normal Flora	Sputum Acid Fast Bacilli (AFB)	Positive x 3

You also send the patient for a high resolution CT (HRCT) scan, which demonstrates a cavity in the right upper lobe with associated tree-in-bud appearances in the surrounding lung. There is no associated lymphadenopathy. What is the most likely causative organism for this presentation?

- Klebsiella species
- Mycobacterium tuberculosis
- Mycobacterium kansasii
- Allergic bronco-pulmonary aspergillosis (ABPA)

Staphylococcal aureus

Submit answer

Reference ranges

Score: **0%**

1	-
2	-
3	-
4	-
5	-
6	-
7	-
8	-
9	-
10	-
11	-

All contents of this site are © 2024 Passmedicine Limited

A 60-year-old caucasian female attends the respiratory clinic for review, She has been referred by her GP after presenting complaining of a chronic cough which has persisted for 6 months. The cough is productive, however she denies any haemoptysis. The patient's husband has commented that she appears to have lost weight during this time period, and she admits to unintentionally going down a dress size.

Before the onset of her cough, the patient reports that she had been reasonably fit and well, walking half an hour every day. She has never smoked and does not have any underlying respiratory pathology. She denies any history of fever or night sweats and has recently traveled to Italy for a summer holiday where she visited a famous bird sanctuary.

You review her chest radiograph which was performed prior to the clinic. There is an increased opacity in the right upper lung field. You perform a number of further investigations detailed below:

Hb	140g/l	Na^+	138 mmol/l
Platelets	400 * 10^9/l	K^+	5.0 mmol/l
WBC	11.0 * 10^9/l	Urea	3.0 mmol/l
Neuts	6.6 * 10^9/l	Creatinine	89 µmol/l
Lymphs	2.0 * 10^9/l	CRP	18 mg/l
Eosin	0.01 * 10^9/l	IFNγ-release assay	Negative
Sputum MC&S	Normal Flora	Sputum Acid Fast Bacilli (AFB)	Positive x 3

You also send the patient for a high resolution CT (HRCT) scan, which demonstrates a cavity in the right upper lobe with associated tree-in-bud appearances in the surrounding lung. There is no associated lymphadenopathy. What is the most likely causative organism for this presentation?

- Klebsiella species 2%
- Mycobacterium tuberculosis 26%
- Mycobacterium kansasii 58%
- Allergic bronco-pulmonary aspergillosis (ABPA) 13%

Staphylococcal aureus 1%

Non-tuberculous mycobacteria (NTM) pulmonary infection is increasing in prevalence within the non-HIV population. There are over 100 different species on NTM, the geographical distribution of which varies between region and country.

Diagnosis of pulmonary NTM infection can be challenging given the environmental nature of the organisms.

This question tests your understanding of the common presentations of pulmonary non-tuberculous mycobacterium (NTM) infection in immunocompetent individuals. NTM infection in the non-HIV population is challenging diagnosis to make due to the environmental nature of NTM.

NTM can present in a variety of patterns commonly described based on the radiological characteristics demonstrated. The main types are:

- Hypersensitive-like disease
- Cavitating disease
- Bronchiectasis with or without nodules

Diagnosis can be made by following the joint American Thoracic Society / Infectious Diseases Society of America (ATS/IDSA) guidelines which were published in 2007. Diagnosis requires a range of clinical, radiological and microbiological characteristics to be fulfilled as described below:

Clinical: Pulmonary symptoms (e.g. cough, sputum, or constitutional) and exclusion of alternative diagnosis

Radiological: Chest X-ray or HRCT demonstrating cavities, bronchiectasis and or nodules
Microbiological: Two or more positive sputum samples for an NTM species taken on separate days (or one of more positive sample from bronchoalveolar lavage or tissue biopsy)

In this question, although several of the alternative answers have the ability to cause cavitating disease of the lungs, the multiple positive AFB sputum samples point towards a mycobacterial cause. The negative IFNγ-release assay points away from the patient having tuberculosis, leaving Mycobacterium kansasii as the leading answer. However, it is worth noting that there are reports of cross reactivity between certain NTM species and IFNγ-release assay's.

ATS/IDSA guidelines: https://www.thoracic.org/statements/resources/mtpi/nontuberculous-mycobacterial-diseases.pdf

Discuss (4) Improve

Next question

Nontuberculous mycobacteria

Nontuberculous mycobacteria (NTM) are mycobacterial species other than those belonging to the *Mycobacterium tuberculosis* complex. NTM are typically free-living organisms that are common in the environment.

Most non-tuberculous mycobacteria are caused by *M. avium* complex (MAC) organisms.

Presentations include:

- pulmonary disease
  - cavitating lesions
  - nodular / bronchiectatic disease
- disseminated disease

Next question

Textbooks

High-yield textbook

Extended textbook

Links

British Thoracic Society

0 0

2017 Management of non-tuberculous mycobacterial pulmonary disease (NTM-PD)

Suggest link | Report broken link

Score: **16%**

1	✗
2	✗
3	✗
4	✗
5	✗
6	✗
7	✗
8	✗
9	✗
10	✗
11	✗
12	✓
13	✗
14	✗
15	✗
16	✗
17	✗
18	✗
19	✗
20	✗
21	✗
22	✗
23	✓
24	✗
25	✗
26	✗
27	✗

28	✗
29	✓
30	✗
31	✓
32	✗
33	✗
34	✗
35	✗
36	✓
37	✓
38	✗
39	✗
40	✗
41	✓
42	✗
43	✗
44	✗
45	✗
46	✗
47	✗
48	✗
49	✓
50	✗

All contents of this site are © 2024 Passmedicine Limited

Back to top

A 53-year-old man is reviewed in the respiratory outpatient clinic with progressive shortness of breath. He has a past medical history of chronic obstructive pulmonary disease and hypercholesterolaemia. He is on regular atorvastatin, salbutamol and symbicort. He still smokes 5 cigarettes daily and has a 40 pack-year history. He lives with his wife and his exercise tolerance is approximately 30 yards.

Clinical examination reveals hyper-resonance to percussion bilaterally and a barrel-shaped chest. There is moderate harsh-sounding wheeze on auscultation. The jugular venous pulse is not raised and there is no peripheral oedema. The heart sounds are normal and the pulse is regular. His fingertips are stained with nicotine. There is no clubbing.

Lung function tests:

FEV1	35% (predicted)
FVC	68% (predicted)
FEV1/FVC	51.4%

Blood tests:

Hb	154 g/L	Male: (135-180) Female: (115 - 160)
Platelets	211 * 10^9/L	(150 - 400)
WBC	7.2 * 10^9/L	(4.0 - 11.0)
Na^+	133 mmol/L	(135 - 145)
K^+	4.4 mmol/L	(3.5 - 5.0)
Urea	5.3 mmol/L	(2.0 - 7.0)
Creatinine	99 µmol/L	(55 - 120)
Bilirubin	14 µmol/L	(3 - 17)
ALP	91 u/L	(30 - 100)
ALT	34 u/L	(3 - 40)
Î³GT	66 u/L	(8 - 60)
D-dimer	333 ng/ml	(<500)
Albumin	36 g/L	(35 - 50)

CRP	4mg/L	(<5)
BNP	88 pg/ml	(<100)

Plain radiography of the chest demonstrates generalized increased lucency bilaterally but clear lung fields.

Given the clinical history, what is the appropriate next step in management?

Add a long-acting beta antagonist	21%
Add furosemide and switch salbutamol to ipratropium bromide	1%
Add theophylline	3%
Switch salbutamol to ipratropium bromide	4%
Add a long acting muscarinic antagonist (LAMA)	71%

COPD - still breathless despite using SABA/SAMA and a LABA + ICS → add a LAMA

Important for me   Less important

Add a long-acting muscarinic antagonist (LAMA) is correct. This patient has worsening shortness of breath on a background of COPD. Common differential diagnoses have been excluded such as pulmonary embolism (normal d-dimer), heart failure (clinical examination and normal BNP) and infection (normal WCC, CRP and chest x-ray). The explanation for his symptoms is therefore worsening COPD. If patients are still breathless despite using a SABA and LABA + ICS (i.e. symbicort), then a LAMA should be added.

Add a long-acting beta antagonist is incorrect. The patient is already taking a combined LABA + inhaled corticosteroids (i.e. symbicort).

Add theophylline is incorrect. This should only be trialled once inhaled options have been exhausted.

Switch salbutamol to ipratropium bromide is incorrect. This will not be sufficiently effective.

Add furosemide and switch salbutamol to ipratropium bromide is incorrect. The patient has no clinical evidence of heart failure or fluid overload and has a normal BNP. Therefore furosemide is not indicated.

COPD: stable management

NICE updated its guidelines on the management of chronic obstructive pulmonary disease (COPD) in 2018.

General management

- >smoking cessation advice: including offering nicotine replacement therapy, varenicline or bupropion
- annual influenza vaccination
- one-off pneumococcal vaccination
- pulmonary rehabilitation to all people who view themselves as functionally disabled by COPD (usually Medical Research Council [MRC] grade 3 and above)

Bronchodilator therapy

- a short-acting beta2-agonist (SABA) or short-acting muscarinic antagonist (SAMA) is first-line treatment
- for patients who remain breathless or have exacerbations despite using short-acting bronchodilators the next step is determined by whether the patient has '*asthmatic features/features suggesting steroid responsiveness*'

There are a number of criteria NICE suggest to determine whether a patient has asthmatic/steroid responsive features:

- any previous, secure diagnosis of asthma or of atopy
- a higher blood eosinophil count - note that NICE recommend a full blood count for all patients as part of the work-up
- substantial variation in FEV1 over time (at least 400 ml)
- substantial diurnal variation in peak expiratory flow (at least 20%)

Interestingly NICE do not recommend formal reversibility testing as one of the criteria. In the guidelines they state that '*routine spirometric reversibility testing is not necessary as part of the diagnostic process or to plan initial therapy with bronchodilators or corticosteroids. It may be unhelpful or misleading...*'. They then go on to discuss why they have reached this conclusion. Please see the guidelines for more details.

No asthmatic features/features suggesting steroid responsiveness

- add a long-acting beta2-agonist (LABA) + long-acting muscarinic antagonist (LAMA)
    - if already taking a SAMA, discontinue and switch to a SABA

Asthmatic features/features suggesting steroid responsiveness
- LABA + inhaled corticosteroid (ICS)
- if patients remain breathless or have exacerbations offer triple therapy i.e. LAMA + LABA + ICS
    - if already taking a SAMA, discontinue and switch to a SABA
- NICE recommend the use of combined inhalers where possible

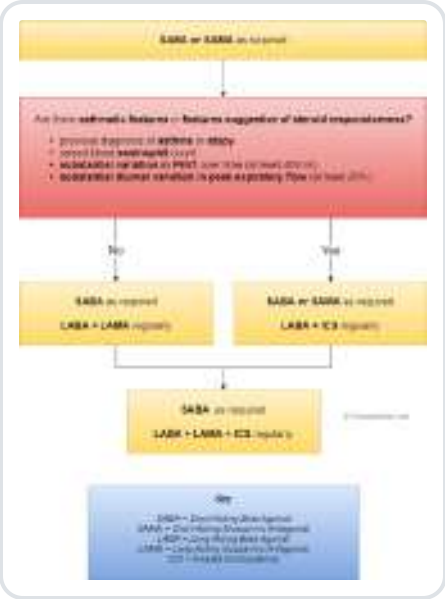

Oral theophylline
- NICE only recommends theophylline after trials of short and long-acting bronchodilators or to people who cannot used inhaled therapy
- the dose should be reduced if macrolide or fluoroquinolone antibiotics are co-prescribed

Oral prophylactic antibiotic therapy
- azithromycin prophylaxis is recommended in select patients
- patients should not smoke, have optimised standard treatments and continue to have exacerbations
- other prerequisites include a CT thorax (to exclude bronchiectasis) and sputum culture (to exclude atypical infections and tuberculosis)
- LFTs and an ECG to exclude QT prolongation should also be done as azithromycin can prolong the QT interval

Standby medication: NICE recommend offering a short course of oral corticosteroids and oral antibiotics to keep at home if: NICE
- have had an exacerbation within the last year
- understand how to take the medication, and are aware of associated risks and benefits
- know to when to seek help and when to ask for replacements once medication has been used

Mucolytics
- should be 'considered' in patients with a chronic productive cough and continued if symptoms improve

Phosphodiesterase-4 (PDE-4) inhibitors NICE

- oral PDE-4 inhibitors such as roflumilast reduce the risk of COPD exacerbations in patients with severe COPD and a history of frequent COPD exacerbations
- NICE recommend if:
  - the disease is severe, defined as a forced expiratory volume in 1 second (FEV1) after a bronchodilator of less than 50% of predicted normal, and
  - the person has had 2 or more exacerbations in the previous 12 months despite triple inhaled therapy with a long-acting muscarinic antagonist, a long-acting beta-2 agonist and an inhaled corticosteroid

Cor pulmonale

- features include peripheral oedema, raised jugular venous pressure, systolic parasternal heave, loud P2
- use a loop diuretic for oedema, consider long-term oxygen therapy
- ACE-inhibitors, calcium channel blockers and alpha blockers are not recommended by NICE

Factors which may improve survival in patients with stable COPD

- smoking cessation - the single most important intervention in patients who are still smoking
- long term oxygen therapy in patients who fit criteria
- lung volume reduction surgery in selected patients

AI + Q 123

Next question >

Textbooks

High-yield textbook

Extended textbook

Links

Global Initiative for Chronic Obstructive Lung Disease 14 32

GOLD criteria 2017

NICE 33 30

2018 COPD guidelines

NICE 15 10

Roflumilast NICE recommendations

NICE 65 18

2018 COPD management diagram

Suggest link

Report broken link

Media

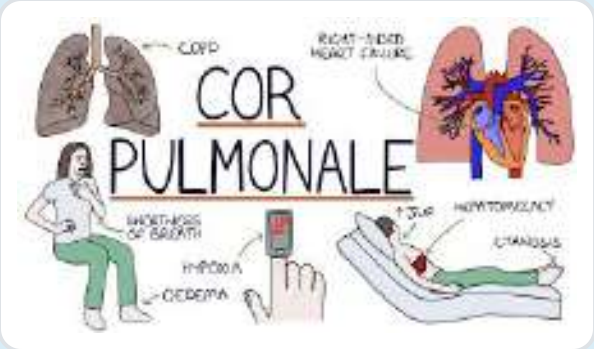

Cor pulmonale

Zero To Finals - YouTube 5 0

Chronic bronchitis

Osmosis - YouTube 3 0

Cor pulmonale

Osmosis - YouTube 1 0

Understanding COPD

Armando Hasudungan - YouTube 0 0

All about COPD (for Medical Students)

MedFlix - YouTube 3 1

Report broken media

Score: **16%**

1 ✗
2 ✗
3 ✗
4 ✗
5 ✗
6 ✗
7 ✗
8 ✗
9 ✗
10 ✗
11 ✗
12 ✓
13 ✗
14 ✗
15 ✗
16 ✗

17	✗
18	✗
19	✗
20	✗
21	✗
22	✗
23	✓
24	✗
25	✗
26	✗
27	✗
28	✗
29	✓
30	✗
31	✓
32	✗
33	✗
34	✗
35	✗
36	✓
37	✓
38	✗
39	✗
40	✗
41	✓
42	✗
43	✗
44	✗
45	✗
46	✗
47	✗
48	✗
49	✓
50	✗

All contents of this site are © 2024 Passmedicine Limited

A 67-year-old gentleman presents to the respiratory clinic via the 2-week rule. He presented to his general practitioner with haemoptysis and a persistent cough. On examination in the clinic, you observe that his clothes are loosely fitted. Chest percussion reveals left upper zone dullness. Chest X-ray confirms the presence of a left upper zone mass. After discussion with your consultant an urgent staging Computerised Tomography (CT) is arranged which unfortunately confirms a large left upper zone mass, mediastinal lymph node involvement and hepatocellular metastases. His performance status is 1. Hyponatraemia is noted on the bloods you requested in the clinic.

Na^+	126 mmol/l
K^+	4.1 mmol/l
Urea	7.5 mmol/l
Creatinine	91 µmol/l

In the context of the most likely diagnosis and staging, what would be the most appropriate treatment option?

- Lobectomy
- Partial pneumonectomy
- Palliation
- Chemotherapy
- Radiotherapy

Submit answer

Reference ranges

Score: **0%**

1	-
2	-
3	-
4	-
5	-
6	-
7	-
8	-
9	-
10	-
11	-
12	-
13	-

All contents of this site are © 2024 Passmedicine Limited

Back to top

A 67-year-old gentleman presents to the respiratory clinic via the 2-week rule. He presented to his general practitioner with haemoptysis and a persistent cough. On examination in the clinic, you observe that his clothes are loosely fitted. Chest percussion reveals left upper zone dullness. Chest X-ray confirms the presence of a left upper zone mass. After discussion with your consultant an urgent staging Computerised Tomography (CT) is arranged which unfortunately confirms a large left upper zone mass, mediastinal lymph node involvement and hepatocellular metastases. His performance status is 1. Hyponatraemia is noted on the bloods you requested in the clinic.

Na^+	126 mmol/l
K^+	4.1 mmol/l
Urea	7.5 mmol/l
Creatinine	91 μmol/l

In the context of the most likely diagnosis and staging, what would be the most appropriate treatment option?

- Lobectomy 4%
- Partial pneumonectomy 2%
- Palliation 33%
- Chemotherapy 52%
- Radiotherapy 10%

From the clinical details given the candidate would be expected to understand that the most likely underlying diagnosis is small cell lung carcinoma. Hyponatraemia secondary to syndrome of inappropriate antidiuretic hormone secretion (SIADH) is a classic MRCP association.

Small cell lung carcinoma has a poor prognosis. National Institute for Clinical Excellence (NICE) guidelines state that in the context of small cell carcinoma with extensive disease chemotherapy should be offered as a treatment option provided after multidisciplinary team discussion the patient is deemed fit enough.

There is no role for surgical resection in small cell carcinoma, however, radiotherapy is an option in those with limited disease.

Discuss (10) Improve

Next question

Lung cancer: small cell

Features

- usually central
- arise from APUD* cells
- associated with ectopic ADH, ACTH secretion
- ADH → hyponatraemia
- ACTH → Cushing's syndrome
- ACTH secretion can cause bilateral adrenal hyperplasia, the high levels of cortisol can lead to hypokalaemic alkalosis
- Lambert-Eaton syndrome: antibodies to voltage gated calcium channels causing myasthenic like syndrome

Management

- usually metastatic disease by time of diagnosis
- patients with very early stage disease (T1-2a, N0, M0) are now considered for surgery. NICE support this approach in their 2011 guidelines
- however, most patients with limited disease receive a combination of chemotherapy and radiotherapy
- patients with more extensive disease are offered palliative chemotherapy

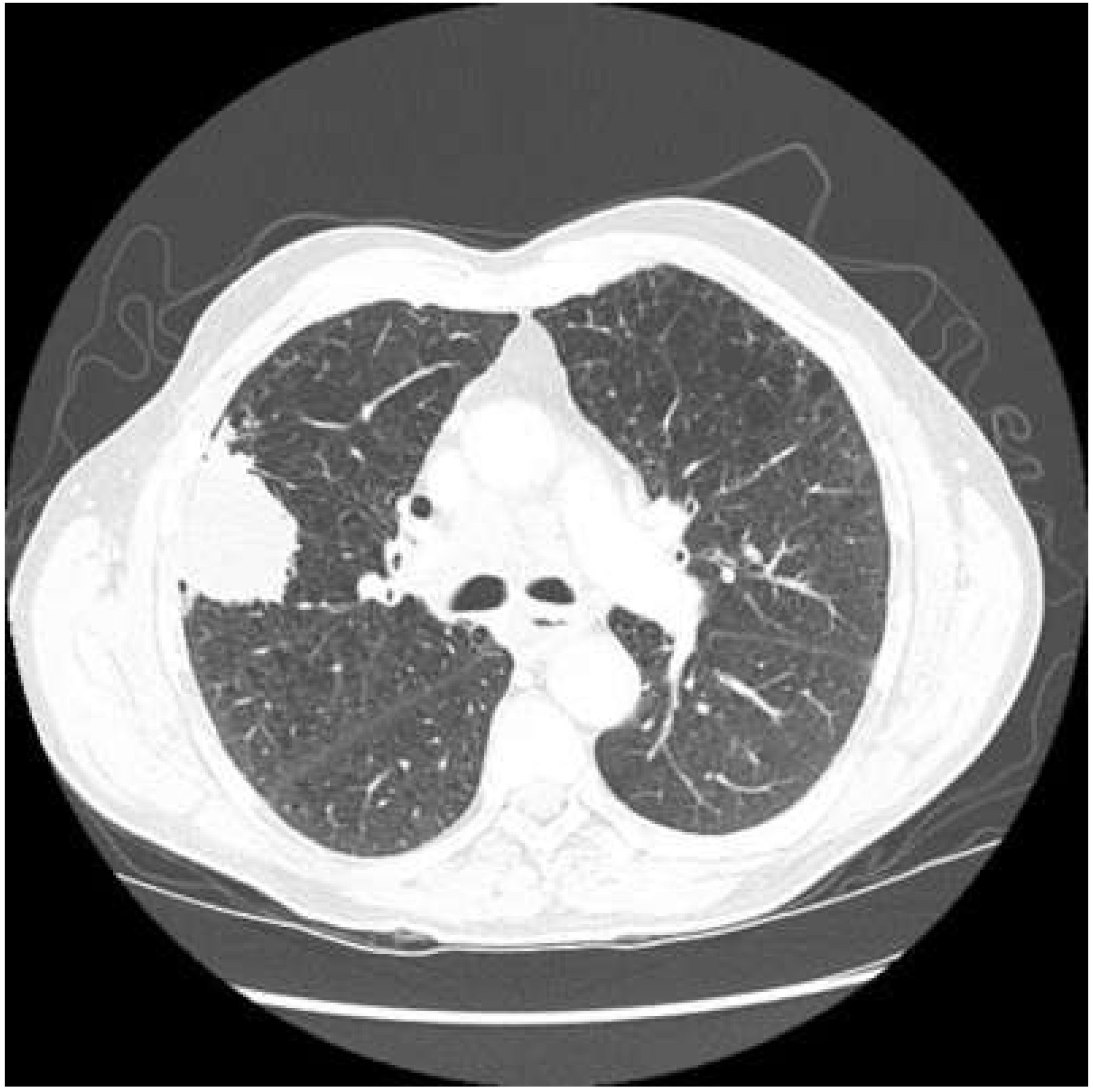

© Image used on license from Radiopaedia

CT scan showing small cell lung cancer with multiple pulmonary nodules and extensive mediastinal nodal metastases.

*an acronym for

- Amine - high amine content
- Precursor Uptake - high uptake of amine precursors
- Decarboxylase - high content of the enzyme decarboxylase

+ Q 123

Next question >

Textbooks

High-yield textbook

Extended textbook

Links

SIGN

[2014 Lung cancer management guidelines]

3 5

NICE

[2011 Lung cancer guidelines]

4 4

Suggest link

Report broken link

Media

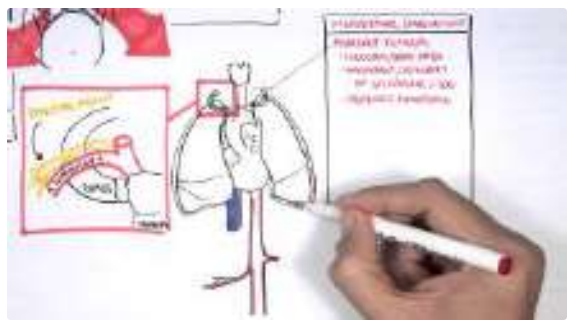

Lung cancer

Armando Hasudungan - YouTube 1 0

Lung cancer

MedFlix - YouTube 1 0

Lung Cancer: An Overview

Oncology for Medical Students - YouTube 1 0

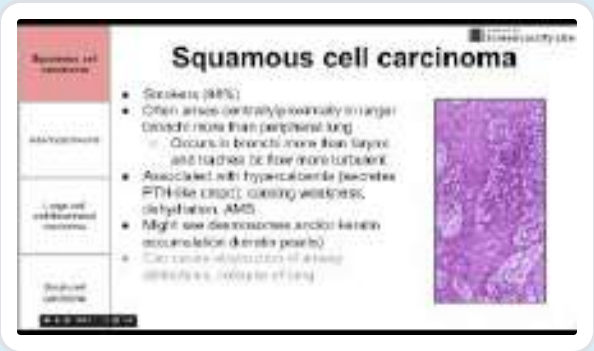

Cancers of the lung

MedLecturesMadeEasy - YouTube 3 2

Report broken media

Score: **16%**

1	✗
2	✗
3	✗
4	✗
5	✗
6	✗
7	✗
8	✗
9	✗
10	✗
11	✗
12	✓
13	✗
14	✗
15	✗
16	✗
17	✗
18	✗
19	✗
20	✗
21	✗
22	✗
23	✓
24	✗

25 ✗
26 ✗
27 ✗
28 ✗
29 ✓
30 ✗
31 ✓
32 ✗
33 ✗
34 ✗
35 ✗
36 ✓
37 ✓
38 ✗
39 ✗
40 ✗
41 ✓
42 ✗
43 ✗
44 ✗
45 ✗
46 ✗
47 ✗
48 ✗
49 ✓
50 ✗

All contents of this site are © 2024 Passmedicine Limited

Back to top

A 60-year-old woman is referred to the general respiratory clinic with increasing shortness of breath over the last nine month months. This has been associated with pedal oedema. There is no orthopnoea, paroxysmal nocturnal dyspnea or cough. Her past medical history includes bilateral extensive pulmonary emboli and she is currently taking warfarin. She has no other lung disease and she does not smoke.

On examination her chest is clear but auscultation demonstrates a loud second heart sound. There is also a right ventricular heave with visible V-waves on jugular venous pressure.

A recent CT pulmonary angiogram showed resolution of the thrombus. Echocardiogram demonstrates severe right heart dilatation and impaired function with moderate tricuspid regurgitation.

What test will most likely provide a formal diagnosis?

- Cardiac MR imaging
- Right heart catheterisation
- Left heart catheterisation
- Brain natriuretic peptide (BNP) measurement
- 6-minute walk test

Submit answer

Reference ranges

Score: **0%**

1 -

2	-
3	-
4	-
5	-
6	-
7	-
8	-
9	-
10	-
11	-
12	-
13	-
14	-

All contents of this site are © 2024 Passmedicine Limited

Back to top

A 60-year-old woman is referred to the general respiratory clinic with increasing shortness of breath over the last nine month months. This has been associated with pedal oedema. There is no orthopnoea, paroxysmal nocturnal dyspnea or cough. Her past medical history includes bilateral extensive pulmonary emboli and she is currently taking warfarin. She has no other lung disease and she does not smoke.

On examination her chest is clear but auscultation demonstrates a loud second heart sound. There is also a right ventricular heave with visible V-waves on jugular venous pressure.

A recent CT pulmonary angiogram showed resolution of the thrombus. Echocardiogram demonstrates severe right heart dilatation and impaired function with moderate tricuspid regurgitation.

What test will most likely provide a formal diagnosis?

- Cardiac MR imaging 4%
- Right heart catheterisation 88%
- Left heart catheterisation 4%
- Brain natriuretic peptide (BNP) measurement 3%
- 6-minute walk test 1%

This lady has right sided heart failure. The most likely diagnosis is chronic thromboembolic pulmonary hypertension and she requires a right heart catheterization to assess the pulmonary pressures (pulmonary hypertension = pulmonary arterial pressure 25 mmHg). Note these can be estimated on echocardiogram and cardiac MR imaging but should not be used to formally diagnose the condition. A cardiac MR can be used to further assess the right ventricular volumes, mass and function or for longitudinal follow up of patients treated for pulmonary hypertension.

A left heart catheterization is used to assess the coronary arteries and left side of the heart which should be relatively normal in this lady.

The BNP will invariably be raised given the severe right ventricular impairment and dilatation.

The 6-minute walk test is used as a prognostic measurement in pulmonary hypertension.

Further reading:

Badesch DB, Champion HC, Sanchez MAG et al. Diagnosis and assessment of pulmonary arterial hypertension. JACC 2009;54:S5566.

BMJ Critical Review: Pulmonary hypertension: diagnosis and management
http://www.bmj.com/content/346/bmj.f2028

Discuss (2) Improve

Next question >

Pulmonary hypertension: causes and classification

Pulmonary hypertension may be defined as a sustained elevation in mean pulmonary arterial pressure of greater than 20 mmHg at rest. It has recently been reclassified by the WHO:

Group 1: Pulmonary arterial hypertension (PAH)
- idiopathic*
- familial
- associated conditions: collagen vascular disease, congenital heart disease with systemic to pulmonary shunts, HIV**, drugs and toxins, sickle cell disease
- persistent pulmonary hypertension of the newborn

Group 2: Pulmonary hypertension with left heart disease
- left-sided atrial, ventricular or valvular disease such as left ventricular systolic and diastolic dysfunction, mitral stenosis and mitral regurgitation

Group 3: Pulmonary hypertension secondary to lung disease/hypoxia
- COPD
- interstitial lung disease
- sleep apnoea
- high altitude

Group 4: Pulmonary hypertension due to thromboembolic disease

Group 5: Miscellaneous conditions
- lymphangiomatosis e.g. secondary to carcinomatosis or sarcoidosis

*previously termed primary pulmonary hypertension
**the mechanism by which HIV infection produces pulmonary hypertension remains unknown

123

Next question

Textbooks

High-yield textbook

Extended textbook

Links

Medcomic 2 1

Pulmonary hypertension

Suggest link
Report broken link

Media

Pulmonary hypertension

Osmosis - YouTube 5 0

Report broken media

Score: **16%**

1	✗
2	✗
3	✗
4	✗
5	✗
6	✗
7	✗
8	✗
9	✗
10	✗
11	✗
12	✓
13	✗
14	✗
15	✗
16	✗
17	✗
18	✗
19	✗
20	✗
21	✗
22	✗
23	✓
24	✗
25	✗
26	✗
27	✗
28	✗
29	✓
30	✗
31	✓
32	✗
33	✗

34	✗
35	✗
36	✓
37	✓
38	✗
39	✗
40	✗
41	✓
42	✗
43	✗
44	✗
45	✗
46	✗
47	✗
48	✗
49	✓
50	✗

All contents of this site are © 2024 Passmedicine Limited

Back to top

A 67-year-old man presents to the emergency department with severe shortness of breath. He has a past medical history of COPD, type 2 diabetes mellitus and hypertension. On examination he appears very breathless and looks drowsy, with bilateral crackles and wheeze audible on auscultation. Following treatment with nebulisers, steroids, antibiotics and fluids he remains in type 2 respiratory failure with acidosis.

Arterial blood gas on admission:

pH	7.32
pO_2	7.3kPa
pCO_2	8.1kPa
HCO_3^-	25mmol/L

Arterial blood gas at two hours:

pH	7.30
pO_2	8.2kPa
pCO_2	9.6kPa
HCO_3^-	26mmol/L

He is started on non-invasive ventilation with a bi-level positive airway pressure. What initial settings would be most appropriate for IPAP and EPAP?

- IPAP 3cmH_2O and EPAP 15cmH_2O
- IPAP 10cmH_2O and EPAP 10cmH_2O
- IPAP 15cmH_2O and EPAP 3cmH_2O
- IPAP 20cmH_2O and EPAP 7cmH_2O
- IPAP 20cmH_2O and EPAP 3cmH_2O

Submit answer

Reference ranges

Score: **0%**

1	-
2	-
3	-
4	-
5	-
6	-
7	-
8	-
9	-
10	-
11	-
12	-
13	-
14	-
15	-

All contents of this site are © 2024 Passmedicine Limited

Back to top

A 67-year-old man presents to the emergency department with severe shortness of breath. He has a past medical history of COPD, type 2 diabetes mellitus and hypertension. On examination he appears very breathless and looks drowsy, with bilateral crackles and wheeze audible on auscultation. Following treatment with nebulisers, steroids, antibiotics and fluids he remains in type 2 respiratory failure with acidosis.

Arterial blood gas on admission:

pH	7.32
pO_2	7.3kPa
pCO_2	8.1kPa
HCO_3^-	25mmol/L

Arterial blood gas at two hours:

pH	7.30
pO_2	8.2kPa
pCO_2	9.6kPa
HCO_3^-	26mmol/L

He is started on non-invasive ventilation with a bi-level positive airway pressure. What initial settings would be most appropriate for IPAP and EPAP?

- IPAP 3cmH_2O and EPAP 15cmH_2O — 9%
- IPAP 10cmH_2O and EPAP 10cmH_2O — 7%
- IPAP 15cmH_2O and EPAP 3cmH_2O — 72%
- IPAP 20cmH_2O and EPAP 7cmH_2O — 10%
- IPAP 20cmH_2O and EPAP 3cmH_2O — 2%

The correct answer is IPAP 15cmH_2O and EPAP 3cmH_2O.

BTS advises that BiPAP should started with IPAP of 15cmH_2O in COPD. If the pH <7.25 then start with IPAP at 20cmH_2O. For neuromuscular disease needing NIV then starting with IPAP at

10cmH_2O is appropriate.

EPAP should be started at 3cmH_2O unless obstructive sleep apnoea is expected according to the British Thoracic Society, but it is common practice to start with an IPAP of 10cmH_2O and an EPAP of 4cmH_2O. In either case, IPAP should be uptitrated with an aim of IPAP of 20cmH_2O or as high as the patient can tolerate.

Source:
Davidson, Craig et al. British Thoracic Society/Intensive Care Society Guideline for the Ventilatory Management of Acute Hypercapnic Respiratory Failure in Adults. BMJ Open Respiratory Research 3.1 (2016): e000133. PMC. Web. 7 Mar. 2017.

Discuss (5) | Improve

Next question >

Acute exacerbation of COPD

Acute exacerbations of COPD are one of the most common reasons why people present to hospital in developed countries.

The most common infective causes of COPD exacerbations are:

- bacteria
  - *Haemophilus influenzae* (most common cause)
  - *Streptococcus pneumoniae*
  - *Moraxella catarrhalis*
- respiratory viruses
  - account for around 30% of exacerbations
  - human rhinovirus is the most important pathogen

Features

- increase in dyspnoea, cough, wheeze
- there may be an increase in sputum suggestive of an infective cause
- patients may be hypoxic and in some cases have acute confusion

NICE guidelines from 2010 recommend the following:

- increase the frequency of bronchodilator use and consider giving via a nebuliser
- give prednisolone 30 mg daily for 5 days
- it is common practice for all patients with an exacerbation of COPD to receive antibiotics. NICE do not support this approach. They recommend giving oral antibiotics 'if sputum is

purulent or there are clinical signs of pneumonia'
- the BNF recommends one of the following oral antibiotics first-line: amoxicillin or clarithromycin or doxycycline.

Admission is recommended if any of the following criteria are met
- severe breathlessness
- acute confusion or impaired consciousness
- cyanosis
- oxygen saturation less than 90% on pulse oximetry.
- social reasons e.g. inability to cope at home (or living alone)
- significant comorbidity (such as cardiac disease or insulin-dependent diabetes)

Severe exacerbations requiring secondary care

Oxygen therapy
- COPD patients are at risk of hypercapnia - therefore an initial oxygen saturation target of 88-92% should be used
- prior to the availability of blood gases, use a 28% Venturi mask at 4 l/min and aim for an oxygen saturation of 88-92% for patients with risk factors for hypercapnia but no prior history of respiratory acidosis
- adjust target range to 94-98% if the pCO_2 is normal

Nebulised bronchodilator
- beta adrenergic agonist: e.g. salbutamol
- muscarinic antagonists: e.g. ipratropium

Steroid therapy as above
- IV hydrocortisone may sometimes be considered instead of oral prednisolone

IV theophylline
- may be considered for patients not responding to nebulised bronchodilators

Patients with COPD are prone to develop type 2 respiratory failure. If this develops then non-invasive ventilation may be used
- typically used for COPD with respiratory acidosis pH 7.25-7.35
    - the BTS guidelines state that NIV can be used in patients who are more acidotic (i.e. pH < 7.25) but that a greater degree of monitoring is required (e.g. HDU) and a lower threshold for intubation and ventilation should be used

- bilevel positive airway pressure (BiPaP) is typically used with initial settings:
  - Expiratory Positive Airway Pressure (EPAP): 4-5 cm H2O
  - Inspiratory Positive Airway Pressure (IPAP): RCP advocate 10 cm H20 whilst BTS suggest 12-15 cm H2O

+ Q 123

Next question >

Textbooks

High-yield textbook

Extended textbook

Links

Clinical Knowledge Summaries 28 25

Acute exacerbation of COPD guidelines

NICE 22 10

2018 COPD guidelines

Suggest link Report broken link

Media

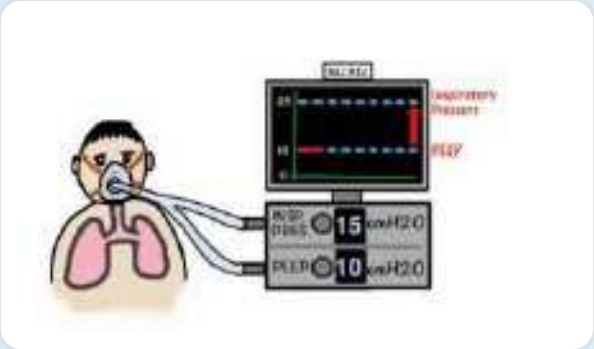

CPAP and Non-Invasive Ventilation in 5 minutes

Nick Smith - YouTube 6 2

Report broken media

Score: **16%**

1	✗
2	✗
3	✗
4	✗
5	✗
6	✗
7	✗
8	✗
9	✗
10	✗
11	✗
12	✓
13	✗
14	✗
15	✗
16	✗
17	✗
18	✗
19	✗
20	✗
21	✗
22	✗
23	✓
24	✗
25	✗
26	✗
27	✗
28	✗

29	✓
30	✗
31	✓
32	✗
33	✗
34	✗
35	✗
36	✓
37	✓
38	✗
39	✗
40	✗
41	✓
42	✗
43	✗
44	✗
45	✗
46	✗
47	✗
48	✗
49	✓
50	✗

All contents of this site are © 2024 Passmedicine Limited

Back to top

A 48-year-old man presents to the respiratory clinic with a 2-month history of progressive shortness of breath and a dry cough. There is no history of fever or chest pain, although, he does complain of worsening lethargy. He works as a school teacher and visited India 6 months prior. He denies occupational exposure to hazardous chemicals and has never smoked. His past medical history includes childhood asthma, type 1 diabetes, and rheumatoid arthritis.

On examination, his observations are within normal limits. On auscultation, there are audible fine crackles at the bases with normal heart sounds. His calves are soft and non-tender with no visible oedema.

A chest x-ray and CT chest are organised, as shown below.

© Image used on license from Radiopaedia

Which of the following conditions is the most likely diagnosis?

- Allergic bronchopulmonary aspergillosis
- Ankylosing spondylitis
- Rheumatoid arthritis
- Sarcoidosis
- Tuberculosis

Submit answer

Reference ranges

Score: **0%**

1	-
2	-
3	-
4	-
5	-
6	-
7	-
8	-
9	-
10	-
11	-
12	-
13	-
14	-
15	-
16	-

All contents of this site are © 2024 Passmedicine Limited

Back to top

PassMedicine

A 48-year-old man presents to the respiratory clinic with a 2-month history of progressive shortness of breath and a dry cough. There is no history of fever or chest pain, although, he does complain of worsening lethargy. He works as a school teacher and visited India 6 months prior. He denies occupational exposure to hazardous chemicals and has never smoked. His past medical history includes childhood asthma, type 1 diabetes, and rheumatoid arthritis.

On examination, his observations are within normal limits. On auscultation, there are audible fine crackles at the bases with normal heart sounds. His calves are soft and non-tender with no visible oedema.

A chest x-ray and CT chest are organised, as shown below.

© Image used on license from Radiopaedia

Which of the following conditions is the most likely diagnosis?

- Allergic bronchopulmonary aspergillosis 25%
- Ankylosing spondylitis 3%
- Rheumatoid arthritis 45%
- Sarcoidosis 20%
- Tuberculosis 8%

Causes of lower zone fibrosis: **MAID**
Most connective tissue diseases (e.g. rheumatoid arthritis)
Asbestosis

Idiopathic pulmonary fibrosis, infection
Drugs (e.g. methotrexate, amiodarone, bleomycin)

This patient's chest x-ray and CT scan show features of lower zone fibrosis with visible honeycombing on the CT scan. On closer inspection of the chest x-ray, there is a visible well-circumscribed opacity in the left lower zone in keeping with a pulmonary nodule (e.g. rheumatoid nodule), and multiple smaller opacities can be seen throughout the slice of the CT scan. Of the conditions listed in the question, rheumatoid arthritis is the only disease that causes lower zone fibrosis, with the other conditions classically causing a pattern of fibrosis in the upper zones. Furthermore, the history of worsening lethargy and arthralgia are suggestive of rheumatoid arthritis, which commonly has an insidious onset over time.

Allergic bronchopulmonary aspergillosis (ABPA) causes a clinical picture similar to asthma and arises following exposure to *Aspergillus* spores. Symptoms include cough, wheeze, and shortness of breath. CT imaging shows dilated bronchioles (similar to bronchiectasis) and occasionally a 'finger-in-glove' appearance can be seen that represents the mucous filling of dilated bronchi. Lower zone pulmonary fibrosis is not a feature of ABPA.

Ankylosing spondylitis is a spondyloarthropathy that typically presents as a young man with lower back pain and stiffness that is worse in the morning. Ankylosing spondylitis causes apical fibrosis, unlike the changes seen on this CT chest that shows lower zone fibrosis.

Sarcoidosis is a multisystem disorder that causes respiratory symptoms such as shortness of breath and a dry cough, along with extra-pulmonary manifestations including fever, arthralgia, and erythema nodosum. Imaging findings in sarcoidosis include bilateral hilar lymphadenopathy, interstitial infiltrates, and fibrosis (typically in the upper lobes).

Tuberculosis is caused by the bacterium *Mycobacterium tuberculosis* with symptoms consisting of fever, productive cough, lethargy, night sweats, and weight loss. In contrast, the patient in this question describes progressive shortness of breath and a dry cough. Tuberculosis does not commonly cause fibrosis, but instead causes calcified lesions (typically apical in location).

Discuss (5) | Improve

Next question

Rheumatoid arthritis: respiratory manifestations

A variety of respiratory problems may be seen in patients with rheumatoid arthritis:

- pulmonary fibrosis

- pleural effusion
- pulmonary nodules
- bronchiolitis obliterans
    - progressive dyspnoea
    - obstructive pattern on spirometry
    - centrilobular nodules, bronchial wall thickening is seen on CT
- complications of drug therapy e.g. methotrexate pneumonitis
- pleurisy
- Caplan's syndrome
    - massive fibrotic nodules with occupational coal dust exposure
- infection (possibly atypical) secondary to immunosuppression

123

Next question >

Textbooks

High-yield textbook

Extended textbook

Score: **16%**

1 ✕
2 ✕

3	✗
4	✗
5	✗
6	✗
7	✗
8	✗
9	✗
10	✗
11	✗
12	✓
13	✗
14	✗
15	✗
16	✗
17	✗
18	✗
19	✗
20	✗
21	✗
22	✗
23	✓
24	✗
25	✗
26	✗
27	✗
28	✗
29	✓
30	✗
31	✓
32	✗
33	✗
34	✗
35	✗
36	✓
37	✓
38	✗

39	✗
40	✗
41	✓
42	✗
43	✗
44	✗
45	✗
46	✗
47	✗
48	✗
49	✓
50	✗

All contents of this site are © 2024 Passmedicine Limited

Back to top

A 65-year-old woman slips on an icy road and has a neck of femur fracture. Her past medical history includes hypertension, type 2 diabetes and a pack-year history of 40 years. After six days in hospital, she becomes short of breath and develops haemoptysis. Her observations are:

- Blood pressure: 135/70 mmHg
- Pulse: 110 bpm
- Temperature: 36.4 deg C
- Respiratory rate: 24/min
- Oxygen saturation: 89% on air

A subsequent CTPA shows a right segmental pulmonary embolus and a 4mm solid nodule in her right upper lobe.

What is the most appropriate management of her nodule?

- Antibiotics and repeat CT
- Biopsy of lung nodule
- No further follow-up required
- PET-CT
- Repeat CT in 3 months

Submit answer

Reference ranges

2	-
3	-
4	-
5	-
6	-
7	-
8	-
9	-
10	-
11	-
12	-
13	-
14	-
15	-
16	-
17	-

All contents of this site are © 2024 Passmedicine Limited

Back to top

A 65-year-old woman slips on an icy road and has a neck of femur fracture. Her past medical history includes hypertension, type 2 diabetes and a pack-year history of 40 years. After six days in hospital, she becomes short of breath and develops haemoptysis. Her observations are:

- Blood pressure: 135/70 mmHg
- Pulse: 110 bpm
- Temperature: 36.4 deg C
- Respiratory rate: 24/min
- Oxygen saturation: 89% on air

A subsequent CTPA shows a right segmental pulmonary embolus and a 4mm solid nodule in her right upper lobe.

What is the most appropriate management of her nodule?

Antibiotics and repeat CT	1%
Biopsy of lung nodule	8%
No further follow-up required	60%
PET-CT	6%
Repeat CT in 3 months	25%

Solitary, solid and non-calcified lung nodules of less than 5mm in size do not warrant further investigations or monitoring

Important for me Less important

Lung nodules are a common incidental finding in patients who have undergone CT scans. BTS guidelines recommend that solid nodules that are less than 5mm in size **do not require any further follow-up**, even in a smoker.

While chest infections are a common complication after surgery, there is no indication this patient has a chest infection and her CTPA did not show pneumonia. **Antibiotics** are therefore not indicated.

Larger (>8mm) nodules are more likely to be malignant, especially in patients who are smokers. Patients with such nodules should be ideally offered a **PET-CT** to help determine the risk of malignancy by combining nodule characteristics with patient characteristics. Patients with a higher risk of malignancy may be offered several options, including **a biopsy** to confirm malignancy or active surveillance such as **a repeat CT in 3 months**. This patient's nodule is too small.

Discuss (7) | Improve

Next question

Solitary lung nodule

BTS guidelines for lung nodules:

- Nodule <5mm, or clear benign features, or unsuitable for treatment: can be discharged
- Nodule =>8mm and high risk*: then CT-PET, and if CT-PET shows high uptake then biopsy
- Nodule 5-6mm, or =>8mm and low-risk*: then CT surveillance
- CT surveillance: if 5-6mm then at 1 year, if =>6 then in three months

*To determine the risk of malignancy following CT the BTS uses the Brock model

123

Next question

Textbooks

High-yield textbook

Extended textbook

Score: **16%**

1	✗
2	✗
3	✗
4	✗
5	✗
6	✗
7	✗
8	✗
9	✗
10	✗
11	✗
12	✓
13	✗
14	✗
15	✗
16	✗
17	✗
18	✗
19	✗
20	✗
21	✗
22	✗
23	✓
24	✗
25	✗
26	✗
27	✗
28	✗
29	✓
30	✗
31	✓
32	✗

33	✗
34	✗
35	✗
36	✓
37	✓
38	✗
39	✗
40	✗
41	✓
42	✗
43	✗
44	✗
45	✗
46	✗
47	✗
48	✗
49	✓
50	✗

All contents of this site are © 2024 Passmedicine Limited

Back to top

A 71-year-old man presents to his GP having suffered from daytime sleeping, which has become so interrupting that he has been placed on probation by his manager at work. He complains of having frequent morning headaches and often gets breathless on walking to the shops. He used to smoke 20 cigarettes per day for 20 years and drinks a pint of beer per evening at the pub. He is also clinically obese.

After being referred to the hospital, an evening arterial blood test is performed and reveals a PaO2 of 9.9 kPa and a PaCO2 of 4.4 kPa. The arterial blood gas is repeated the next morning and reveals a PaO2 of 10.0 kPa and a PaCO2 of 9.1 kPa.

What is the most likely diagnosis?

- Pulmonary hypertension
- Central sleep apnoea
- Obesity hypoventilation syndrome
- Benign intracranial hypertension
- Multiple pulmonary emboli

Submit answer

Reference ranges

Score: **0%**

1 -
2 -
3 -
4 -

5 -
6 -
7 -
8 -
9 -
10 -
11 -
12 -
13 -
14 -
15 -
16 -
17 -
18 -

All contents of this site are © 2024 Passmedicine Limited

A 71-year-old man presents to his GP having suffered from daytime sleeping, which has become so interrupting that he has been placed on probation by his manager at work. He complains of having frequent morning headaches and often gets breathless on walking to the shops. He used to smoke 20 cigarettes per day for 20 years and drinks a pint of beer per evening at the pub. He is also clinically obese.

After being referred to the hospital, an evening arterial blood test is performed and reveals a PaO_2 of 9.9 kPa and a $PaCO_2$ of 4.4 kPa. The arterial blood gas is repeated the next morning and reveals a PaO_2 of 10.0 kPa and a $PaCO_2$ of 9.1 kPa.

What is the most likely diagnosis?

Pulmonary hypertension	1%
Central sleep apnoea	25%
Obesity hypoventilation syndrome	74%
Benign intracranial hypertension	0%
Multiple pulmonary emboli	0%

This patient most likely has obesity hypoventilation syndrome as characterised by his raised carbon dioxide levels in the morning, as opposed to the evening.

Discuss (13) Improve

Next question

Obesity hypoventilation syndrome

Obesity hypoventilation syndrome (OHS) is a complex respiratory disorder characterized by chronic hypoventilation, obesity, and sleep-disordered breathing, particularly obstructive sleep apnea (OSA). This condition, also known as Pickwickian syndrome, can result in significant morbidity and mortality if left untreated. This textbook entry aims to provide a comprehensive

overview of the pathophysiology, clinical presentation, diagnosis, and management of OHS to help doctors better understand and manage this condition.

Pathophysiology

OHS results from a combination of factors related to obesity and its effects on the respiratory system. These factors include:

- Impaired respiratory mechanics: Excessive adipose tissue, particularly in the chest and abdominal regions, can restrict lung expansion and limit diaphragmatic movement, resulting in decreased lung volumes and increased work of breathing.
- Altered ventilatory control: OHS patients may have impaired central respiratory drive, leading to inadequate ventilation and subsequent hypoventilation, particularly during sleep.
- Sleep-disordered breathing: OSA is highly prevalent in OHS patients, contributing to nocturnal hypoventilation, intermittent hypoxia, and hypercapnia.
- Hormonal and metabolic factors: Obesity is associated with hormonal and metabolic abnormalities that can further exacerbate hypoventilation, such as leptin resistance and insulin resistance.

Clinical Presentation

Patients with OHS typically present with the following signs and symptoms:

- Obesity: Body mass index (BMI) ≥30 kg/m2, often with central adiposity.
- Daytime hypoventilation: Manifests as dyspnea, exercise intolerance, and fatigue.
- Sleep-disordered breathing: Symptoms may include loud snoring, witnessed apneas, nocturnal choking or gasping, and excessive daytime sleepiness.
- Morning headaches and cognitive dysfunction: These symptoms may result from chronic hypercapnia and hypoxemia.
- Signs of right heart failure: Including peripheral edema, jugular venous distention, and hepatomegaly, due to chronic hypoxemia and pulmonary hypertension.

Diagnosis

The diagnosis of OHS is based on the following criteria:

- Obesity: BMI ≥30 kg/m2.
- Hypoventilation: Daytime arterial blood gas analysis demonstrating hypercapnia and hypoxemia in the absence of other causes.
- Sleep-disordered breathing: Polysomnography demonstrating the presence of OSA or other sleep-related breathing disorders.
- Additional diagnostic tests may include pulmonary function tests, chest radiography, electrocardiography, and echocardiography to evaluate lung function, rule out alternative diagnoses, and assess the severity of the condition.

Management

The management of OHS involves addressing the underlying causes and complications, including:

- Weight loss: Encouraging lifestyle modifications, such as a balanced diet and regular physical activity, is crucial. Bariatric surgery may be considered in refractory cases or for patients with severe obesity.
- Positive airway pressure therapy: Continuous positive airway pressure (CPAP) or bilevel positive airway pressure (BiPAP) can be used to treat OSA and nocturnal hypoventilation.
- Oxygen therapy: Supplemental oxygen may be required for patients with persistent hypoxemia despite positive airway pressure therapy.

+ Q 123

Next question >

Textbooks

High-yield textbook

Extended textbook

Score: **16%**

1 ✗
2 ✗
3 ✗
4 ✗
5 ✗

6	✗
7	✗
8	✗
9	✗
10	✗
11	✗
12	✓
13	✗
14	✗
15	✗
16	✗
17	✗
18	✗
19	✗
20	✗
21	✗
22	✗
23	✓
24	✗
25	✗
26	✗
27	✗
28	✗
29	✓
30	✗
31	✓
32	✗
33	✗
34	✗
35	✗
36	✓
37	✓
38	✗
39	✗
40	✗
41	✓

42	✗
43	✗
44	✗
45	✗
46	✗
47	✗
48	✗
49	✓
50	✗

All contents of this site are © 2024 Passmedicine Limited

A 67-year-old patient is reviewed in oncology clinic. He has recently been diagnosed with mesothelioma following a pleural biopsy. He has a past medical history of hypothyroidism, pseudogout and depression. He is concerned about the financial implications and is due to seek compensation. He has worked as a plumber for all of his professional life and wants to know when the asbestos exposure most likely occurred to cause him to develop mesothelioma.

How long ago would his asbestos exposure occurred?

- >50 years ago
- >30 years ago
- >10 years ago
- >5 years ago
- >2 year ago

Submit answer

Reference ranges

Score: **0%**

1 -
2 -
3 -
4 -
5 -
6 -
7 -
8 -

All contents of this site are © 2024 Passmedicine Limited

A 67-year-old patient is reviewed in oncology clinic. He has recently been diagnosed with mesothelioma following a pleural biopsy. He has a past medical history of hypothyroidism, pseudogout and depression. He is concerned about the financial implications and is due to seek compensation. He has worked as a plumber for all of his professional life and wants to know when the asbestos exposure most likely occurred to cause him to develop mesothelioma.

How long ago would his asbestos exposure occurred?

>50 years ago	4%
>30 years ago	64%
>10 years ago	26%
>5 years ago	2%
>2 year ago	4%

The correct answer is >30 years ago. This is a gentleman with mesothelioma. It normally takes at least 10 years for pleural plaques to develop, 20 years for asbestosis and finally 30 years for mesothelioma. To develop mesothelioma a heavy exposure of asbestos will have occurred.

Discuss (4) | Improve

Next question

Mesothelioma

Mesothelioma is a cancer of the mesothelial layer of the pleural cavity that is strongly associated with asbestos exposure. In a small percentage of cases, other mesothelial layers such as those in the abdomen may be affected.

Features

- Dyspnoea, weight loss, chest wall pain
- Clubbing

- 30% present as painless pleural effusion
- Only 20% have pre-existing asbestosis
- History of asbestos exposure in 85-90%, latent period of 30-40 years

Basics

- Malignancy of mesothelial cells of pleura
- Metastases to contralateral lung and peritoneum
- Right lung affected more often than left

Investigation/diagnosis

- suspicion is normally raised by a chest x-ray showing either a pleural effusion or pleural thickening
- the next step is normally a pleural CT
- if a pleural effusion is present fluid should be sent for MC&S, biochemistry and cytology (but cytology is only helpful in 20-30% of cases)
- local anaesthetic thoracoscopy is increasingly used to investigate cytology negative exudative effusions as it has a high diagnostic yield (around 95%)
- if an area of pleural nodularity is seen on CT then an image-guided pleural biopsy may be used

Management

- Symptomatic
- Industrial compensation
- Chemotherapy, Surgery if operable
- Prognosis poor, median survival 12 months

123

Next question

Textbooks

High-yield textbook

Extended textbook

Links

British Thoracic Society 1 2

2018 Investigation and Management of Pleural Mesothelioma

British Thoracic Society 5 0

2023 Pleural disease guidelines

Suggest link Report broken link

Media

Mesothelioma

Osmosis - YouTube 2 0

Report broken media

Score: **16%**

1 ✗

2	✗
3	✗
4	✗
5	✗
6	✗
7	✗
8	✗
9	✗
10	✗
11	✗
12	✓
13	✗
14	✗
15	✗
16	✗
17	✗
18	✗
19	✗
20	✗
21	✗
22	✗
23	✓
24	✗
25	✗
26	✗
27	✗
28	✗
29	✓
30	✗
31	✓
32	✗
33	✗
34	✗
35	✗
36	✓
37	✓

38	✗
39	✗
40	✗
41	✓
42	✗
43	✗
44	✗
45	✗
46	✗
47	✗
48	✗
49	✓
50	✗

All contents of this site are © 2024 Passmedicine Limited

Back to top

A 71-year-old woman is referred by her out-of-hours GP service to the emergency department following her presentation with worsening shortness of breath and cough. The shortness of breath has been increasing in severity over the last 3 weeks and is associated by an occasional non-productive cough.

She has an extensive cardiac past medical history including two myocardial infarctions which were treated with percutaneous coronary intervention, an aortic heart valve replacement and mild mitral regurgitation. Other history includes hypertension which is treated with amlodipine and ramipril, hypercholesterolaemia which is treated with atorvastatin and mild COPD for which he takes salbutamol and ipratropium bromide. She previously worked as a librarian, has smoked 10 cigarettes for the past 20 years and drinks on average 5 units of alcohol per week.

Examination reveals dull percussion and reduced breath sounds over the left mid and lower bases of the lung. Urgent chest x-ray reveals a left-sided pleural effusion. Pleural aspirate is taken and shows:

Protein content	45 g/L
Glucose	2.4mmol/L
pH	7.32

What is the most likely diagnosis?

- Congestive cardiac failure
- Bronchial carcinoma
- Systemic lupus erythematosus
- Mesothelioma
- Boerhaave's syndrome

Submit answer

Reference ranges

Score: **0%**

1	-
2	-
3	-
4	-
5	-
6	-
7	-
8	-
9	-
10	-
11	-
12	-
13	-
14	-
15	-
16	-
17	-
18	-
19	-
20	-

All contents of this site are © 2024 Passmedicine Limited

A 71-year-old woman is referred by her out-of-hours GP service to the emergency department following her presentation with worsening shortness of breath and cough. The shortness of breath has been increasing in severity over the last 3 weeks and is associated by an occasional non-productive cough.

She has an extensive cardiac past medical history including two myocardial infarctions which were treated with percutaneous coronary intervention, an aortic heart valve replacement and mild mitral regurgitation. Other history includes hypertension which is treated with amlodipine and ramipril, hypercholesterolaemia which is treated with atorvastatin and mild COPD for which he takes salbutamol and ipratropium bromide. She previously worked as a librarian, has smoked 10 cigarettes for the past 20 years and drinks on average 5 units of alcohol per week.

Examination reveals dull percussion and reduced breath sounds over the left mid and lower bases of the lung. Urgent chest x-ray reveals a left-sided pleural effusion. Pleural aspirate is taken and shows:

Protein content	45 g/L
Glucose	2.4mmol/L
pH	7.32

What is the most likely diagnosis?

- Congestive cardiac failure 16%
- Bronchial carcinoma 60%
- Systemic lupus erythematosus 4%
- Mesothelioma 14%
- Boerhaave's syndrome 6%

The protein content of the pleural fluid is high (>30g/L) demonstrating that the fluid is an exudate. The low glucose and pH of the fluid, when coupled with the clinical symptoms of shortness of breath and cough indicates that the most likely diagnosis is bronchial carcinoma. There is no

history of asbestos exposure and no clinical feature of systemic lupus erythematosus or Boerhaave's syndrome present.

Discuss (5) Improve

Next question

Pleural effusion: investigation and management

The British Thoracic Society (BTS) produced guidelines in 2010 covering the investigation of patients with a pleural effusion.

Imaging

- posterioranterior (PA) chest x-rays should be performed in all patients
- ultrasound is recommended: it increases the likelihood of successful pleural aspiration and is sensitive for detecting pleural fluid septations
- contrast CT is now increasingly performed to investigate the underlying cause, particularly for exudative effusions

Pleural aspiration

- as above, ultrasound is recommended to reduce the complication rate
- a 21G needle and 50ml syringe should be used
- fluid should be sent for pH, protein, lactate dehydrogenase (LDH), cytology and microbiology

Light's criteria was developed in 1972 to help distinguish between a transudate and an exudate. The BTS recommend using the criteria for borderline cases:

- exudates have a protein level of >30 g/L, transudates have a protein level of <30 g/L
- if the protein level is between 25-35 g/L, Light's criteria should be applied. An exudate is likely if at least one of the following criteria are met:
    - pleural fluid protein divided by serum protein >0.5
    - pleural fluid LDH divided by serum LDH >0.6
    - pleural fluid LDH more than two-thirds the upper limits of normal serum LDH

Other characteristic pleural fluid findings:
- low glucose: rheumatoid arthritis, tuberculosis
- raised amylase: pancreatitis, oesophageal perforation
- heavy blood staining: mesothelioma, pulmonary embolism, tuberculosis

Pleural infection

All patients with a pleural effusion in association with sepsis or a pneumonic illness require diagnostic pleural fluid sampling
- if the fluid is purulent or turbid/cloudy a chest tube should be placed to allow drainage
- if the fluid is clear but the **pH is less than 7.2 in patients with suspected pleural infection a chest tube should be placed**

Management of recurrent pleural effusion

Options for managing patients with recurrent pleural effusions include:
- recurrent aspiration
- pleurodesis
- indwelling pleural catheter
- drug management to alleviate symptoms e.g. opioids to relieve dyspnoea

123

Next question

Textbooks

High-yield textbook

Extended textbook

Links

British Thoracic Society 17 14

2023 Pleural disease guidelines

Royal College of Physicians 13 7

2012 Pleural infection review

Suggest link Report broken link

Media

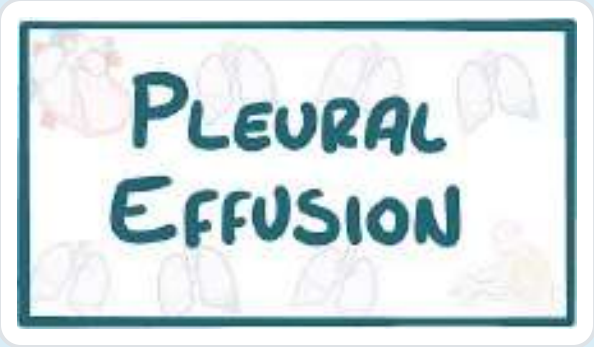

Pleural effusion

Osmosis - YouTube 8 1

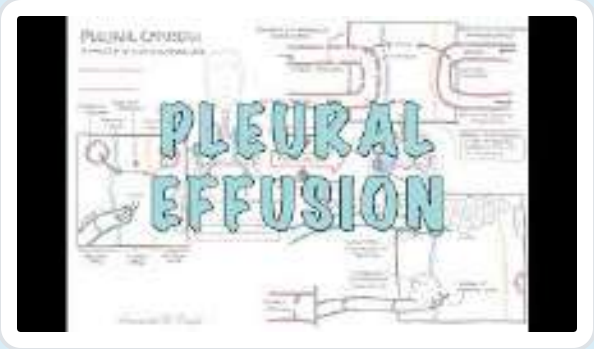

Pleural effusion

Armando Hasudungan - YouTube 6 1

Report broken media

Score: **16%**

1 ✗

2	✗
3	✗
4	✗
5	✗
6	✗
7	✗
8	✗
9	✗
10	✗
11	✗
12	✓
13	✗
14	✗
15	✗
16	✗
17	✗
18	✗
19	✗
20	✗
21	✗
22	✗
23	✓
24	✗
25	✗
26	✗
27	✗
28	✗
29	✓
30	✗
31	✓
32	✗
33	✗
34	✗
35	✗
36	✓
37	✓

38	✗
39	✗
40	✗
41	✓
42	✗
43	✗
44	✗
45	✗
46	✗
47	✗
48	✗
49	✓
50	✗

All contents of this site are © 2024 Passmedicine Limited

Back to top

A 56-year-old woman with a diagnosis of asthma attends her respiratory outpatient appointment. She has had two exacerbations requiring hospitalisation over the past year and also has hypothyroidism and angina. She takes tiotropium, fluticasone, levothyroxine, simvastatin, aspirin and GTN spray. She was started on theophylline at a standard regime in the previous clinic appointment and has completed a course of ciprofloxacin the last week for a mild exacerbation. She is otherwise well and smokes 20 cigarettes a day. She has allergies to pollen.

On examination, she has a dry cough but is able to speak in full sentences. Her chest has scattered wheeze throughout.

Na^+	145 mmol/l
K^+	3.9 mmol/l
Urea	4.2 mmol/l
Creatinine	56 µmol/l
Chest x-ray	hyperexpanded lung fields
Theophylline level	6 mcg/ml (normal range 10-20)
TSH	5.2 mU/l

What is the likely cause of her subtherapeutic theophylline level?

- Ciprofloxacin
- Simvastatin
- Smoking
- Alcohol binge
- Hypothyroid state

Submit answer

Reference ranges

Score: **0%**

1	-
2	-
3	-
4	-
5	-
6	-
7	-
8	-
9	-
10	-
11	-
12	-
13	-
14	-
15	-
16	-
17	-
18	-
19	-
20	-
21	-

All contents of this site are © 2024 Passmedicine Limited

Back to top

A 56-year-old woman with a diagnosis of asthma attends her respiratory outpatient appointment. She has had two exacerbations requiring hospitalisation over the past year and also has hypothyroidism and angina. She takes tiotropium, fluticasone, levothyroxine, simvastatin, aspirin and GTN spray. She was started on theophylline at a standard regime in the previous clinic appointment and has completed a course of ciprofloxacin the last week for a mild exacerbation. She is otherwise well and smokes 20 cigarettes a day. She has allergies to pollen.

On examination, she has a dry cough but is able to speak in full sentences. Her chest has scattered wheeze throughout.

Na^+	145 mmol/l
K^+	3.9 mmol/l
Urea	4.2 mmol/l
Creatinine	56 µmol/l
Chest x-ray	hyperexpanded lung fields
Theophylline level	6 mcg/ml (normal range 10-20)
TSH	5.2 mU/l

What is the likely cause of her subtherapeutic theophylline level?

- Ciprofloxacin 43%
- Simvastatin 8%
- Smoking 32%
- Alcohol binge 12%
- Hypothyroid state 5%

Current smokers -> liver enzyme induction -> higher doses aminophylline required

Important for me Less important

Theophylline/aminophylline requirements vary between individuals. They are metabolised by the liver and therefore concentration depends on the rate of metabolism. Statins, ciprofloxacin and an alcohol binge or inhibit the liver increasing sensitivity to theophylline and increasing the risk of toxicity at smaller doses. In contrast, smoking is an inducer of liver enzyme activity and therefore smokers often require higher starting doses. The TSH suggests she is slightly hypothyroid at present but this does not significantly affect the metabolism.

Discuss (5) Improve

Next question

Aminophylline infusions

Aminophylline infusions are used in the management of acute asthma and chronic obstructive pulmonary disease (COPD).

For patients not already treated with xanthines (theophylline or aminophylline) a loading dose is given:

- dose: 5mg/kg
- given by slow intravenous injection over at least 20 minutes

For the maintenance infusion 1g of aminophylline is added to 1 litre of normal saline to give a solution of 1 mg/ml.

- dose: 500-700mcg/kg/hour. If elderly: 300mcg/kg/hour
- plasma theophylline concentrations should be monitored

+ Q 123

Next question

Textbooks

High-yield textbook

Extended textbook

Score: **16%**

1	✗
2	✗
3	✗
4	✗
5	✗
6	✗
7	✗
8	✗
9	✗
10	✗
11	✗
12	✓
13	✗
14	✗
15	✗
16	✗
17	✗
18	✗
19	✗
20	✗
21	✗
22	✗
23	✓
24	✗
25	✗
26	✗
27	✗

28	✗
29	✓
30	✗
31	✓
32	✗
33	✗
34	✗
35	✗
36	✓
37	✓
38	✗
39	✗
40	✗
41	✓
42	✗
43	✗
44	✗
45	✗
46	✗
47	✗
48	✗
49	✓
50	✗

All contents of this site are © 2024 Passmedicine Limited

Back to top

A 71-year-old man is being treated in a medical ward for an empyema. Shortly after admission, a chest drain is inserted under ultrasound guidance and antibiotics are started. Over the past few days, there have been significant volumes drained and the patient has been improving clinically.

On the daily morning ward round, his chest drain is reviewed. It is on suction. There is minimal drain output over the past 24 hours and it is noted that the chest drain is bubbling. This bubbling is more significant when the patient is asked to cough.

What does this indicate?

- Blocked chest drain
- Bronchopleural fistula
- Chest drain moved displaced outside of the chest
- Normal
- Unresolved empyema

Submit answer

Reference ranges

Score: **0%**

1	-
2	-
3	-
4	-
5	-
6	-

7	-
8	-
9	-
10	-
11	-
12	-
13	-
14	-
15	-
16	-
17	-
18	-
19	-
20	-
21	-
22	-

All contents of this site are © 2024 Passmedicine Limited

Back to top

A 71-year-old man is being treated in a medical ward for an empyema. Shortly after admission, a chest drain is inserted under ultrasound guidance and antibiotics are started. Over the past few days, there have been significant volumes drained and the patient has been improving clinically.

On the daily morning ward round, his chest drain is reviewed. It is on suction. There is minimal drain output over the past 24 hours and it is noted that the chest drain is bubbling. This bubbling is more significant when the patient is asked to cough.

What does this indicate?

Blocked chest drain	2%
Bronchopleural fistula	72%
Chest drain moved displaced outside of the chest	6%
Normal	18%
Unresolved empyema	2%

Bubbling of a chest drain inserted to drain an empyema may indicates that a bronchopleural fistula has occurred

Important for me Less important

Bubbling of a chest drain inserted into the pleural space is indicative of an air leak. Therefore, given the clinical history of an empyema, it is likely that a **bronchopleural fistula has formed**. This is therefore the correct answer.

As there is bubbling of the chest drain, it cannot be **blocked**. This is therefore an incorrect answer.

If the **chest drain is displaced outside of the chest** and on suction, bubbling can occur. Distinguishing between a bronchopleural fistula and a displaced chest drain can be difficult however one simple test is to ask the patient to cough. As the patient coughs and the intrathoracic pressure rises, this will cause an increase in the air flowing into the pleural space and therefore the bubbling of the drain. If the drain is outside of the pleural space, the bubbling will be constant and unrelated to coughing.

Bubbling from a chest drain is not a **normal finding** . Although swinging is normal with changes in intrathoracic pressure, bubbling is caused by air being entrained into the drain. The most common cause for this is the displacement of the drain outside of the thorax, however, a bronchopleural fistula is the diagnosis here as indicated by the changes on coughing.

An **unresolved empyema** is not necessarily indicated here by the drain activity as this would not cause bubbling of the chest drain. The drain is clearly patent, as indicated by the bubbling which is worse on coughing, and there is minimal drain output. It may be that the drain is not located within the empyema limiting its resolution, however further imaging would be required to determine this.

Discuss (1) | Improve

Next question

Chest drain

A chest drain is a tube inserted into the pleural cavity which creates a one-way valve, allowing movement of air or liquid out of the cavity.

Chest drain insertion is indicated in cases of:
- Pleural effusion
- Pneumothorax not suitable for conservative management or aspiration
- Empyema
- Haemothorax
- Haemopneumothorax
- Chylothorax
- In some cases of penetrating chest wall injury in ventilated patients

Insertion of a chest drain is relatively contraindicated in patients with any of the following:
- INR > 1.3
- Platelet count < 75
- Pulmonary bullae
- Pleural adhesions

Please note, all of the above represent only relative contraindications, addressing respiratory compromise in an emergency situation should always be on an individual case basis.

Once patient consent has been obtained and patient imaging assessed, the patient should be positioned in a supine position or at a 45° angle. The patient's forearm may be positioned behind

the patient's head to allow easy access to the axilla. Identify the 5th intercostal space in the midaxillary line. Alternatively, positioning may be determined by ultrasound guidance, British Thoracic Society Guidance 'strongly recommend' use of ultrasound guidance in all cases of fluid within the pleura. The area should be anaesthetised using local anaesthetic injection (lidocaine, up to 3mg/kg). The drainage tube should then be inserted using a Seldinger technique. The drain tubing should then be secured using either a straight stitch or with an adhesive dressing.

Positioning can be confirmed by aspiration of fluid from the drainage tubing, by 'swinging' of the fluid within the drain tubing when the patient inspires and on chest x-ray.

Complications that may occur and which the patient should be advised of in the process of obtaining consent:

- Failure of insertion - the drain may be abutting the apical pleura, in which case it should be pulled back, or may be subcutaneous or in rare cases could enter the abdominal cavity. In both latter cases, the drain should be removed and re-sited.
- Bleeding - around the site of the drain or into the pleural space
- Infection
- Penetration of the lung
- Re-expansion pulmonary oedema

Re-expansion pulmonary oedema may be preceded by the onset of a cough and/or shortness of breath. In the event of concerns regarding re-expansion pulmonary oedema, the chest drain should be clamped and an urgent chest x-ray should be obtained. To avoid re-expansion pulmonary oedema, it is recommended that the drain tubing should be clamped regularly in the event of rapid fluid output i.e. drain output should not exceed 1L of fluid over a short period of time (less than 6 hours).

Removal of the chest drain is dependent upon the indication for insertion:

- In cases of fluid drainage from the pleural cavity, the drain should be removed when there has been no output for > 24 hours and imaging shows resolution of the fluid collection.
- In cases of pneumothorax, the drain should be removed when it is no longer bubbling spontaneously or when the patient coughs and ideally when imaging shows resolution of the pneumothorax.
- Drains inserted in cases of penetrating chest injury should be reviewed by the specialist to confirm an appropriate time for removal.

123

Next question

Textbooks

High-yield textbook

Extended textbook

Score: **16%**

1	✗
2	✗
3	✗
4	✗
5	✗
6	✗
7	✗
8	✗
9	✗
10	✗
11	✗
12	✓
13	✗
14	✗
15	✗
16	✗
17	✗
18	✗
19	✗
20	✗
21	✗

22	✗
23	✓
24	✗
25	✗
26	✗
27	✗
28	✗
29	✓
30	✗
31	✓
32	✗
33	✗
34	✗
35	✗
36	✓
37	✓
38	✗
39	✗
40	✗
41	✓
42	✗
43	✗
44	✗
45	✗
46	✗
47	✗
48	✗
49	✓
50	✗

All contents of this site are © 2024 Passmedicine Limited

Back to top

A 69-year-old woman presents to the Emergency Department with a one month history of gradually worsening breathlessness. She is generally fit and well but last year was diagnosed with chronic obstructive pulmonary disease (COPD) after a 50-pack-year history of smoking. Around 10 years ago she retired from the local car production plant. On examination she is breathless at rest with a respiratory rate of 18/min and oxygen saturations of 93% on room air.

A chest x-ray is performed:

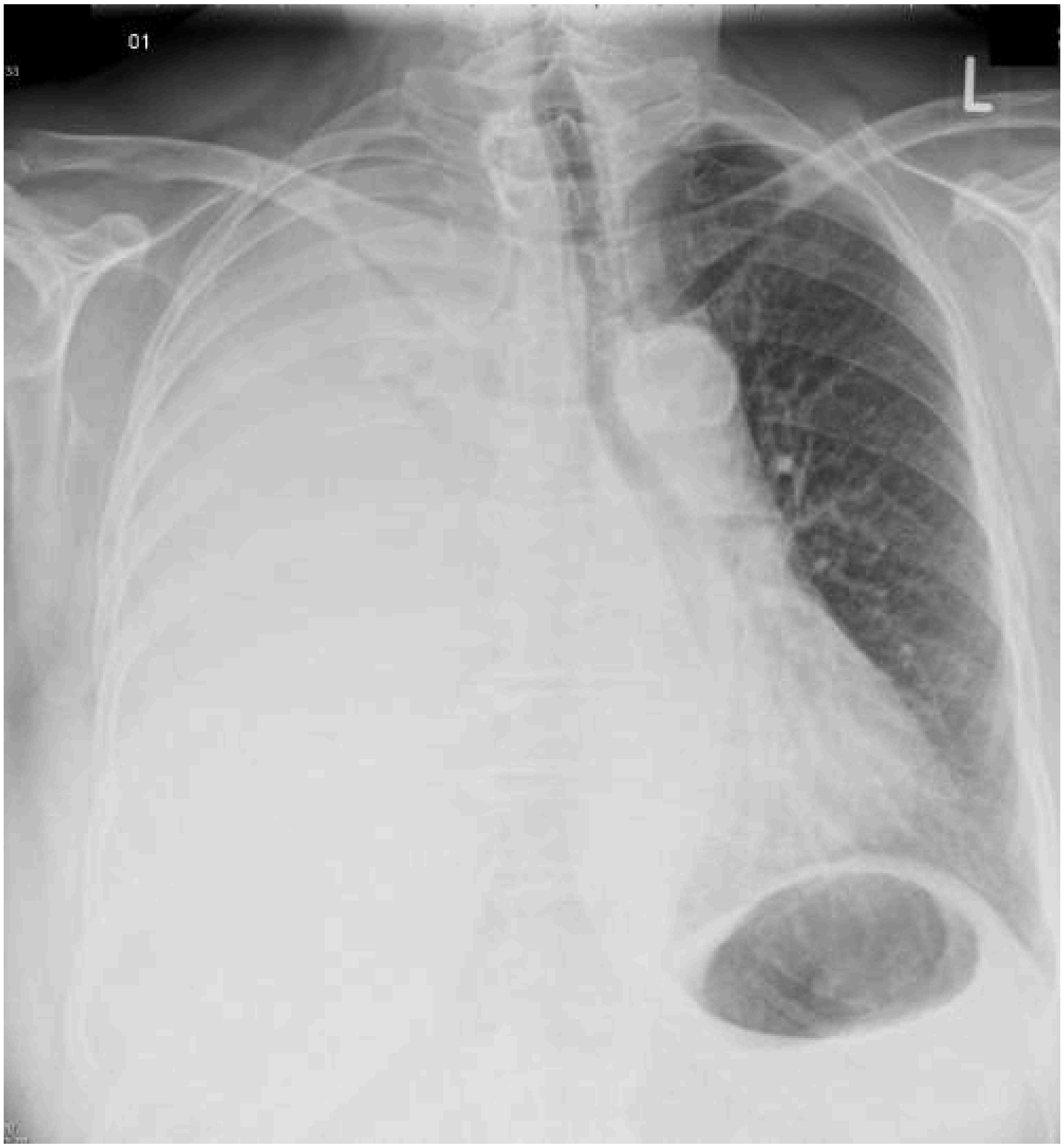

© Image used on license from Radiopaedia

What is the most likely diagnosis?

- Pneumonectomy
- Mesothelioma

- Lung collapse
- Massive pleural effusion
- Ewing sarcoma

Submit answer

Reference ranges

Score: **0%**

1	-
2	-
3	-
4	-
5	-
6	-
7	-
8	-
9	-
10	-
11	-
12	-
13	-
14	-
15	-
16	-
17	-
18	-
19	-
20	-
21	-
22	-
23	-

All contents of this site are © 2024 Passmedicine Limited

A 69-year-old woman presents to the Emergency Department with a one month history of gradually worsening breathlessness. She is generally fit and well but last year was diagnosed with chronic obstructive pulmonary disease (COPD) after a 50-pack-year history of smoking. Around 10 years ago she retired from the local car production plant. On examination she is breathless at rest with a respiratory rate of 18/min and oxygen saturations of 93% on room air.

A chest x-ray is performed:

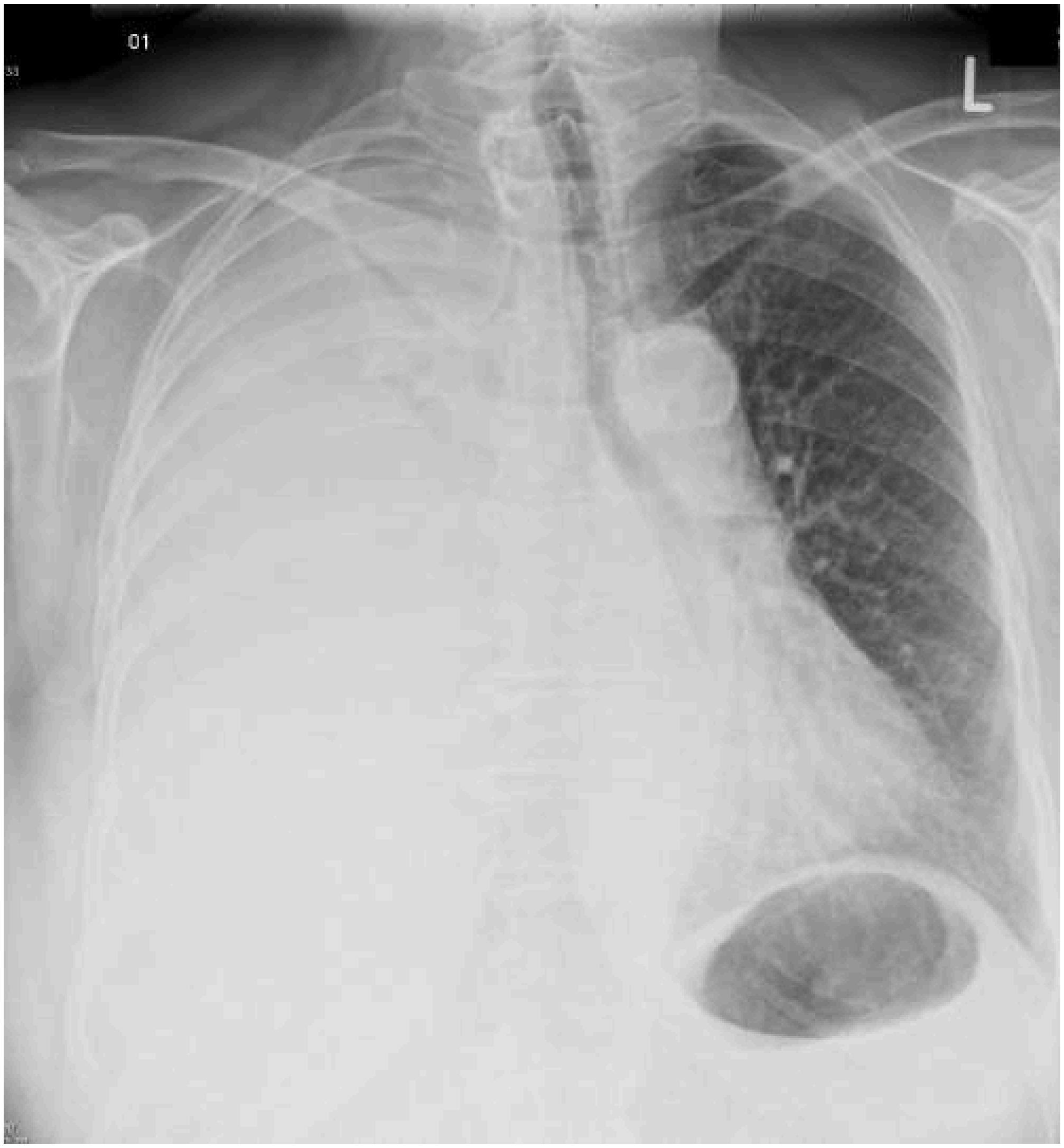

© Image used on license from Radiopaedia

What is the most likely diagnosis?

- Pneumonectomy 6%
- Mesothelioma 6%

Lung collapse 7%

Massive pleural effusion 80%

Ewing sarcoma 1%

The chest x-ray shows that the the trachea (blue) is pushed away the side of the white-out. The other signs of a positive mass effect include leftward bowing of the azygo-oesophageal recess (yellow) and splaying of the ribs on the right.

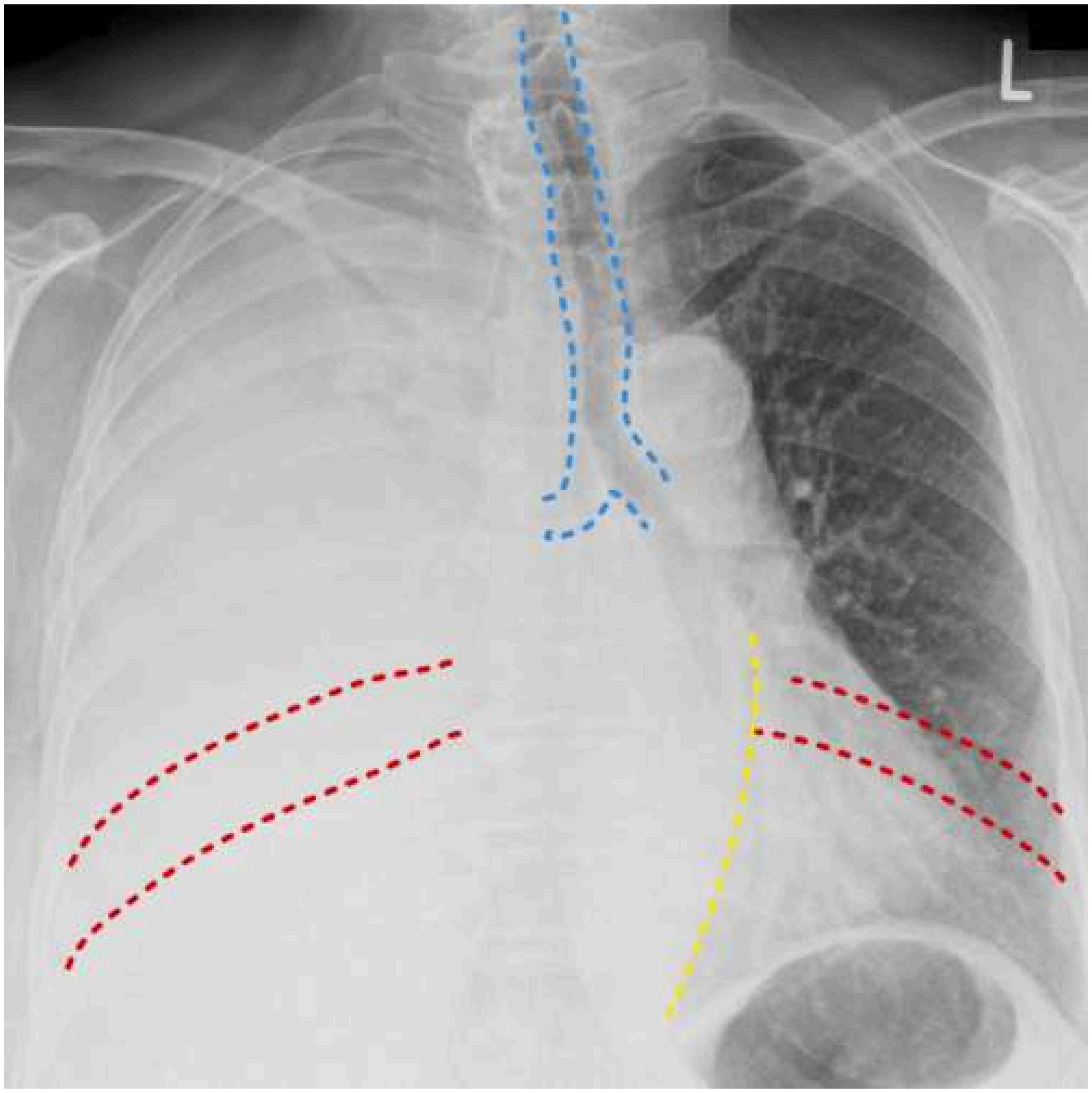

© Image used on license from Radiopaedia

In this case there was an underlying lung cancer.

Discuss (4) Improve

Next question

Chest x-ray: white lung lesions

There are numerous causes of white shadowing in the lungs including:

- consolidation
- pleural effusion
- collapse
- pneumonectomy
- specific lesions e.g. tumours
- fluid e.g. pulmonary oedema

If there is a 'white-out' of a hemithorax it is useful to assess the position of the trachea - is it central, pulled or pushed from the side of opacification.

Trachea pulled toward the white-out	Trachea central	Trachea pushed away from the white-out
Pneumonectomy Complete lung collapse e.g. endobronchial intubation Pulmonary hypoplasia	Consolidation Pulmonary oedema (usually bilateral) Mesothelioma	Pleural effusion Diaphragmatic hernia Large thoracic mass

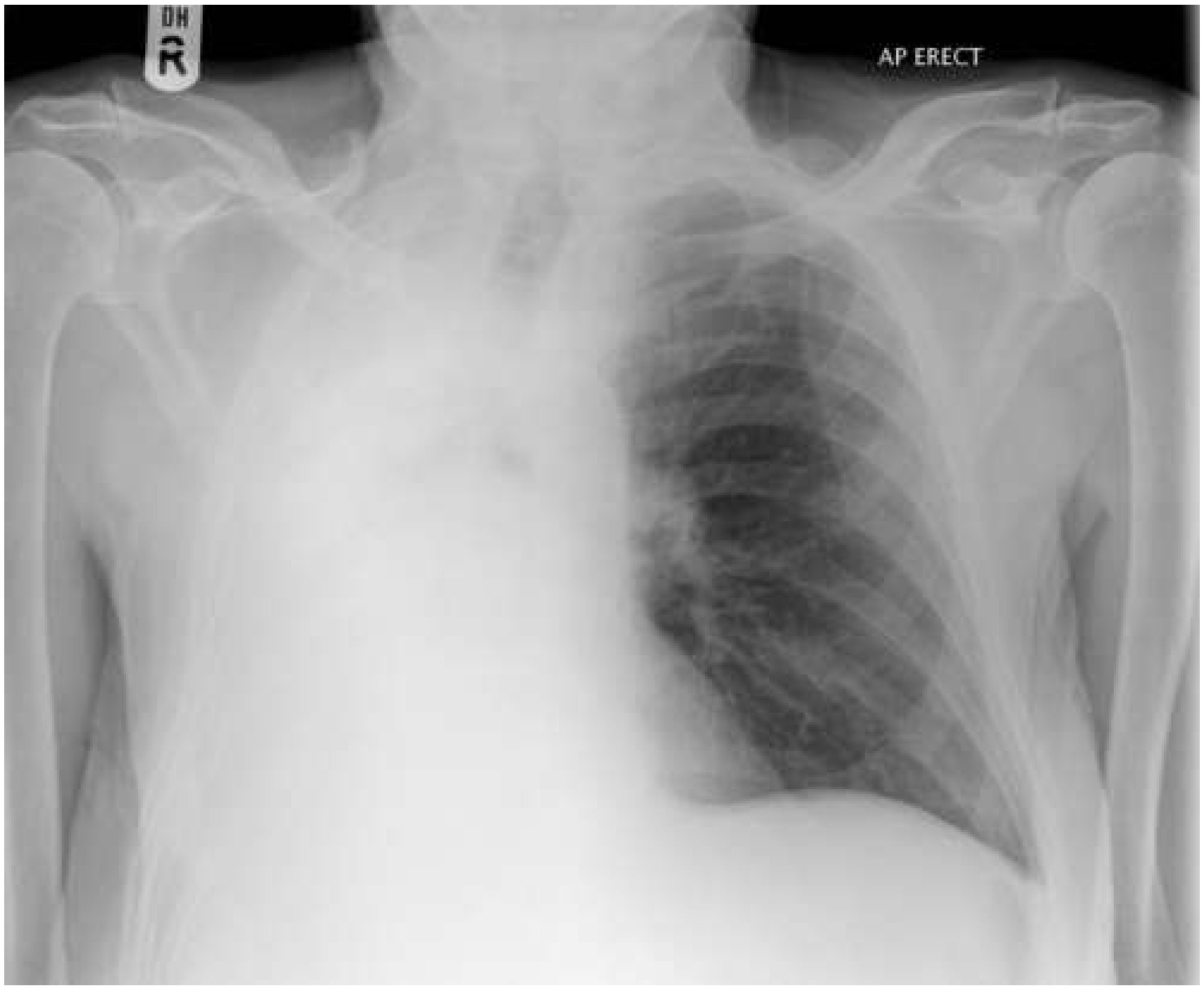

© Image used on license from Radiopaedia

Lung collapse - note how the trachea is pulled towards the side of the white-out

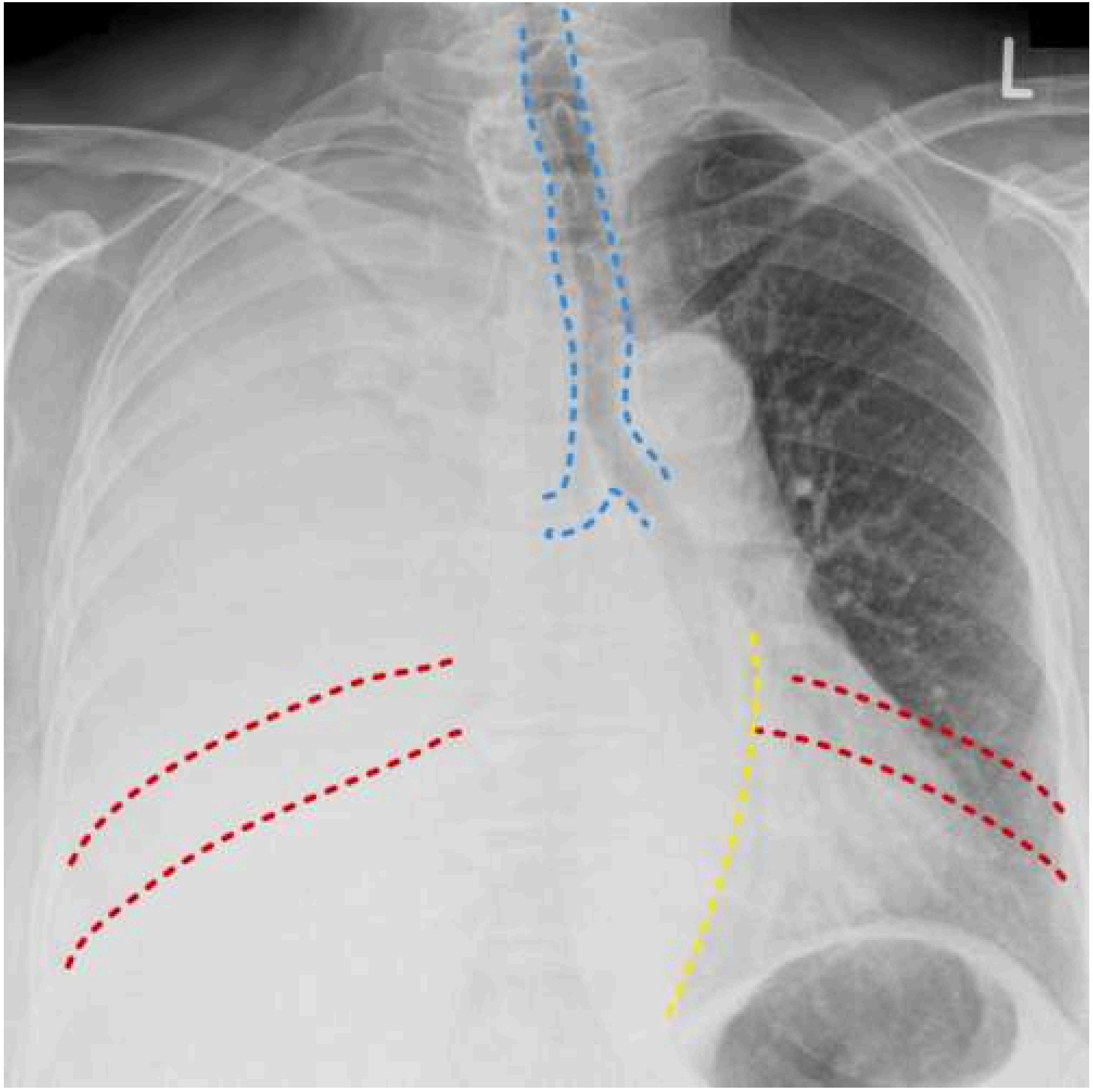

© Image used on license from Radiopaedia

Pleural effusion - note how the trachea (blue) is pushed away the side of the white-out. The other signs of a positive mass effect include leftward bowing of the azygo-oesophageal recess (yellow) and splaying of the ribs on the right (red)

For more information check out the link to the superb Radiology Masterclass website.

123

Next question

Textbooks

High-yield textbook

Extended textbook

Links

Wiki Radiography 13 4

Example of right upper lobe consolidation

Radiology Masterclass 42 6

Fantastic radiology teaching website

Suggest link

Report broken link

Score: **16%**

1	✗
2	✗
3	✗
4	✗
5	✗
6	✗
7	✗
8	✗
9	✗
10	✗
11	✗
12	✓
13	✗
14	✗
15	✗
16	✗

17	✗
18	✗
19	✗
20	✗
21	✗
22	✗
23	✓
24	✗
25	✗
26	✗
27	✗
28	✗
29	✓
30	✗
31	✓
32	✗
33	✗
34	✗
35	✗
36	✓
37	✓
38	✗
39	✗
40	✗
41	✓
42	✗
43	✗
44	✗
45	✗
46	✗
47	✗
48	✗
49	✓
50	✗

All contents of this site are © 2024 Passmedicine Limited

A 39-year-old woman is seen in the respiratory clinic with a 6-week history of progressive shortness of breath and a dry cough. There is no history of fever or weight loss. She has a past medical history of recently-diagnosed asthma for which she is taking regular salbutamol and beclomethasone inhalers although, she reports that they have had little effect on her symptoms. There is no history of smoking and she denies any allergies.

On examination, there is diffuse expiratory wheeze but no audible crackles. Her cardiovascular examination is unremarkable.

Laboratory tests:

Hb	136 g/L	(115 - 160)
Platelets	$201 * 10^9/L$	(150 - 400)
WBC	$9.1 * 10^9/L$	(4.0 - 11.0)
Lymphocytes	$1.6 * 10^9/L$	(1.5 - 4.5)
Neutrophils	$5.5 * 10^9/L$	(2.0 - 7.5)
Eosinophils	$1.2 * 10^9/L$	(0 - 0.4)
CRP	12 mg/L	(< 5)

Aspergillus IgE	Raised

What is the most appropriate next step in the management of this patient?

- Intravenous amphotericin B
- Intravenous co-trimoxazole and methylprednisolone
- Oral montelukast
- Oral prednisolone
- Salbutamol and ipratropium nebulisers

Submit answer

Reference ranges

Score: **0%**

1	-
2	-
3	-
4	-
5	-
6	-
7	-
8	-
9	-
10	-
11	-
12	-
13	-
14	-
15	-
16	-
17	-
18	-
19	-
20	-
21	-
22	-
23	-
24	-

All contents of this site are © 2024 Passmedicine Limited

A 39-year-old woman is seen in the respiratory clinic with a 6-week history of progressive shortness of breath and a dry cough. There is no history of fever or weight loss. She has a past medical history of recently-diagnosed asthma for which she is taking regular salbutamol and beclomethasone inhalers although, she reports that they have had little effect on her symptoms. There is no history of smoking and she denies any allergies.

On examination, there is diffuse expiratory wheeze but no audible crackles. Her cardiovascular examination is unremarkable.

Laboratory tests:

Hb	136 g/L	(115 - 160)
Platelets	201 * 10^9/L	(150 - 400)
WBC	9.1 * 10^9/L	(4.0 - 11.0)
Lymphocytes	1.6 * 10^9/L	(1.5 - 4.5)
Neutrophils	5.5 * 10^9/L	(2.0 - 7.5)
Eosinophils	1.2 * 10^9/L	(0 - 0.4)
CRP	12 mg/L	(< 5)

Aspergillus IgE	Raised

What is the most appropriate next step in the management of this patient?

- Intravenous amphotericin B 18%
- Intravenous co-trimoxazole and methylprednisolone 6%
- Oral montelukast 10%
- Oral prednisolone 65%
- Salbutamol and ipratropium nebulisers 1%

Oral glucocorticoids are the treatment of choice for allergic bronchopulmonary aspergillosis

Important for me Less important

The diagnosis here is allergic bronchopulmonary aspergillosis (ABPA). It is a hypersensitivity reaction to the fungus *Aspergillus* causing an eosinophilic pneumonia. Presenting symptoms are similar to asthma and include dyspnoea, dry cough and wheeze. Patients with ABPA are commonly misdiagnosed as having asthma and standard treatments for asthma (e.g. salbutamol inhalers) have little benefit. This patient describes similar symptoms of shortness of breath and a dry cough. Furthermore, her blood tests demonstrate a raised eosinophil count and IgE level, both of which point towards ABPA. The treatment of choice is **oral prednisolone** to help facilitate the clearing of pulmonary infiltrates.

Intravenous amphotericin B is used in the treatment of systemic fungal infections, including invasive *Candida albicans* or invasive aspergillosis. Invasive aspergillosis is uncommon and is mostly seen in immunosuppressed patients and presents with systemic illness. Amphotericin B is not routinely given first-line to treat infections with *Aspergillus*. Instead, fluconazole or itraconazole can be given, if indicated. However, the combination of wheeze, shortness of breath, and dry cough are more in keeping with ABPA, for which oral corticosteroids are the most appropriate treatment.

Intravenous co-trimoxazole and methylprednisolone are used in the treatment of *Pneumocystis jiroveci* pneumonia (PCP). PCP presents in a similar way to this patient with dyspnoea, fever and a dry cough. However, PCP is mostly seen in immunocompromised patients, such as those with HIV or on immunosuppressant medications. There is nothing in this patient's history to suggest immunosuppression, therefore it is likely that PCP is not the underlying diagnosis.

If asthma is not controlled with salbutamol and inhaled corticosteroid inhalers, the dose of the corticosteroid can be increased. Failing this, the next step in the management of asthma includes the addition of a leukotriene antagonist such as **montelukast**. However, this patient's history and laboratory findings point toward a diagnosis of ABPA over poorly controlled asthma, for which oral corticosteroids is the preferred method of treatment.

Salbutamol and ipratropium nebulisers are used in the acute treatment of asthma. However, it plays no role in the treatment of ABPA.

Discuss (2) Improve

Next question

Allergic bronchopulmonary aspergillosis

Allergic bronchopulmonary aspergillosis results from an allergy to *Aspergillus spores*. In the exam questions often give a history of bronchiectasis and eosinophilia.

Features

- bronchoconstriction: wheeze, cough, dyspnoea. Patients may have a previous label of asthma
- bronchiectasis (proximal)

Investigations

- eosinophilia
- flitting CXR changes
- positive radioallergosorbent (RAST) test to Aspergillus
- positive IgG precipitins (not as positive as in aspergilloma)
- raised IgE

Management

- oral glucocorticoids
- itraconazole is sometimes introduced as a second-line agent

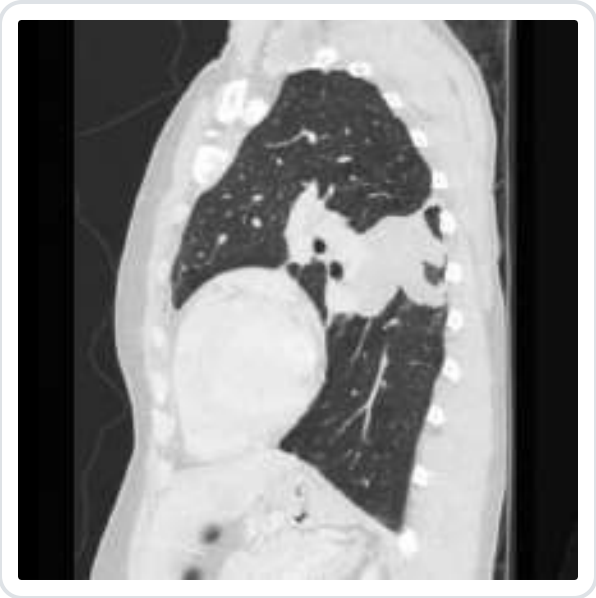

+ Q 123

Next question >

Textbooks

High-yield textbook

Extended textbook

Score: **16%**

1	✗
2	✗
3	✗
4	✗
5	✗
6	✗
7	✗
8	✗
9	✗
10	✗
11	✗
12	✓
13	✗
14	✗
15	✗
16	✗
17	✗
18	✗
19	✗
20	✗
21	✗
22	✗
23	✓
24	✗
25	✗
26	✗
27	✗
28	✗
29	✓

30	✗
31	✓
32	✗
33	✗
34	✗
35	✗
36	✓
37	✓
38	✗
39	✗
40	✗
41	✓
42	✗
43	✗
44	✗
45	✗
46	✗
47	✗
48	✗
49	✓
50	✗

All contents of this site are © 2024 Passmedicine Limited

Back to top

A 35-year-old female with a past medical history of sinusitis and asthma for four years is admitted with a pyrexia and new onset dyspnoea and ankle swelling. Two weeks prior to admission she had noticed blood streaks were present in her sputum.

On examination, she had widespread wheeze and bi-basal crepitations on auscultation of her chest. Her saturations are 94% without oxygen but come up to 99% after treatment with salbutamol and ipratropium bromide nebulisers and oxygen therapy.

She has a heart rate of 112 beats per minute, normal heart sounds and a raised JVP. She has pitting oedema up to her knees. Examination of her abdominal system is unremarkable.

Haemoglobin	102 g/L
White cell count	11.2 Ã— 109/L
Eosinophil count	1.9 Ã— 109/L
Platelet count	478 Ã— 109/L
International normalised ratio	1.3

Serum sodium	135 mmol/L
Serum potassium	5.5 mmol/L
Serum urea	21 mmol/L
Serum creatinine	211 umol/L
CRP	22 mg/l
Blood cultures	Coagulase-negative staphylococci
ANCA positive	immunostaining awaited

Urine dip- positive for protein and blood

CXR: Bi-basal non specific shadowing

What is the most likely diagnosis?

- Churg-Strauss syndrome

- Systematic inflammatory response syndrome
- Systematic lupus erythematous
- Granulomatosis with polyangiitis
- Microscopic polyangiitis

Submit answer

Reference ranges

Score: **0%**

1 -
2 -
3 -
4 -
5 -
6 -
7 -
8 -
9 -
10 -
11 -
12 -
13 -
14 -
15 -
16 -
17 -
18 -
19 -
20 -
21 -
22 -

23	-
24	-
25	-

All contents of this site are © 2024 Passmedicine Limited

PassMedicine

A 35-year-old female with a past medical history of sinusitis and asthma for four years is admitted with a pyrexia and new onset dyspnoea and ankle swelling. Two weeks prior to admission she had noticed blood streaks were present in her sputum.

On examination, she had widespread wheeze and bi-basal crepitations on auscultation of her chest. Her saturations are 94% without oxygen but come up to 99% after treatment with salbutamol and ipratropium bromide nebulisers and oxygen therapy.

She has a heart rate of 112 beats per minute, normal heart sounds and a raised JVP. She has pitting oedema up to her knees. Examination of her abdominal system is unremarkable.

Haemoglobin	102 g/L
White cell count	11.2 Ã— 109/L
Eosinophil count	1.9 Ã— 109/L
Platelet count	478 Ã— 109/L
International normalised ratio	1.3

Serum sodium	135 mmol/L
Serum potassium	5.5 mmol/L
Serum urea	21 mmol/L
Serum creatinine	211 umol/L
CRP	22 mg/l
Blood cultures	Coagulase-negative staphylococci
ANCA positive	immunostaining awaited

Urine dip- positive for protein and blood

CXR: Bi-basal non specific shadowing

What is the most likely diagnosis?

Churg-Strauss syndrome 68%

Systematic inflammatory response syndrome 2%

Systematic lupus erythematous 1%

Granulomatosis with polyangiitis 27%

Microscopic polyangiitis 2%

This patient has essentially presented with acute kidney injury and is ANCA positive. ANCA may be positive in granulomatosis with polyangiitis, Churg Strauss syndrome and microscopic polyangiitis all of which can affect the kidneys. However, the history of asthma and sinusitis coupled with a raised eosinophil count make Churg Strauss syndrome the most likely option.

Systematic Inflammatory response syndrome is unlikely to explain the entire clinical picture. Additionally, although blood cultures are positive this is most likely to be a contaminant considering the organism and the trivial C-reactive protein.

Discuss (13) Improve

Next question

Eosinophilic granulomatosis with polyangiitis (Churg-Strauss syndrome)

Eosinophilic granulomatosis with polyangiitis (EGPA) is now the preferred term for **Churg-Strauss syndrome**. It is an ANCA associated small-medium vessel vasculitis.

Features

- asthma
- blood eosinophilia (e.g. > 10%)
- paranasal sinusitis
- mononeuritis multiplex
- pANCA positive in 60%

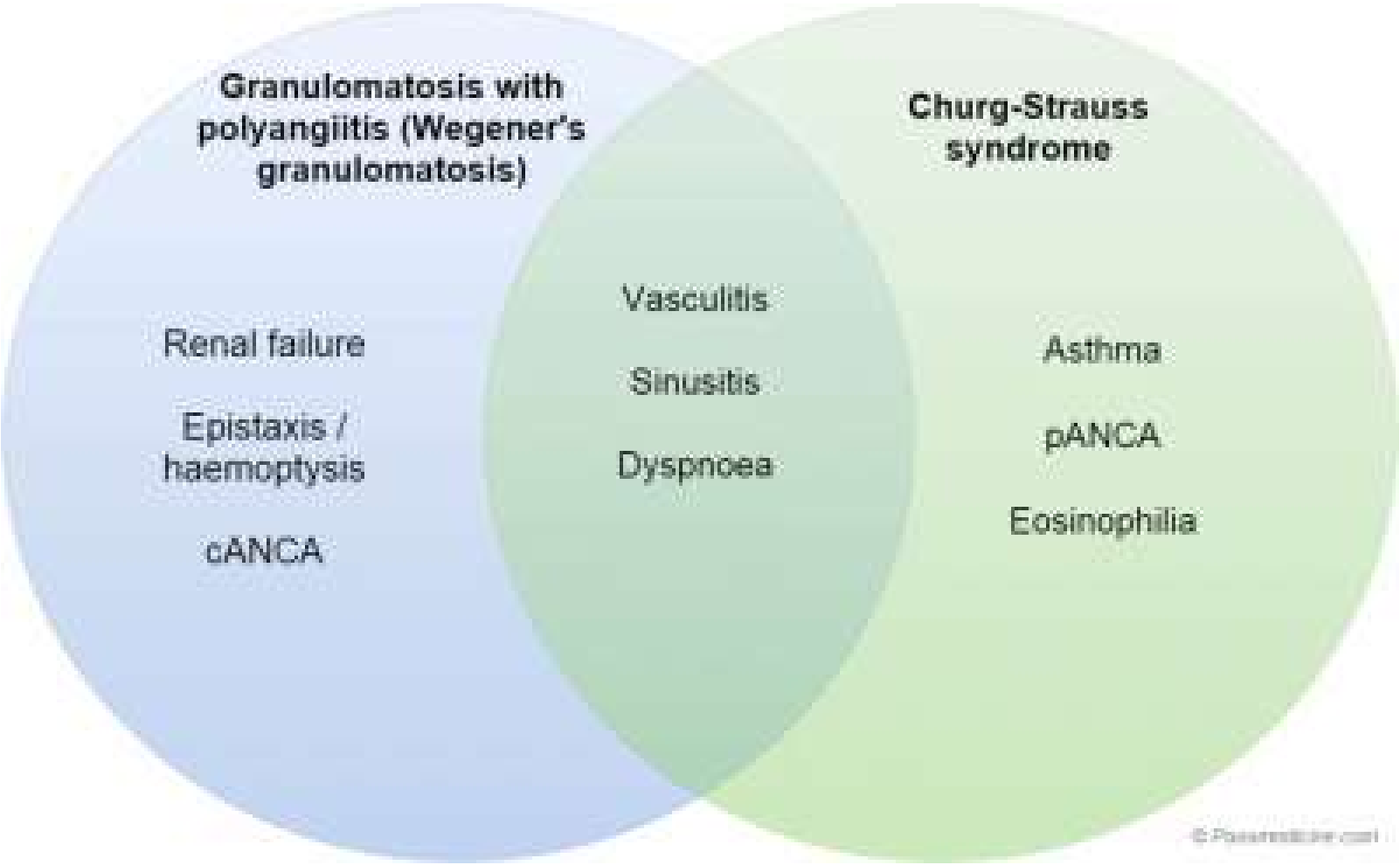

Comparison of granulomatosis with polyangiitis and Churg-Strauss syndrome

Leukotriene receptor antagonists may precipitate the disease.

123

Next question >

Textbooks

High-yield textbook

Extended textbook

Media

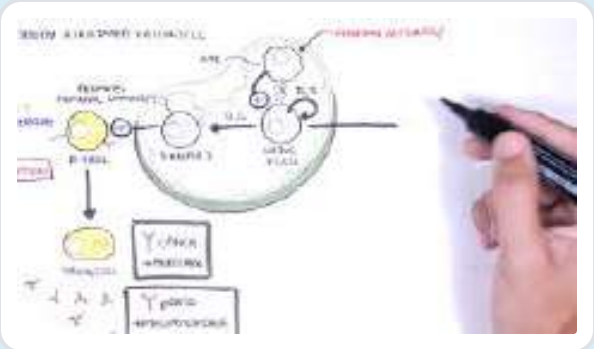

ANCA (Anti-Neutrophil Cytoplasmic Antibody) Associated Vasculitis - Causes, Pathophysiology, Types

Armando Hasudungan - YouTube

3 3

Report broken media

Score: **16%**

1	✗
2	✗
3	✗
4	✗
5	✗
6	✗
7	✗
8	✗
9	✗
10	✗
11	✗
12	✓
13	✗
14	✗
15	✗
16	✗
17	✗
18	✗
19	✗
20	✗
21	✗
22	✗
23	✓
24	✗
25	✗
26	✗
27	✗
28	✗

29	✓
30	✗
31	✓
32	✗
33	✗
34	✗
35	✗
36	✓
37	✓
38	✗
39	✗
40	✗
41	✓
42	✗
43	✗
44	✗
45	✗
46	✗
47	✗
48	✗
49	✓
50	✗

All contents of this site are © 2024 Passmedicine Limited

Back to top

A 51-year-old woman is being investigated by the respiratory team. She reports a four-month history of dry cough with associated lethargy and weight loss. She has no relevant past medical history and has never smoked.

A chest x-ray is displayed below:

© Image used on license from Radiopaedia

Which further test would be most appropriate to aid in diagnosis?

- Cytoplasmic antineutrophil cytoplasmic antibodies (cANCA)
- Interferon-gamma release assay (IGRA)
- Perinuclear antineutrophil cytoplasmic antibodies (pANCA)
- Serum angiotensin-converting enzyme (ACE)
- Sputum microscopy, culture, and sensitivity (MCS)

Submit answer

Reference ranges

Score: **0%**

1	-
2	-
3	-
4	-
5	-
6	-
7	-
8	-
9	-
10	-
11	-
12	-
13	-
14	-
15	-
16	-
17	-
18	-
19	-
20	-
21	-
22	-
23	-
24	-
25	-
26	-

All contents of this site are © 2024 Passmedicine Limited

A 51-year-old woman is being investigated by the respiratory team. She reports a four-month history of dry cough with associated lethargy and weight loss. She has no relevant past medical history and has never smoked.

A chest x-ray is displayed below:

© Image used on license from Radiopaedia

Which further test would be most appropriate to aid in diagnosis?

Cytoplasmic antineutrophil cytoplasmic antibodies (cANCA)	3%
Interferon-gamma release assay (IGRA)	6%
Perinuclear antineutrophil cytoplasmic antibodies (pANCA)	2%
Serum angiotensin-converting enzyme (ACE)	84%
Sputum microscopy, culture, and sensitivity (MCS)	5%

This woman has sarcoidosis. This explains her clinical symptoms and is confirmed by the bilateral lymphadenopathy on her chest x-ray. Serum ACE is a specific blood biomarker for sarcoidosis and is, therefore, the correct answer in this instance.

cANCA is a biochemical marker for granulomatosis with polyangiitis (previously known as Wegner's granulomatosis). This classically presents with haemoptysis, rhinitis, epistaxis, and potentially renal involvement. The typical x-ray findings include nodules with or without cavitations, pulmonary haemorrhages, and peripheral consolidation. As none of these symptoms or imaging features are to be found in this case, this is not the diagnosis and therefore pANCA is incorrect.

IGRA is a test used to diagnose tuberculosis (TB) infection. Although the symptoms here could be indicative of active pulmonary TB, this classically presents with upper lobe consolidation on chest x-ray. As this is not present, TB is not the diagnosis here. Therefore an IGRA would not be an appropriate test to order in this instance.

pANCA is a biochemical marker for eosinophilic granulomatosis with polyangiitis (previously known as Churg-Strauss syndrome). This typically presents with asthmatic features as well as other sequelae of vasculitis. The x-ray findings in eosinophilic granulomatosis with polyangiitis include peripheral consolidation and pleural effusions. As none of these symptoms or imaging features are to be found in this case, this is not the diagnosis and therefore pANCA is incorrect.

The x-ray here shows bilateral hilar lymphadenopathy rather than focal areas of consolidation and is, therefore, more indicative of sarcoidosis. Sputum MCS is very effective in identifying organisms and assessing sensitivities in infective pathologies however have no role in sarcoidosis as this is an autoimmune process. This is therefore an incorrect answer.

Discuss (5) | Improve

Next question >

Sarcoidosis: investigation

There is no one diagnostic test for sarcoidosis and hence diagnosis is still largely clinical. ACE levels have a sensitivity of 60% and specificity of 70% and are therefore not reliable in the diagnosis of sarcoidosis although they may have a role in monitoring disease activity. Routine bloods may show hypercalcaemia (seen in 10% if patients) and a raised ESR

A chest x-ray may show the following changes:

- stage 0 = normal

- stage 1 = bilateral hilar lymphadenopathy (BHL)
- stage 2 = BHL + interstitial infiltrates
- stage 3 = diffuse interstitial infiltrates only
- stage 4 = diffuse fibrosis

Other investigations
- spirometry: may show a restrictive defect
- tissue biopsy: non-caseating granulomas
- gallium-67 scan - not used routinely
- the Kveim test (where part of the spleen from a patient with known sarcoidosis is injected under the skin) is no longer performed due to concerns about cross-infection

+ Q 123

Next question >

Textbooks

High-yield textbook

Extended textbook

Media

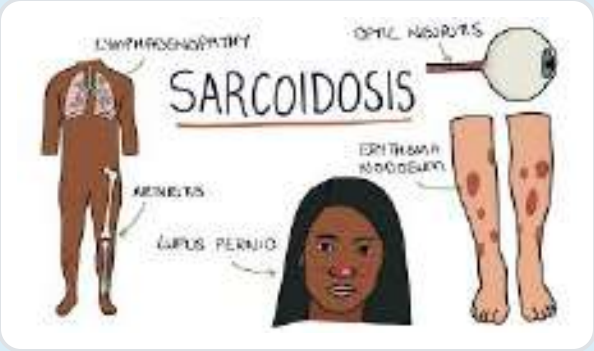

Sarcoidosis

Sarcoidosis - YouTube 7 0

Sarcoidosis

Osmosis - YouTube 4 0

Report broken media

Score: **16%**

1	✗
2	✗
3	✗
4	✗
5	✗
6	✗
7	✗
8	✗
9	✗
10	✗
11	✗
12	✓
13	✗
14	✗
15	✗
16	✗
17	✗

18	✗
19	✗
20	✗
21	✗
22	✗
23	✓
24	✗
25	✗
26	✗
27	✗
28	✗
29	✓
30	✗
31	✓
32	✗
33	✗
34	✗
35	✗
36	✓
37	✓
38	✗
39	✗
40	✗
41	✓
42	✗
43	✗
44	✗
45	✗
46	✗
47	✗
48	✗
49	✓
50	✗

All contents of this site are © 2024 Passmedicine Limited

Back to top

A 50-year-old gentleman presents with shortness of breath. He is a current smoker of 20 cigarettes per day and used to work a coal miner. His body mass index (BMI) is 40 kg/m^2. His spirometry results are as follows:

Forced expiratory volume in 1 second (FEV1)	3.05 (79% predicted)
Forced vital capacity (FVC)	3.27 (70% predicted)
Diffusion capacity of the lung (DLCO)	86% predicted
Rate of carbon monoxide uptake (KCO)	105% predicted

What is the likely cause of this gentleman's shortness of breath?

- Obesity
- Pneumoconiosis
- Chronic obstructive pulmonary disease (COPD)
- Idiopathic pulmonary fibrosis
- Asthma

Submit answer

Reference ranges

5	-
6	-
7	-
8	-
9	-
10	-
11	-
12	-
13	-
14	-
15	-
16	-
17	-
18	-
19	-
20	-
21	-
22	-
23	-
24	-
25	-
26	-
27	-

All contents of this site are © 2024 Passmedicine Limited

Back to top

A 50-year-old gentleman presents with shortness of breath. He is a current smoker of 20 cigarettes per day and used to work a coal miner. His body mass index (BMI) is 40 kg/m^2. His spirometry results are as follows:

Forced expiratory volume in 1 second (FEV1)	3.05 (79% predicted)
Forced vital capacity (FVC)	3.27 (70% predicted)
Diffusion capacity of the lung (DLCO)	86% predicted
Rate of carbon monoxide uptake (KCO)	105% predicted

What is the likely cause of this gentleman's shortness of breath?

- Obesity 41%
- Pneumoconiosis 33%
- Chronic obstructive pulmonary disease (COPD) 8%
- Idiopathic pulmonary fibrosis 14%
- Asthma 4%

This gentleman has evidence of restrictive lung disease on his spirometry results. A low DLCO but a high KCO implies that he has an extra-pulmonary cause of his restriction. Obesity is the only extra-pulmonary cause of a restrictive deficit from the list of options. COPD and asthma cause obstructive lung disease and pneumoconiosis and idiopathic pulmonary fibrosis and intrapulmonary causes of restrictive lung disease.

Discuss (9) Improve

Next question

Obstructive vs. restrictive lung diseases

<table>
<tr><th></th><th>Obstructive</th><th>Restrictive</th></tr>
<tr><td>Spirometry</td><td>FEV1/FVC < 80%</td><td>FEV1/FVC > 80%</td></tr>
<tr><td>Examples</td><td>Chronic obstructive pulmonary disease
chronic bronchitis
emphysema: including alpha-1 antitrypsin deficiency
Asthma

Bronchiectasis</td><td>Intrapulmonary
idiopathic pulmonary fibrosis
extrinsic allergic alveolitis
coal worker's pneumoconiosis/progressive massive fibrosis
silicosis
sarcoidosis
histiocytosis
drug-induced fibrosis: amiodarone, bleomycin, methotrexate
asbestosis
Extrapulmonary
neuromuscular disease: polio, myasthenia gravis
obesity
scoliosis</td></tr>
</table>

+ Q 123

Next question ›

Textbooks

High-yield textbook

Extended textbook

Media

Restrictive lung disease

Osmosis - YouTube 4 0

Peak Flow and Spirometry - Lung Function Tests

Oxford Medical Education - YouTube 4 0

Report broken media

Score: **16%**

1	✗
2	✗
3	✗
4	✗
5	✗
6	✗
7	✗
8	✗
9	✗
10	✗
11	✗
12	✓
13	✗
14	✗
15	✗

16	✗
17	✗
18	✗
19	✗
20	✗
21	✗
22	✗
23	✓
24	✗
25	✗
26	✗
27	✗
28	✗
29	✓
30	✗
31	✓
32	✗
33	✗
34	✗
35	✗
36	✓
37	✓
38	✗
39	✗
40	✗
41	✓
42	✗
43	✗
44	✗
45	✗
46	✗
47	✗
48	✗
49	✓
50	✗

All contents of this site are © 2024 Passmedicine Limited

A 79-year-old is investigated for weight loss.

© Image used on license from Radiopaedia

What is the most likely diagnosis?

- Paget's disease of the bone
- Lung cancer
- Liver cancer
- Reactivation of pulmonary tuberculosis
- Mesothelioma

Submit answer

Reference ranges

Score: **0%**

1	-
2	-
3	-
4	-
5	-
6	-
7	-
8	-
9	-
10	-
11	-
12	-
13	-
14	-
15	-
16	-
17	-
18	-
19	-
20	-
21	-
22	-
23	-
24	-
25	-
26	-
27	-
28	-

All contents of this site are © 2024 Passmedicine Limited

Back to top

A 79-year-old is investigated for weight loss.

© Image used on license from Radiopaedia

What is the most likely diagnosis?

- Paget's disease of the bone 1%
- Lung cancer 69%
- Liver cancer 1%
- Reactivation of pulmonary tuberculosis 9%
- Mesothelioma 19%

The x-ray shows a large right sided hilar mass with resultant collapse of the right upper lobe. As a consequence the hyperexpanded right middle and lower lobes are hyperlucent ('blacker').

Discuss (6) | Improve

Next question

Chest x-ray: lobar collapse

Common causes of lobar collapse include:

- lung cancer (the most common cause in older adults)
- asthma (due to mucous plugging)
- foreign body

The general signs of lobar collapse on a chest x-ray are as follows:

- tracheal deviation towards the side of the collapse
- mediastinal shift towards the side of the collapse
- elevation of the hemidiaphragm

123

Next question

Textbooks

High-yield textbook

Extended textbook

Links

British Institute of Radiology 4 3

Unofficial guide to radiology

Suggest link

Report broken link

Media

[Golden S sign - radiology video tutorial (x-ray)]

Radiology Channel - YouTube 👍 11 👎 1

Report broken media

Score: **16%**

1	✗
2	✗
3	✗
4	✗
5	✗
6	✗
7	✗
8	✗
9	✗
10	✗
11	✗
12	✓
13	✗
14	✗
15	✗
16	✗
17	✗
18	✗
19	✗
20	✗
21	✗
22	✗

23	✓
24	✗
25	✗
26	✗
27	✗
28	✗
29	✓
30	✗
31	✓
32	✗
33	✗
34	✗
35	✗
36	✓
37	✓
38	✗
39	✗
40	✗
41	✓
42	✗
43	✗
44	✗
45	✗
46	✗
47	✗
48	✗
49	✓
50	✗

All contents of this site are © 2024 Passmedicine Limited

Back to top

A 56-year-old woman presents to clinic for review following investigations and MDT discussion. She has chronic exertional dyspnoea and following a restrictive pattern detected on spirometry and changes on high-resolution CT scanning she has been diagnosed with idiopathic pulmonary fibrosis. What medication can be used to modify disease progression?

- Azathioprine
- Prednisolone
- Co-trimoxazole
- Sildenafil
- Pirfenidone

Submit answer

Reference ranges

Score: **0%**

1 -
2 -
3 -
4 -
5 -
6 -
7 -
8 -
9 -
10 -
11 -

12	-
13	-
14	-
15	-
16	-
17	-
18	-
19	-
20	-
21	-
22	-
23	-
24	-
25	-
26	-
27	-
28	-
29	-

All contents of this site are © 2024 Passmedicine Limited

Back to top

A 56-year-old woman presents to clinic for review following investigations and MDT discussion. She has chronic exertional dyspnoea and following a restrictive pattern detected on spirometry and changes on high-resolution CT scanning she has been diagnosed with idiopathic pulmonary fibrosis. What medication can be used to modify disease progression?

Azathioprine	1%
Prednisolone	3%
Co-trimoxazole	1%
Sildenafil	2%
Pirfenidone	93%

The correct answer is pirfenidone. Guidelines recommend supportive care, pulmonary rehabilitation and supplementary oxygen, but in very selective patients pirfenidone can be used. All of the other medication options have been attempted, but are advised by NICE that there is insufficient evidence to recommend their use. Patients are commonly prescribed azathioprine and prednisolone but this does not affect the disease course and does not help symptom control. Co-trimoxazole is useful primarily in immunosuppression from HIV to prevent infection, whilst sildenafil, a type 5 phosphodiesterase inhibitor, is more useful in pulmonary arterial hypertension.

Discuss Improve

Next question

Idiopathic pulmonary fibrosis

Idiopathic pulmonary fibrosis (IPF, previously termed cryptogenic fibrosing alveolitis) is a chronic lung condition characterised by progressive fibrosis of the interstitium of the lungs. Whilst there are many causes of lung fibrosis (e.g. medications, connective tissue disease, asbestos) the term IPF is reserved when no underlying cause exists.

IPF is typically seen in patients aged 50-70 years and is twice as common in men.

Features

- progressive exertional dyspnoea
- bibasal fine end-inspiratory crepitations on auscultation
- dry cough
- clubbing

Diagnosis

- spirometry: classically a restrictive picture (FEV1 normal/decreased, FVC decreased, FEV1/FVC increased)
- impaired gas exchange: reduced transfer factor (TLCO)
- imaging: bilateral interstitial shadowing (typically small, irregular, peripheral opacities - 'ground-glass' - later progressing to 'honeycombing') may be seen on a chest x-ray but high-resolution CT scanning is the investigation of choice and required to make a diagnosis of IPF
- ANA positive in 30%, rheumatoid factor positive in 10% but this does not necessarily mean that the fibrosis is secondary to a connective tissue disease. Titres are usually low

Management

- pulmonary rehabilitation
- very few medications have been shown to give any benefit in IPF. There is some evidence that pirfenidone (an antifibrotic agent) may be useful in selected patients (see NICE guidelines)
- many patients will require supplementary oxygen and eventually a lung transplant

Prognosis

- poor, average life expectancy is around 3-4 years

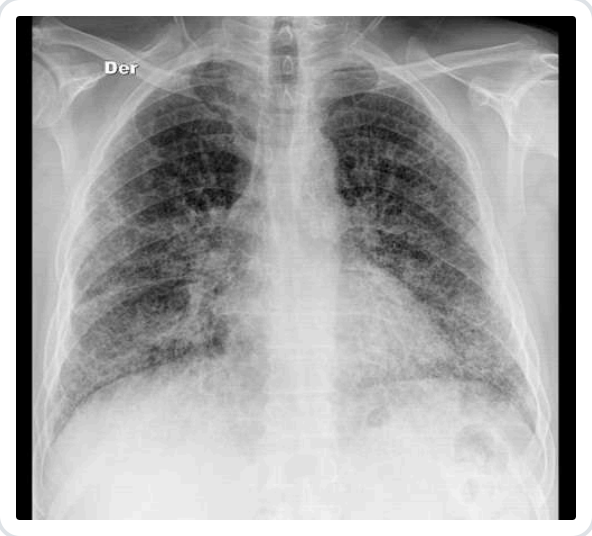

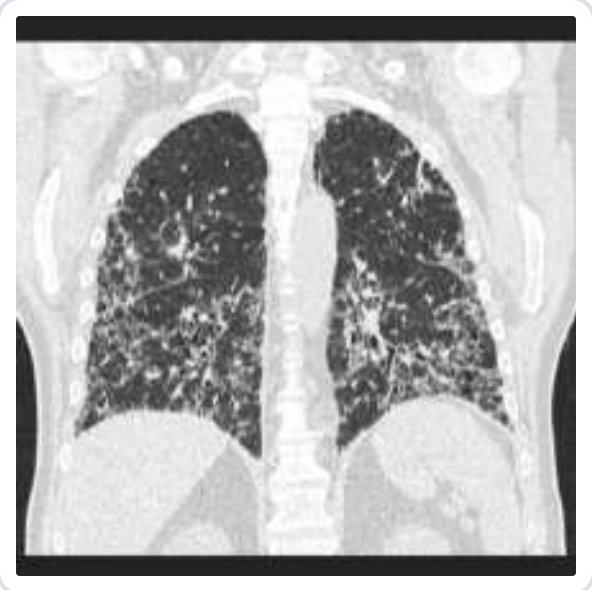

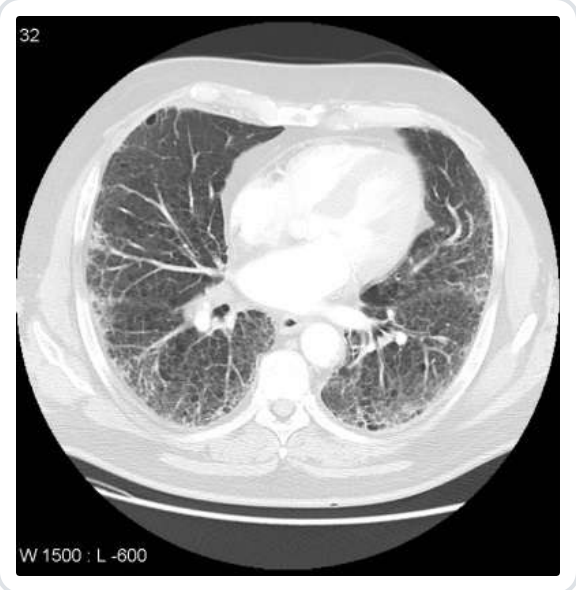

123

Next question

Textbooks

High-yield textbook

Extended textbook

Links

Royal College of Physicians 13 10

Update in diagnosis and management of interstitial lung disease

NICE 11 6

2013 Idiopathic pulmonary fibrosis guidelines

Suggest link

Report broken link

Media

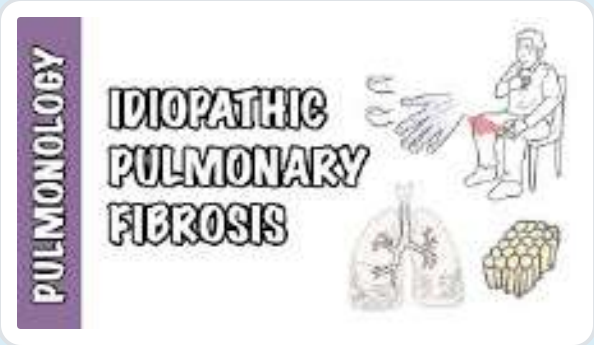

Idiopathic pulmonary fibrosis

Armando Hasudungan - YouTube 6 0

Interstitial Lung Disease (ILD) - Classification, pathophysiology, signs and symptoms

Armando Hasudungan - YouTube 5 0

Idiopathic pulmonary fibrosis

Osmosis - YouTube

4 0

Report broken media

Score: **16%**

1	✗
2	✗
3	✗
4	✗
5	✗
6	✗
7	✗
8	✗
9	✗
10	✗
11	✗
12	✓
13	✗
14	✗
15	✗
16	✗
17	✗
18	✗
19	✗
20	✗
21	✗
22	✗
23	✓
24	✗

25	✗
26	✗
27	✗
28	✗
29	✓
30	✗
31	✓
32	✗
33	✗
34	✗
35	✗
36	✓
37	✓
38	✗
39	✗
40	✗
41	✓
42	✗
43	✗
44	✗
45	✗
46	✗
47	✗
48	✗
49	✓
50	✗

All contents of this site are © 2024 Passmedicine Limited

Back to top

PassMedicine

A 52-year-old woman presents to the respiratory clinic with breathlessness. She was referred from her GP who was concerned about breathlessness and a chest X-ray demonstrating left pleural effusion. She had recently undergone a left-sided wide local excision with axillary clearance for ductal carcinoma in sit.

She has unilaterally reduced breath sounds with dullness on percussion and deviation of the trachea away from that side of her chest. A plural aspirate is obtained and is milky white in colour. The two possibilities considered are chylothorax from pseudochylothorax.

What investigation would aid in distinguishing chylothorax from pseudochylothorax?

- pH
- Albumin
- Microscopy
- Triglycerides
- Amylase

Submit answer

Reference ranges

Score: **0%**

1 -
2 -
3 -
4 -
5 -

6 -
7 -
8 -
9 -
10 -
11 -
12 -
13 -
14 -
15 -
16 -
17 -
18 -
19 -
20 -
21 -
22 -
23 -
24 -
25 -
26 -
27 -
28 -
29 -
30 -

All contents of this site are © 2024 Passmedicine Limited

Back to top

A 52-year-old woman presents to the respiratory clinic with breathlessness. She was referred from her GP who was concerned about breathlessness and a chest X-ray demonstrating left pleural effusion. She had recently undergone a left-sided wide local excision with axillary clearance for ductal carcinoma in sit.

She has unilaterally reduced breath sounds with dullness on percussion and deviation of the trachea away from that side of her chest. A plural aspirate is obtained and is milky white in colour. The two possibilities considered are chylothorax from pseudochylothorax.

What investigation would aid in distinguishing chylothorax from pseudochylothorax?

pH	5%
Albumin	4%
Microscopy	2%
Triglycerides	85%
Amylase	5%

The correct answer is triglycerides. Chylothorax is the accumulation of lymph in the pleural space. This can occur following damage to the thoracic duct in surgery or in malignant melanoma. It is most likely that the recent surgery is relevant to this. A chylothorax is high in triglycerides and chylomicrons whilst a pseudochylothorax would be high in cholesterol. A pseudochylothorax occurs with longstanding fibrotic pleura. pH would be most useful in determining the presence of empyema, amylase in pancreatitis associated effusions, whilst microscopy would help in malignant effusions.

Discuss (4) Improve

Next question

Pleural effusion: investigation and management

The British Thoracic Society (BTS) produced guidelines in 2010 covering the investigation of patients with a pleural effusion.

Imaging

- posterioranterior (PA) chest x-rays should be performed in all patients
- ultrasound is recommended: it increases the likelihood of successful pleural aspiration and is sensitive for detecting pleural fluid septations
- contrast CT is now increasingly performed to investigate the underlying cause, particularly for exudative effusions

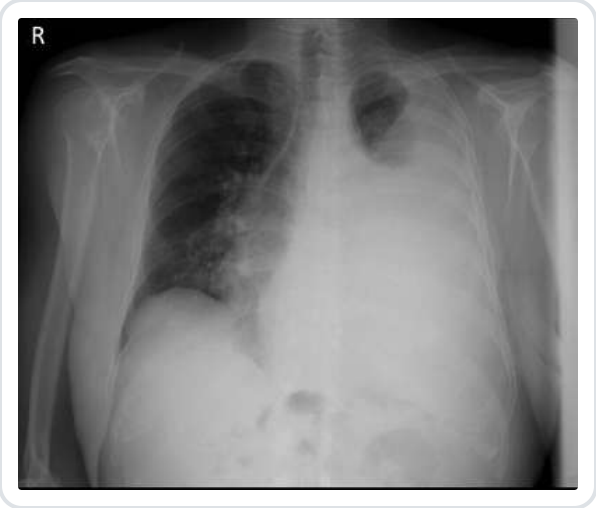

Pleural aspiration

- as above, ultrasound is recommended to reduce the complication rate
- a 21G needle and 50ml syringe should be used
- fluid should be sent for pH, protein, lactate dehydrogenase (LDH), cytology and microbiology

Light's criteria was developed in 1972 to help distinguish between a transudate and an exudate. The BTS recommend using the criteria for borderline cases:

- exudates have a protein level of >30 g/L, transudates have a protein level of <30 g/L
- if the protein level is between 25-35 g/L, Light's criteria should be applied. An exudate is likely if at least one of the following criteria are met:
    - pleural fluid protein divided by serum protein >0.5
    - pleural fluid LDH divided by serum LDH >0.6
    - pleural fluid LDH more than two-thirds the upper limits of normal serum LDH

Other characteristic pleural fluid findings:

- low glucose: rheumatoid arthritis, tuberculosis
- raised amylase: pancreatitis, oesophageal perforation
- heavy blood staining: mesothelioma, pulmonary embolism, tuberculosis

Pleural infection

All patients with a pleural effusion in association with sepsis or a pneumonic illness require diagnostic pleural fluid sampling

- if the fluid is purulent or turbid/cloudy a chest tube should be placed to allow drainage
- if the fluid is clear but the **pH is less than 7.2 in patients with suspected pleural infection a chest tube should be placed**

Management of recurrent pleural effusion

Options for managing patients with recurrent pleural effusions include:

- recurrent aspiration
- pleurodesis
- indwelling pleural catheter
- drug management to alleviate symptoms e.g. opioids to relieve dyspnoea

+ Q 123

Next question >

Textbooks

High-yield textbook

Extended textbook

Links

British Thoracic Society 17 14

2023 Pleural disease guidelines

Royal College of Physicians 13 7

2012 Pleural infection review

Suggest link Report broken link

Media

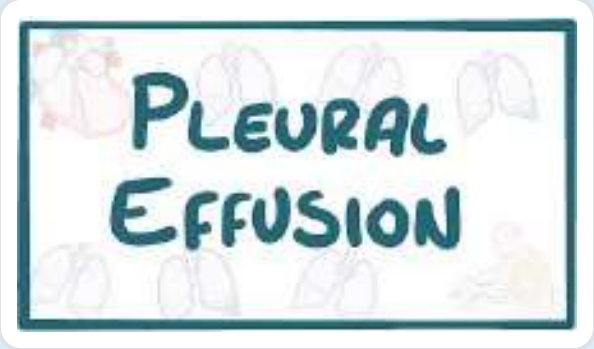

Pleural effusion

Osmosis - YouTube 👍 8 👎 1

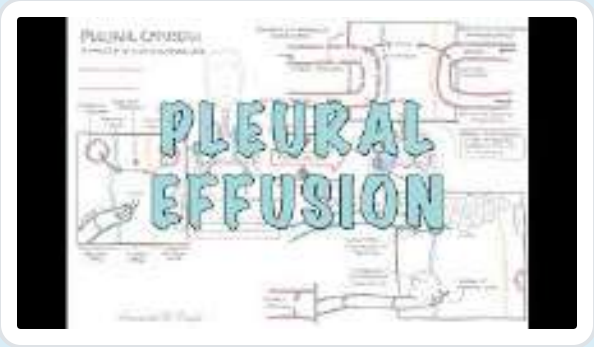

Pleural effusion

Armando Hasudungan - YouTube 👍 6 👎 1

Report broken media

Score: **16%**

1	✗
2	✗
3	✗
4	✗
5	✗
6	✗
7	✗
8	✗
9	✗
10	✗
11	✗
12	✓
13	✗
14	✗

15	✗
16	✗
17	✗
18	✗
19	✗
20	✗
21	✗
22	✗
23	✓
24	✗
25	✗
26	✗
27	✗
28	✗
29	✓
30	✗
31	✓
32	✗
33	✗
34	✗
35	✗
36	✓
37	✓
38	✗
39	✗
40	✗
41	✓
42	✗
43	✗
44	✗
45	✗
46	✗
47	✗
48	✗
49	✓
50	✗

All contents of this site are © 2024 Passmedicine Limited

You are asked to review a 78 year-old male on the respiratory ward during a night shift. He is currently an inpatient being treated for an infective exacerbation of pulmonary fibrosis. You review his chest X-Ray which shows extensive left sided consolidation. His co-morbidities include end-stage renal failure (haemodialysis dependent) secondary to type 1 diabetes mellitus. He escalation plan has been discussed previously and he did not want escalation to ICU or CPR in the event of a cardiac arrest.

He has been treated with high flow oxygen and intravenous antibiotics for the past few days but nursing staff inform you he has been deteriorating in the last 24 hours. On examination he is very dyspnoeic and distressed with saturations of 72% on 80% high flow humidified oxygen.

What is the correct course of action?

- Increase the inspired oxygen concentration
- 2.5mg midazolam subcutaneously
- 2.5mg morphine subcutaneously
- 5mg morphine orally
- 100mcg alfentanil subcutaneously

Submit answer

Reference ranges

Score: **0%**

1 -
2 -

3 -
4 -
5 -
6 -
7 -
8 -
9 -
10 -
11 -
12 -
13 -
14 -
15 -
16 -
17 -
18 -
19 -
20 -
21 -
22 -
23 -
24 -
25 -
26 -
27 -
28 -
29 -
30 -
31 -

All contents of this site are © 2024 Passmedicine Limited
Back to top

You are asked to review a 78 year-old male on the respiratory ward during a night shift. He is currently an inpatient being treated for an infective exacerbation of pulmonary fibrosis. You review his chest X-Ray which shows extensive left sided consolidation. His co-morbidities include end-stage renal failure (haemodialysis dependent) secondary to type 1 diabetes mellitus. He escalation plan has been discussed previously and he did not want escalation to ICU or CPR in the event of a cardiac arrest.

He has been treated with high flow oxygen and intravenous antibiotics for the past few days but nursing staff inform you he has been deteriorating in the last 24 hours. On examination he is very dyspnoeic and distressed with saturations of 72% on 80% high flow humidified oxygen.

What is the correct course of action?

- Increase the inspired oxygen concentration — 8%
- 2.5mg midazolam subcutaneously — 28%
- 2.5mg morphine subcutaneously — 34%
- 5mg morphine orally — 6%
- 100mcg alfentanil subcutaneously — 24%

This gentleman is approaching the end of his life. He is on maximal oxygen therapy and has expressed a wish not for escalation beyond ward based care. His renal failure means that he is likely to accumulate morphine and the most appropriate option for palliation of his breathlessness is alfentanil - a short acting opiate.

Discuss (8) Improve

Next question

Idiopathic pulmonary fibrosis

Idiopathic pulmonary fibrosis (IPF, previously termed cryptogenic fibrosing alveolitis) is a chronic lung condition characterised by progressive fibrosis of the interstitium of the lungs. Whilst there are many causes of lung fibrosis (e.g. medications, connective tissue disease, asbestos) the term IPF is reserved when no underlying cause exists.

IPF is typically seen in patients aged 50-70 years and is twice as common in men.

Features

- progressive exertional dyspnoea
- bibasal fine end-inspiratory crepitations on auscultation
- dry cough
- clubbing

Diagnosis

- spirometry: classically a restrictive picture (FEV1 normal/decreased, FVC decreased, FEV1/FVC increased)
- impaired gas exchange: reduced transfer factor (TLCO)
- imaging: bilateral interstitial shadowing (typically small, irregular, peripheral opacities - 'ground-glass' - later progressing to 'honeycombing') may be seen on a chest x-ray but high-resolution CT scanning is the investigation of choice and required to make a diagnosis of IPF
- ANA positive in 30%, rheumatoid factor positive in 10% but this does not necessarily mean that the fibrosis is secondary to a connective tissue disease. Titres are usually low

Management

- pulmonary rehabilitation
- very few medications have been shown to give any benefit in IPF. There is some evidence that pirfenidone (an antifibrotic agent) may be useful in selected patients (see NICE guidelines)
- many patients will require supplementary oxygen and eventually a lung transplant

Prognosis

- poor, average life expectancy is around 3-4 years

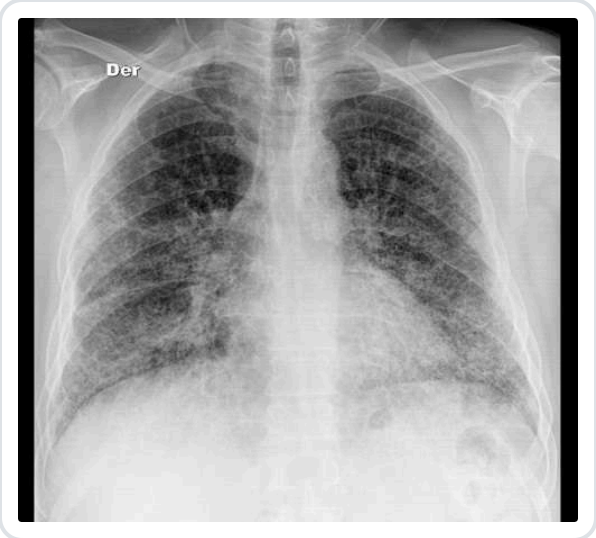

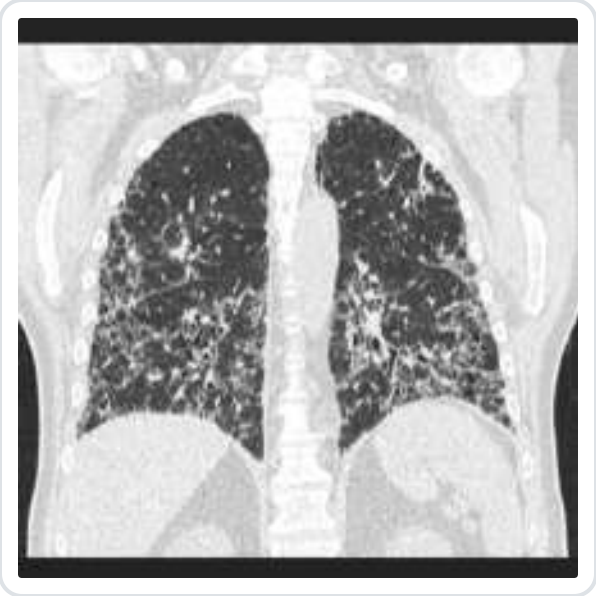

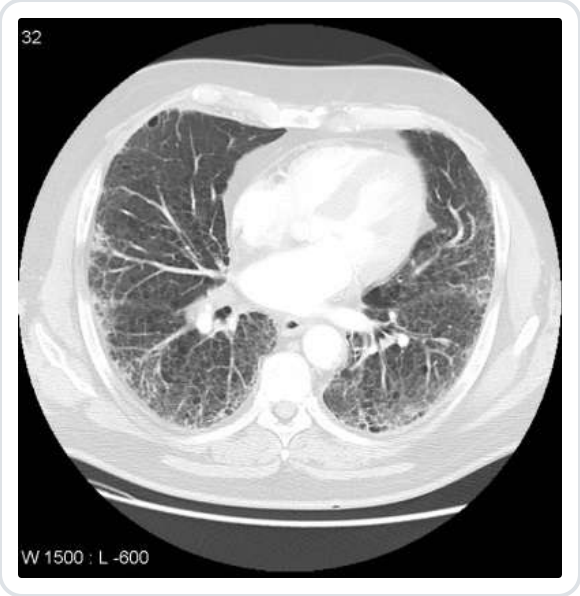

AI + Q 123

Next question

Textbooks

High-yield textbook

Extended textbook

Links

Royal College of Physicians 13 10

Update in diagnosis and management of interstitial lung disease

NICE 11 6

2013 Idiopathic pulmonary fibrosis guidelines

Suggest link

Report broken link

Media

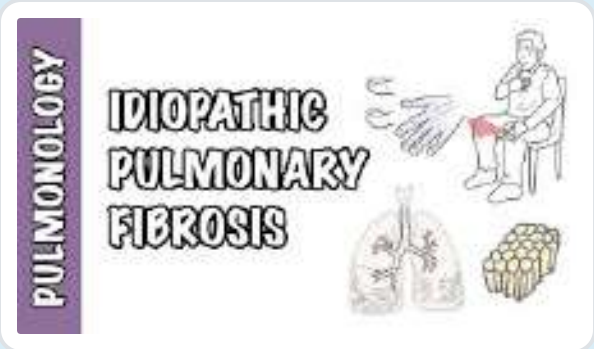

Idiopathic pulmonary fibrosis

Armando Hasudungan - YouTube 6 0

Interstitial Lung Disease (ILD) - Classification, pathophysiology, signs and symptoms

Armando Hasudungan - YouTube 👍 5 👎 0

Idiopathic pulmonary fibrosis

Osmosis - YouTube 👍 4 👎 0

Report broken media

Score: **16%**

1 ✗
2 ✗
3 ✗
4 ✗
5 ✗
6 ✗
7 ✗
8 ✗
9 ✗
10 ✗
11 ✗
12 ✓
13 ✗
14 ✗
15 ✗
16 ✗
17 ✗
18 ✗
19 ✗
20 ✗
21 ✗

22	✗
23	✓
24	✗
25	✗
26	✗
27	✗
28	✗
29	✓
30	✗
31	✓
32	✗
33	✗
34	✗
35	✗
36	✓
37	✓
38	✗
39	✗
40	✗
41	✓
42	✗
43	✗
44	✗
45	✗
46	✗
47	✗
48	✗
49	✓
50	✗

All contents of this site are © 2024 Passmedicine Limited

A 56-year-old lady is brought into the emergency department with a Glasgow Coma Scale of 5. She was found by a friend this morning unconscious and purple with no response. She had been unwell the previous days with an exacerbation of her COPD in which she was developing severe pleuritic chest pain. She had recurrent exacerbations of her COPD and had been hospitalised three times this year with one admission to ITU for intubation and ventilation.

In addition, she had hypertension, hypothyroidism and chronic regional pain syndrome. Her medications include fostair, ventolin, gabapentin, codeine, paracetamol, amlodipine, ramipril, levothyroxine and morphine sulfate. She had taken extra doses of oramorph to control her pleuritic pain. She has started a rescue pack of amoxicillin and prednisolone one day prior

On examination, she does not open her eyes which have 2mm pupils bilaterally that are reactive. She groans to pain but there is no motor response. Her chest has some wheeze across and her respiratory rate is 9 breaths per minute. She is saturating at 88% on 4 litres oxygen via nasal cannulae and there is no accessory muscle use. She has mild pitting oedema and is centrally cyanosed. She has a capillary refill of two seconds and there are no murmurs.

Hb	160 g/l	Na^+	138 mmol/l
Platelets	310 * 10^9/l	K^+	5.1 mmol/l
WBC	9.0 * 10^9/l	Urea	7.8 mmol/l
Neuts	7.8 * 10^9/l	Creatinine	110 µmol/l
Lymphs	1.0 * 10^9/l	CRP	30 mg/l

ABG (on arrival) pH	7.25
pO2	7.91 kPa
pCO2	7.6 kPa
HCO3	31mmol/l

Chest x-ray	poor inspiration, no overt consolidation
ECG	sinus rhythm

What is your first step in management?

- Salbutamol nebuliser
- Intubation and ventilation
- Intravenous antibiotics
- Naloxone
- Non-invasive ventilation

Submit answer

Reference ranges

Score: **0%**

1 -
2 -
3 -
4 -
5 -
6 -
7 -
8 -
9 -
10 -
11 -
12 -
13 -
14 -
15 -
16 -
17 -
18 -
19 -
20 -

21 -
22 -
23 -
24 -
25 -
26 -
27 -
28 -
29 -
30 -
31 -
32 -

All contents of this site are © 2024 Passmedicine Limited

Back to top

A 56-year-old lady is brought into the emergency department with a Glasgow Coma Scale of 5. She was found by a friend this morning unconscious and purple with no response. She had been unwell the previous days with an exacerbation of her COPD in which she was developing severe pleuritic chest pain. She had recurrent exacerbations of her COPD and had been hospitalised three times this year with one admission to ITU for intubation and ventilation.

In addition, she had hypertension, hypothyroidism and chronic regional pain syndrome. Her medications include fostair, ventolin, gabapentin, codeine, paracetamol, amlodipine, ramipril, levothyroxine and morphine sulfate. She had taken extra doses of oramorph to control her pleuritic pain. She has started a rescue pack of amoxicillin and prednisolone one day prior

On examination, she does not open her eyes which have 2mm pupils bilaterally that are reactive. She groans to pain but there is no motor response. Her chest has some wheeze across and her respiratory rate is 9 breaths per minute. She is saturating at 88% on 4 litres oxygen via nasal cannulae and there is no accessory muscle use. She has mild pitting oedema and is centrally cyanosed. She has a capillary refill of two seconds and there are no murmurs.

Hb	160 g/l	Na^+	138 mmol/l
Platelets	310 * 10^9/l	K^+	5.1 mmol/l
WBC	9.0 * 10^9/l	Urea	7.8 mmol/l
Neuts	7.8 * 10^9/l	Creatinine	110 µmol/l
Lymphs	1.0 * 10^9/l	CRP	30 mg/l

ABG (on arrival) pH	7.25
pO2	7.91 kPa
pCO2	7.6 kPa
HCO3	31mmol/l

Chest x-ray	poor inspiration, no overt consolidation
ECG	sinus rhythm

What is your first step in management?

Salbutamol nebuliser	1%
Intubation and ventilation	41%
Intravenous antibiotics	1%
Naloxone	40%
Non-invasive ventilation	17%

Opioids can precipitate respiratory failure in patients with chronic respiratory disease

Important for me Less important

This lady has entered type 2 respiratory failure. A lot of the options are suitable here but the key is identifying what the quickest solution may be. Ventilation is key but there are some other actions that should be tried first. Intravenous antibiotics are useful but she is haemodynamically stable and not overtly septic. Salbutamol nebulisers will help her air entry. However, there are several clues in the question. She is taking lots of opioids and other sedatives and has increased her uptake of oramorph because of pleuritic pain. She has pin point pupils and bradypnoea and a stat dose of naloxone may rapidly recover her respiratory drive and allow her to recover without needing the other options.

Discuss (12) Improve

Next question

Respiratory acidosis

Respiratory acidosis may be caused by a number of conditions:

- COPD
- decompensation in other respiratory conditions e.g. life-threatening asthma / pulmonary oedema
- neuromuscular disease
- obesity hypoventilation syndrome
- sedative drugs: benzodiazepines, opiate overdose

123

Next question

Textbooks

High-yield textbook

Extended textbook

Media

ABG Interpretation Made Easy

Respiratory Therapy Zone - YouTube 5 0

Acid-base disturbances

Osmosis - YouTube 3 0

Report broken media

Score: **16%**

1 ✗

2	✗
3	✗
4	✗
5	✗
6	✗
7	✗
8	✗
9	✗
10	✗
11	✗
12	✓
13	✗
14	✗
15	✗
16	✗
17	✗
18	✗
19	✗
20	✗
21	✗
22	✗
23	✓
24	✗
25	✗
26	✗
27	✗
28	✗
29	✓
30	✗
31	✓
32	✗
33	✗
34	✗
35	✗
36	✓
37	✓

38	✗
39	✗
40	✗
41	✓
42	✗
43	✗
44	✗
45	✗
46	✗
47	✗
48	✗
49	✓
50	✗

All contents of this site are © 2024 Passmedicine Limited

Back to top

A 22-year-old man presents to rheumatology clinic with chronic lower back pain and early morning stiffness. He has past medical history of asthma and is on regular steroid inhalers and suffers from multiple exacerbations annually. He is due to see a respiratory physician to help better manage his symptoms. Clinical examination shows demonstrate Schober's sign. Pelvic X-rays demonstrate sacroiliitis. A diagnosis of ankylosing spondylitis is made. The patient is concerned about using NSAIDs to control his symptoms; what factor may suggest that NSAID-sensitive asthma?

- Previous reaction to beta-blockers
- High frequency of exacerbations
- Presence of nasal polyps
- Adult-onset asthma
- Previous ITU admission

Submit answer

Reference ranges

Score: **0%**

1 -
2 -
3 -
4 -
5 -
6 -

7	-
8	-
9	-
10	-
11	-
12	-
13	-
14	-
15	-
16	-
17	-
18	-
19	-
20	-
21	-
22	-
23	-
24	-
25	-
26	-
27	-
28	-
29	-
30	-
31	-
32	-
33	-

All contents of this site are © 2024 Passmedicine Limited

Back to top

A 22-year-old man presents to rheumatology clinic with chronic lower back pain and early morning stiffness. He has past medical history of asthma and is on regular steroid inhalers and suffers from multiple exacerbations annually. He is due to see a respiratory physician to help better manage his symptoms. Clinical examination shows demonstrate Schober's sign. Pelvic X-rays demonstrate sacroiliitis. A diagnosis of ankylosing spondylitis is made. The patient is concerned about using NSAIDs to control his symptoms; what factor may suggest that NSAID-sensitive asthma?

- Previous reaction to beta-blockers 14%
- High frequency of exacerbations 12%
- Presence of nasal polyps 63%
- Adult-onset asthma 10%
- Previous ITU admission 2%

The correct answer is nasal polyps. Asthmatics are typically taught to be aware that NSAID's can worsen asthma but not all patients are sensitive. The presence of nasal polyps is associated with a higher chance of reaction to NSAID's, whilst having had NSAID's and suffered no reaction within the last 12 months reduces the chance of further reactions. The other options do not predict a reaction ITU admissions and high frequency of admissions can suggest poorly managed or brittle asthma.

Source:
'Drug allergy: diagnosis and management' Clinical Guideline [CG183]. The National Institute for Health and Care Excellence, Sep. 2014.

Discuss (4) Improve

Next question

Asthma: management in adults

In 2024 NICE, the British Thoracic Society and SIGN produced joint guidelines on the management of asthma following many years of conflicting guidelines. The new guidelines represent a major step change in the management of asthma is both diagnosed and treated.

For many years patients with asthma were started on a short-acting beta-2 agonist (SABA) inhaler before 'stepping up' to a regular inhaled corticosteroid with a SABA as required. The new guidelines now advocate the use of combined inhalers (ICS + long-acting beta-2 agonist) as reliever therapy or regularly, depending on the severity of asthma. Given the prevalence of asthma, it is likely that doctors will have to deal with patients on 'conventional' asthma treatments for many years to come. The joint guidelines therefore include guidance on how to manage these patients if their current treatment is controlling their symptoms sufficiently.

Management of adult patients aged children aged ≥ 12 years with newly diagnosed asthma

Step 1 NICE

- a low-dose inhaled corticosteroid (ICS)/formoterol combination inhaler to be taken as needed for symptom relief
    - this is termed anti-inflammatory reliever (AIR) therapy
- if the patient presents highly symptomatic (for example, regular nocturnal waking) or with a severe exacerbation:
    - start treatment with low-dose MART (maintenance and reliever therapy, see below)
    - treat the acute symptoms as appropriate (e.g. a course of oral corticosteroids may be indicated)

Step 2 NICE

- a low-dose MART
    - MART describes using an inhaled corticosteroid (ICS)/formoterol combination inhaler for daily maintenance therapy and the relief of symptoms as needed, i.e. regularly and as required

Step 3

- a moderate-dose MART

Step 4

- check the fractional exhaled nitric oxide (FeNO) level if available, and the blood eosinophil count NICE
    - if either of these is raised, refer to a specialist in asthma care

- if neither FeNO nor eosinophil count is raised, consider a trial of either a leukotriene receptor antagonist (LTRA) or a long-acting muscarinic receptor antagonist (LAMA) used in addition to moderate-dose MART
- if control has not improved, stop the LTRA or LAMA and start a trial of the alternative medicine (LTRA or LAMA)

Step 5

- refer people to a specialist in asthma care when asthma is not controlled despite treatment with moderate-dose MART, and trials of an LTRA and a LAMA

Transferring people aged 12 and over from other treatment pathways

There will be many people whose asthma was managed according to the previous guidelines that present with uncontrolled asthmatic symptoms. The guidelines give advice on how these people should be switched: NICE

Existing asthma treatment	New asthma treatment
SABA as required only	Low-dose ICS/formoterol combination inhaler used as needed (as-needed AIR therapy)
SABA as required + regular low-dose ICS SABA as required + regular low-dose ICS/LABA SABA as required + regular low-dose ICS + LTRA SABA as required + regular low-dose ICS/LABA + LTRA	Regular low-dose regular ICS/formoterol combination inhaler (MART therapy)
SABA as required + regular moderate-dose ICS SABA as required + regular moderate-dose ICS/LABA SABA as required + regular moderate-dose ICS + LTRA or LAMA	Regular moderate-dose MART therapy

Existing asthma treatment	New asthma treatment
SABA as required + regular moderate-dose ICS/LABA + LTRA or LAMA	
Treatment regime containing a high-dose ICS	Refer to a respiratory specialist

123

Next question

Textbooks

High-yield textbook

Extended textbook

Links

NICE 1 0

2024 Asthma: diagnosis, monitoring and chronic asthma management (BTS, NICE, SIGN)

Suggest link Report broken link

Media

Asthma

MedFlix - YouTube 2 0

Inhaler and Nebuliser Explanation

Oxford Medical Education - YouTube 5 1

Report broken media

Score: **16%**

1	✗
2	✗
3	✗
4	✗
5	✗
6	✗
7	✗
8	✗
9	✗
10	✗
11	✗
12	✓
13	✗
14	✗
15	✗
16	✗
17	✗
18	✗
19	✗
20	✗
21	✗
22	✗

23	✓
24	✗
25	✗
26	✗
27	✗
28	✗
29	✓
30	✗
31	✓
32	✗
33	✗
34	✗
35	✗
36	✓
37	✓
38	✗
39	✗
40	✗
41	✓
42	✗
43	✗
44	✗
45	✗
46	✗
47	✗
48	✗
49	✓
50	✗

All contents of this site are © 2024 Passmedicine Limited

Back to top

A 48-year-old male presents to the respiratory clinic with his partner. They are concerned as he has lost 5 kgs in weight over the last three months. He also reports a productive cough which has been troubling him for a similar time period. He reports that he is currently producing approximately half a cup of phlegm each day. He denies fevers or night sweats and systems review is unremarkable.

You send the patient for a chest X-ray which is reported as showing multiple cavitating lesions. Sputum microscopy, sensitivities and culture (MC&S) are all negative and a HIV test is negative. You refer the patient for a bronchoscopy and bronco-alveolar lavage (BAL) to aid your diagnosis. Several weeks later you receive a call from the microbiology registrar on call to inform you that the patients sputum has cultured a non-tuberculous mycobacterium (Mycobacterium intracellulare).

You call the patient back into clinic and find that his symptoms have persisted since his last visit. What is the most appropriate management plan for this individual?

- Rifampicin, isoniazid, ethambutol, pyrazinamide
- Repeat sputum cultures
- Clarithromycin monotherapy
- Rifampicin, clarithromycin and ethambutol
- Rifampicin and isoniazid

Submit answer

Reference ranges

2	-
3	-
4	-
5	-
6	-
7	-
8	-
9	-
10	-
11	-
12	-
13	-
14	-
15	-
16	-
17	-
18	-
19	-
20	-
21	-
22	-
23	-
24	-
25	-
26	-
27	-
28	-
29	-
30	-
31	-
32	-
33	-
34	-

All contents of this site are © 2024 Passmedicine Limited
Back to top

A 48-year-old male presents to the respiratory clinic with his partner. They are concerned as he has lost 5 kgs in weight over the last three months. He also reports a productive cough which has been troubling him for a similar time period. He reports that he is currently producing approximately half a cup of phlegm each day. He denies fevers or night sweats and systems review is unremarkable.

You send the patient for a chest X-ray which is reported as showing multiple cavitating lesions. Sputum microscopy, sensitivities and culture (MC&S) are all negative and a HIV test is negative. You refer the patient for a bronchoscopy and bronco-alveolar lavage (BAL) to aid your diagnosis. Several weeks later you receive a call from the microbiology registrar on call to inform you that the patients sputum has cultured a non-tuberculous mycobacterium (Mycobacterium intracellulare).

You call the patient back into clinic and find that his symptoms have persisted since his last visit. What is the most appropriate management plan for this individual?

Rifampicin, isoniazid, ethambutol, pyrazinamide	20%
Repeat sputum cultures	3%
Clarithromycin monotherapy	11%
Rifampicin, clarithromycin and ethambutol	53%
Rifampicin and isoniazid	14%

This question tests your understanding of the diagnostic criteria for non-tuberculous mycobacteria (NTM) and appropriate treatment of common causative species. Diagnosis can be made by following the joint American Thoracic Society / Infectious Diseases Society of America (ATS/IDSA) guidelines which were published in 2007. Diagnosis requires a range of clinical, radiological and microbiological characteristics to be fulfilled as described below:

Clinical: Pulmonary symptoms (e.g. cough, sputum, or constitutional) and exclusion of alternative diagnosis
Radiological: Chest X-ray or HRCT demonstrating cavities, bronchiectasis and or nodules
Microbiological: Two or more positive sputum samples for an NTM species taken on separate days (or one of more positive sample from bronco-alveolar lavage or tissue biopsy)

Once a diagnosis of NTM is reached, it is important to know the basic treatment for common pulmonary NTM infections. It is important to have a basic understanding of two commonly identified groups: Mycobacterium avium complex (MAC) and Mycobacterium kansasii.

- MAC: Rifampicin, clarithromycin and ethambutol. Treatment should continue until the patients sputum has remained negative for MAC for 12 months
- M.kansasii: Rifampicin, isoniazid and ethambutol. Treatment should continue until the patient has been sputum culture negative for 12 months.

It is important that patients with NTM infection should never receive clarithromycin monotherapy due to concerns over development of resistance.

ATS/IDSA guidelines: https://www.thoracic.org/statements/resources/mtpi/nontuberculous-mycobacterial-diseases.pdf

Discuss (9) Improve

Next question

Nontuberculous mycobacteria

Nontuberculous mycobacteria (NTM) are mycobacterial species other than those belonging to the *Mycobacterium tuberculosis* complex. NTM are typically free-living organisms that are common in the environment.

Most non-tuberculous mycobacteria are caused by *M. avium* complex (MAC) organisms.

Presentations include:

- pulmonary disease
    - cavitating lesions
    - nodular / bronchiectatic disease
- disseminated disease

123

Next question

Textbooks

High-yield textbook

Extended textbook

Links

British Thoracic Society 0 0

2017 Management of non-tuberculous mycobacterial pulmonary disease (NTM-PD)

Suggest link Report broken link

Score: **16%**

1 ✗
2 ✗
3 ✗
4 ✗
5 ✗
6 ✗
7 ✗
8 ✗
9 ✗
10 ✗
11 ✗
12 ✓
13 ✗
14 ✗

15	✗
16	✗
17	✗
18	✗
19	✗
20	✗
21	✗
22	✗
23	✓
24	✗
25	✗
26	✗
27	✗
28	✗
29	✓
30	✗
31	✓
32	✗
33	✗
34	✗
35	✗
36	✓
37	✓
38	✗
39	✗
40	✗
41	✓
42	✗
43	✗
44	✗
45	✗
46	✗
47	✗
48	✗
49	✓
50	✗

All contents of this site are © 2024 Passmedicine Limited

PassMedicine

You review the chest x-ray of a 35-year-old man who started treatment for a chest infection two weeks ago. He completed a one week course of antibiotics but still feels short-of-breath on exertion. He has a 15 pack-year history of smoking.

On examination his respiratory rate is 16/min, saturations 98% on room air and auscultation of his chest is unremarkable.

His chest x-ray is shown below:

© Image used on license from Radiopaedia

What does the chest x-ray show?

- Right lower lobe collapse
- Lung tumour

- ○ Pleural effusion ×
- ○ Elevated right hemidiaphragm ×
- ○ Persistent consolidation ×

Submit answer

Reference ranges

Score: **0%**

1	-
2	-
3	-
4	-
5	-
6	-
7	-
8	-
9	-
10	-
11	-
12	-
13	-
14	-
15	-
16	-
17	-
18	-
19	-
20	-
21	-
22	-
23	-
24	-

25 -
26 -
27 -
28 -
29 -
30 -
31 -
32 -
33 -
34 -
35 -

All contents of this site are © 2024 Passmedicine Limited

You review the chest x-ray of a 35-year-old man who started treatment for a chest infection two weeks ago. He completed a one week course of antibiotics but still feels short-of-breath on exertion. He has a 15 pack-year history of smoking.

On examination his respiratory rate is 16/min, saturations 98% on room air and auscultation of his chest is unremarkable.

His chest x-ray is shown below:

© Image used on license from Radiopaedia

What does the chest x-ray show?

- Right lower lobe collapse 21%
- Lung tumour 1%

Pleural effusion	52%
Elevated right hemidiaphragm	22%
Persistent consolidation	3%

The chest x-ray shows a right basal opacity obscuring the right costodiaphragmatic recess with a meniscus, findings consistent with a pleural effusion. Lungs and pleural spaces are otherwise unremarkable. Cardiomediastinal contour within normal limits.

Discuss (2) Improve

Next question

Pleural effusion: investigation and management

The British Thoracic Society (BTS) produced guidelines in 2010 covering the investigation of patients with a pleural effusion.

Imaging

- posterioranterior (PA) chest x-rays should be performed in all patients
- ultrasound is recommended: it increases the likelihood of successful pleural aspiration and is sensitive for detecting pleural fluid septations
- contrast CT is now increasingly performed to investigate the underlying cause, particularly for exudative effusions

Pleural aspiration

- as above, ultrasound is recommended to reduce the complication rate
- a 21G needle and 50ml syringe should be used
- fluid should be sent for pH, protein, lactate dehydrogenase (LDH), cytology and microbiology

Light's criteria was developed in 1972 to help distinguish between a transudate and an exudate.

The BTS recommend using the criteria for borderline cases:

- exudates have a protein level of >30 g/L, transudates have a protein level of <30 g/L
- if the protein level is between 25-35 g/L, Light's criteria should be applied. An exudate is likely if at least one of the following criteria are met:
    - pleural fluid protein divided by serum protein >0.5
    - pleural fluid LDH divided by serum LDH >0.6
    - pleural fluid LDH more than two-thirds the upper limits of normal serum LDH

Other characteristic pleural fluid findings:

- low glucose: rheumatoid arthritis, tuberculosis
- raised amylase: pancreatitis, oesophageal perforation
- heavy blood staining: mesothelioma, pulmonary embolism, tuberculosis

Pleural infection

All patients with a pleural effusion in association with sepsis or a pneumonic illness require diagnostic pleural fluid sampling

- if the fluid is purulent or turbid/cloudy a chest tube should be placed to allow drainage
- if the fluid is clear but the **pH is less than 7.2 in patients with suspected pleural infection a chest tube should be placed**

Management of recurrent pleural effusion

Options for managing patients with recurrent pleural effusions include:

- recurrent aspiration
- pleurodesis
- indwelling pleural catheter
- drug management to alleviate symptoms e.g. opioids to relieve dyspnoea

+ Q 123

Next question >

Textbooks

High-yield textbook

Extended textbook

Links

British Thoracic Society 17 14

2023 Pleural disease guidelines

Royal College of Physicians 13 7

2012 Pleural infection review

Suggest link

Report broken link

Media

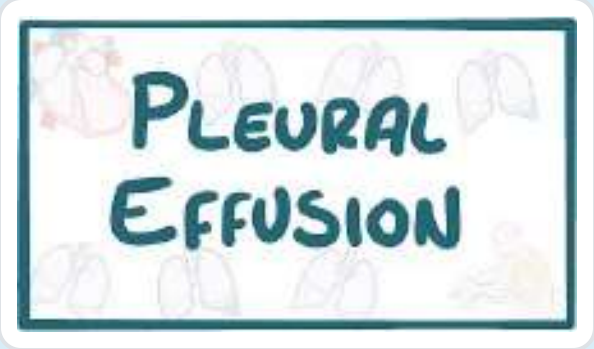

Pleural effusion

Osmosis - YouTube 8 1

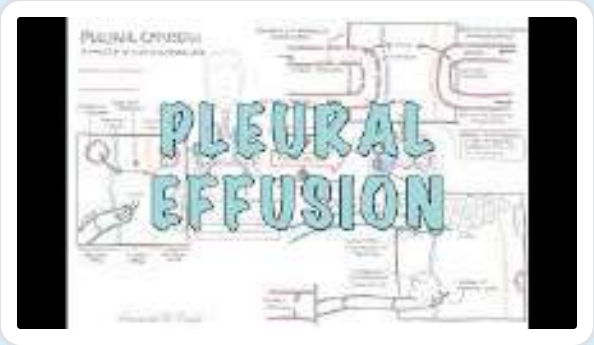

Pleural effusion

Armando Hasudungan - YouTube 6 1

Report broken media

Score: **16%**

1	✗
2	✗
3	✗
4	✗
5	✗
6	✗
7	✗
8	✗
9	✗
10	✗
11	✗
12	✓
13	✗
14	✗
15	✗
16	✗
17	✗
18	✗
19	✗
20	✗
21	✗
22	✗
23	✓
24	✗
25	✗
26	✗
27	✗
28	✗
29	✓
30	✗
31	✓
32	✗
33	✗
34	✗

35 ✗
36 ✓
37 ✓
38 ✗
39 ✗
40 ✗
41 ✓
42 ✗
43 ✗
44 ✗
45 ✗
46 ✗
47 ✗
48 ✗
49 ✓
50 ✗

All contents of this site are © 2024 Passmedicine Limited
Back to top

A 72-year-old gentleman presents for review in the medical clinic. He has had COPD for five years and is on regular bronchodilator treatment with a combination budesonide and formoterol fumarate inhaler and salbutamol inhaler as needed. He has found that he suffers from regular coughing bouts and finds his exercise tolerance has reduced.

His past medical history includes macular degeneration, osteoarthritis, mild memory impairment and diverticulosis. He has noticed that the distance he can walk has reduced from being able to go to the local shop, roughly one mile away, to having to stop half-way to catch his breath.

What investigation would be most useful to help determine the severity of his COPD?

- FEV1/FVC
- Chest X-ray
- High resolution CT scan of the chest
- Partial pressure of oxygen on arterial blood gas
- FEV1% of predicted

Submit answer

Reference ranges

6 -
7 -
8 -
9 -
10 -
11 -
12 -
13 -
14 -
15 -
16 -
17 -
18 -
19 -
20 -
21 -
22 -
23 -
24 -
25 -
26 -
27 -
28 -
29 -
30 -
31 -
32 -
33 -
34 -
35 -
36 -

All contents of this site are © 2024 Passmedicine Limited
Back to top

A 72-year-old gentleman presents for review in the medical clinic. He has had COPD for five years and is on regular bronchodilator treatment with a combination budesonide and formoterol fumarate inhaler and salbutamol inhaler as needed. He has found that he suffers from regular coughing bouts and finds his exercise tolerance has reduced.

His past medical history includes macular degeneration, osteoarthritis, mild memory impairment and diverticulosis. He has noticed that the distance he can walk has reduced from being able to go to the local shop, roughly one mile away, to having to stop half-way to catch his breath.

What investigation would be most useful to help determine the severity of his COPD?

FEV1/FVC	20%
Chest X-ray	0%
High resolution CT scan of the chest	2%
Partial pressure of oxygen on arterial blood gas	4%
FEV1% of predicted	74%

The correct answer is FEV1% of predicted. All of the mentioned investigations, in addition to routine blood tests, can be useful in assessing COPD, but the primary investigation standard for COPD is FEV1% of predicted. This compares the patient's ability to exhale over one second with what someone of the same sex, height, weight and ethnicity. It is a marker of the extent of airway obstruction and therefore a marker of COPD severity.

FEV1/FVC is useful in diagnosis but not the severity of COPD.

Imaging can show radiological changes, but these are not as standardised as spirometry changes.

Hypoxia on arterial blood gases is more useful in establishing the need for home oxygen than COPD severity.

Discuss Improve

COPD: investigation and diagnosis

NICE recommend considering a diagnosis of COPD in patients over 35 years of age who are smokers or ex-smokers and have symptoms such as exertional breathlessness, chronic cough or regular sputum production.

The following investigations are recommended in patients with suspected COPD:

- post-bronchodilator spirometry to demonstrate airflow obstruction: FEV1/FVC ratio less than 70%
- chest x-ray: hyperinflation, bullae, flat hemidiaphragm. Also important to exclude lung cancer
- full blood count: exclude secondary polycythaemia
- body mass index (BMI) calculation

The severity of COPD is categorised using the FEV1*:

Post-bronchodilator FEV1/FVC	**FEV1 (of predicted)**	**Severity**
< 0.7	> 80%	Stage 1 - Mild - symptoms should be present to diagnose COPD in these patients
< 0.7	50-79%	Stage 2 - Moderate
< 0.7	30-49%	Stage 3 - Severe
< 0.7	< 30%	Stage 4 - Very severe

Measuring peak expiratory flow is of limited value in COPD, as it may underestimate the degree of airflow obstruction.

*note that the grading system has changed following the 2010 NICE guidelines. If the FEV1 is greater than 80% predicted but the post-bronchodilator FEV1/FVC is < 0.7 then this is classified as Stage 1 - mild

Textbooks

High-yield textbook

Extended textbook

Links

NICE 9 8

2018 COPD guidelines

Suggest link

Report broken link

Media

All about COPD (for Medical Students)

MedFlix - YouTube 1 0

Peak Flow and Spirometry - Lung Function Tests

Oxford Medical Education - YouTube 1 2

Report broken media

Score: **16%**

1	✗
2	✗
3	✗
4	✗
5	✗
6	✗
7	✗
8	✗
9	✗
10	✗
11	✗
12	✓
13	✗
14	✗
15	✗
16	✗
17	✗
18	✗
19	✗
20	✗
21	✗
22	✗
23	✓
24	✗
25	✗
26	✗
27	✗
28	✗
29	✓
30	✗
31	✓
32	✗
33	✗

34	✗
35	✗
36	✓
37	✓
38	✗
39	✗
40	✗
41	✓
42	✗
43	✗
44	✗
45	✗
46	✗
47	✗
48	✗
49	✓
50	✗

All contents of this site are © 2024 Passmedicine Limited

Back to top

A 68-year-old female attends the acute medical unit with dyspnoea. She states that the dyspnoea is present at rest and exacerbated by exertion. She has a past medical history of hypothyroidism, recurrent urinary tract infections, and anxiety. Her drug history includes nitrofurantoin, levothyroxine, paracetamol, bisoprolol and sertraline. On examination you note right basal crepitations and stony dull percussion at the right lung base.

A chest x-ray demonstrates a right sided pleural effusion.

What drug is the most likely cause of the pleural effusion?

- Levothyroxine
- Bisoprolol
- Sertraline
- Paracetamol
- Nitrofurantoin

Submit answer

Reference ranges

Score: **0%**

1 -
2 -
3 -
4 -
5 -
6 -

7 -
8 -
9 -
10 -
11 -
12 -
13 -
14 -
15 -
16 -
17 -
18 -
19 -
20 -
21 -
22 -
23 -
24 -
25 -
26 -
27 -
28 -
29 -
30 -
31 -
32 -
33 -
34 -
35 -
36 -
37 -

All contents of this site are © 2024 Passmedicine Limited
Back to top

A 68-year-old female attends the acute medical unit with dyspnoea. She states that the dyspnoea is present at rest and exacerbated by exertion. She has a past medical history of hypothyroidism, recurrent urinary tract infections, and anxiety. Her drug history includes nitrofurantoin, levothyroxine, paracetamol, bisoprolol and sertraline. On examination you note right basal crepitations and stony dull percussion at the right lung base.

A chest x-ray demonstrates a right sided pleural effusion.

What drug is the most likely cause of the pleural effusion?

- Levothyroxine 7%
- Bisoprolol 3%
- Sertraline 7%
- Paracetamol 1%
- Nitrofurantoin 81%

Several drugs are known to cause pleural effusion including nitrofurantoin, methotrexate, and amiodarone

Important for me Less important

Several drugs are known to cause pleural effusion including nitrofurantoin, methotrexate, and amiodarone. None of the other options are known to cause pleural effusions.

Nitrofurantoin is sometimes used long term for prophylaxis of urinary tract infections. Respiratory complications of nitrofurantoin include acute pulmonary reactions (e.g. consolidation) and chronic reactions (e.g. fibrosis and effusions). Patients should have spirometry every 3-6 months while on nitrofurantoin.

Discuss (6) Improve

Next question

Pleural effusion: causes

Pleural effusions may be classified as being either a transudate or exudate according to the protein concentration.

Transudate (< 30g/L protein)

- heart failure (most common transudate cause)
- hypoalbuminaemia
  - liver disease
  - nephrotic syndrome
  - malabsorption
- hypothyroidism
- Meigs' syndrome

Exudate (> 30g/L protein)

- infection
  - pneumonia (most common exudate cause),
  - tuberculosis
  - subphrenic abscess
- connective tissue disease
  - rheumatoid arthritis
  - systemic lupus erythematosus
- neoplasia
  - lung cancer
  - mesothelioma
  - metastases
- pancreatitis
- pulmonary embolism
- Dressler's syndrome
- yellow nail syndrome

Features

- dyspnoea, non-productive cough or chest pain are possible presenting symptoms
- classic examination findings include dullness to percussion, reduced breath sounds and reduced chest expansion

+ Q 123

Next question >

Textbooks

High-yield textbook

Extended textbook

Media

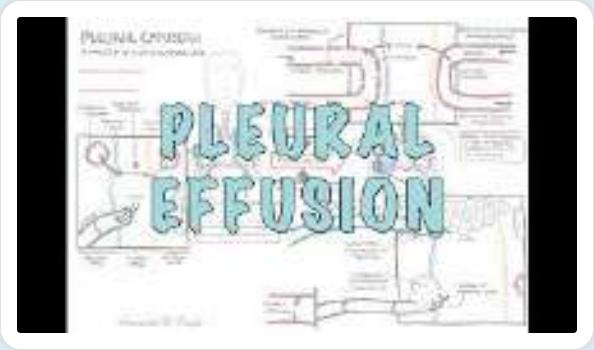

Pleural effusion

Armando Hasudungan - YouTube 1 0

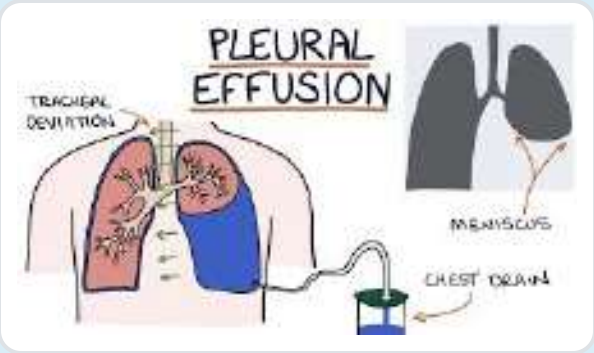

Understanding Pleural Effusions

Zero to Finals - YouTube 1 1

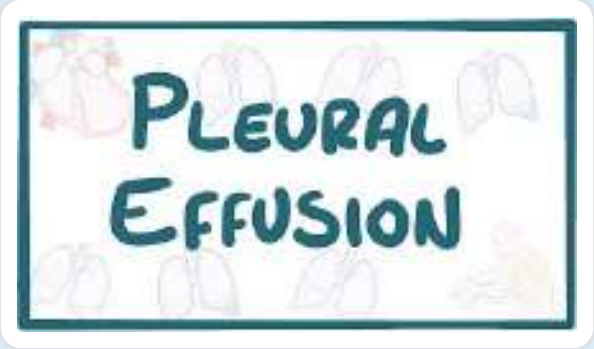

Pleural effusion

Osmosis - YouTube 1 1

Report broken media

Score: **16%**

1	✗
2	✗
3	✗
4	✗
5	✗
6	✗
7	✗
8	✗
9	✗
10	✗
11	✗
12	✓
13	✗
14	✗
15	✗
16	✗
17	✗
18	✗
19	✗
20	✗
21	✗
22	✗
23	✓
24	✗
25	✗
26	✗
27	✗
28	✗
29	✓
30	✗
31	✓
32	✗
33	✗

34	✗
35	✗
36	✓
37	✓
38	✗
39	✗
40	✗
41	✓
42	✗
43	✗
44	✗
45	✗
46	✗
47	✗
48	✗
49	✓
50	✗

All contents of this site are © 2024 Passmedicine Limited

Back to top

A 57-year-old is admitted with confusion, fever and decreased oral intake. HIs past medical history is significant for type 2 diabetes mellitus, hypertension, osteoarthritis and gout. Blood cultures are positive for *E. coli*. Despite antibiotic therapy, he slips into respiratory failure. He is intubated and placed on mechanical ventilation with an FiO_2 of 70%, tidal volume of 370 ml and respiratory rate of 14/min.

His current arterial blood gases are:

pH	7.45
pO_2	7.86 kPa
pCO_2	3.99 kPa
HCO_3	21 mmol/l

Which of the following is the best next step in managing this patient?

- Increase tidal volume
- Increase respiratory rate
- Increase the fraction of inspired oxygen
- Add positive end-expiratory pressure
- Decrease the fraction of inspired oxygen

Submit answer

Reference ranges

Score: **0%**

```
-
-
-
-
-
-
-
-
-
-
-
-
-
-
-
-
-
-
-
-
-
-
-
-
-
-
-
-
-
-
-
-
-
-
-
-
-
-
```

All contents of this site are © 2024 Passmedicine Limited

A 57-year-old is admitted with confusion, fever and decreased oral intake. HIs past medical history is significant for type 2 diabetes mellitus, hypertension, osteoarthritis and gout. Blood cultures are positive for *E. coli*. Despite antibiotic therapy, he slips into respiratory failure. He is intubated and placed on mechanical ventilation with an FiO_2 of 70%, tidal volume of 370 ml and respiratory rate of 14/min.

His current arterial blood gases are:

pH	7.45
pO_2	7.86 kPa
pCO_2	3.99 kPa
HCO_3	21 mmol/l

Which of the following is the best next step in managing this patient?

- Increase tidal volume 16%
- Increase respiratory rate 4%
- Increase the fraction of inspired oxygen 37%
- Add positive end-expiratory pressure 35%
- Decrease the fraction of inspired oxygen 8%

Fever, confusion, decreased food intake and blood cultures positive for *E. coli* all point towards a diagnosis of sepsis, a common cause of acute respiratory distress syndrome (ARDS). ARDS is characterised by diffuse injury to the pulmonary capillary endothelium and alveolar epithelium that ultimately leads to alveolar collapse and impaired pulmonary gas exchange.

The patients blood gases reflect hypoxaemia and a slight respiratory alkalosis, meaning that despite high FiO_2 settings and sufficient ventilation, his arterial oxygenation remains inadequate. Generally speaking, oxygenation may be improved by further increasing the FiO_2 or by adding positive end-expiratory pressure (PEEP). High FiO_2 is contraindicated due to the risk of pulmonary oxygen toxicity. Thus, the goal in managing mechanically ventilated patients should be to keep the FiO_2 below 40% at all times. Adding PEEP is the next best step here. PEEP prevents alveolar

collapse, directly counteracting the means by which ARDS causes hypoxaemia. It may also reopen some alveoli that have already collapsed.

Choice 1: This patients level of ventilation is adequate as confirmed by a slightly low pCO_2. Increasing the tidal volume would unnecessarily increase the minute ventilation and peak inspiratory pressure, thereby worsening the respiratory alkalosis and increasing the risk of barotrauma respectively.

Choice 2: This patients level of ventilation is adequate as confirmed by a slightly low pCO_2. Increasing the respiratory rate would worsen the respiratory alkalosis and would not improve oxygenation.

Choice 5: Decreasing the FiO_2 at this point would further reduce the patients oxygenation. This patients FiO_2 does need to be reduced soon in order to avoid pulmonary oxygen toxicity, but this should be accomplished by first increasing oxygenation by another means, such as by increasing PEEP.

Discuss (17) Improve

Next question

Acute respiratory distress syndrome

Acute respiratory distress syndrome (ARDS) is caused by the increased permeability of alveolar capillaries leading to fluid accumulation in the alveoli, i.e. non-cardiogenic pulmonary oedema. It is a serious condition that has a mortality of around 40% and is associated with significant morbidity in those who survive.

Causes
- infection: sepsis, pneumonia
- massive blood transfusion
- trauma
- smoke inhalation
- acute pancreatitis
- Covid-19
- cardio-pulmonary bypass

Clinical features are typically of an acute onset and severe:
- dyspnoea
- elevated respiratory rate

- bilateral lung crackles
- low oxygen saturations

A chest x-ray and arterial blood gases are the key investigations.

Criteria (American-European Consensus Conference)
- acute onset (within 1 week of a known risk factor)
- pulmonary oedema: bilateral infiltrates on chest x-ray ('not fully explained by effusions, lobar/lung collapse or nodules)
- non-cardiogenic (pulmonary artery wedge pressure needed if doubt)
- pO2/FiO2 < 40kPa (300 mmHg)

Management
- due to the severity of the condition patients are generally managed in ITU
- oxygenation/ventilation to treat the hypoxaemia
- general organ support e.g. vasopressors as needed
- treatment of the underlying cause e.g. antibiotics for sepsis
- certain strategies such as prone positioning and muscle relaxation have been shown to improve outcome in ARDS

AI + Q 123

Next question >

Textbooks

High-yield textbook

Extended textbook

Links

Royal College of Physicians

6 6

[2011 Acute lung injury review]

Radiopaedia 13 4

[Acute respiratory distress syndrome]

Suggest link Report broken link

Media

Respiratory distress syndrome

Osmosis - YouTube 8 1

Report broken media

Score: **16%**

1 ✗
2 ✗
3 ✗
4 ✗
5 ✗
6 ✗
7 ✗
8 ✗
9 ✗
10 ✗
11 ✗
12 ✓
13 ✗
14 ✗

15	✗
16	✗
17	✗
18	✗
19	✗
20	✗
21	✗
22	✗
23	✓
24	✗
25	✗
26	✗
27	✗
28	✗
29	✓
30	✗
31	✓
32	✗
33	✗
34	✗
35	✗
36	✓
37	✓
38	✗
39	✗
40	✗
41	✓
42	✗
43	✗
44	✗
45	✗
46	✗
47	✗
48	✗
49	✓
50	✗

All contents of this site are © 2024 Passmedicine Limited

A 73-year-old woman presents to the respiratory clinic with progressive breathlessness over the last 18 months. Her past medical history includes angina, breast cancer 14 years ago (treated with mastectomy and radiotherapy) and rheumatoid arthritis (on sulfasalazine and methotrexate). She previously smoked 15 cigarettes per day for 20 years but stopped after her diagnosis of breast cancer.

On examination, the patient has evidence of clubbing with a regular pulse of 68 beats per minute. She is not cyanosed and has no evidence of CO2 retention. On examination of her lungs, there are fine end-inspiratory crackles most affecting the upper zones.

What is the most likely cause of this patient's lung disease?

- Chronic obstructive pulmonary disease
- Idiopathic pulmonary fibrosis
- Methotrexate pneumonitis
- Radiation pneumonitis
- Rheumatoid arthritis

Submit answer

Reference ranges

Score: **0%**

1 -
2 -
3 -
4 -

5 -
6 -
7 -
8 -
9 -
10 -
11 -
12 -
13 -
14 -
15 -
16 -
17 -
18 -
19 -
20 -
21 -
22 -
23 -
24 -
25 -
26 -
27 -
28 -
29 -
30 -
31 -
32 -
33 -
34 -
35 -
36 -
37 -
38 -
39 -

All contents of this site are © 2024 Passmedicine Limited
Back to top

A 73-year-old woman presents to the respiratory clinic with progressive breathlessness over the last 18 months. Her past medical history includes angina, breast cancer 14 years ago (treated with mastectomy and radiotherapy) and rheumatoid arthritis (on sulfasalazine and methotrexate). She previously smoked 15 cigarettes per day for 20 years but stopped after her diagnosis of breast cancer.

On examination, the patient has evidence of clubbing with a regular pulse of 68 beats per minute. She is not cyanosed and has no evidence of CO2 retention. On examination of her lungs, there are fine end-inspiratory crackles most affecting the upper zones.

What is the most likely cause of this patient's lung disease?

Chronic obstructive pulmonary disease	1%
Idiopathic pulmonary fibrosis	10%
Methotrexate pneumonitis	16%
Radiation pneumonitis	62%
Rheumatoid arthritis	11%

Radiotherapy may result in radiation pneumonitis, typically causing upper zone lung fibrosis

Important for me Less important

This patient likely has interstitial lung disease (ILD) as evidenced by clubbing and fine end-inspiratory crackles.

Of the causes listed, **radiation pneumonitis** is a cause of ILD which is most likely to affect the upper zones and the patient has a history of previous radiotherapy, making radiation pneumonitis the most likely cause.

Chronic obstructive pulmonary disease (COPD) does not fit with the clinical findings of clubbing and end-inspiratory crackles.

Idiopathic pulmonary fibrosis is a form of ILD which typically affects the lower zones more than the upper zones and is, therefore, less likely to be the cause.

Rheumatoid arthritis is a form of ILD which typically affects the lower zones more than the upper zones and is, therefore, less likely to be the cause.

Methotrexate pneumonitis typically presents with cough, breathlessness and fever. Methotrexate can also cause lung fibrosis but this would also typically affect the lower zones more than the upper zones so would be the less likely diagnosis in this instance.

Discuss (2) Improve

Next question >

Lung fibrosis

It is important in the exam to be able to differentiate between conditions causing predominately upper or lower zone fibrosis. It should be noted that the more common causes (idiopathic pulmonary fibrosis, drugs) tend to affect the lower zones

Fibrosis predominately affecting the upper zones

- hypersensitivity pneumonitis (also known as extrinsic allergic alveolitis)
- coal worker's pneumoconiosis/progressive massive fibrosis
- silicosis
- sarcoidosis
- ankylosing spondylitis (rare)
- histiocytosis
- tuberculosis
- radiation-induced pulmonary fibrosis
    - may develop following radiotherapy for breast or lung cancer
    - typically seen between 6 and 12 months following completion of radiotherapy course

Fibrosis predominately affecting the lower zones

- idiopathic pulmonary fibrosis
- most connective tissue disorders (except ankylosing spondylitis) e.g. SLE
- drug-induced: amiodarone, bleomycin, methotrexate
- asbestosis

Acronym for causes of upper zone fibrosis:

CHARTS

- C - Coal worker's pneumoconiosis
- H - Histiocytosis/ hypersensitivity pneumonitis
- A - Ankylosing spondylitis
- R - Radiation
- T - Tuberculosis
- S - Silicosis/sarcoidosis

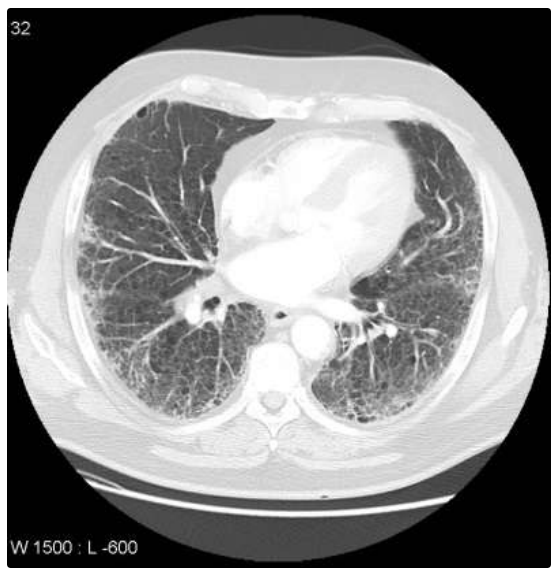

AI + Q 123

Next question

Textbooks

High-yield textbook

Extended textbook

Media

Interstitial Lung Disease (ILD) - Classification, pathophysiology, signs and symptoms

Armando Hasudungan - YouTube

1 0

Report broken media

Score: **16%**

1	✗
2	✗
3	✗
4	✗
5	✗
6	✗
7	✗
8	✗
9	✗
10	✗
11	✗
12	✓
13	✗
14	✗
15	✗
16	✗
17	✗
18	✗
19	✗
20	✗
21	✗
22	✗
23	✓

24	✗
25	✗
26	✗
27	✗
28	✗
29	✓
30	✗
31	✓
32	✗
33	✗
34	✗
35	✗
36	✓
37	✓
38	✗
39	✗
40	✗
41	✓
42	✗
43	✗
44	✗
45	✗
46	✗
47	✗
48	✗
49	✓
50	✗

All contents of this site are © 2024 Passmedicine Limited

Back to top

A 74-year-old ex-miner is reviewed in the Respiratory Clinic with a 4-month history of episodic dyspnoea and dry cough. The attacks last for several days at a time and are accompanied by fever, malaise, and chest tightness. He recovered from the most recent episode 2 weeks ago.

His past medical history is unremarkable and he states that he is generally well between episodes. He does report some long-standing shortness of breath on exertion, but this has been stable for the past 6 years and he estimates his exercise tolerance at 200 yards.

He worked as a miner until the early 1980s and then retrained as a plumber. He continued to work until his retirement in the early 2000s. He now enjoys housing pigeons in his back garden. He does not smoke.

On examination, his respiratory rate is 14/min and his oxygen saturations are 95% breathing room air. His fingers are clubbed and there are bibasal crackles on auscultation of the chest. His heart sounds are dual with nil added.

A high-resolution CT (HRCT) scan of the thorax is reported as showing subpleural bibasal reticular opacities with some evidence of honeycombing but no appreciable ground-glass opacification.

What is the most likely cause of his symptoms?

- Asbestosis
- Hypersensitivity pneumonitis
- Silicosis
- Coal worker's pneumoconiosis
- Idiopathic pulmonary fibrosis

Submit answer

Reference ranges

Score: **0%**

1	-
2	-
3	-
4	-
5	-
6	-
7	-
8	-
9	-
10	-
11	-
12	-
13	-
14	-
15	-
16	-
17	-
18	-
19	-
20	-
21	-
22	-
23	-
24	-
25	-
26	-
27	-
28	-
29	-
30	-
31	-
32	-
33	-
34	-
35	-
36	-
37	-
38	-

39 -
40 -

All contents of this site are © 2024 Passmedicine Limited Back to top

A 74-year-old ex-miner is reviewed in the Respiratory Clinic with a 4-month history of episodic dyspnoea and dry cough. The attacks last for several days at a time and are accompanied by fever, malaise, and chest tightness. He recovered from the most recent episode 2 weeks ago.

His past medical history is unremarkable and he states that he is generally well between episodes. He does report some long-standing shortness of breath on exertion, but this has been stable for the past 6 years and he estimates his exercise tolerance at 200 yards.

He worked as a miner until the early 1980s and then retrained as a plumber. He continued to work until his retirement in the early 2000s. He now enjoys housing pigeons in his back garden. He does not smoke.

On examination, his respiratory rate is 14/min and his oxygen saturations are 95% breathing room air. His fingers are clubbed and there are bibasal crackles on auscultation of the chest. His heart sounds are dual with nil added.

A high-resolution CT (HRCT) scan of the thorax is reported as showing subpleural bibasal reticular opacities with some evidence of honeycombing but no appreciable ground-glass opacification.

What is the most likely cause of his symptoms?

Asbestosis	33%
Hypersensitivity pneumonitis	26%
Silicosis	5%
Coal worker's pneumoconiosis	11%
Idiopathic pulmonary fibrosis	24%

The key to successfully answering this question is to appreciate that it is asking you to explain his symptoms rather than the examination and investigation findings. MRCP questions often include varying amounts of distracting information in order to simulate the complexity of clinical practice, although in this case there is enough information in the opening paragraph to make the diagnosis irrespective of the confounding information presented in the rest of the vignette.

The occurrence of episodic dyspnoea, cough, and flu-like symptoms in response to an environmental antigen is consistent with the acute presentation of hypersensitivity pneumonitis. Patients are well in between episodes and during the early phase of the disease examination and investigation can be normal.

The abnormalities on the HRCT are consistent with usual interstitial pneumonia (UIP); a pathological pattern of interstitial lung disease rather than a diagnosis in itself. UIP has numerous causes, including asbestosis and idiopathic pulmonary fibrosis (IPF). Both of these diagnoses would be in keeping with the clubbing and bibasal crepitations found on examination, but neither would cause the relapsing and remitting symptoms described.

The patient does describe some longstanding dyspnoea on exertion, which would be more in keeping with asbestosis or stable IPF. The absence of ground glass on the HRCT implies there is no active lung inflammation and also suggests stable disease.

Silicosis and coal worker's pneumoconiosis cause upper zone fibrosis. Both conditions typically cause chronic rather than episodic symptoms.

Discuss (13) Improve

Next question

Extrinsic allergic alveolitis

Extrinsic allergic alveolitis (EAA, also known as hypersensitivity pneumonitis) is a condition caused by hypersensitivity induced lung damage due to a variety of inhaled organic particles. It is thought to be largely caused by immune-complex mediated tissue damage (type III hypersensitivity) although delayed hypersensitivity (type IV) is also thought to play a role in EAA, especially in the chronic phase.

Examples
- bird fanciers' lung: avian proteins from bird droppings
- farmers lung: spores of *Saccharopolyspora rectivirgula* from wet hay (formerly *Micropolyspora faeni*)
- malt workers' lung: *Aspergillus clavatus*
- mushroom workers' lung: thermophilic actinomycetes*

Presentation
- acute (occurs 4-8 hrs after exposure)
  - dyspnoea

- dry cough
- fever
- chronic (occurs weeks-months after exposure)
    - lethargy
    - dyspnoea
    - productive cough
    - anorexia and weight loss

Investigation

- imaging: upper/mid-zone fibrosis
- bronchoalveolar lavage: lymphocytosis
- serologic assays for specific IgG antibodies
- blood: NO eosinophilia

Management

- avoid precipitating factors
- oral glucocorticoids

*here the terminology is slightly confusing as thermophilic actinomycetes is an umbrella term covering strains such as *Micropolyspora faeni*

© Image used on license from Radiopaedia

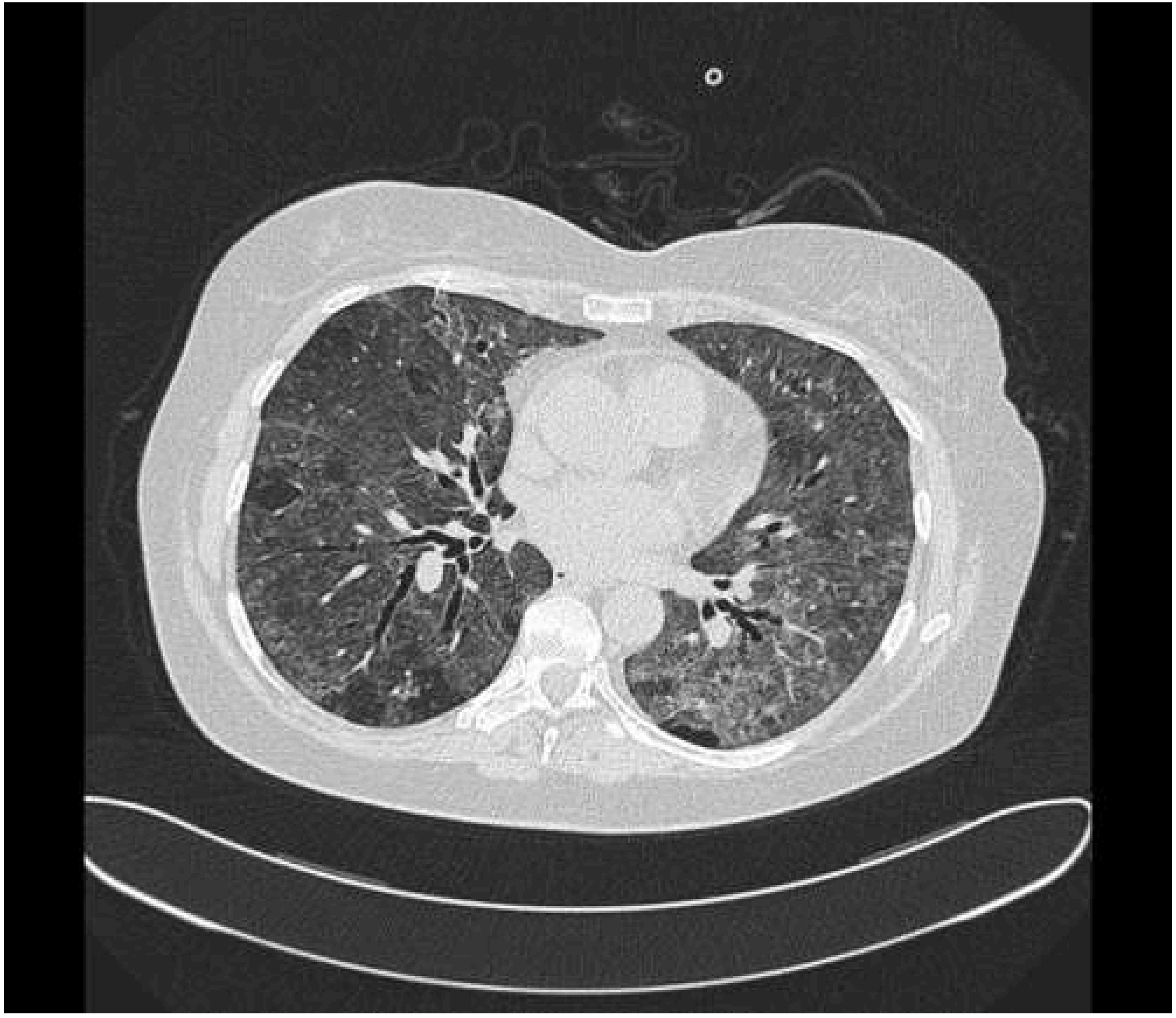

© Image used on license from Radiopaedia

Chest x-ray and CT scan from a middle-aged woman who presented with dyspnoea. The CT demonstrates multuple centrilobular ground glass nodules consistent with hypersensitivity pneumonitis

123

Next question

Textbooks

High-yield textbook

Extended textbook

Media

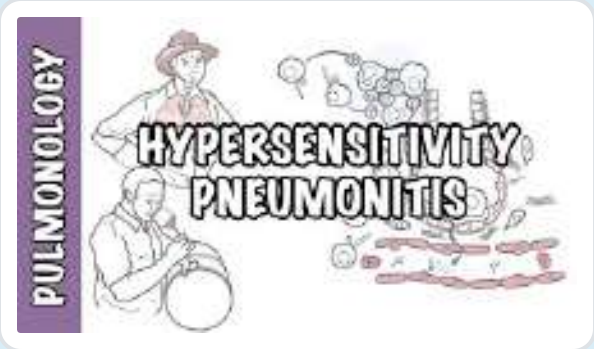

Hypersensitivity pneumonitis

Armando Hasudungan - YouTube 👍 3 👎 1

Report broken media

Score: **16%**

1	✗
2	✗
3	✗
4	✗
5	✗
6	✗
7	✗
8	✗
9	✗
10	✗
11	✗
12	✓
13	✗
14	✗
15	✗
16	✗
17	✗
18	✗
19	✗
20	✗
21	✗
22	✗

23	✓
24	✗
25	✗
26	✗
27	✗
28	✗
29	✓
30	✗
31	✓
32	✗
33	✗
34	✗
35	✗
36	✓
37	✓
38	✗
39	✗
40	✗
41	✓
42	✗
43	✗
44	✗
45	✗
46	✗
47	✗
48	✗
49	✓
50	✗

All contents of this site are © 2024 Passmedicine Limited

Back to top

A 58-year-old smoker was referred to the respiratory outpatient clinic by his GP with a history of progressively worsening shortness of breath. His symptoms started several months ago with shortness of breath on extreme exertion but he gradually developed shortness of breath with minimal activity. He also complained of increasing tiredness and a non-productive cough had lost approximately 3 pounds in 6 months. He denied the presence of sputum production, haemoptysis or chest pain, and also denied the presence of both orthopnoea and paroxysmal nocturnal dyspnoea. He had a past medical history comprising ankylosing spondylosis diagnosed 30 years ago as well as hypertension and hypercholesterolaemia. His drug history comprised naproxen 500mg BD, lansoprazole 30mg OD, felodipine M/R 2.5mg OD and atorvastatin 20mg OD. He stated that he had been trialled with a course of methotrexate a few years ago for his ankylosing spondylosis and was subsequently stopped.

Examination revealed the presence of a well male with a blood pressure of 146/86 mmHg, heart rate 74 bpm and respiratory rate of 18/min. His oxygen saturations were 93% on air. There was no BCG scar seen on examination of his arm. Examination of his respiratory system revealed the presence of bilateral fine upper zone crackles but nil else and no respiratory distress. Examination of his cardiovascular system revealed no abnormalities including a normal JVP and the absence of pedal oedema, and examination of his gastrointestinal system was likewise unremarkable.

Initial investigations revealed the following:

Hb	166 g/l
Platelets	$341 * 10^9$/l
WBC	$6.3 * 10^9$/l
ESR	34 mm/hr
CRP	26 mg/l

Chest x-ray: Bilateral apical fibrosis

Pulmonary function testing

- FEV1 2.4 l (predicted value 2.3)
- FVC 2.6 l (predicted value 4.8)
- FEV1/FVC ratio 92%
- TLCO transfer factor 86% of predicted value

What is the most likely diagnosis?

- Pulmonary hypertension
- Pulmonary tuberculosis
- Pulmonary fibrosis secondary to methotrexate
- Extrinsic allergic alveolitis (EAA)
- Pulmonary fibrosis secondary to ankylosing spondylosis

Submit answer

Reference ranges

Score: **0%**

1 -
2 -
3 -
4 -
5 -
6 -
7 -
8 -
9 -
10 -
11 -
12 -
13 -
14 -
15 -
16 -
17 -
18 -

19 -
20 -
21 -
22 -
23 -
24 -
25 -
26 -
27 -
28 -
29 -
30 -
31 -
32 -
33 -
34 -
35 -
36 -
37 -
38 -
39 -
40 -
41 -

All contents of this site are © 2024 Passmedicine Limited
Back to top

A 58-year-old smoker was referred to the respiratory outpatient clinic by his GP with a history of progressively worsening shortness of breath. His symptoms started several months ago with shortness of breath on extreme exertion but he gradually developed shortness of breath with minimal activity. He also complained of increasing tiredness and a non-productive cough had lost approximately 3 pounds in 6 months. He denied the presence of sputum production, haemoptysis or chest pain, and also denied the presence of both orthopnoea and paroxysmal nocturnal dyspnoea. He had a past medical history comprising ankylosing spondylosis diagnosed 30 years ago as well as hypertension and hypercholesterolaemia. His drug history comprised naproxen 500mg BD, lansoprazole 30mg OD, felodipine M/R 2.5mg OD and atorvastatin 20mg OD. He stated that he had been trialled with a course of methotrexate a few years ago for his ankylosing spondylosis and was subsequently stopped.

Examination revealed the presence of a well male with a blood pressure of 146/86 mmHg, heart rate 74 bpm and respiratory rate of 18/min. His oxygen saturations were 93% on air. There was no BCG scar seen on examination of his arm. Examination of his respiratory system revealed the presence of bilateral fine upper zone crackles but nil else and no respiratory distress. Examination of his cardiovascular system revealed no abnormalities including a normal JVP and the absence of pedal oedema, and examination of his gastrointestinal system was likewise unremarkable.

Initial investigations revealed the following:

Hb	166 g/l
Platelets	341 * 10^9/l
WBC	6.3 * 10^9/l
ESR	34 mm/hr
CRP	26 mg/l

Chest x-ray: Bilateral apical fibrosis

Pulmonary function testing
- FEV1 2.4 l (predicted value 2.3)
- FVC 2.6 l (predicted value 4.8)
- FEV1/FVC ratio 92%
- TLCO transfer factor 86% of predicted value

What is the most likely diagnosis?

- Pulmonary hypertension 1%
- Pulmonary tuberculosis 3%
- Pulmonary fibrosis secondary to methotrexate 9%
- Extrinsic allergic alveolitis (EAA) 6%
- Pulmonary fibrosis secondary to ankylosing spondylosis 81%

Upper zones lung fibrosis: ankylosing spondylitis

Important for me Less important

This gentleman has presented with a gradual history of progressing worsening shortness of breath on exertion and a dry cough. His spirometry illustrates a restrictive picture and chest x-ray confirms bilateral apical fibrosis. Of the above options, the most likely option is being secondary to ankylosing spondylosis. Methotrexate causes a lower zone fibrosis and of the remaining options, there is little evidence of exposure to suggest a diagnosis of EAA. There is little evidence to suggest the presence of clinically symptomatic pulmonary hypertension as manifest by the presence of a normal JVP and absence of peripheral oedema.

Discuss (9) Improve

Next question

Lung fibrosis

It is important in the exam to be able to differentiate between conditions causing predominately upper or lower zone fibrosis. It should be noted that the more common causes (idiopathic pulmonary fibrosis, drugs) tend to affect the lower zones

Fibrosis predominately affecting the upper zones

- hypersensitivity pneumonitis (also known as extrinsic allergic alveolitis)
- coal worker's pneumoconiosis/progressive massive fibrosis
- silicosis
- sarcoidosis
- ankylosing spondylitis (rare)

- histiocytosis
- tuberculosis
- radiation-induced pulmonary fibrosis
  - may develop following radiotherapy for breast or lung cancer
  - typically seen between 6 and 12 months following completion of radiotherapy course

Fibrosis predominately affecting the lower zones

- idiopathic pulmonary fibrosis
- most connective tissue disorders (except ankylosing spondylitis) e.g. SLE
- drug-induced: amiodarone, bleomycin, methotrexate
- asbestosis

Acronym for causes of upper zone fibrosis:

CHARTS

- C - Coal worker's pneumoconiosis
- H - Histiocytosis/ hypersensitivity pneumonitis
- A - Ankylosing spondylitis
- R - Radiation
- T - Tuberculosis
- S - Silicosis/sarcoidosis

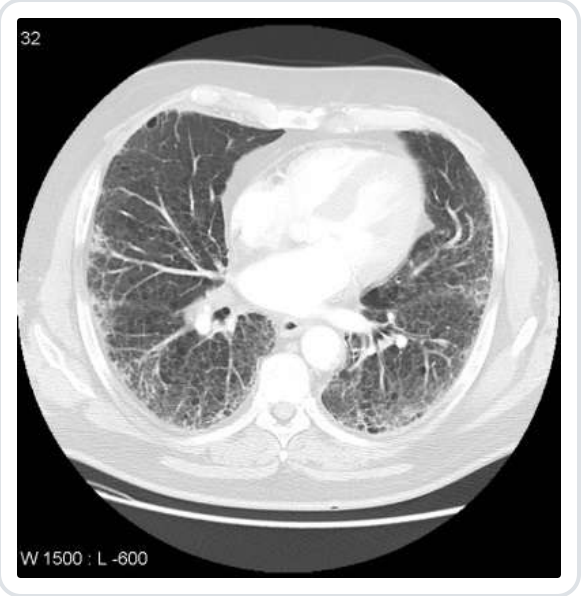

123

Next question

Textbooks

High-yield textbook

Extended textbook

Media

Interstitial Lung Disease (ILD) - Classification, pathophysiology, signs and symptoms

Armando Hasudungan - YouTube 1 0

Report broken media

Score: **16%**

1 ✕
2 ✕
3 ✕
4 ✕
5 ✕
6 ✕
7 ✕
8 ✕
9 ✕
10 ✕
11 ✕

12	✓
13	✗
14	✗
15	✗
16	✗
17	✗
18	✗
19	✗
20	✗
21	✗
22	✗
23	✓
24	✗
25	✗
26	✗
27	✗
28	✗
29	✓
30	✗
31	✓
32	✗
33	✗
34	✗
35	✗
36	✓
37	✓
38	✗
39	✗
40	✗
41	✓
42	✗
43	✗
44	✗
45	✗
46	✗
47	✗

48	✗
49	✓
50	✗

All contents of this site are © 2024 Passmedicine Limited

Back to top

A 10-year-old patient is referred to the respiratory outpatient clinic with recurrent chest infections associated with purulent sputum. His family life is chaotic and his parents frequently did not bring him to routine hospital appointments.

On examination, there are bilateral coarse crackles heard on chest auscultation, which clear on coughing. He is of thin body habitus. The nails are normal.

A chest x-ray shows evidence of bronchiectasis. A sputum sample grows *Burkholderia cepacia* . Genetic testing reveals that he is homozygous for the delta F508 mutation.

Given the likely diagnosis, which of the following is an appropriate treatment option?

- Low calorie, low fat diet
- Lumacaftor/Ivacaftor
- Lung transplant
- Mepolizumab
- Octreotide

Submit answer

Reference ranges

Score: **0%**

1 -
2 -
3 -
4 -

```
-
-
-
-
-
-
-
-
-
-
-
-
-
-
-
-
-
-
-
-
-
-
-
-
-
-
-
-
-
-
-
-
-
-
-
-
-
-
```

All contents of this site are © 2024 Passmedicine Limited

A 10-year-old patient is referred to the respiratory outpatient clinic with recurrent chest infections associated with purulent sputum. His family life is chaotic and his parents frequently did not bring him to routine hospital appointments.

On examination, there are bilateral coarse crackles heard on chest auscultation, which clear on coughing. He is of thin body habitus. The nails are normal.

A chest x-ray shows evidence of bronchiectasis. A sputum sample grows *Burkholderia cepacia* . Genetic testing reveals that he is homozygous for the delta F508 mutation.

Given the likely diagnosis, which of the following is an appropriate treatment option?

Low calorie, low fat diet	4%
Lumacaftor/Ivacaftor	81%
Lung transplant	9%
Mepolizumab	4%
Octreotide	2%

Lumacaftor/Ivacaftor (Orkambi) can be used to treat cystic fibrosis patients who are homozygous for the delta F508 mutation

Important for me   Less important

Lumacaftor/Ivacaftor is the correct answer. The patient has cystic fibrosis as evidenced by recurrent chest infections, bronchiectasis and homozygosity for the delta F508 mutation of the cystic fibrosis transmembrane conductance regulator (CFTR) gene. It is known as 'Orkambi'. It has been shown to improve pulmonary function, increase weight and decrease pulmonary exacerbations. This patient's chaotic family life explains the delayed diagnosis.

Lung transplant is incorrect. This patient is colonized with *Burkholderia cepacia* , which is a CF contraindication to lung transplant.

Mepolizumab is incorrect. This is an IL5 inhibitor that is used in the treatment of refractory asthma, rather than CF. Given it is an immunosuppressant medication, it would probably have deleterious

effects in CF where infections are common.

Low calorie, low-fat diet is incorrect. Patients with CF are often of low body weight and should be encouraged to have a high fat, high-calorie diet.

Octreotide is incorrect. This has been postulated to be of benefit in yellow nail syndrome, which is a rare cause of bronchiectasis. However, the nails are normal in this case and there are no pleural effusions, making this diagnosis unlikely.

Discuss (1) Improve

Next question

Cystic fibrosis: management

Management of cystic fibrosis (CF) involves a multidisciplinary approach

Key points
- regular (at least twice daily) chest physiotherapy and postural drainage. Parents are usually taught to do this. Deep breathing exercises are also useful
- high calorie diet, including high fat intake*
- patients with CF should try to minimise contact with each other to prevent cross infection with *Burkholderia cepacia* complex and *Pseudomonas aeruginosa*
- vitamin supplementation
- pancreatic enzyme supplements taken with meals
- lung transplantion
    - chronic infection with *Burkholderia cepacia* is an important CF-specific contraindication to lung transplantation

Lumacaftor/Ivacaftor (Orkambi)
- is used to treat cystic fibrosis patients who are homozygous for the delta F508 mutation
- lumacaftor increases the number of CFTR proteins that are transported to the cell surface
- ivacaftor is a potentiator of CFTR that is already at the cell surface, increasing the probability that the defective channel will be open and allow chloride ions to pass through the channel pore

*this is now the standard recommendation - previously high calorie, low-fat diets have been recommended to reduce the amount of steatorrhoea

123

Next question

Textbooks

High-yield textbook

Extended textbook

Links

Cystic Fibrosis Trust 6 6

Nutrition for adults

NICE 9 4

2017 Cystic fibrosis: diagnosis and management

Suggest link

Report broken link

Media

Cystic fibrosis

Osmosis - YouTube 6 0

Cystic fibrosis: pathology review

Osmosis - YouTube 👍 2 👎 0

Report broken media

Score: **16%**

1	✗
2	✗
3	✗
4	✗
5	✗
6	✗
7	✗
8	✗
9	✗
10	✗
11	✗
12	✓
13	✗
14	✗
15	✗
16	✗
17	✗
18	✗
19	✗
20	✗
21	✗
22	✗
23	✓
24	✗

25	✗
26	✗
27	✗
28	✗
29	✓
30	✗
31	✓
32	✗
33	✗
34	✗
35	✗
36	✓
37	✓
38	✗
39	✗
40	✗
41	✓
42	✗
43	✗
44	✗
45	✗
46	✗
47	✗
48	✗
49	✓
50	✗

All contents of this site are © 2024 Passmedicine Limited

Back to top

A 27-year-old non smoker Chinese lady presents to the emergency department with sudden onset left pleuritic chest pain and shortness of breath. She explains that she has suffered from gradual deterioration in her exercise tolerance over the last year.

Chest x-ray demonstrated a large pneumothorax that is aspirated successfully. Repeat chest x-ray shows resolution of the pneumothorax but reticulonodular changes in the bases bilaterally.

CT chest: cystic changes in the lung bases with a minimal left sided pleural effusion.

What is the most likely diagnosis?

- Neurofibromatosis
- Alveolar proteinosis
- Langerhans cell histiocytosis
- Lymphangioleiomyomatosis
- Hermansky Pudlak Syndrome

Submit answer

Reference ranges

6 -
7 -
8 -
9 -
10 -
11 -
12 -
13 -
14 -
15 -
16 -
17 -
18 -
19 -
20 -
21 -
22 -
23 -
24 -
25 -
26 -
27 -
28 -
29 -
30 -
31 -
32 -
33 -
34 -
35 -
36 -
37 -
38 -
39 -
40 -
41 -
42 -
43 -

All contents of this site are © 2024 Passmedicine Limited

A 27-year-old non smoker Chinese lady presents to the emergency department with sudden onset left pleuritic chest pain and shortness of breath. She explains that she has suffered from gradual deterioration in her exercise tolerance over the last year.

Chest x-ray demonstrated a large pneumothorax that is aspirated successfully. Repeat chest x-ray shows resolution of the pneumothorax but reticulonodular changes in the bases bilaterally.

CT chest: cystic changes in the lung bases with a minimal left sided pleural effusion.

What is the most likely diagnosis?

Neurofibromatosis	1%
Alveolar proteinosis	14%
Langerhans cell histiocytosis	29%
Lymphangioleiomyomatosis	41%
Hermansky Pudlak Syndrome	15%

Lymphangioleiomyomatosis (LAM) affects premenopausal women causing proliferation of atypical smooth muscle cells in the lungs, lymphatics and uterus, most likely caused by oestrogens. There is associations with tuberous sclerosis and renal angiomyolipomas. Presentation is with dyspnoea due to progressive interstitial lung disease, pneumothorax or chylous pleural effusion. Lung damage is similar to emphysema with pulmonary function tests showing reduced FVC, TLCO and KCO with increased TLC.

Medroxyprogesterone is an anti-oestrogen used to delay disease progression.

It is important to exclude metastatic sarcoma and atypical Langerhans cell histiocytosis. Langerhans cell histiocytosis affects smokers 20-40 years due to proliferation of Langerhans cells (antigen presenting cells containing Birkbeck bodies on electron microscopy). Presentation of LCH is with exertional dyspnoea and cough, spontaneous pneumothorax, clubbing and manifestation of granuloma infiltration in bones and the hypothalamus (diabetes insipidus is commonly seen).

Alveolar proteinosis most commonly affects males and can be secondary to insecticides, silica, HIV.

There is accumulation of lipoproteinaceous material in the alveolar spaces. Presentation involves dyspnoea, chest pain, haemoptysis and clubbing. Chest x-ray shows bat wings and diagnosis is confirmed with bronchoalveolar lavage (milky fluid, PAS positive material).

Hermansky Pudlak syndrome consists of oculocutaneous albinism, abnormal platelet function and interstitial lung disease.

Discuss (7) Improve

Next question

Pneumothorax: management

The British Thoracic Society (BTS) published updated guidelines for the management of spontaneous pneumothorax in 2023.

The updated guidelines put less emphasis on the size of the pneumothorax and more emphasis on whether the patient is symptomatic and the presence of high-risk characteristics.

Decision algorithm

The first step is assessing whether the patient is symptomatic
- the BTS define minimal symptoms as '*no significant pain or breathlessness and no physiological compromise*'
- no or minimal symptoms → conservative care, regardless of pneumothorax size
- symptomatic → assess for high-risk characteristics

If a pneumothorax is symptomatic, the next step is assessment for high-risk characteristics
- high-risk characteristics are defined as follows:
    - haemodynamic compromise (suggesting a tension pneumothorax)
    - significant hypoxia
    - bilateral pneumothorax
    - underlying lung disease
    - ≥ 50 years of age with significant smoking history
    - haemothorax
- if no high-risk characteristics are present, and it is safe to intervene, then there is a choice of intervention:
    - conservative care
    - ambulatory device
    - needle aspiration

- if high-risk characteristics are present, and it is safe to intervene → chest drain

How is safety or intervention determined?

- before a needle aspiration/chest drain insertion, the safety of intervention should be assessed
- this depends on the clinical context, but is usually:
  - 2cm laterally or apically on chest x-ray, or
  - any size on CT scan which can be safely accessed with radiological support

Management options

Conservative care

- patients with a primary spontaneous pneumothorax that is managed conservatively should be reviewed every 2-4 days as an outpatient
- patients with a secondary spontaneous pneumothorax that is managed conservatively should be monitored as an inpatient
- if stable, follow-up in the outpatients department in 2-4 weeks

Ambulatory care

- an example of an ambulatory device is the Rocketµ Pleural Vent„
- it includes an 8FG catheter mounted on an 18G needle and a pigtail catheter to minimize the risk of occlusion
- ambulatory devices typically have a one-way valve and vent to prevent air and fluid return to the pleural space while allowing for controlled escape of air and drainage of fluid
- many devices also have an indication diaphragm that signals when the catheter tip enters the pleural space and continues to fluctuate with respiration, aiding in the assessment of pneumothorax resolution

Needle aspiration

- a chest drain should be inserted if needle aspiration of a pneumothorax is unsuccessful
- if resolved, discharge and follow-up in the outpatients department in 2-4 weeks

Chest drain insertion

- daily review as an inpatient
- remove drain when resolved
- discharge and follow-up in the outpatients department in 2-4 weeks

Persistentent / recurrent pneumothorax

If a patient has a persistent air leak or insufficient lung reexpansion despite chest drain insertion, or the patient has recurrent pneumothoraces, then video-assisted thoracoscopic surgery (VATS) should be considered to allow for mechanical/chemical pleurodesis +/- bullectomy.

Discharge advice

Smoking

- patients should be advised to avoid smoking to reduce the risk of further episodes - the lifetime risk of developing a pneumothorax in healthy smoking men is around 10% compared with around 0.1% in non-smoking men

Fitness to fly

- absolute contraindication, the CAA suggest patients may travel 2 weeks after successful drainage if there is no residual air. The British Thoracic Society used to recommend not travelling by air for a period of 6 weeks but this has now been changed to 1 week post check x-ray

Scuba diving

- the BTS guidelines state: '*Diving should be permanently avoided unless the patient has undergone bilateral surgical pleurectomy and has normal lung function and chest CT scan postoperatively.*'

Image gallery

123

Next question

Textbooks

High-yield textbook

Extended textbook

Links

British Thoracic Society

2 1

2023 Pleural disease guidelines

Suggest link

Report broken link

Media

[How to identify pneumothorax on a chest X-ray]

Medmastery - YouTube 30 1

Pneumothorax

Zero To Finals - YouTube 9 1

Pneumothorax

Osmosis - YouTube 6 1

Needle Aspiration of Pneumothorax

NEJM - YouTube 10 6

Report broken media

Score: **16%**

1 ✗
2 ✗
3 ✗
4 ✗
5 ✗
6 ✗
7 ✗
8 ✗

9	✗
10	✗
11	✗
12	✓
13	✗
14	✗
15	✗
16	✗
17	✗
18	✗
19	✗
20	✗
21	✗
22	✗
23	✓
24	✗
25	✗
26	✗
27	✗
28	✗
29	✓
30	✗
31	✓
32	✗
33	✗
34	✗
35	✗
36	✓
37	✓
38	✗
39	✗
40	✗
41	✓
42	✗
43	✗
44	✗

45 ✗
46 ✗
47 ✗
48 ✗
49 ✓
50 ✗

All contents of this site are © 2024 Passmedicine Limited

Back to top

A 28-year-old man is referred by A&E to the acute medical team. He is a Swedish student studying for his PhD at the local university. He complains of a 6-week history of a non-productive cough associated with fevers. He denies haemoptysis or weight but admits that his exercise tolerance has reduced over the same period. He also reports pains in his knees, ankles and wrists and some painful red swellings on his legs. He admits to having had these before several years ago but they went away without any medical treatment and left no scars. He denies any bowel symptoms. On examination, he is afebrile and cardiovascularly stable. His respiratory rate is 18 at rest and his saturations are 96% on air. He has no palpable lymphadenopathy and his respiratory examination is normal, as is cardiovascular and abdominal examinations. His shins have bilateral tender red nodules on them.

His bloods results done by A&E are:

Hb	145 g/l
Platelets	365 * 10^9/l
WBC	9.1 * 10^9/l
Neuts	5.1 * 10^9/l

Na^+	140 mmol/l
K^+	4.2 mmol/l
Urea	5.4 mmol/l
Creatinine	82 µmol/l

Bilirubin	4 µmol/l
ALP	59 u/l
ALT	23 u/l
Albumin	43 g/l
CRP	5 mg/l
Adjusted calcium	2.65 mmol/l

His chest x-ray shows bilateral hilar lymphadenopathy with some small bilateral pulmonary infiltrates.

He goes on to have a CT chest which confirms the above findings. A bronchoscopy is performed

which is normal and transbronchial biopsies of the hilar lymph nodes show non-caseating granulomas.

What is the most appropriate treatment for this gentleman?

- Prednisolone
- NSAIDs
- R-CHOP
- Methotrexate
- Nothing

Submit answer

Reference ranges

Score: **0%**

1 -
2 -
3 -
4 -
5 -
6 -
7 -
8 -
9 -
10 -
11 -
12 -
13 -
14 -

15 -
16 -
17 -
18 -
19 -
20 -
21 -
22 -
23 -
24 -
25 -
26 -
27 -
28 -
29 -
30 -
31 -
32 -
33 -
34 -
35 -
36 -
37 -
38 -
39 -
40 -
41 -
42 -
43 -
44 -

All contents of this site are © 2024 Passmedicine Limited
Back to top

A 28-year-old man is referred by A&E to the acute medical team. He is a Swedish student studying for his PhD at the local university. He complains of a 6-week history of a non-productive cough associated with fevers. He denies haemoptysis or weight but admits that his exercise tolerance has reduced over the same period. He also reports pains in his knees, ankles and wrists and some painful red swellings on his legs. He admits to having had these before several years ago but they went away without any medical treatment and left no scars. He denies any bowel symptoms. On examination, he is afebrile and cardiovascularly stable. His respiratory rate is 18 at rest and his saturations are 96% on air. He has no palpable lymphadenopathy and his respiratory examination is normal, as is cardiovascular and abdominal examinations. His shins have bilateral tender red nodules on them.

His bloods results done by A&E are:

Hb	145 g/l
Platelets	365 * 10^9/l
WBC	9.1 * 10^9/l
Neuts	5.1 * 10^9/l

Na^+	140 mmol/l
K^+	4.2 mmol/l
Urea	5.4 mmol/l
Creatinine	82 µmol/l

Bilirubin	4 µmol/l
ALP	59 u/l
ALT	23 u/l
Albumin	43 g/l
CRP	5 mg/l
Adjusted calcium	2.65 mmol/l

His chest x-ray shows bilateral hilar lymphadenopathy with some small bilateral pulmonary infiltrates.

He goes on to have a CT chest which confirms the above findings. A bronchoscopy is performed

which is normal and transbronchial biopsies of the hilar lymph nodes show non-caseating granulomas.

What is the most appropriate treatment for this gentleman?

Prednisolone	77%
NSAIDs	3%
R-CHOP	2%
Methotrexate	2%
Nothing	17%

This gentleman has Lofgren's syndrome a presentation of Sarcoidosis characterised by Arthralgias, fevers, erythema nodosum and bilateral hilar lymphadenopathy. It is typically more common in Scandinavian patients and less common in Afro-Caribbean patients and typically has a much better prognosis. This gentleman has stage 2 sarcoidosis as indicated by the presence of BHL and pulmonary infiltrates on CXR. In this case, oral corticosteroids are the preferred treatment. For less symptomatic patients then supportive measures and NSAIDs for arthralgia are the preferred treatment options. For patients who are not responsive to steroids or steroid intolerant then immunosuppressant agents such as methotrexate can be tried. RCHOP is a chemotherapy regime used in lymphoma patients but the presence of non-caseating granulomas should suggest a diagnosis other than lymphoma.

Discuss (1) Improve

Next question

Lofgren's syndrome

Lofgren's syndrome is an acute form sarcoidosis characterised by bilateral hilar lymphadenopathy (BHL), erythema nodosum, fever and polyarthralgia.

It typically occurs in young females and carries an excellent prognosis.

123

Next question

Textbooks

High-yield textbook

Extended textbook

Score: **16%**

1	✗
2	✗
3	✗
4	✗
5	✗
6	✗
7	✗
8	✗
9	✗
10	✗
11	✗
12	✓
13	✗
14	✗
15	✗

16	✗
17	✗
18	✗
19	✗
20	✗
21	✗
22	✗
23	✓
24	✗
25	✗
26	✗
27	✗
28	✗
29	✓
30	✗
31	✓
32	✗
33	✗
34	✗
35	✗
36	✓
37	✓
38	✗
39	✗
40	✗
41	✓
42	✗
43	✗
44	✗
45	✗
46	✗
47	✗
48	✗
49	✓
50	✗

All contents of this site are © 2024 Passmedicine Limited

A 52-year-old woman presents to the respiratory clinic for review. She recently had a cough for which she received a week-long course of amoxicillin by her GP. As the cough had not settled within ten days, she returned to the GP who organised a chest X-ray. Afterwards, she was referred to the respiratory clinic due to the findings on it. This surprised her as by this point all of her symptoms had resolved. She has a past medical history of idiopathic intracranial hypertension, polycystic ovaries and type 2 diabetes mellitus. She takes only metformin and has no allergies. She has never smoked and has no occupational exposure of note. She drinks roughly one glass of wine per day. On examination she is obese but her chest is clear on auscultation. The chest X-ray demonstrates bilateral hilar lymphadenopathy.

Hb	127 g/l
Platelets	417 * 10^9/l
WBC	6.2 * 10^9/l
ESR	43 mm/hr
Na^+	138 mmol/
K^+	3.7 mmol/l
Urea	4.8 mmol/l
Creatinine	82 μmol/l
Corrected calcium	2.1 mmol/l

What is the most appropriate management plan?

- Discharge without further investigation
- Start ACE inhibitors
- Monitoring of lung function tests
- Start methotrexate
- Start corticosteroids

Submit answer

Reference ranges

Score: **0%**

1	-
2	-
3	-
4	-
5	-
6	-
7	-
8	-
9	-
10	-
11	-
12	-
13	-
14	-
15	-
16	-
17	-
18	-
19	-
20	-
21	-
22	-
23	-
24	-
25	-
26	-
27	-
28	-
29	-
30	-
31	-
32	-
33	-
34	-

35 -
36 -
37 -
38 -
39 -
40 -
41 -
42 -
43 -
44 -
45 -

All contents of this site are © 2024 Passmedicine Limited

A 52-year-old woman presents to the respiratory clinic for review. She recently had a cough for which she received a week-long course of amoxicillin by her GP. As the cough had not settled within ten days, she returned to the GP who organised a chest X-ray. Afterwards, she was referred to the respiratory clinic due to the findings on it. This surprised her as by this point all of her symptoms had resolved. She has a past medical history of idiopathic intracranial hypertension, polycystic ovaries and type 2 diabetes mellitus. She takes only metformin and has no allergies. She has never smoked and has no occupational exposure of note. She drinks roughly one glass of wine per day. On examination she is obese but her chest is clear on auscultation. The chest X-ray demonstrates bilateral hilar lymphadenopathy.

Hb	127 g/l
Platelets	417 * 10^9/l
WBC	6.2 * 10^9/l
ESR	43 mm/hr
Na^+	138 mmol/
K^+	3.7 mmol/l
Urea	4.8 mmol/l
Creatinine	82 µmol/l
Corrected calcium	2.1 mmol/l

What is the most appropriate management plan?

- Discharge without further investigation 45%
- Start ACE inhibitors 4%
- Monitoring of lung function tests 31%
- Start methotrexate 1%
- Start corticosteroids 19%

The correct answer is to monitor lung function tests. This is a patient who has X-ray features consistent with sarcoidosis. As these are stage I X-ray features, there is no involvement of other

organs and the calcium is normal there is no need to start treatment with corticosteroids. Corticosteroids would be the mainstay of treatment if indicated. Sarcoidosis patients should have lung function assessed and a decline in lung function should warrant treatment.

Discuss (12) Improve

Next question

Sarcoidosis: management

Sarcoidosis is a multisystem disorder of unknown aetiology characterised by non-caseating granulomas. It is more common in young adults and in people of African descent.

Indications for steroids

- patients with chest x-ray stage 2 or 3 disease who are symptomatic. Patients with asymptomatic and stable stage 2 or 3 disease who have only mildly abnormal lung function do not require treatment
- hypercalcaemia
- eye, heart or neuro involvement

+ Q 123

Next question

Textbooks

High-yield textbook

Extended textbook

Links

Radiopaedia 8 6

Pulmonary sarcoidosis staging

Suggest link Report broken link

Media

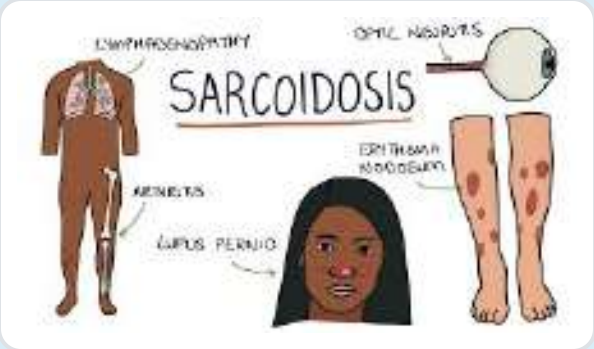

Sarcoidosis

Sarcoidosis - YouTube 6 0

Sarcoidosis

Osmosis - YouTube 4 0

Report broken media

Score: **16%**

1 ✗
2 ✗
3 ✗
4 ✗
5 ✗
6 ✗
7 ✗
8 ✗
9 ✗
10 ✗

11	✗
12	✓
13	✗
14	✗
15	✗
16	✗
17	✗
18	✗
19	✗
20	✗
21	✗
22	✗
23	✓
24	✗
25	✗
26	✗
27	✗
28	✗
29	✓
30	✗
31	✓
32	✗
33	✗
34	✗
35	✗
36	✓
37	✓
38	✗
39	✗
40	✗
41	✓
42	✗
43	✗
44	✗
45	✗
46	✗

47 ✗
48 ✗
49 ✓
50 ✗

All contents of this site are © 2024 Passmedicine Limited

A 68-year-old builder presents to the emergency department with a 2-week history of worsening left-sided chest pain. The pain is sharp in nature and worsens on inspiration and movement, making him almost restricted to sitting down all day. He feels occasionally short of breath. His past medical history consists of peripheral vascular disease and chronic obstructive pulmonary disease (COPD).

On examination, he is afebrile. His heart rate is 88bpm with a blood pressure of 116/77mmHg. His respiratory rate is 21 breaths per minute with saturations of 91% on room air. On auscultation, there is mild wheeze bilaterally but no coarse crackles. Heart sounds are normal and abdominal examination is unremarkable. There is mild reproducible left-sided chest wall tenderness.

A number of investigations are requested.

Laboratory results:

Hb	101 g/L	Male: (135-180)
MCV	71 fL	(80-100 fL)
Platelets	299 * 10^9/L	(150 - 400)
WBC	8.1 * 10^9/L	(4.0 - 11.0)
D-Dimer	501 ng/mL	(< 400)
Na^+	136 mmol/L	(135 - 145)
K^+	4.1 mmol/L	(3.5 - 5.0)
Urea	6.2 mmol/L	(2.0 - 7.0)
Creatinine	98 µmol/L	(55 - 120)
CRP	67 mg/L	(< 5)

Chest x-ray:

© Image used on license from Radiopaedia

What is the most likely diagnosis?

- Asbestosis
- Loculated pleural effusion
- Mesothelioma
- Pulmonary embolism
- Small cell carcinoma

Submit answer

Reference ranges

Score: **0%**

1 -
2 -
3 -
4 -
5 -
6 -
7 -
8 -
9 -
10 -
11 -
12 -
13 -
14 -
15 -
16 -
17 -
18 -
19 -
20 -
21 -
22 -
23 -
24 -
25 -
26 -
27 -
28 -
29 -
30 -
31 -
32 -
33 -
34 -
35 -
36 -
37 -
38 -

39 -
40 -
41 -
42 -
43 -
44 -
45 -
46 -

All contents of this site are © 2024 Passmedicine Limited
Back to top

A 68-year-old builder presents to the emergency department with a 2-week history of worsening left-sided chest pain. The pain is sharp in nature and worsens on inspiration and movement, making him almost restricted to sitting down all day. He feels occasionally short of breath. His past medical history consists of peripheral vascular disease and chronic obstructive pulmonary disease (COPD).

On examination, he is afebrile. His heart rate is 88bpm with a blood pressure of 116/77mmHg. His respiratory rate is 21 breaths per minute with saturations of 91% on room air. On auscultation, there is mild wheeze bilaterally but no coarse crackles. Heart sounds are normal and abdominal examination is unremarkable. There is mild reproducible left-sided chest wall tenderness.

A number of investigations are requested.

Laboratory results:

Hb	101 g/L	Male: (135-180)
MCV	71 fL	(80-100 fL)
Platelets	299 * 10^9/L	(150 - 400)
WBC	8.1 * 10^9/L	(4.0 - 11.0)
D-Dimer	501 ng/mL	(< 400)
Na^+	136 mmol/L	(135 - 145)
K^+	4.1 mmol/L	(3.5 - 5.0)
Urea	6.2 mmol/L	(2.0 - 7.0)
Creatinine	98 µmol/L	(55 - 120)
CRP	67 mg/L	(< 5)

Chest x-ray:

© Image used on license from Radiopaedia

What is the most likely diagnosis?

Asbestosis	17%
Loculated pleural effusion	14%
Mesothelioma	56%
Pulmonary embolism	11%
Small cell carcinoma	2%

This patient has mesothelioma, a type of malignancy of the mesothelium, the tissue surrounding visceral organs including the lungs and chest wall, heart and abdominal cavity. Most commonly the pleura are affected. The biggest risk factor is asbestos exposure. With this patient having worked as a builder, it is very possible that he has come into contact with asbestos during his career. There is a visible opacification on the left lateral chest wall of the chest x-ray, in keeping with a pleural mass. Unlike other types of pulmonary malignancy that commonly affect the bronchi and lung parenchyma, mesothelioma affects the pleura and would therefore be located peripherally. One of the most common and important symptoms to recognise is severe chest wall pain as the tumour invades into the intercostal nerves.

Asbestosis is characterised by the development of lung fibrosis secondary to asbestos exposure. Important distinguishing features between asbestosis and mesothelioma are the presence of chest pain, progressive shortness of breath and constitutional symptoms such as fever, weight loss and night sweats. This patient is experiencing chest pain, fatigue and shortness of breath. Furthermore, his full blood count demonstrates microcytic anaemia which suggests the possibility of an underlying malignancy.

A pleural effusion is a collection of fluid within the pleural space. An exudative pleural effusion is more likely to become loculated. Appearances of loculated pleural effusions can sometimes appear similar to the chest x-ray shown in the question. However, the absence of a raised white cell count, in combination with a significant history of chest wall pain suggests an alternative diagnosis.

A pulmonary embolism is an important differential diagnosis given the raised D-dimer and pleuritic-sounding chest pain. Occasionally, a pulmonary embolism may have chest x-ray findings such as a wedge infarction. However, a raised D-dimer can also indicate an underlying malignancy. Furthermore, a peripherally-located lesion is unlikely to represent a pulmonary embolism.

Small cell carcinoma is a pulmonary malignancy commonly associated with tobacco use. As this patient has a history of COPD, it is likely that he has a significant smoking history. Asbestos exposure and tobacco use are synergistic to one another and increase the risk of malignancy. A small cell carcinoma tends to be located more centrally on chest x-ray films compared to mesothelioma as seen here.

Discuss (5) | Improve

Next question ›

Mesothelioma

Mesothelioma is a cancer of the mesothelial layer of the pleural cavity that is strongly associated with asbestos exposure. In a small percentage of cases, other mesothelial layers such as those in the abdomen may be affected.

Features

- Dyspnoea, weight loss, chest wall pain
- Clubbing
- 30% present as painless pleural effusion
- Only 20% have pre-existing asbestosis
- History of asbestos exposure in 85-90%, latent period of 30-40 years

Basics

- Malignancy of mesothelial cells of pleura
- Metastases to contralateral lung and peritoneum
- Right lung affected more often than left

Investigation/diagnosis

- suspicion is normally raised by a chest x-ray showing either a pleural effusion or pleural thickening
- the next step is normally a pleural CT
- if a pleural effusion is present fluid should be sent for MC&S, biochemistry and cytology (but cytology is only helpful in 20-30% of cases)
- local anaesthetic thoracoscopy is increasingly used to investigate cytology negative exudative effusions as it has a high diagnostic yield (around 95%)
- if an area of pleural nodularity is seen on CT then an image-guided pleural biopsy may be used

Management

- Symptomatic
- Industrial compensation
- Chemotherapy, Surgery if operable
- Prognosis poor, median survival 12 months

123

Next question

Textbooks

High-yield textbook

Extended textbook

Links

British Thoracic Society

1 2

2018 Investigation and Management of Pleural Mesothelioma

British Thoracic Society

5 0

2023 Pleural disease guidelines

Suggest link

Report broken link

Media

Mesothelioma

Osmosis - YouTube 2 0

Report broken media

Score: **16%**

1 ✗
2 ✗
3 ✗
4 ✗
5 ✗
6 ✗

7	✗
8	✗
9	✗
10	✗
11	✗
12	✓
13	✗
14	✗
15	✗
16	✗
17	✗
18	✗
19	✗
20	✗
21	✗
22	✗
23	✓
24	✗
25	✗
26	✗
27	✗
28	✗
29	✓
30	✗
31	✓
32	✗
33	✗
34	✗
35	✗
36	✓
37	✓
38	✗
39	✗
40	✗
41	✓
42	✗

43 ✗
44 ✗
45 ✗
46 ✗
47 ✗
48 ✗
49 ✓
50 ✗

All contents of this site are © 2024 Passmedicine Limited

A 62-year-old man was admitted to the hospital with a productive cough. Chest x-ray showed right basal pneumonia. He responded well to intravenous antibiotics and was discharged after being successfully weaned off oxygen.

What, if any, follow-up should this man receive?

- CT thorax in 6 weeks to exclude malignancy
- No follow-up required
- Repeat chest x-ray in 6 weeks
- Repeat chest x-ray in 6 weeks and routine respiratory clinic follow up
- Respiratory clinic follow up routinely

Submit answer

Reference ranges

Score: **0%**

1 -
2 -
3 -
4 -
5 -
6 -
7 -
8 -
9 -
10 -

11	-
12	-
13	-
14	-
15	-
16	-
17	-
18	-
19	-
20	-
21	-
22	-
23	-
24	-
25	-
26	-
27	-
28	-
29	-
30	-
31	-
32	-
33	-
34	-
35	-
36	-
37	-
38	-
39	-
40	-
41	-
42	-
43	-
44	-
45	-
46	-
47	-

All contents of this site are © 2024 Passmedicine Limited

Back to top

A 62-year-old man was admitted to the hospital with a productive cough. Chest x-ray showed right basal pneumonia. He responded well to intravenous antibiotics and was discharged after being successfully weaned off oxygen.

What, if any, follow-up should this man receive?

CT thorax in 6 weeks to exclude malignancy	1%
No follow-up required	6%
Repeat chest x-ray in 6 weeks	71%
Repeat chest x-ray in 6 weeks and routine respiratory clinic follow up	21%
Respiratory clinic follow up routinely	1%

All cases of pneumonia should have a repeat chest X-ray at 6 weeks after clinical resolution

Important for me Less important

Repeat chest x-ray in 6 weeks: the British Thoracic Society recommends repeating a chest x-ray for patients with confirmed pneumonia 6-12 weeks after clinical resolution. This is to exclude malignancy which can be obscured by active consolidation.

CT thorax in 6 weeks to exclude malignancy: a CT wound not be indicated in the absence of any other signs or symptoms. There would be no justification for the high level of radiation.

No follow up required: a chest x-ray is required to exclude underlying malignancy.

Repeat chest x-ray in 6 weeks and routine respiratory clinic follow up: there is currently no recommendation to arrange routine clinic follow up for pneumonia patients.

Respiratory clinic follow up routinely: there is currently no recommendation to arrange routine clinic follow-up for pneumonia patients.

Discuss (1) Improve

Pneumonia: assessment and management

Primary care setting

NICE recommends that patients should initially be assessed in primary care using the CRB65 criteria:

Criterion	Marker
C	Confusion (abbreviated mental test score <= 8/10)
R	Respiration rate >= 30/min
B	Blood pressure: systolic <= 90 mmHg and/or diastolic <= 60 mmHg
65	Aged >= 65 years

Patients are stratified for risk of death as follows:
- 0: low risk (less than 1% mortality risk)
  - NICE recommend that treatment at home should be considered (alongside clinical judgement)
- 1 or 2: intermediate risk (1-10% mortality risk)
  - NICE recommend that ' hospital assessment should be considered (particularly for people with a score of 2)'
- 3 or 4: high risk (more than 10% mortality risk)
  - NICE recommend urgent admission to hospital

NICE also mention point-of-care CRP test. This is currently not widely available but they make the following recommendation with reference to the use of antibiotic therapy:
- CRP < 20 mg/L - do not routinely offer antibiotic therapy
- CRP 20 - 100 mg/L - consider a delayed antibiotic prescription
- CRP > 100 mg/L - offer antibiotic therapy

Secondary care setting

Note that in hospital, once blood tests are available the CURB65, rather than the CRB65, can be used. This adds an extra criterion of urea > 7 mmol/L:

Criterion	Marker
C	Confusion (abbreviated mental test score <= 8/10)
U	urea > 7 mmol/L
R	Respiration rate >= 30/min
B	Blood pressure: systolic <= 90 mmHg and/or diastolic <= 60 mmHg
65	Aged >= 65 years

NICE recommend, in conjunction with clinical judgement:

- consider home-based care for patients with a CURB65 score of 0 or 1 - low risk (less than 3% mortality risk)
- consider hospital-based care for patients with a CURB65 score of 2 or more - intermediate risk (3-15% mortality risk)
- consider intensive care assessment for patients with a CURB65 score of 3 or more - high risk (more than 15% mortality risk)

Investigations

- chest x-ray
- in intermediate or high-risk patients NICE recommend blood and sputum cultures, pneumococcal and legionella urinary antigen tests
- CRP monitoring is recommend for admitted patients to help determine response to treatment

Management of low-severity community acquired pneumonia

- amoxicillin is first-line
- if penicillin allergic then use a macrolide or tetracycline
- NICE now recommend a 5 day course of antibiotics for patients with low severity community acquired pneumonia

Management of moderate and high-severity community acquired pneumonia

- dual antibiotic therapy is recommended with amoxicillin and a macrolide
- a 7-10 day course is recommended
- NICE recommend considering a beta-lactamase stable penicillin such as co-amoxiclav, ceftriaxone or piperacillin with tazobactam and a macrolide in high-severity community

acquired pneumonia

Discharge criteria and advice post-discharge

NICE recommend that patients are not routinely discharged if in the past 24 hours they have had 2 or more of the following findings:

- temperature higher than 37.5°C
- respiratory rate 24 breaths per minute or more
- heart rate over 100 beats per minute
- systolic blood pressure 90 mmHg or less
- oxygen saturation under 90% on room air
- abnormal mental status
- inability to eat without assistance.

They also recommend delaying discharge if the temperature is higher than 37.5°C.

NICE recommend that the following information is given to patients with pneumonia in terms of how quickly their symptoms should symptoms should resolve:

Time	**Progress**
1 week	Fever should have resolved
4 weeks	Chest pain and sputum production should have substantially reduced
6 weeks	Cough and breathlessness should have substantially reduced
3 months	Most symptoms should have resolved but fatigue may still be present
6 months	Most people will feel back to normal.

All cases of pneumonia should have a repeat chest X-ray at 6 weeks after clinical resolution to ensure that the consolidation has resolved and there is no underlying secondary abnormalities (e.g. a lung tumour).

+ Q 123

Textbooks

High-yield textbook

Extended textbook

Links

NICE — 16 / 11

2014 Pneumonia in adults: diagnosis and management

Clinical Knowledge Summaries — 14 / 7

Community-acquired pneumonia

MDCalc — 17 / 5

CURB-65 scoring tool

Suggest link

Report broken link

Media

Pneumonia

Osmosis - YouTube — 4 / 0

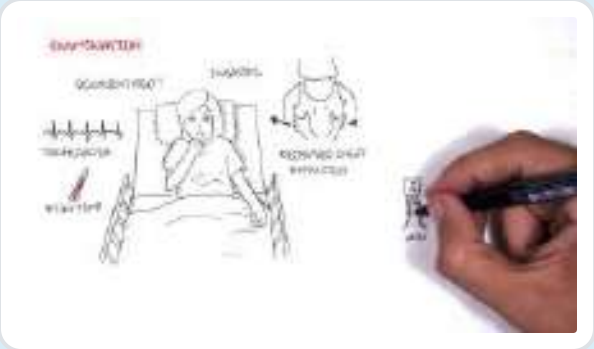

Community Acquired Pneumonia

Armando Hasudungan - YouTube 3 0

Report broken media

Score: **16%**

1	✗
2	✗
3	✗
4	✗
5	✗
6	✗
7	✗
8	✗
9	✗
10	✗
11	✗
12	✓
13	✗
14	✗
15	✗
16	✗
17	✗
18	✗
19	✗
20	✗
21	✗
22	✗
23	✓
24	✗

25	✗
26	✗
27	✗
28	✗
29	✓
30	✗
31	✓
32	✗
33	✗
34	✗
35	✗
36	✓
37	✓
38	✗
39	✗
40	✗
41	✓
42	✗
43	✗
44	✗
45	✗
46	✗
47	✗
48	✗
49	✓
50	✗

All contents of this site are © 2024 Passmedicine Limited

A 72-year-old gentleman presents with a five month history of dry cough and worsening shortness of breath on exertion. He undergoes extensive investigations and is diagnosed with idiopathic pulmonary fibrosis.

Bloods performed as part of the diagnostic work up show:

Hb	141 g/l
Platelets	255 * 10^9/l
WBC	5.2 * 10^9/l
ESR	32 mm/h

Na^+	139 mmol/l
K^+	3.6 mmol/l
Urea	4.7 mmol/l
Creatinine	92 µmol/l
CRP	15 mg/L

His lung function tests show a forced vital capacity (FVC) of 65% of predicted.

On examination the patient has obvious finger clubbing and fine end-inspiratory crepitations on auscultation of the chest.

Of note in his past medical history he smoked for ten years between the ages of 20 and 30.

He is understandably very distressed by the diagnosis and asks about potential therapies. He is enrolled on a pulmonary rehabilitation programme but is keen to try a pharmacological therapy. Which drug should be considered in this patient?

- Azathioprine
- Prednisolone
- Bosentan

Pirfenidone

Sildenafil

Submit answer

Reference ranges

Score: **0%**

1 -
2 -
3 -
4 -
5 -
6 -
7 -
8 -
9 -
10 -
11 -
12 -
13 -
14 -
15 -
16 -
17 -
18 -
19 -
20 -
21 -
22 -
23 -
24 -
25 -
26 -

27	-
28	-
29	-
30	-
31	-
32	-
33	-
34	-
35	-
36	-
37	-
38	-
39	-
40	-
41	-
42	-
43	-
44	-
45	-
46	-
47	-
48	-

All contents of this site are © 2024 Passmedicine Limited

A 72-year-old gentleman presents with a five month history of dry cough and worsening shortness of breath on exertion. He undergoes extensive investigations and is diagnosed with idiopathic pulmonary fibrosis.

Bloods performed as part of the diagnostic work up show:

Hb	141 g/l
Platelets	255 * 10^9/l
WBC	5.2 * 10^9/l
ESR	32 mm/h

Na^+	139 mmol/l
K^+	3.6 mmol/l
Urea	4.7 mmol/l
Creatinine	92 µmol/l
CRP	15 mg/L

His lung function tests show a forced vital capacity (FVC) of 65% of predicted.

On examination the patient has obvious finger clubbing and fine end-inspiratory crepitations on auscultation of the chest.

Of note in his past medical history he smoked for ten years between the ages of 20 and 30.

He is understandably very distressed by the diagnosis and asks about potential therapies. He is enrolled on a pulmonary rehabilitation programme but is keen to try a pharmacological therapy. Which drug should be considered in this patient?

- Azathioprine 1%
- Prednisolone 3%
- Bosentan 4%

Pirfenidone	90%
Sildenafil	1%

Idiopathic pulmonary fibrosis (IPF) is a chronic progressive disease with a dismal prognosis. In the UK the median survival is three years from diagnosis although a sub -group (approximately 20%) survive over five years. The disease rarely presents below the age of 45 and presenting symptoms include; breathlessness on exertion, persistent cough and fatigue.

Management of IPF has changed dramatically over the last decade. Previous small trials had shown small benefits of using a combination of corticosteroids with azathioprine and this combination remained the only pharmacological therapy for many years. Later larger trials demonstrated that this treatment regime confers no benefit and may actually cause harm thus the National Institute for Clinical Excellence (NICE) states that immunosuppressant therapies such as azathioprine, prednisolone and mycophenolate mofetil should not be used in IPF.

The only pharmacological therapy that has shown any benefit in IPF is pirfenidone, an immunosuppressant that has been shown to have anti-inflammatory and antifibrotic effects. The mechanism of action of pirfenidone is not completely understood but is thought that it suppresses fibroblast proliferation thus reducing the production of fibrosis-associated proteins and cytokines.

The only other therapeutic option for patients is lung transplantation and NICE recommends that any patients wishing to explore this option should be referred providing they have no absolute contraindications. Unfortunately, the speed of progression of the disease and availability of suitable organs means that this treatment modality is only used in a very small minority of patients.

It is clear from these guidelines that pirfenidone is the correct answer. Bosentan is an endothelin receptor antagonist used in the treatment of primary pulmonary hypertension. Sildenafil is a phosphodiesterase inhibitor which has vasodilating effects and is best known for its use in the treatment of erectile dysfunction. It was initially devised as a therapy for primary pulmonary hypertension and it has beneficial effects in this disease.

NICE technology appraisal on pirfenidone can be found here:
http://www.nice.org.uk/guidance/ta282/resources/guidance-pirfenidone-for-treating-idiopathic-pulmonary-fibrosis-pdf

NICE guidelines on IPF can be found here:
https://www.nice.org.uk/guidance/cg163/resources/guidance-idiopathic-pulmonary-fibrosis-pdf

Discuss (1) Improve

Next question

Idiopathic pulmonary fibrosis

Idiopathic pulmonary fibrosis (IPF, previously termed cryptogenic fibrosing alveolitis) is a chronic lung condition characterised by progressive fibrosis of the interstitium of the lungs. Whilst there are many causes of lung fibrosis (e.g. medications, connective tissue disease, asbestos) the term IPF is reserved when no underlying cause exists.

IPF is typically seen in patients aged 50-70 years and is twice as common in men.

Features

- progressive exertional dyspnoea
- bibasal fine end-inspiratory crepitations on auscultation
- dry cough
- clubbing

Diagnosis

- spirometry: classically a restrictive picture (FEV1 normal/decreased, FVC decreased, FEV1/FVC increased)
- impaired gas exchange: reduced transfer factor (TLCO)
- imaging: bilateral interstitial shadowing (typically small, irregular, peripheral opacities - 'ground-glass' - later progressing to 'honeycombing') may be seen on a chest x-ray but high-resolution CT scanning is the investigation of choice and required to make a diagnosis of IPF
- ANA positive in 30%, rheumatoid factor positive in 10% but this does not necessarily mean that the fibrosis is secondary to a connective tissue disease. Titres are usually low

Management

- pulmonary rehabilitation
- very few medications have been shown to give any benefit in IPF. There is some evidence that pirfenidone (an antifibrotic agent) may be useful in selected patients (see NICE guidelines)
- many patients will require supplementary oxygen and eventually a lung transplant

Prognosis

- poor, average life expectancy is around 3-4 years

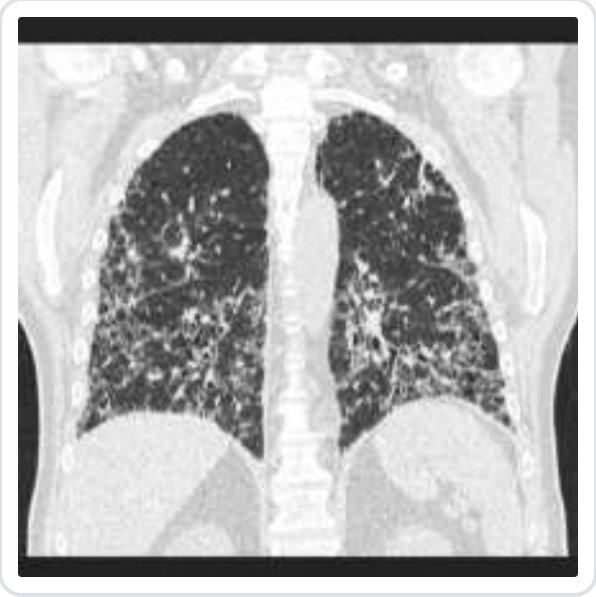

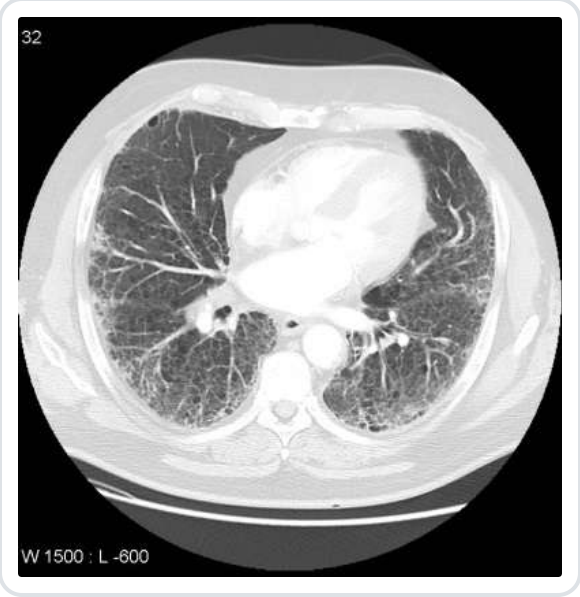

123

Next question

Textbooks

High-yield textbook

Extended textbook

Links

Royal College of Physicians 13 10

Update in diagnosis and management of interstitial lung disease

NICE 11 6

2013 Idiopathic pulmonary fibrosis guidelines

Suggest link

Report broken link

Media

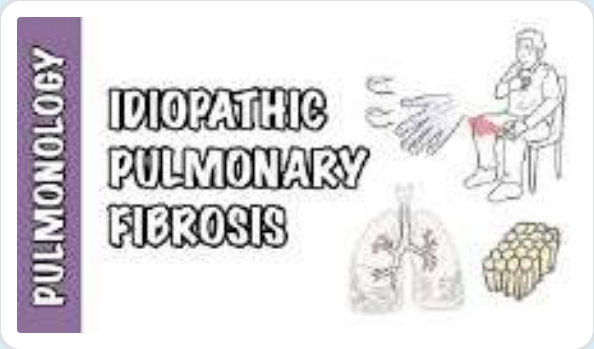

Idiopathic pulmonary fibrosis

Armando Hasudungan - YouTube 6 0

Interstitial Lung Disease (ILD) - Classification, pathophysiology, signs and symptoms

Armando Hasudungan - YouTube 5 0

Idiopathic pulmonary fibrosis

Osmosis - YouTube 4 0

Report broken media

Score: **16%**

1 ✕
2 ✕
3 ✕
4 ✕
5 ✕
6 ✕
7 ✕
8 ✕
9 ✕
10 ✕

11	✗
12	✓
13	✗
14	✗
15	✗
16	✗
17	✗
18	✗
19	✗
20	✗
21	✗
22	✗
23	✓
24	✗
25	✗
26	✗
27	✗
28	✗
29	✓
30	✗
31	✓
32	✗
33	✗
34	✗
35	✗
36	✓
37	✓
38	✗
39	✗
40	✗
41	✓
42	✗
43	✗
44	✗
45	✗
46	✗

47	✗
48	✗
49	✓
50	✗

All contents of this site are © 2024 Passmedicine Limited
Back to top

A 78-year-old man with Chronic Obstructive Pulmonary Disease is reviewed in Respiratory clinic. He is complaining of decreased exercise tolerance with shortness of breath at rest. He suffers from exacerbations infrequently and does not have a productive cough. Oxygen saturations on air are 90%. His FEV 1 is 27% predicted.

He has a past medical history of osteoarthritis, ischaemic heart disease and chronic kidney disease.

His medications include Paracetamol, Ramipril, Aspirin, inhaled long acting beta agonist with inhaled corticosteroid and inhaled long acting muscarinc agonist. He has previously undergone pulmonary rehabilitation. He does not smoke

Investigations:

Hb	19.8 g/dL
WCC	6.0 *10^9/l
Platelets	180 *10^9/l
MCV	88fL

Echocardiogram: No abnormality seen.

CT Chest: Widespread mild bullous disease throughout upper and lower lung fields.

Arterial blood gas on air:

	Current	**Four weeks previously**
pH	7.40	7.37
pCO2	5.1 kPa	4.7 kPa
pO2	7.5 kPa	7.4 kPa
HCO3	25 mmol/l	24 mmol/l

What is the most appropriate treatment?

- Lung volume reduction surgery
- Mucolytic therapy
- Long term antibiotic prophylaxis
- Oral corticosteroids
- Long term oxygen therapy

Submit answer

Reference ranges

Score: **0%**

1	-
2	-
3	-
4	-
5	-
6	-
7	-
8	-
9	-
10	-
11	-
12	-
13	-
14	-
15	-
16	-
17	-
18	-
19	-
20	-

21 -
22 -
23 -
24 -
25 -
26 -
27 -
28 -
29 -
30 -
31 -
32 -
33 -
34 -
35 -
36 -
37 -
38 -
39 -
40 -
41 -
42 -
43 -
44 -
45 -
46 -
47 -
48 -
49 -

All contents of this site are © 2024 Passmedicine Limited

A 78-year-old man with Chronic Obstructive Pulmonary Disease is reviewed in Respiratory clinic. He is complaining of decreased exercise tolerance with shortness of breath at rest. He suffers from exacerbations infrequently and does not have a productive cough. Oxygen saturations on air are 90%. His FEV 1 is 27% predicted.

He has a past medical history of osteoarthritis, ischaemic heart disease and chronic kidney disease.

His medications include Paracetamol, Ramipril, Aspirin, inhaled long acting beta agonist with inhaled corticosteroid and inhaled long acting muscarinc agonist. He has previously undergone pulmonary rehabilitation. He does not smoke

Investigations:

Hb	19.8 g/dL
WCC	6.0 *10^9/l
Platelets	180 *10^9/l
MCV	88fL

Echocardiogram: No abnormality seen.

CT Chest: Widespread mild bullous disease throughout upper and lower lung fields.

Arterial blood gas on air:

	Current	**Four weeks previously**
pH	7.40	7.37
pCO2	5.1 kPa	4.7 kPa
pO2	7.5 kPa	7.4 kPa
HCO3	25 mmol/l	24 mmol/l

What is the most appropriate treatment?

- Lung volume reduction surgery 16%
- Mucolytic therapy 2%
- Long term antibiotic prophylaxis 5%
- Oral corticosteroids 4%
- Long term oxygen therapy 73%

Lung volume reduction surgery. This is a possibility for patients with optimal medical therapy with symptomatic dyspnoea and severe COPD. It has improved mortality in patients with upper lobe predominant emphysema. This patient also has significant co-morbidities that make this option incorrect.

Mucolytic therapy. This patient is not suffering from a chronic productive cough, therefore, this is less likely to benefit the patient. It would be advisible to trial in patients for 3-4 weeks with a productive cough e.g. Carbocisteine.

Long term antibiotic prophylaxis. Minimal exacerbations in this patient and poor overall data make this option incorrect.

Oral Corticosteroids. This patient is not suffering from an exacerbation. Maintenance corticosteroids may be required in advanced disease if unable to wean off after an exacerbation.

Long term Oxygen therapy. This patient is suffering from severe COPD (FEV1 <30%). He has polycythaemia, it is likely to be secondary to COPD as he has normal platelets and MCV. LTOT is indicated in COPD if the pO2 is <7.3 on two separate ABGs 3 weeks apart. It can be offered to patients with a pO2 7.3-8 kPa with secondary polycythaemia, peripheral oedema, nocturnal hypoxaemia or pulmonary hypertension. He will need to be monitored on oxygen for hypercapnia and acidosis.

Discuss (5) Improve

Next question

COPD: long-term oxygen therapy

The 2018 NICE guidelines on COPD clearly define which patients should be assessed for and offered long-term oxygen therapy (LTOT). Patients who receive LTOT should breathe

supplementary oxygen for at least 15 hours a day. Oxygen concentrators are used to provide a fixed supply for LTOT.

Assess patients if any of the following:

- very severe airflow obstruction (FEV1 < 30% predicted). Assessment should be 'considered' for patients with severe airflow obstruction (FEV1 30-49% predicted)
- cyanosis
- polycythaemia
- peripheral oedema
- raised jugular venous pressure
- oxygen saturations less than or equal to 92% on room air

Assessment is done by measuring arterial blood gases on 2 occasions at least 3 weeks apart in patients with stable COPD on optimal management.

Offer LTOT to patients with a pO2 of < 7.3 kPa or to those with a pO2 of 7.3 - 8 kPa and one of the following:

- secondary polycythaemia
- peripheral oedema
- pulmonary hypertension

In terms of smoking, NICE advise the following:

- do not offer LTOT to people who continue to smoke despite being offered smoking cessation advice and treatment, and referral to specialist stop smoking services.

NICE suggest that a structured risk assessment is carried out before offering LTOT, including:

- the risks of falls from tripping over the equipment
- the risks of burns and fires, and the increased risk of these for people who live in homes where someone smokes (including e-cigarettes)

123

Next question

Textbooks

High-yield textbook

Extended textbook

Links

NICE

2018 COPD guidelines

17 6

Suggest link

Report broken link

Score: **16%**

1	✗
2	✗
3	✗
4	✗
5	✗
6	✗
7	✗
8	✗
9	✗
10	✗
11	✗
12	✓
13	✗
14	✗
15	✗
16	✗
17	✗
18	✗
19	✗

20	✗
21	✗
22	✗
23	✓
24	✗
25	✗
26	✗
27	✗
28	✗
29	✓
30	✗
31	✓
32	✗
33	✗
34	✗
35	✗
36	✓
37	✓
38	✗
39	✗
40	✗
41	✓
42	✗
43	✗
44	✗
45	✗
46	✗
47	✗
48	✗
49	✓
50	✗

All contents of this site are © 2024 Passmedicine Limited

A 54-year-old woman is reviewed in gastroenterology clinic following the insertion of a transjugular intrahepatic portosystemic shunt (TIPS). She is known to have alcohol related hepatic cirrhosis with portal hypertension and was found to have large varices on endoscopy and therefore underwent the insertion of a TIPS two months ago. However, she has started to feel breathless in the last month and found that her exercise tolerance has been reduced. She has otherwise felt well and denies any pain, confusion or nausea. On examination, there is evidence of chronic liver disease including palmar erythema, Dupuytren's contracture, spider naevi and leukonychia. Her chest is clear on auscultation. There is a loud P2 sound but otherwise, there are no abnormalities on cardiac auscultation. What is the most likely cause of breathlessness?

- Hepatorenal syndrome
- Pulmonary hypertension
- Anaemia
- Pleural effusion
- COPD

Submit answer

Reference ranges

Score: **0%**

1 -
2 -
3 -
4 -
5 -
6 -

7 -
8 -
9 -
10 -
11 -
12 -
13 -
14 -
15 -
16 -
17 -
18 -
19 -
20 -
21 -
22 -
23 -
24 -
25 -
26 -
27 -
28 -
29 -
30 -
31 -
32 -
33 -
34 -
35 -
36 -
37 -
38 -
39 -
40 -
41 -
42 -
43 -
44 -
45 -
46 -

47	-
48	-
49	-
50	-

All contents of this site are © 2024 Passmedicine Limited

A 54-year-old woman is reviewed in gastroenterology clinic following the insertion of a transjugular intrahepatic portosystemic shunt (TIPS). She is known to have alcohol related hepatic cirrhosis with portal hypertension and was found to have large varices on endoscopy and therefore underwent the insertion of a TIPS two months ago. However, she has started to feel breathless in the last month and found that her exercise tolerance has been reduced. She has otherwise felt well and denies any pain, confusion or nausea. On examination, there is evidence of chronic liver disease including palmar erythema, Dupuytren's contracture, spider naevi and leukonychia. Her chest is clear on auscultation. There is a loud P2 sound but otherwise, there are no abnormalities on cardiac auscultation. What is the most likely cause of breathlessness?

Hepatorenal syndrome	7%
Pulmonary hypertension	84%
Anaemia	3%
Pleural effusion	5%
COPD	1%

The correct answer is pulmonary hypertension. This is a known complication of TIPS as the procedure causes an increased cardiac preload by diverting blood past the cirrhotic liver, thereby significantly reducing peripheral resistance. This can lead to pulmonary hypertension which can explain the patient's breathlessness. The absence of respiratory findings makes pleural effusion and COPD unlikely. With effusions, dullness and reduced air entry would be expected and COPD could occur with cirrhosis in anti-trypsin deficiency, but the absence of wheeze makes this very unlikely. Anaemia can occur, but is unlikely to be related to TIPS.

Discuss (7) Improve

Next question

Pulmonary hypertension: causes and classification

Pulmonary hypertension may be defined as a sustained elevation in mean pulmonary arterial pressure of greater than 20 mmHg at rest. It has recently been reclassified by the WHO:

Group 1: Pulmonary arterial hypertension (PAH)
- idiopathic*
- familial
- associated conditions: collagen vascular disease, congenital heart disease with systemic to pulmonary shunts, HIV**, drugs and toxins, sickle cell disease
- persistent pulmonary hypertension of the newborn

Group 2: Pulmonary hypertension with left heart disease
- left-sided atrial, ventricular or valvular disease such as left ventricular systolic and diastolic dysfunction, mitral stenosis and mitral regurgitation

Group 3: Pulmonary hypertension secondary to lung disease/hypoxia
- COPD
- interstitial lung disease
- sleep apnoea
- high altitude

Group 4: Pulmonary hypertension due to thromboembolic disease

Group 5: Miscellaneous conditions
- lymphangiomatosis e.g. secondary to carcinomatosis or sarcoidosis

*previously termed primary pulmonary hypertension
**the mechanism by which HIV infection produces pulmonary hypertension remains unknown

AI + Q 123

Next question ›

Textbooks

High-yield textbook

Extended textbook

Links

Medcomic 2 1

Pulmonary hypertension

Suggest link Report broken link

Media

Pulmonary hypertension

Osmosis - YouTube 5 0

Report broken media

Score: **16%**

1 ✕
2 ✕
3 ✕
4 ✕
5 ✕
6 ✕
7 ✕
8 ✕
9 ✕
10 ✕
11 ✕

12 ✓
13 ✗
14 ✗
15 ✗
16 ✗
17 ✗
18 ✗
19 ✗
20 ✗
21 ✗
22 ✗
23 ✓
24 ✗
25 ✗
26 ✗
27 ✗
28 ✗
29 ✓
30 ✗
31 ✓
32 ✗
33 ✗
34 ✗
35 ✗
36 ✓
37 ✓
38 ✗
39 ✗
40 ✗
41 ✓
42 ✗
43 ✗
44 ✗
45 ✗
46 ✗
47 ✗

48	✗
49	✓
50	✗

All contents of this site are © 2024 Passmedicine Limited

A 45-year-old man is referred to the respiratory department due to increasing shortness-of-breath and frequent chest infections. He is a smoker (20 cigarettes/day). When he was a child he used a salbutamol inhaler but stopped this around the age of 6-7 years. He also had whooping cough as a child. Pulmonary function tests performed by his GP show the following:

FEV1	3.6 L (predicted 3.8 L)
FVC	4.3 L (predicted 4.5 L)
FEV1/FVC	84% (normal > 75%)

On auscultation of his chest scattered crepitations are noted. His oxygen saturations are 96% on room air.

A CT chest is requested:

© Image used on license from Radiopaedia

What is the most likely diagnosis?

- Lung cancer
- Previous *Bordetella pertussis* infection
- Emphysema

Kartagener's syndrome ×

Cystic fibrosis ×

Submit answer

Reference ranges

Score: **16%**

1	✗
2	✗
3	✗
4	✗
5	✗
6	✗
7	✗
8	✗
9	✗
10	✗
11	✗
12	✓
13	✗
14	✗
15	✗
16	✗
17	✗
18	✗
19	✗
20	✗
21	✗
22	✗
23	✓

24	✗
25	✗
26	✗
27	✗
28	✗
29	✓
30	✗
31	✓
32	✗
33	✗
34	✗
35	✗
36	✓
37	✓
38	✗
39	✗
40	✗
41	✓
42	✗
43	✗
44	✗
45	✗
46	✗
47	✗
48	✗
49	✓
50	✗
51	-

All contents of this site are © 2024 Passmedicine Limited

Back to top

A 45-year-old man is referred to the respiratory department due to increasing shortness-of-breath and frequent chest infections. He is a smoker (20 cigarettes/day). When he was a child he used a salbutamol inhaler but stopped this around the age of 6-7 years. He also had whooping cough as a child. Pulmonary function tests performed by his GP show the following:

FEV1	3.6 L (predicted 3.8 L)
FVC	4.3 L (predicted 4.5 L)
FEV1/FVC	84% (normal > 75%)

On auscultation of his chest scattered crepitations are noted. His oxygen saturations are 96% on room air.

A CT chest is requested:

© Image used on license from Radiopaedia

What is the most likely diagnosis?

- Lung cancer 1%
- Previous *Bordetella pertussis* infection 32%
- Emphysema 14%

Kartagener's syndrome 26%

Cystic fibrosis 28%

The CT scan shows signet-rings and tram-tracks consistent with bronchiectasis. This, in combination with normal pulmonary function tests makes a diagnosis of emphysema less likely.

We can also exclude cystic fibrosis (CF). Some patients with CF now survive to 45 years but it would be very unusual to reach this age without significant respiratory problems in the past. An exam question would never include such a bizarre history for CF.

There is also no evidence of situs inversus excluding Kartagener's syndrome.

The bronchiectasis associated with lung cancer is confined to the area distal to the tumour. It would therefore not explain the bilateral symptoms.

The most likely diagnosis is therefore *Bordetella pertussis* infection, a known cause of bronchiectasis.

Discuss (6) Improve

Next question

Bronchiectasis: causes

Bronchiectasis describes a permanent dilatation of the airways secondary to chronic infection or inflammation. There are a wide variety of causes are listed below:

Causes

- post-infective: tuberculosis, measles, pertussis, pneumonia
- cystic fibrosis
- bronchial obstruction e.g. lung cancer/foreign body
- immune deficiency: selective IgA, hypogammaglobulinaemia
- allergic bronchopulmonary aspergillosis (ABPA)
- ciliary dyskinetic syndromes: Kartagener's syndrome, Young's syndrome
- yellow nail syndrome

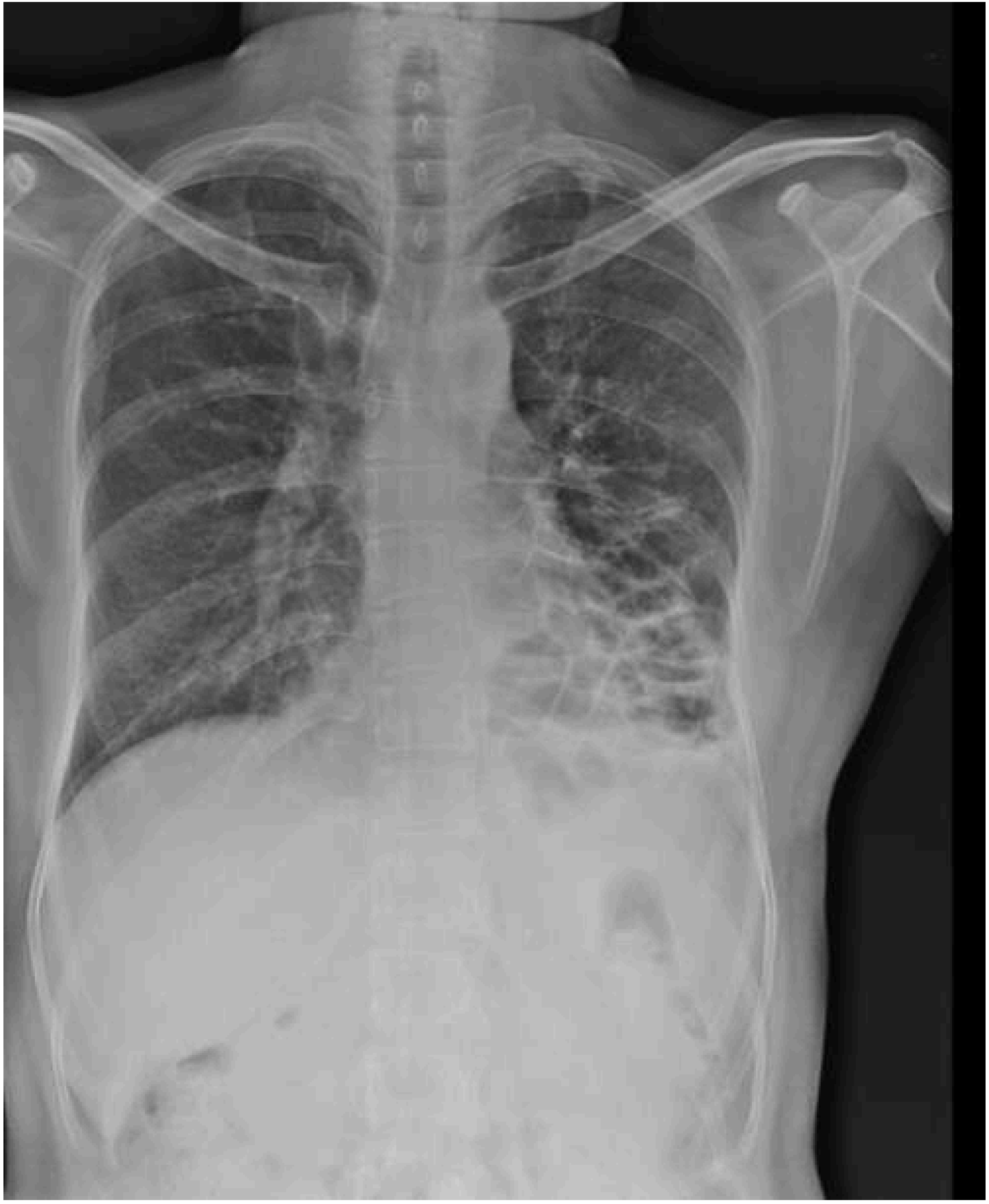

© Image used on license from Radiopaedia

Chest x-ray showing tramlines, most prominent in the left lower zone

© Image used on license from Radiopaedia

CT chest showing widespread tram-track and signet ring signs

123

Next question

Textbooks

High-yield textbook

Extended textbook

Links

British Thoracic Society

2 1

2018 Bronchiectasis guidelines

Suggest link

Report broken link

Media

Bronchiectasis - causes, pathophysiology, signs and symptoms, investigations and treatment

Armando Hasudungan - YouTube

3 0

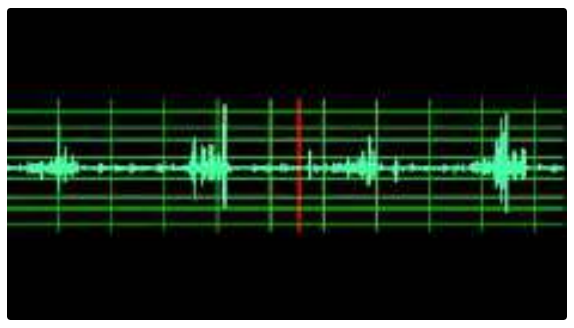

[Bronchiectasis crackles - REQUIRES HEADPHONES]

Thinklabs - YouTube

👍 3 👎 1

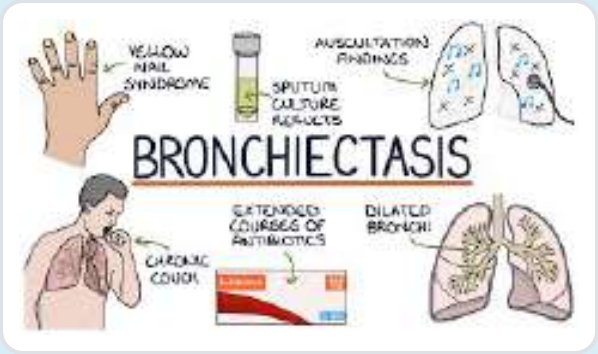

[Bronchiectasis]

Zero To Finals - YouTube

👍 0 👎 2

Report broken media

Score: **17.3%**

1	✗
2	✗
3	✗
4	✗
5	✗
6	✗
7	✗
8	✗
9	✗
10	✗
11	✗
12	✓
13	✗
14	✗
15	✗
16	✗
17	✗
18	✗
19	✗
20	✗
21	✗

22	✗
23	✓
24	✗
25	✗
26	✗
27	✗
28	✗
29	✓
30	✗
31	✓
32	✗
33	✗
34	✗
35	✗
36	✓
37	✓
38	✗
39	✗
40	✗
41	✓
42	✗
43	✗
44	✗
45	✗
46	✗
47	✗
48	✗
49	✓
50	✗
51	✗
52	✓
53	✗
54	✗
55	✓
56	✗
57	✗

58 ✓
59 ✗
60 ✓
61 ✗
62 ✗
63 ✗
64 ✗
65 ✗
66 ✗
67 ✗
68 ✗
69 ✗
70 ✗
71 ✗
72 ✗
73 ✗
74 ✗
75 ✓
76 ✗
77 ✗
78 ✗
79 ✓
80 ✗
81 ✗
82 ✓
83 ✗
84 ✗
85 ✗
86 ✗
87 ✗
88 ✗
89 ✗
90 ✗
91 ✗
92 ✗
93 ✓

94	✗
95	✓
96	✗
97	✗
98	✗
99	✗
100	✗
101	✗
102	✗
103	✓
104	✗
105	✗
106	✓
107	✗
108	✗
109	✗
110	✗
111	-

All contents of this site are © 2024 Passmedicine Limited

A 52-year-old woman is referred to the Acute Medical Unit after developing progressive dyspnoea over the past 4 weeks. She has no significant past medical history of note.

On examination her respiratory rate is 18/min, pulse 84/min, blood pressure 102/64 mmHg and oxygen saturations 96% on room air. Temperature is 37.1ºC.

A chest x-ray is performed:

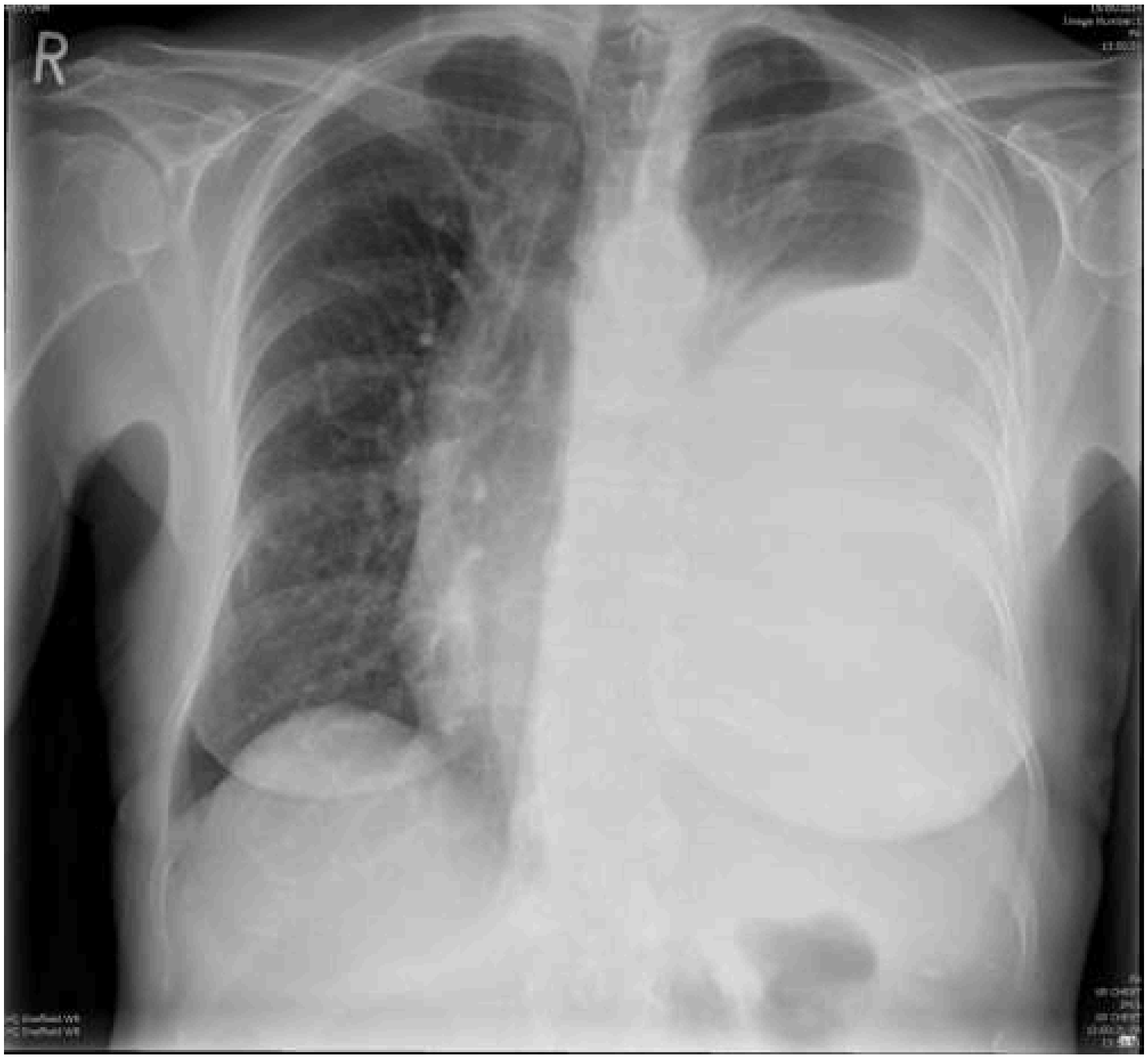

© Image used on license from Radiopaedia

What is the most appropriate initial management?

- Insert a 26F chest drain after performing a thoracostomy
- Arrange a high resolution CT chest
- Prescribe intravenous antibiotics

- ◯ Insert a 18F chest drain using the Seldinger technique ×
- ◯ Pleural aspiration ×

Submit answer

Reference ranges

Score: **16%**

1	✗
2	✗
3	✗
4	✗
5	✗
6	✗
7	✗
8	✗
9	✗
10	✗
11	✗
12	✓
13	✗
14	✗
15	✗
16	✗
17	✗
18	✗
19	✗
20	✗
21	✗
22	✗
23	✓

24	✗
25	✗
26	✗
27	✗
28	✗
29	✓
30	✗
31	✓
32	✗
33	✗
34	✗
35	✗
36	✓
37	✓
38	✗
39	✗
40	✗
41	✓
42	✗
43	✗
44	✗
45	✗
46	✗
47	✗
48	✗
49	✓
50	✗
51	-
52	-

All contents of this site are © 2024 Passmedicine Limited
Back to top

PassMedicine

A 52-year-old woman is referred to the Acute Medical Unit after developing progressive dyspnoea over the past 4 weeks. She has no significant past medical history of note.

On examination her respiratory rate is 18/min, pulse 84/min, blood pressure 102/64 mmHg and oxygen saturations 96% on room air. Temperature is 37.1ºC.

A chest x-ray is performed:

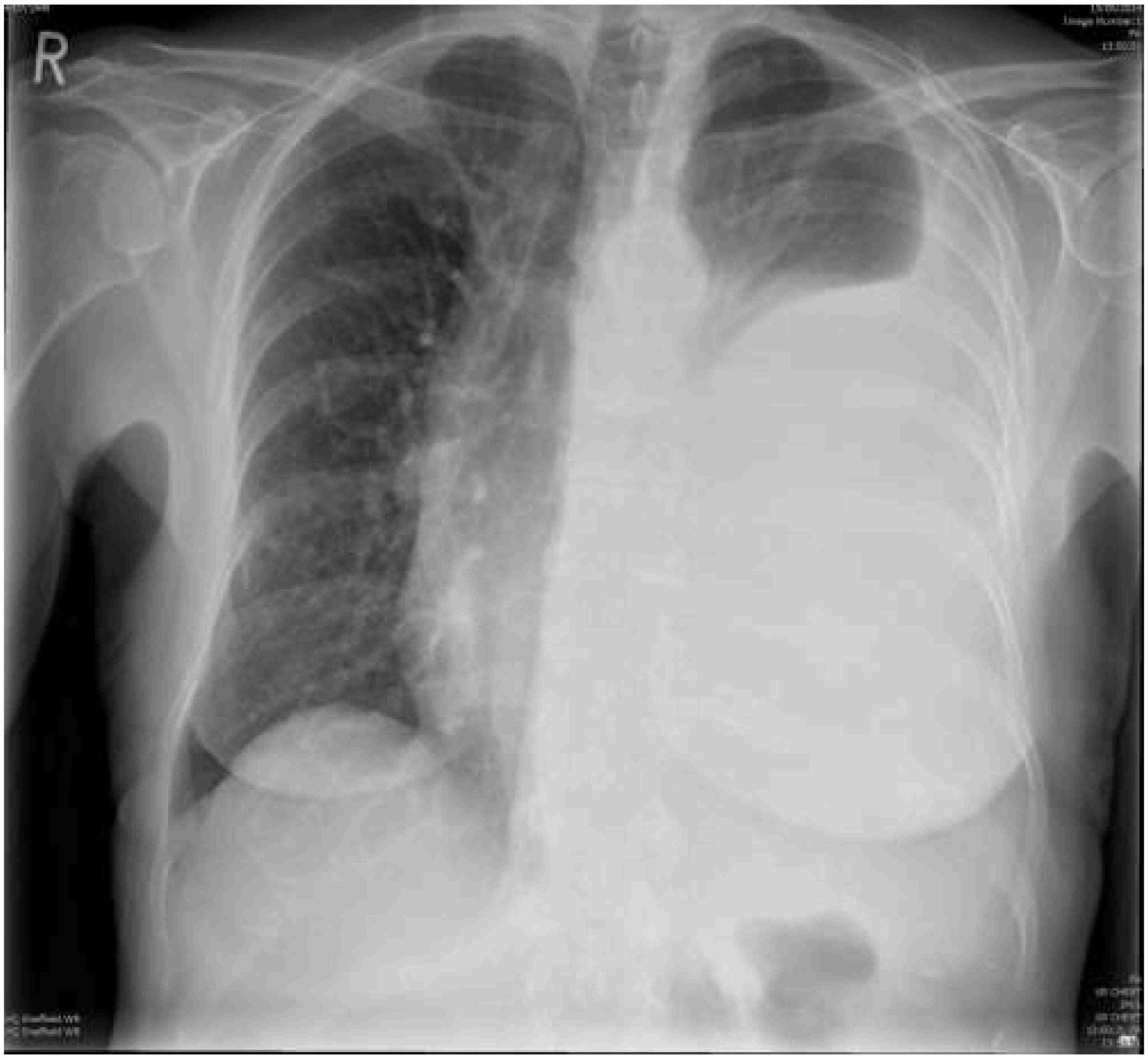

© Image used on license from Radiopaedia

What is the most appropriate initial management?

- Insert a 26F chest drain after performing a thoracostomy — 9%
- Arrange a high resolution CT chest — 13%
- Prescribe intravenous antibiotics — 1%

Insert a 18F chest drain using the Seldinger technique 38%

Pleural aspiration 40%

The first step in the management of this patient is pleural aspiration, preferably under ultrasound guidance. This will help guide further management and determine the aetiology of the effusion. There is no need for immediate chest drain insertion as she is stable.

The x-ray shows a large left-sided pleural effusion. The meniscus is well demonstrated on the superolateral aspect indicating fluid in the pleural space.

Discuss (11) Improve

Next question

Pleural effusion: investigation and management

The British Thoracic Society (BTS) produced guidelines in 2010 covering the investigation of patients with a pleural effusion.

Imaging

- posterioranterior (PA) chest x-rays should be performed in all patients
- ultrasound is recommended: it increases the likelihood of successful pleural aspiration and is sensitive for detecting pleural fluid septations
- contrast CT is now increasingly performed to investigate the underlying cause, particularly for exudative effusions

Pleural aspiration

- as above, ultrasound is recommended to reduce the complication rate
- a 21G needle and 50ml syringe should be used
- fluid should be sent for pH, protein, lactate dehydrogenase (LDH), cytology and microbiology

Light's criteria was developed in 1972 to help distinguish between a transudate and an exudate. The BTS recommend using the criteria for borderline cases:

- exudates have a protein level of >30 g/L, transudates have a protein level of <30 g/L
- if the protein level is between 25-35 g/L, Light's criteria should be applied. An exudate is likely if at least one of the following criteria are met:
    - pleural fluid protein divided by serum protein >0.5
    - pleural fluid LDH divided by serum LDH >0.6
    - pleural fluid LDH more than two-thirds the upper limits of normal serum LDH

Other characteristic pleural fluid findings:

- low glucose: rheumatoid arthritis, tuberculosis
- raised amylase: pancreatitis, oesophageal perforation
- heavy blood staining: mesothelioma, pulmonary embolism, tuberculosis

Pleural infection

All patients with a pleural effusion in association with sepsis or a pneumonic illness require diagnostic pleural fluid sampling

- if the fluid is purulent or turbid/cloudy a chest tube should be placed to allow drainage
- if the fluid is clear but the **pH is less than 7.2 in patients with suspected pleural infection a chest tube should be placed**

Management of recurrent pleural effusion

Options for managing patients with recurrent pleural effusions include:

- recurrent aspiration
- pleurodesis
- indwelling pleural catheter
- drug management to alleviate symptoms e.g. opioids to relieve dyspnoea

AI + Q 123

Next question >

Textbooks

High-yield textbook

Extended textbook

Links

British Thoracic Society

17 14

2023 Pleural disease guidelines

Royal College of Physicians

13 7

2012 Pleural infection review

Suggest link

Report broken link

Media

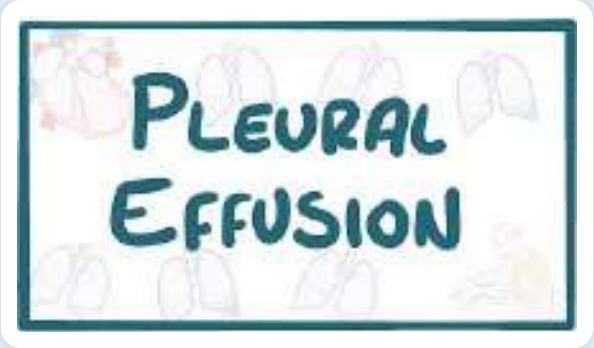

Pleural effusion

Osmosis - YouTube 8 1

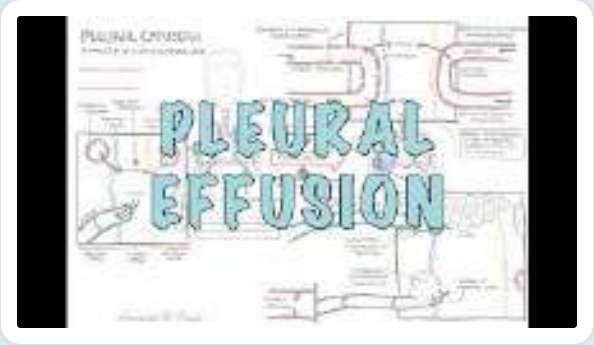

Pleural effusion

Armando Hasudungan - YouTube 6 1

Report broken media

Score: **17.3%**

1	✗
2	✗
3	✗
4	✗
5	✗
6	✗
7	✗
8	✗
9	✗
10	✗
11	✗
12	✓
13	✗
14	✗
15	✗
16	✗
17	✗
18	✗
19	✗
20	✗
21	✗
22	✗
23	✓
24	✗
25	✗
26	✗
27	✗
28	✗
29	✓
30	✗
31	✓
32	✗
33	✗

34	✗
35	✗
36	✓
37	✓
38	✗
39	✗
40	✗
41	✓
42	✗
43	✗
44	✗
45	✗
46	✗
47	✗
48	✗
49	✓
50	✗
51	✗
52	✓
53	✗
54	✗
55	✓
56	✗
57	✗
58	✓
59	✗
60	✓
61	✗
62	✗
63	✗
64	✗
65	✗
66	✗
67	✗
68	✗
69	✗

70	✗
71	✗
72	✗
73	✗
74	✗
75	✓
76	✗
77	✗
78	✗
79	✓
80	✗
81	✗
82	✓
83	✗
84	✗
85	✗
86	✗
87	✗
88	✗
89	✗
90	✗
91	✗
92	✗
93	✓
94	✗
95	✓
96	✗
97	✗
98	✗
99	✗
100	✗
101	✗
102	✗
103	✓
104	✗
105	✗

106	✓
107	✗
108	✗
109	✗
110	✗
111	-

All contents of this site are © 2024 Passmedicine Limited

A 60-year-old man is diagnosed with idiopathic pulmonary fibrosis after presenting with an 18-month history of progressive dyspnoea. His latest FVC is 60% of predicted. What is the average life expectancy for such a patient from the time of diagnosis?

- 3-6 months
- 6-12 months
- 12-18 months
- 3-4 years
- 8-12 years

Submit answer

Reference ranges

Score: **16%**

1	×
2	×
3	×
4	×
5	×
6	×
7	×
8	×
9	×
10	×

11	✗
12	✓
13	✗
14	✗
15	✗
16	✗
17	✗
18	✗
19	✗
20	✗
21	✗
22	✗
23	✓
24	✗
25	✗
26	✗
27	✗
28	✗
29	✓
30	✗
31	✓
32	✗
33	✗
34	✗
35	✗
36	✓
37	✓
38	✗
39	✗
40	✗
41	✓
42	✗
43	✗
44	✗
45	✗
46	✗

47	✗
48	✗
49	✓
50	✗
51	-
52	-
53	-

All contents of this site are © 2024 Passmedicine Limited

Back to top

A 60-year-old man is diagnosed with idiopathic pulmonary fibrosis after presenting with an 18-month history of progressive dyspnoea. His latest FVC is 60% of predicted. What is the average life expectancy for such a patient from the time of diagnosis?

3-6 months	2%
6-12 months	10%
12-18 months	28%
3-4 years	55%
8-12 years	4%

The correct answer in this case is **3-4 years**. Idiopathic pulmonary fibrosis (IPF) is a progressive, irreversible lung disease characterized by fibrosis of the lung parenchyma, leading to worsening dyspnoea and reduced lung function. The prognosis for IPF varies widely, but on average, the median survival from the time of diagnosis is around 3-4 years. In this patient with an FVC of 60% predicted, his life expectancy would also fall within this range.

The option **3-6 months** is incorrect because it represents a significantly shorter life expectancy than what is typically seen in patients with IPF. While some patients may have rapidly progressive disease or other complicating factors that could lead to a shorter survival time, the average life expectancy for someone with IPF is longer than this.

Similarly, the option **6-12 months** is also incorrect as it underestimates the average life expectancy for a patient with IPF. Although some patients may have a more aggressive form of the disease or other comorbidities that contribute to a worse prognosis, most patients can expect to live longer than one year following their diagnosis.

The option **12-18 months** still underestimates the typical life expectancy for someone diagnosed with idiopathic pulmonary fibrosis. While there are cases where individuals may experience rapid progression of their disease or have additional health issues that impact their prognosis, on average, individuals diagnosed with IPF tend to live longer than 18 months.

Lastly, the option **8-12 years** overestimates the average life expectancy for someone with idiopathic pulmonary fibrosis. Although there are cases where individuals may survive beyond this

timeframe due to various factors such as early diagnosis and effective management strategies, these cases are less common and do not represent the average life expectancy for a patient with IPF.

Discuss (1) Improve

Next question

Idiopathic pulmonary fibrosis

Idiopathic pulmonary fibrosis (IPF, previously termed cryptogenic fibrosing alveolitis) is a chronic lung condition characterised by progressive fibrosis of the interstitium of the lungs. Whilst there are many causes of lung fibrosis (e.g. medications, connective tissue disease, asbestos) the term IPF is reserved when no underlying cause exists.

IPF is typically seen in patients aged 50-70 years and is twice as common in men.

Features

- progressive exertional dyspnoea
- bibasal fine end-inspiratory crepitations on auscultation
- dry cough
- clubbing

Diagnosis

- spirometry: classically a restrictive picture (FEV1 normal/decreased, FVC decreased, FEV1/FVC increased)
- impaired gas exchange: reduced transfer factor (TLCO)
- imaging: bilateral interstitial shadowing (typically small, irregular, peripheral opacities - 'ground-glass' - later progressing to 'honeycombing') may be seen on a chest x-ray but high-resolution CT scanning is the investigation of choice and required to make a diagnosis of IPF
- ANA positive in 30%, rheumatoid factor positive in 10% but this does not necessarily mean that the fibrosis is secondary to a connective tissue disease. Titres are usually low

Management

- pulmonary rehabilitation
- very few medications have been shown to give any benefit in IPF. There is some evidence that pirfenidone (an antifibrotic agent) may be useful in selected patients (see NICE guidelines)
- many patients will require supplementary oxygen and eventually a lung transplant

Prognosis

- poor, average life expectancy is around 3-4 years

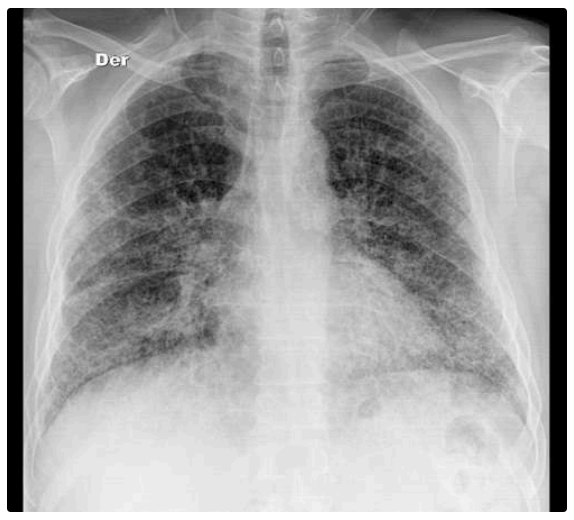

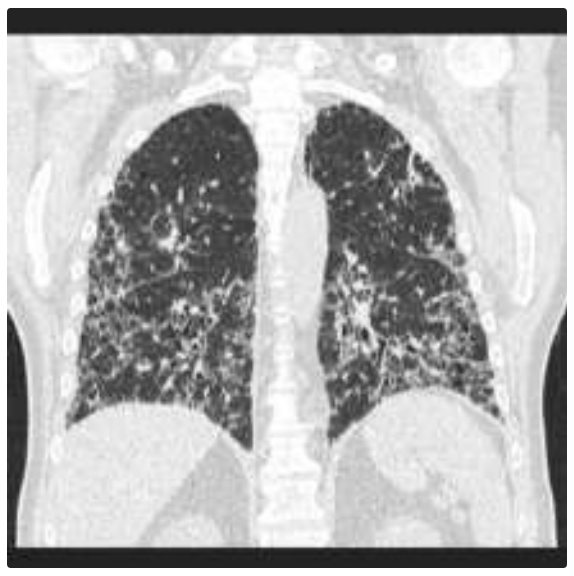

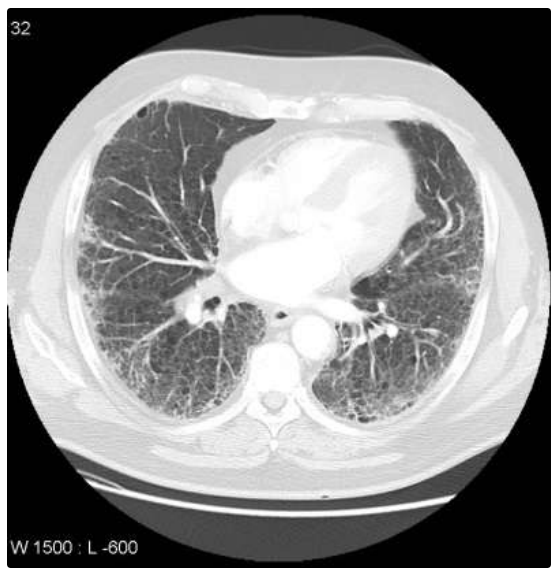

123

Next question

Textbooks

High-yield textbook

Extended textbook

Links

Royal College of Physicians 13 10

Update in diagnosis and management of interstitial lung disease

NICE 11 6

2013 Idiopathic pulmonary fibrosis guidelines

Suggest link Report broken link

Media

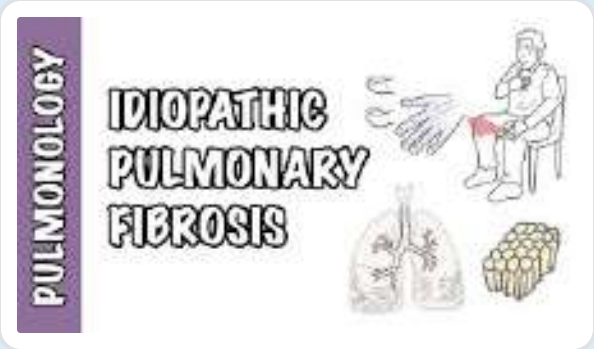

Idiopathic pulmonary fibrosis

Armando Hasudungan - YouTube 6 0

Interstitial Lung Disease (ILD) - Classification, pathophysiology, signs and symptoms

Armando Hasudungan - YouTube 5 0

Idiopathic pulmonary fibrosis

Osmosis - YouTube 4 0

Report broken media

Score: **17.3%**

1 ✗
2 ✗
3 ✗
4 ✗
5 ✗
6 ✗
7 ✗
8 ✗
9 ✗

10	✗
11	✗
12	✓
13	✗
14	✗
15	✗
16	✗
17	✗
18	✗
19	✗
20	✗
21	✗
22	✗
23	✓
24	✗
25	✗
26	✗
27	✗
28	✗
29	✓
30	✗
31	✓
32	✗
33	✗
34	✗
35	✗
36	✓
37	✓
38	✗
39	✗
40	✗
41	✓
42	✗
43	✗
44	✗
45	✗

46	✗
47	✗
48	✗
49	✓
50	✗
51	✗
52	✓
53	✗
54	✗
55	✓
56	✗
57	✗
58	✓
59	✗
60	✓
61	✗
62	✗
63	✗
64	✗
65	✗
66	✗
67	✗
68	✗
69	✗
70	✗
71	✗
72	✗
73	✗
74	✗
75	✓
76	✗
77	✗
78	✗
79	✓
80	✗
81	✗

82	✓
83	✗
84	✗
85	✗
86	✗
87	✗
88	✗
89	✗
90	✗
91	✗
92	✗
93	✓
94	✗
95	✓
96	✗
97	✗
98	✗
99	✗
100	✗
101	✗
102	✗
103	✓
104	✗
105	✗
106	✓
107	✗
108	✗
109	✗
110	✗
111	-

All contents of this site are © 2024 Passmedicine Limited

Back to top

A 63-year-old is reviewed following admission with an infective exacerbation of COPD. He originally presented with shortness of breath, tight-chestedness and feeling generally unwell. He was initially managed with medical treatment including IV piperacillin with tazobactam, IV hydrocortisone, IV fluids, nebulised salbutamol and nebulised ipratropium bromide but his hypercapnia and acidosis failed to improved. He was then initiated on non-invasive ventilation (NIV) starting with IPAP of 10 cm H2O and EPAP of 4 cm H2O. He has managed to have the IPAP increased to 14 cm H2O but he is struggling to tolerate this as he is feeling increasingly anxious. He has only had NIV for three hours so far.

Arterial blood gas results:

	On admission	Current
pH	7.11	7.23
pCO_2	14.7	12.1
pO_2	8.4	10.7

What is the most appropriate method to help him settle him?

- Give him haloperidol
- Give him diazepam
- Increase IPAP
- Increase EPAP alone
- Stop NIV

Submit answer

Reference ranges

Score: **16%**

1	✗
2	✗
3	✗
4	✗
5	✗
6	✗
7	✗
8	✗
9	✗
10	✗
11	✗
12	✓
13	✗
14	✗
15	✗
16	✗
17	✗
18	✗
19	✗
20	✗
21	✗
22	✗
23	✓
24	✗
25	✗
26	✗
27	✗
28	✗
29	✓
30	✗
31	✓
32	✗
33	✗
34	✗

35	✗
36	✓
37	✓
38	✗
39	✗
40	✗
41	✓
42	✗
43	✗
44	✗
45	✗
46	✗
47	✗
48	✗
49	✓
50	✗
51	-
52	-
53	-
54	-

All contents of this site are © 2024 Passmedicine Limited
Back to top

A 63-year-old is reviewed following admission with an infective exacerbation of COPD. He originally presented with shortness of breath, tight-chestedness and feeling generally unwell. He was initially managed with medical treatment including IV piperacillin with tazobactam, IV hydrocortisone, IV fluids, nebulised salbutamol and nebulised ipratropium bromide but his hypercapnia and acidosis failed to improved. He was then initiated on non-invasive ventilation (NIV) starting with IPAP of 10 cm H2O and EPAP of 4 cm H2O. He has managed to have the IPAP increased to 14 cm H2O but he is struggling to tolerate this as he is feeling increasingly anxious. He has only had NIV for three hours so far.

Arterial blood gas results:

	On admission	Current
pH	7.11	7.23
pCO_2	14.7	12.1
pO_2	8.4	10.7

What is the most appropriate method to help him settle him?

- Give him haloperidol 26%
- Give him diazepam 29%
- Increase IPAP 11%
- Increase EPAP alone 22%
- Stop NIV 11%

The correct answer is to give him haloperidol. Many patients struggle to tolerate an NIV mask as it is tight-fitting and blows air uncomfortably at the patient and it can be difficult to accustom too. When first introducing the mask to the patient explain what is happening to the patient as they may be confused, especially if hypercapnic, and gently place the mask on the patient's face. It can help to place the mask in the patient's hand and guide it to their face to facilitate cooperation. Show the patient how to take on and off the mask if they are able to do so as this may ease the process. In the acute phase it is important that there are frequent reviews to ensure the mask is being used.

Many can begin to tolerate the mask over time.

Increasing the IPAP would make it more uncomfortable and would likely make him refuse the treatment entirely, even though it is likely to be needed to help relieve the hypercapnia as it creates greater ventilatory support.. Decreasing the IPAP or stopping NIV would be more comfortable but would be inappropriate as treatment is then likely to fail with greater hypoxia and acidosis. Diazepam is contraindicated in this situation as the added drowsiness can be dangerous, but haloperidol or morphine may help settle him sufficiently to tolerate the mask. Increasing EPAP without increasing IPAP would reduce the amount of ventilatory support and would be inappropriate.

Discuss (8) | Improve

Next question

Non-invasive ventilation

The British Thoracic Society (BTS) published guidelines in 2002 on the use of non-invasive ventilation in acute respiratory failure. Following these the Royal College of Physicians published guidelines in 2008.

Non-invasive ventilation - key indications

- COPD with respiratory acidosis pH 7.25-7.35
  - the BTS guidelines state that NIV can be used in patients who are more acidotic (i.e. pH < 7.25) but that a greater degree of monitoring is required (e.g. HDU) and a lower threshold for intubation and ventilation should be used
- type II respiratory failure secondary to chest wall deformity, neuromuscular disease or obstructive sleep apnoea
- cardiogenic pulmonary oedema unresponsive to CPAP
- weaning from tracheal intubation

Recommended initial settings for bi-level pressure support in COPD

- Expiratory Positive Airway Pressure (EPAP): 4-5 cm H2O
- Inspiratory Positive Airway Pressure (IPAP): RCP advocate 10 cm H20 whilst BTS suggest 12-15 cm H2O
- back up rate: 15 breaths/min
- back up inspiration:expiration ratio: 1:3

AI + Q 123

Next question

Textbooks

High-yield textbook

Extended textbook

Links

British Thoracic Society 12 4

2016 BTS/ICS Guidelines for the Ventilatory Management of Acute Hypercapnic Respiratory Failure in Adults

Suggest link

Report broken link

Media

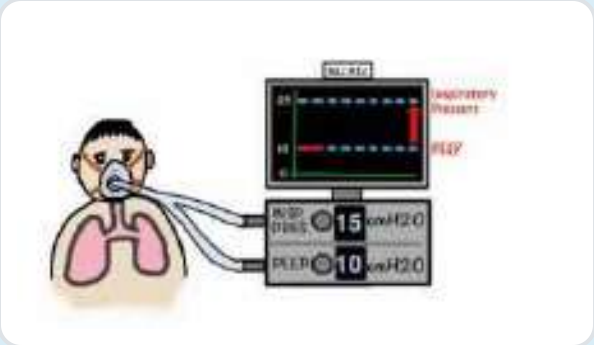

CPAP and Non-Invasive Ventilation in 5 minutes

Nick Smith - YouTube 31 2

Clinical Skills: BiPAP and CPAP

Osmosis - YouTube 3 7

Report broken media

Score: **17.3%**

1	✗
2	✗
3	✗
4	✗
5	✗
6	✗
7	✗
8	✗
9	✗
10	✗
11	✗
12	✓
13	✗
14	✗
15	✗
16	✗
17	✗
18	✗
19	✗
20	✗
21	✗
22	✗
23	✓
24	✗
25	✗
26	✗
27	✗
28	✗
29	✓
30	✗
31	✓
32	✗

33	✗
34	✗
35	✗
36	✓
37	✓
38	✗
39	✗
40	✗
41	✓
42	✗
43	✗
44	✗
45	✗
46	✗
47	✗
48	✗
49	✓
50	✗
51	✗
52	✓
53	✗
54	✗
55	✓
56	✗
57	✗
58	✓
59	✗
60	✓
61	✗
62	✗
63	✗
64	✗
65	✗
66	✗
67	✗
68	✗

69	✗
70	✗
71	✗
72	✗
73	✗
74	✗
75	✓
76	✗
77	✗
78	✗
79	✓
80	✗
81	✗
82	✓
83	✗
84	✗
85	✗
86	✗
87	✗
88	✗
89	✗
90	✗
91	✗
92	✗
93	✓
94	✗
95	✓
96	✗
97	✗
98	✗
99	✗
100	✗
101	✗
102	✗
103	✓
104	✗

105	✗
106	✓
107	✗
108	✗
109	✗
110	✗
111	-

All contents of this site are © 2024 Passmedicine Limited

A 68-year-old is seen in a cardiology clinic. He has a part history of long-standing atrial fibrillation, hypertension and ischaemic heart disease. He describes progressive shortness of breath over the past year and a dry cough. His medication history includes aspirin, amiodarone, ramipril, doxazosin and gliclazide.

On examination, he is comfortable on lying flat but is noticeably dyspnoeic when mobilising. He has minimal ankle oedema, his heart rate is 78 beats per minute and he has fine bibasal crepitations on auscultation of his chest. His oxygen saturations on air are 92%.

An echocardiogram reveals a left ventricular ejection fraction of 45%, a mildly hypertrophied left ventricle and well established right ventricular hypertrophy, pulmonary artery pressures are raised at 32 mmHg (normal: < 25 mmHg). A chest x-ray shows non-specific changes on both bases.

What is the most appropriate next investigation?

- Exercise stress test
- Cardiac MRI
- Overnight oximetry
- Repeat echo
- HRCT chest

Submit answer

Reference ranges

Score: **16%**

1 ✗

2	✗
3	✗
4	✗
5	✗
6	✗
7	✗
8	✗
9	✗
10	✗
11	✗
12	✓
13	✗
14	✗
15	✗
16	✗
17	✗
18	✗
19	✗
20	✗
21	✗
22	✗
23	✓
24	✗
25	✗
26	✗
27	✗
28	✗
29	✓
30	✗
31	✓
32	✗
33	✗
34	✗
35	✗
36	✓
37	✓

38	✗
39	✗
40	✗
41	✓
42	✗
43	✗
44	✗
45	✗
46	✗
47	✗
48	✗
49	✓
50	✗
51	-
52	-
53	-
54	-
55	-

All contents of this site are © 2024 Passmedicine Limited

A 68-year-old is seen in a cardiology clinic. He has a part history of long-standing atrial fibrillation, hypertension and ischaemic heart disease. He describes progressive shortness of breath over the past year and a dry cough. His medication history includes aspirin, amiodarone, ramipril, doxazosin and gliclazide.

On examination, he is comfortable on lying flat but is noticeably dyspnoeic when mobilising. He has minimal ankle oedema, his heart rate is 78 beats per minute and he has fine bibasal crepitations on auscultation of his chest. His oxygen saturations on air are 92%.

An echocardiogram reveals a left ventricular ejection fraction of 45%, a mildly hypertrophied left ventricle and well established right ventricular hypertrophy, pulmonary artery pressures are raised at 32 mmHg (normal: < 25 mmHg). A chest x-ray shows non-specific changes on both bases.

What is the most appropriate next investigation?

Exercise stress test	4%
Cardiac MRI	14%
Overnight oximetry	4%
Repeat echo	3%
HRCT chest	75%

The raised pulmonary artery pressures and right ventricular hypertrophy points to a respiratory pathology. Despite the history of atrial fibrillation a cardiac cause is less likely to be causing his dyspnoea in view of the fact that he is comfortable when lying flat (i.e. no orthopnoea), he has minimal ankle oedema and that his left ventricular function is only mildly impaired. This patient should be investigated for interstitial lung disease in view of his history of amiodarone use. In light of this an exercise stress test, a cardiac MRI and a repeat echo are unlikely to be of any benefit and there is no indication to perform overnight oximetry. An HRCT is warranted to help aid establish a diagnosis.

Discuss (2) Improve

Idiopathic pulmonary fibrosis

Idiopathic pulmonary fibrosis (IPF, previously termed cryptogenic fibrosing alveolitis) is a chronic lung condition characterised by progressive fibrosis of the interstitium of the lungs. Whilst there are many causes of lung fibrosis (e.g. medications, connective tissue disease, asbestos) the term IPF is reserved when no underlying cause exists.

IPF is typically seen in patients aged 50-70 years and is twice as common in men.

Features

- progressive exertional dyspnoea
- bibasal fine end-inspiratory crepitations on auscultation
- dry cough
- clubbing

Diagnosis

- spirometry: classically a restrictive picture (FEV1 normal/decreased, FVC decreased, FEV1/FVC increased)
- impaired gas exchange: reduced transfer factor (TLCO)
- imaging: bilateral interstitial shadowing (typically small, irregular, peripheral opacities - 'ground-glass' - later progressing to 'honeycombing') may be seen on a chest x-ray but high-resolution CT scanning is the investigation of choice and required to make a diagnosis of IPF
- ANA positive in 30%, rheumatoid factor positive in 10% but this does not necessarily mean that the fibrosis is secondary to a connective tissue disease. Titres are usually low

Management

- pulmonary rehabilitation
- very few medications have been shown to give any benefit in IPF. There is some evidence that pirfenidone (an antifibrotic agent) may be useful in selected patients (see NICE guidelines)
- many patients will require supplementary oxygen and eventually a lung transplant

Prognosis

- poor, average life expectancy is around 3-4 years

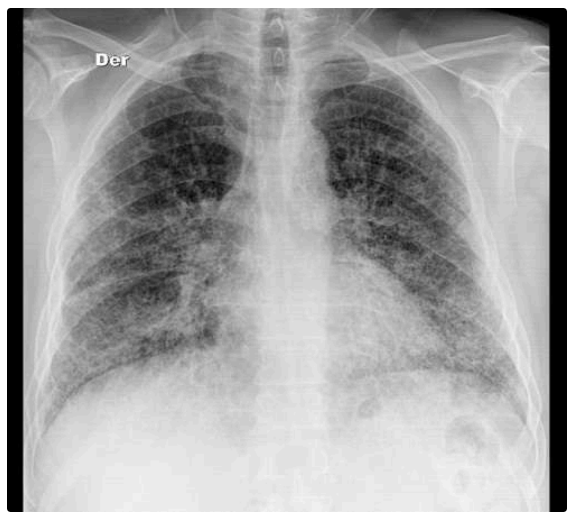 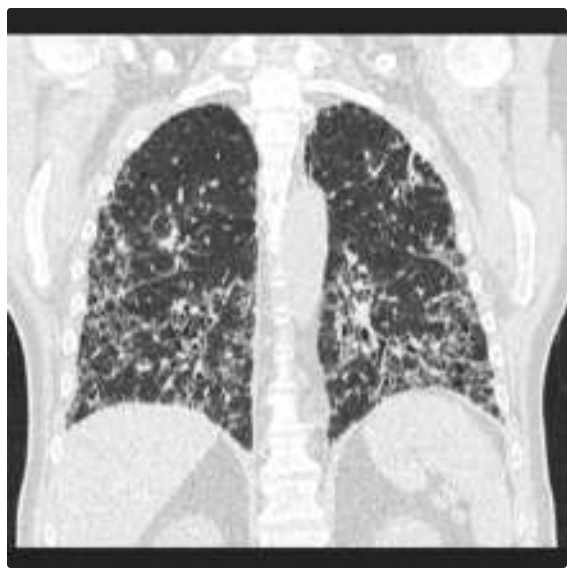 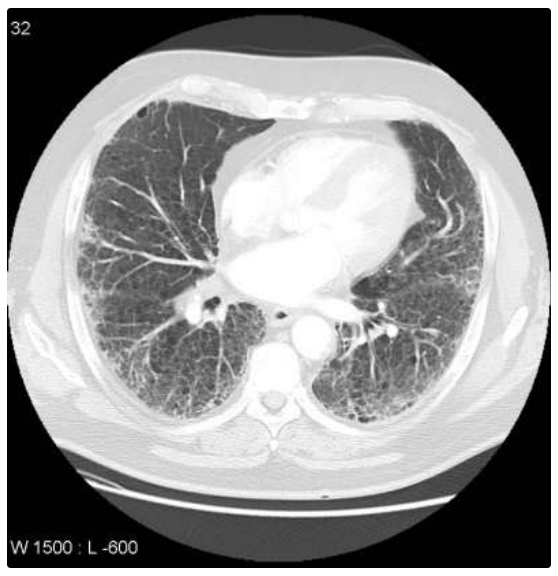

123

Next question

Textbooks

High-yield textbook

Extended textbook

Links

Royal College of Physicians 13 10

Update in diagnosis and management of interstitial lung disease

NICE 11 6

2013 Idiopathic pulmonary fibrosis guidelines

Suggest link Report broken link

Media

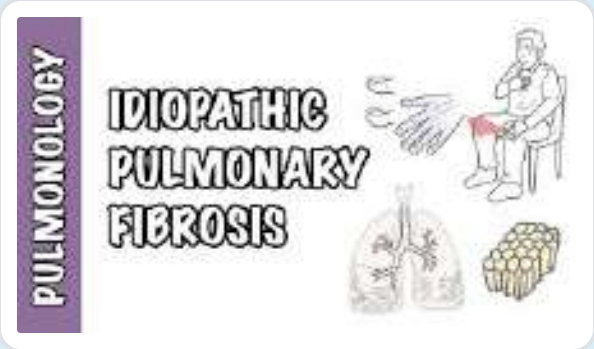

[Idiopathic pulmonary fibrosis]

Armando Hasudungan - YouTube 6 0

Interstitial Lung Disease (ILD) - Classification, pathophysiology, signs and symptoms

Armando Hasudungan - YouTube 5 0

Idiopathic pulmonary fibrosis

Osmosis - YouTube 4 0

Report broken media

Score: **17.3%**

1 ✗
2 ✗
3 ✗
4 ✗
5 ✗
6 ✗
7 ✗
8 ✗
9 ✗
10 ✗

11	✗
12	✓
13	✗
14	✗
15	✗
16	✗
17	✗
18	✗
19	✗
20	✗
21	✗
22	✗
23	✓
24	✗
25	✗
26	✗
27	✗
28	✗
29	✓
30	✗
31	✓
32	✗
33	✗
34	✗
35	✗
36	✓
37	✓
38	✗
39	✗
40	✗
41	✓
42	✗
43	✗
44	✗
45	✗
46	✗

47	✗
48	✗
49	✓
50	✗
51	✗
52	✓
53	✗
54	✗
55	✓
56	✗
57	✗
58	✓
59	✗
60	✓
61	✗
62	✗
63	✗
64	✗
65	✗
66	✗
67	✗
68	✗
69	✗
70	✗
71	✗
72	✗
73	✗
74	✗
75	✓
76	✗
77	✗
78	✗
79	✓
80	✗
81	✗
82	✓

83	✗
84	✗
85	✗
86	✗
87	✗
88	✗
89	✗
90	✗
91	✗
92	✗
93	✓
94	✗
95	✓
96	✗
97	✗
98	✗
99	✗
100	✗
101	✗
102	✗
103	✓
104	✗
105	✗
106	✓
107	✗
108	✗
109	✗
110	✗
111	-

All contents of this site are © 2024 Passmedicine Limited

Back to top

A 65-year-old lady with known severe emphysema attends the emergency department with breathlessness and is diagnosed with a non-infective exacerbation of chronic obstructive pulmonary disease. It is her 6th exacerbation this year. She tells you that she has been referred by her respiratory team for lung volume reduction surgery and is awaiting an appointment.Which of the following criteria would make the patient an unsuitable candidate for lung volume reduction surgery?

- Predominantly upper lobe emphysema and high exercise capacity.
- Non-upper lobe emphysema and high exercise capacity.
- Predominantly upper lobe emphysema and low exercise capacity.
- Upper lobe emphysema and carbon monoxide diffusing capacity 40%
- Non-upper lobe emphysema and low exercise capacity.

Submit answer

Reference ranges

Score: **16%**

1	✕
2	✕
3	✕
4	✕
5	✕
6	✕
7	✕
8	✕

9 ✗
10 ✗
11 ✗
12 ✓
13 ✗
14 ✗
15 ✗
16 ✗
17 ✗
18 ✗
19 ✗
20 ✗
21 ✗
22 ✗
23 ✓
24 ✗
25 ✗
26 ✗
27 ✗
28 ✗
29 ✓
30 ✗
31 ✓
32 ✗
33 ✗
34 ✗
35 ✗
36 ✓
37 ✓
38 ✗
39 ✗
40 ✗
41 ✓
42 ✗
43 ✗
44 ✗

45	✗
46	✗
47	✗
48	✗
49	✓
50	✗
51	-
52	-
53	-
54	-
55	-
56	-

All contents of this site are © 2024 Passmedicine Limited

Back to top

A 65-year-old lady with known severe emphysema attends the emergency department with breathlessness and is diagnosed with a non-infective exacerbation of chronic obstructive pulmonary disease. It is her 6th exacerbation this year. She tells you that she has been referred by her respiratory team for lung volume reduction surgery and is awaiting an appointment.Which of the following criteria would make the patient an unsuitable candidate for lung volume reduction surgery?

Predominantly upper lobe emphysema and high exercise capacity.	9%
Non-upper lobe emphysema and high exercise capacity.	15%
Predominantly upper lobe emphysema and low exercise capacity.	27%
Upper lobe emphysema and carbon monoxide diffusing capacity 40%	15%
Non-upper lobe emphysema and low exercise capacity.	34%

The National Emphysema Treatment Trial was a prospective, randomised, multi-centre trial which compared the results of lung volume reduction surgery to medical therapy which showed that there were 3 groups of patients that tend to benefit:

Group 1: Upper lobe emphysema and low exercise capacity. These patients show improvement in both functional outcomes and survival after lung volume reduction surgery compared to medical therapy.

Group 2: Patients with predominantly upper lobe emphysema and high exercise capacity. These patients have improved functional outcomes but no difference in survival compared to medical therapy.

Group 3: Patients with non-upper lobe emphysema and low exercise capacity. These patients have improved survival after surgery but there is no difference in survival compared to medical therapy.

The trial also identified patients with emphysema that are unlikely to do well from lung volume reduction surgery and have a high risk of death. This includes:

- 1. Patients with non-upper lobe emphysema and high exercise capacity.
- 2. Patients with extremely poor pulmonary function (forced expiratory volume in 1 second (FEV1) 20% or less than predicted) and either homogenous distribution of emphysema on

computed tomography scan or extremely poor carbon monoxide diffusing capacity (20% or less than predicted).

Discuss (4) Improve

Next question

COPD: stable management

NICE updated its guidelines on the management of chronic obstructive pulmonary disease (COPD) in 2018.

General management

- >smoking cessation advice: including offering nicotine replacement therapy, varenicline or bupropion
- annual influenza vaccination
- one-off pneumococcal vaccination
- pulmonary rehabilitation to all people who view themselves as functionally disabled by COPD (usually Medical Research Council [MRC] grade 3 and above)

Bronchodilator therapy

- a short-acting beta2-agonist (SABA) or short-acting muscarinic antagonist (SAMA) is first-line treatment
- for patients who remain breathless or have exacerbations despite using short-acting bronchodilators the next step is determined by whether the patient has '*asthmatic features/features suggesting steroid responsiveness*'

There are a number of criteria NICE suggest to determine whether a patient has asthmatic/steroid responsive features:

- any previous, secure diagnosis of asthma or of atopy
- a higher blood eosinophil count - note that NICE recommend a full blood count for all patients as part of the work-up
- substantial variation in FEV1 over time (at least 400 ml)
- substantial diurnal variation in peak expiratory flow (at least 20%)

Interestingly NICE do not recommend formal reversibility testing as one of the criteria. In the guidelines they state that '*routine spirometric reversibility testing is not necessary as part of the*

diagnostic process or to plan initial therapy with bronchodilators or corticosteroids. It may be unhelpful or misleading...'. They then go on to discuss why they have reached this conclusion. Please see the guidelines for more details.

No asthmatic features/features suggesting steroid responsiveness

- add a long-acting beta2-agonist (LABA) + long-acting muscarinic antagonist (LAMA)
    - if already taking a SAMA, discontinue and switch to a SABA

Asthmatic features/features suggesting steroid responsiveness

- LABA + inhaled corticosteroid (ICS)
- if patients remain breathless or have exacerbations offer triple therapy i.e. LAMA + LABA + ICS
    - if already taking a SAMA, discontinue and switch to a SABA
- NICE recommend the use of combined inhalers where possible

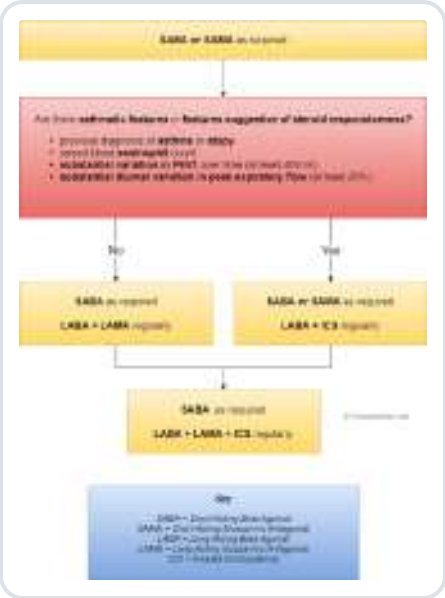

Oral theophylline

- NICE only recommends theophylline after trials of short and long-acting bronchodilators or to people who cannot used inhaled therapy
- the dose should be reduced if macrolide or fluoroquinolone antibiotics are co-prescribed

Oral prophylactic antibiotic therapy

- azithromycin prophylaxis is recommended in select patients
- patients should not smoke, have optimised standard treatments and continue to have exacerbations
- other prerequisites include a CT thorax (to exclude bronchiectasis) and sputum culture (to exclude atypical infections and tuberculosis)
- LFTs and an ECG to exclude QT prolongation should also be done as azithromycin can prolong the QT interval

Standby medication: NICE recommend offering a short course of oral corticosteroids and oral antibiotics to keep at home if: NICE

- have had an exacerbation within the last year
- understand how to take the medication, and are aware of associated risks and benefits

- know to when to seek help and when to ask for replacements once medication has been used

Mucolytics

- should be 'considered' in patients with a chronic productive cough and continued if symptoms improve

Phosphodiesterase-4 (PDE-4) inhibitors NICE

- oral PDE-4 inhibitors such as roflumilast reduce the risk of COPD exacerbations in patients with severe COPD and a history of frequent COPD exacerbations
- NICE recommend if:
  - the disease is severe, defined as a forced expiratory volume in 1 second (FEV1) after a bronchodilator of less than 50% of predicted normal, and
  - the person has had 2 or more exacerbations in the previous 12 months despite triple inhaled therapy with a long-acting muscarinic antagonist, a long-acting beta-2 agonist and an inhaled corticosteroid

Cor pulmonale

- features include peripheral oedema, raised jugular venous pressure, systolic parasternal heave, loud P2
- use a loop diuretic for oedema, consider long-term oxygen therapy
- ACE-inhibitors, calcium channel blockers and alpha blockers are not recommended by NICE

Factors which may improve survival in patients with stable COPD

- smoking cessation - the single most important intervention in patients who are still smoking
- long term oxygen therapy in patients who fit criteria
- lung volume reduction surgery in selected patients

AI + Q 123

Next question >

Textbooks

High-yield textbook

Extended textbook

Links

Global Initiative for Chronic Obstructive Lung Disease 14 32

GOLD criteria 2017

NICE 33 30

2018 COPD guidelines

NICE 15 10

Roflumilast NICE recommendations

NICE 65 18

2018 COPD management diagram

Suggest link Report broken link

Media

Cor pulmonale

Zero To Finals - YouTube 5 0

Chronic bronchitis

Osmosis - YouTube 3 0

[Cor pulmonale]

Osmosis - YouTube 1 0

[Understanding COPD]

Armando Hasudungan - YouTube 0 0

[All about COPD (for Medical Students)]

MedFlix - YouTube 3 1

Report broken media

Score: **17.3%**

1 ✗
2 ✗
3 ✗
4 ✗
5 ✗
6 ✗
7 ✗
8 ✗
9 ✗
10 ✗

11	✗
12	✓
13	✗
14	✗
15	✗
16	✗
17	✗
18	✗
19	✗
20	✗
21	✗
22	✗
23	✓
24	✗
25	✗
26	✗
27	✗
28	✗
29	✓
30	✗
31	✓
32	✗
33	✗
34	✗
35	✗
36	✓
37	✓
38	✗
39	✗
40	✗
41	✓
42	✗
43	✗
44	✗
45	✗
46	✗

47	✗
48	✗
49	✓
50	✗
51	✗
52	✓
53	✗
54	✗
55	✓
56	✗
57	✗
58	✓
59	✗
60	✓
61	✗
62	✗
63	✗
64	✗
65	✗
66	✗
67	✗
68	✗
69	✗
70	✗
71	✗
72	✗
73	✗
74	✗
75	✓
76	✗
77	✗
78	✗
79	✓
80	✗
81	✗
82	✓

83	✗
84	✗
85	✗
86	✗
87	✗
88	✗
89	✗
90	✗
91	✗
92	✗
93	✓
94	✗
95	✓
96	✗
97	✗
98	✗
99	✗
100	✗
101	✗
102	✗
103	✓
104	✗
105	✗
106	✓
107	✗
108	✗
109	✗
110	✗
111	-

All contents of this site are © 2024 Passmedicine Limited

A 60-year-old woman is investigated for recurrent episodes of dyspnoea. She describes becoming progressively more short-of-breath over the past two years with frequent exacerbations associated with fever, lethargy and coughing bouts. Her symptoms often settle down for a time but she does feel her breathing is getting worse over time.

She smokes 20 cigarettes/day, drinks 10 units of alcohol per week and works in a poultry farm. Her past medical history includes hypothyroidism and depression.

On examination her oxygen saturations on air are 94%.

A CT scan is requested:

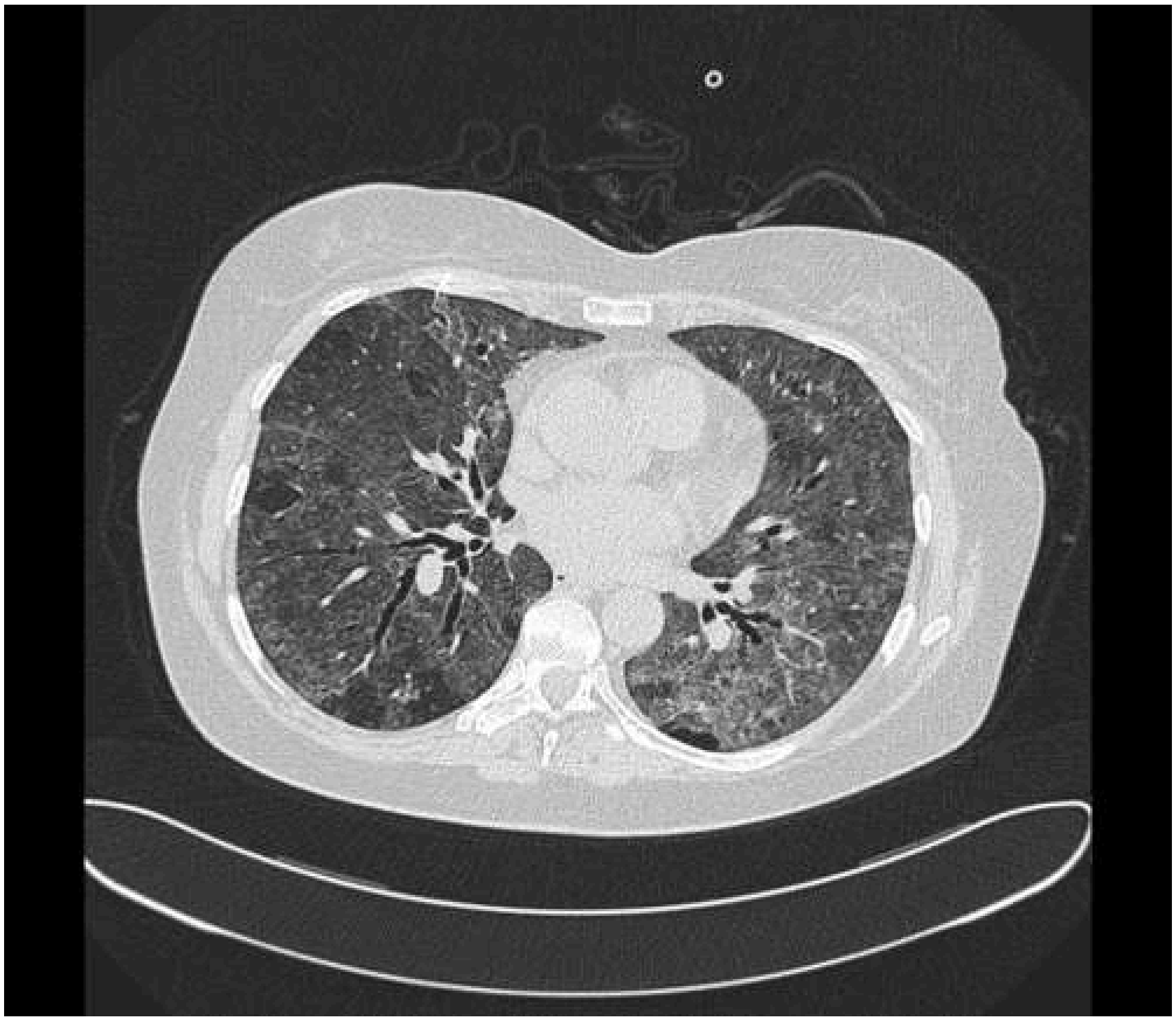

© Image used on license from Radiopaedia

What is the most likely diagnosis?

- Bronchiectasis
- Hypersensitivity pneumonitis

- Sarcoidosis
- Histiocytosis
- Histoplasmosis

Submit answer

Reference ranges

Score: **16%**

1	✗
2	✗
3	✗
4	✗
5	✗
6	✗
7	✗
8	✗
9	✗
10	✗
11	✗
12	✓
13	✗
14	✗
15	✗
16	✗
17	✗
18	✗
19	✗
20	✗
21	✗

22	✗
23	✓
24	✗
25	✗
26	✗
27	✗
28	✗
29	✓
30	✗
31	✓
32	✗
33	✗
34	✗
35	✗
36	✓
37	✓
38	✗
39	✗
40	✗
41	✓
42	✗
43	✗
44	✗
45	✗
46	✗
47	✗
48	✗
49	✓
50	✗
51	-
52	-
53	-
54	-
55	-
56	-
57	-

All contents of this site are © 2024 Passmedicine Limited

PassMedicine

A 60-year-old woman is investigated for recurrent episodes of dyspnoea. She describes becoming progressively more short-of-breath over the past two years with frequent exacerbations associated with fever, lethargy and coughing bouts. Her symptoms often settle down for a time but she does feel her breathing is getting worse over time.

She smokes 20 cigarettes/day, drinks 10 units of alcohol per week and works in a poultry farm. Her past medical history includes hypothyroidism and depression.

On examination her oxygen saturations on air are 94%.

A CT scan is requested:

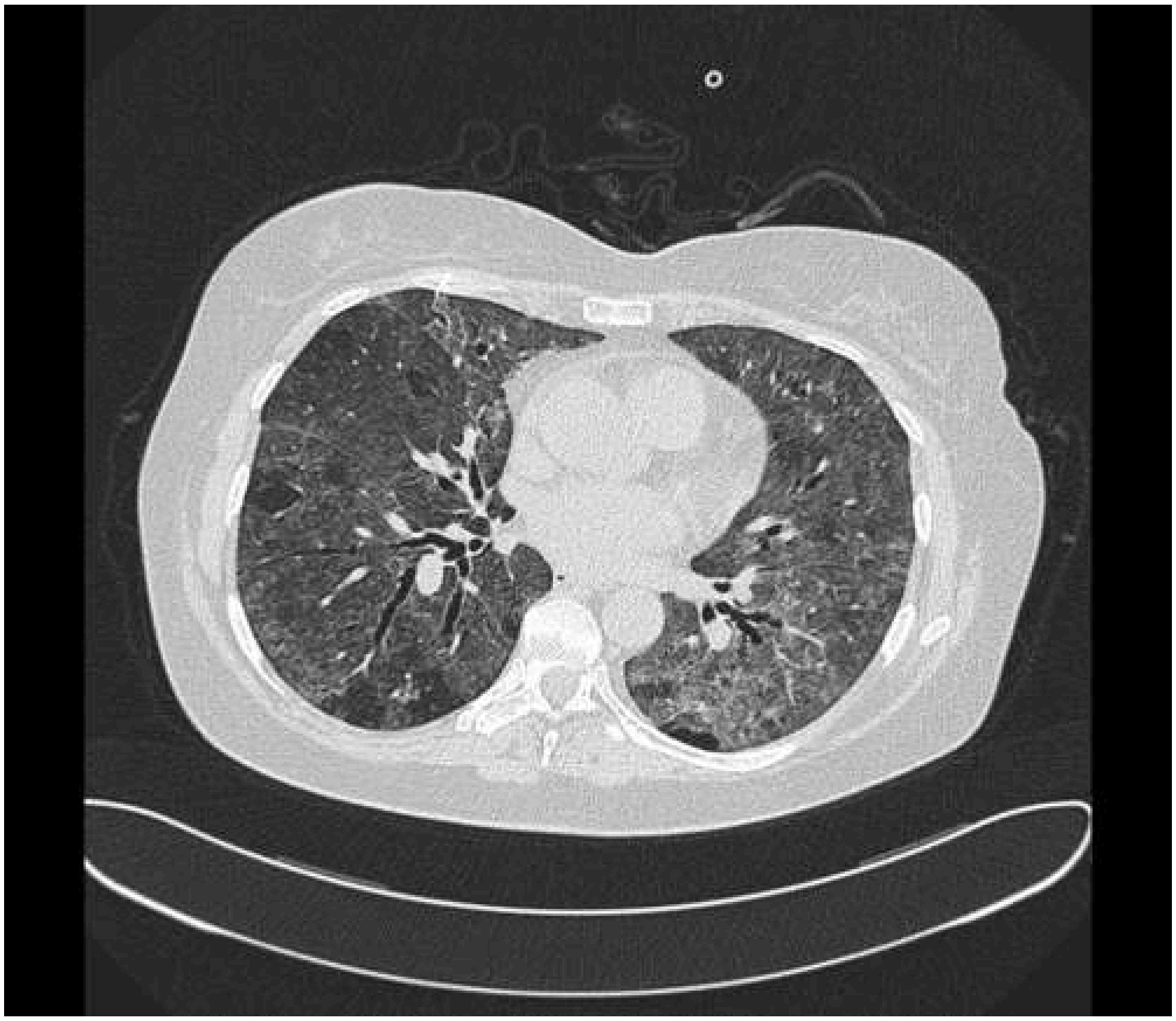

© Image used on license from Radiopaedia

What is the most likely diagnosis?

Bronchiectasis	33%
Hypersensitivity pneumonitis	57%

Sarcoidosis	2%
Histiocytosis	5%
Histoplasmosis	4%

This lady most like had acute hypersensitivity pneumonitis to start with which has now progressed to the sub-acute/chronic form. The diagnosis is suggested by her occupation, intermittent symptoms and CT findings which show multuple centrilobular ground glass nodules.

Discuss (7) Improve

Next question

Extrinsic allergic alveolitis

Extrinsic allergic alveolitis (EAA, also known as hypersensitivity pneumonitis) is a condition caused by hypersensitivity induced lung damage due to a variety of inhaled organic particles. It is thought to be largely caused by immune-complex mediated tissue damage (type III hypersensitivity) although delayed hypersensitivity (type IV) is also thought to play a role in EAA, especially in the chronic phase.

Examples

- bird fanciers' lung: avian proteins from bird droppings
- farmers lung: spores of *Saccharopolyspora rectivirgula* from wet hay (formerly *Micropolyspora faeni*)
- malt workers' lung: *Aspergillus clavatus*
- mushroom workers' lung: thermophilic actinomycetes*

Presentation

- acute (occurs 4-8 hrs after exposure)
  - dyspnoea
  - dry cough
  - fever
- chronic (occurs weeks-months after exposure)
  - lethargy
  - dyspnoea
  - productive cough
  - anorexia and weight loss

Investigation

- imaging: upper/mid-zone fibrosis
- bronchoalveolar lavage: lymphocytosis
- serologic assays for specific IgG antibodies
- blood: NO eosinophilia

Management

- avoid precipitating factors
- oral glucocorticoids

*here the terminology is slightly confusing as thermophilic actinomycetes is an umbrella term covering strains such as *Micropolyspora faeni*

© Image used on license from Radiopaedia

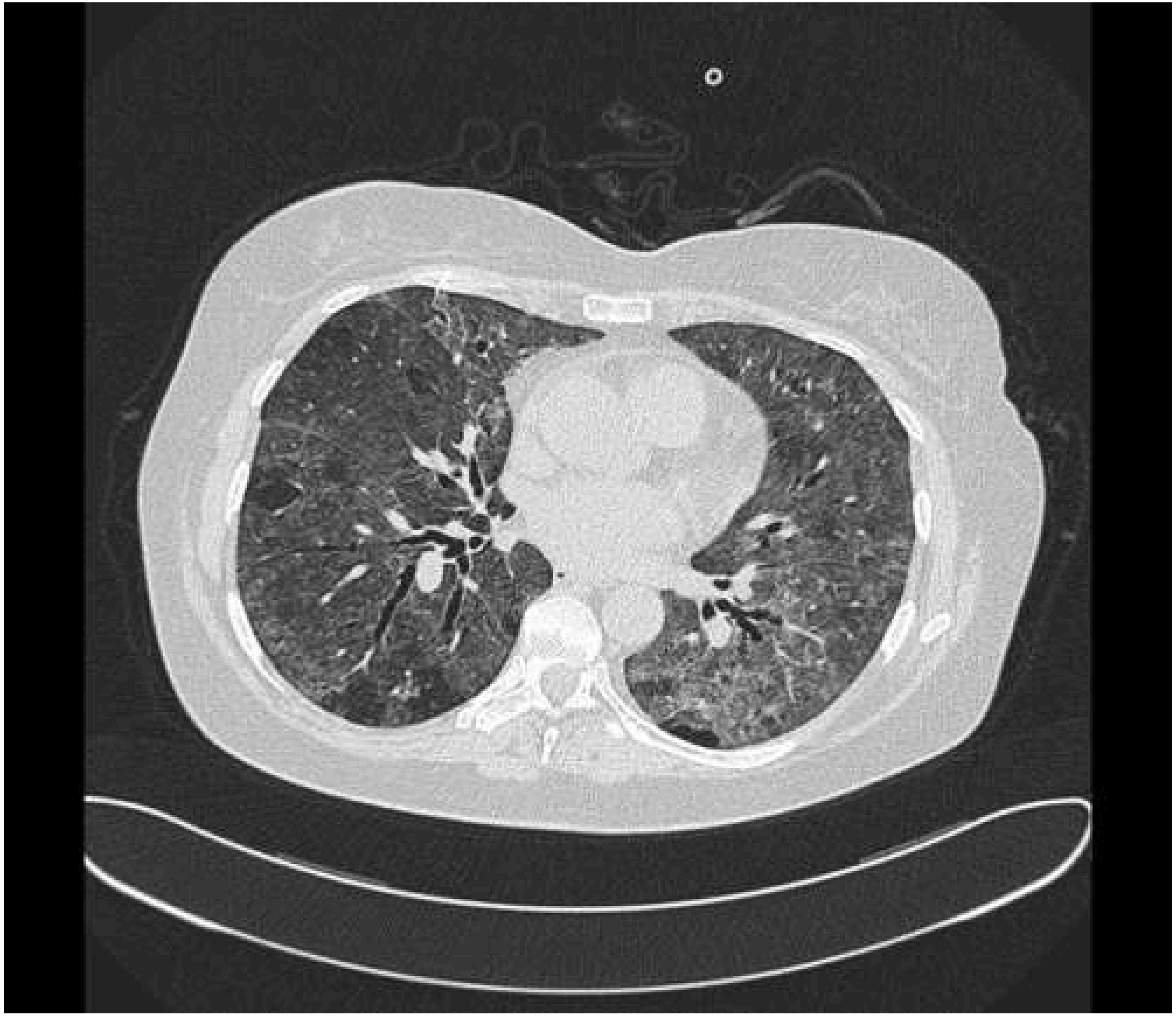

© Image used on license from Radiopaedia

Chest x-ray and CT scan from a middle-aged woman who presented with dyspnoea. The CT demonstrates multuple centrilobular ground glass nodules consistent with hypersensitivity pneumonitis

+ Q 123

Next question >

Textbooks

High-yield textbook

Extended textbook

Media

Hypersensitivity pneumonitis

Armando Hasudungan - YouTube 👍 3 👎 1

Report broken media

Score: **17.3%**

1	✗
2	✗
3	✗
4	✗
5	✗
6	✗
7	✗
8	✗
9	✗
10	✗
11	✗
12	✓
13	✗
14	✗
15	✗
16	✗
17	✗
18	✗
19	✗
20	✗
21	✗
22	✗

23	✓
24	✗
25	✗
26	✗
27	✗
28	✗
29	✓
30	✗
31	✓
32	✗
33	✗
34	✗
35	✗
36	✓
37	✓
38	✗
39	✗
40	✗
41	✓
42	✗
43	✗
44	✗
45	✗
46	✗
47	✗
48	✗
49	✓
50	✗
51	✗
52	✓
53	✗
54	✗
55	✓
56	✗
57	✗
58	✓

59	✗
60	✓
61	✗
62	✗
63	✗
64	✗
65	✗
66	✗
67	✗
68	✗
69	✗
70	✗
71	✗
72	✗
73	✗
74	✗
75	✓
76	✗
77	✗
78	✗
79	✓
80	✗
81	✗
82	✓
83	✗
84	✗
85	✗
86	✗
87	✗
88	✗
89	✗
90	✗
91	✗
92	✗
93	✓
94	✗

95	✓
96	✗
97	✗
98	✗
99	✗
100	✗
101	✗
102	✗
103	✓
104	✗
105	✗
106	✓
107	✗
108	✗
109	✗
110	✗
111	-

All contents of this site are © 2024 Passmedicine Limited

A 54-year-old male is reviewed in the respiratory clinic. He originally presented with progressive shortness of breath and a dry cough, while having no other significant history or exposure to chemicals or environmental triggers. He is a non-smoker and does not take any medications.

Examination is consistent with bibasal inspiratory crackles and there is evident clubbing. There is no signs of cardiac failure. He currently saturates at 94% on air and has a known FVC of 70% measured at his last appointment.

His pulmonary function test reveals a restrictive pattern and a high resolution CT is undertaken concluding:
'Bilateral lung volume loss with >5% honeycombing extensively at the bases and subpleural areas with evidence of peripheral traction bronchiectasis, extensively at the lung bases'.

Prior blood investigations have been negative with regards to any connective tissue disease.

He has already been referred for pulmonary rehabilitation but is wondering whether any medication could potentially alter the course of his disease.

Which medication can be used to reduce functional decline in this group of patients?

- Azathioprine
- Sildenafil
- Prednisolone
- Bosentan
- Pirfenidone

Submit answer

Reference ranges

Score: **16%**

1	✗
2	✗
3	✗
4	✗
5	✗
6	✗
7	✗
8	✗
9	✗
10	✗
11	✗
12	✓
13	✗
14	✗
15	✗
16	✗
17	✗
18	✗
19	✗
20	✗
21	✗
22	✗
23	✓
24	✗
25	✗
26	✗
27	✗
28	✗
29	✓
30	✗
31	✓
32	✗
33	✗

34	✗
35	✗
36	✓
37	✓
38	✗
39	✗
40	✗
41	✓
42	✗
43	✗
44	✗
45	✗
46	✗
47	✗
48	✗
49	✓
50	✗
51	-
52	-
53	-
54	-
55	-
56	-
57	-
58	-

All contents of this site are © 2024 Passmedicine Limited

Back to top

A 54-year-old male is reviewed in the respiratory clinic. He originally presented with progressive shortness of breath and a dry cough, while having no other significant history or exposure to chemicals or environmental triggers. He is a non-smoker and does not take any medications.

Examination is consistent with bibasal inspiratory crackles and there is evident clubbing. There is no signs of cardiac failure. He currently saturates at 94% on air and has a known FVC of 70% measured at his last appointment.

His pulmonary function test reveals a restrictive pattern and a high resolution CT is undertaken concluding:
'Bilateral lung volume loss with >5% honeycombing extensively at the bases and subpleural areas with evidence of peripheral traction bronchiectasis, extensively at the lung bases'.

Prior blood investigations have been negative with regards to any connective tissue disease.

He has already been referred for pulmonary rehabilitation but is wondering whether any medication could potentially alter the course of his disease.

Which medication can be used to reduce functional decline in this group of patients?

Azathioprine	3%
Sildenafil	2%
Prednisolone	4%
Bosentan	4%
Pirfenidone	87%

Pirfenidone and nintedanib can be used as drug management options in idiopathic pulmonary fibrosis as they may decrease the functional decline, prolong survival and potentially reduce acute exacerbations

Important for me Less important

The patient in question suffers from idiopathic pulmonary fibrosis (usually interstitial pneumonia type) as evident by the restrictive pattern, lack of history suggestive of other causes of fibrosis

alongside the pathognomonic CT features. Therefore the question really focuses on the pharmacological management of this disease bearing in mind its irreversible nature.

Pirfenidone and nintedanib are two antifibrotic agents currently licensed for use in the UK provided the forced vital capacity (FVC) between 50% and 80% predicted given the evidence in literature currently.

Sildenafil is a phosphodiesterase-5-inhibitor that has been trialled in such patients in order to examine the potential of improved oxygen delivery; a study in 2010 concluded that there was no potential benefit in the use of sildenafil in such patients, except where pulmonary hypertension exists.

Prednisolone and steroid use in patients with idiopathic pulmonary fibrosis as a disease modifier has not been proven to be beneficial.

Bosentan is a dual endothelin receptor antagonist that is currently licensed for the treatment of pulmonary arterial hypertension. As per the BUILD-3 trial, the use of bosentan does not delay idiopathic pulmonary fibrosis progression or death.

Azathioprine is a purine analogue which is used in a variety of autoimmune conditions. It has been used extensively in the past in caring for patients with idiopathic pulmonary fibrosis as part of the triple therapy of prednisolone/azathioprine/N-acetylcysteine; however due to PANTHER-IPF study and the increased hospitalisation of patients with side-effects of immunosuppression the study has been put on hold and this treatment is encouraged to be avoided.

Discuss (2) Improve

Next question

Idiopathic pulmonary fibrosis

Idiopathic pulmonary fibrosis (IPF, previously termed cryptogenic fibrosing alveolitis) is a chronic lung condition characterised by progressive fibrosis of the interstitium of the lungs. Whilst there are many causes of lung fibrosis (e.g. medications, connective tissue disease, asbestos) the term IPF is reserved when no underlying cause exists.

IPF is typically seen in patients aged 50-70 years and is twice as common in men.

Features

- progressive exertional dyspnoea
- bibasal fine end-inspiratory crepitations on auscultation

- dry cough
- clubbing

Diagnosis

- spirometry: classically a restrictive picture (FEV1 normal/decreased, FVC decreased, FEV1/FVC increased)
- impaired gas exchange: reduced transfer factor (TLCO)
- imaging: bilateral interstitial shadowing (typically small, irregular, peripheral opacities - 'ground-glass' - later progressing to 'honeycombing') may be seen on a chest x-ray but high-resolution CT scanning is the investigation of choice and required to make a diagnosis of IPF
- ANA positive in 30%, rheumatoid factor positive in 10% but this does not necessarily mean that the fibrosis is secondary to a connective tissue disease. Titres are usually low

Management

- pulmonary rehabilitation
- very few medications have been shown to give any benefit in IPF. There is some evidence that pirfenidone (an antifibrotic agent) may be useful in selected patients (see NICE guidelines)
- many patients will require supplementary oxygen and eventually a lung transplant

Prognosis

- poor, average life expectancy is around 3-4 years

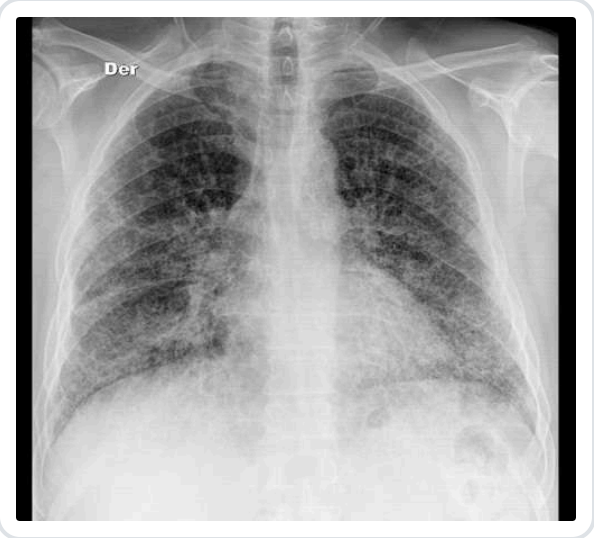

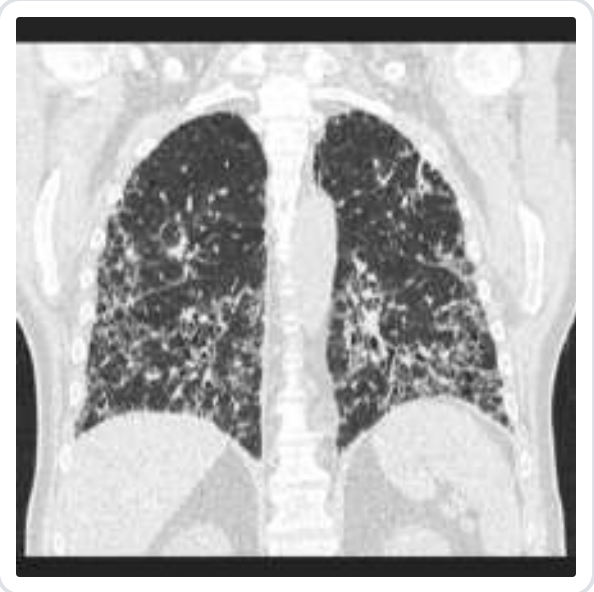

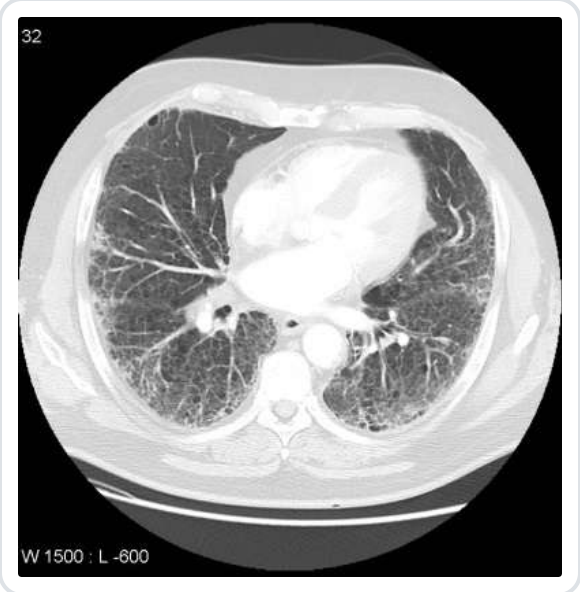

123

Next question

Textbooks

High-yield textbook

Extended textbook

Links

Royal College of Physicians 13 10

Update in diagnosis and management of interstitial lung disease

NICE 11 6

2013 Idiopathic pulmonary fibrosis guidelines

Suggest link Report broken link

Media

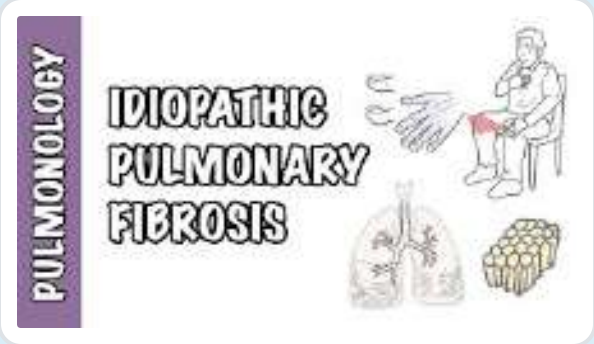

Idiopathic pulmonary fibrosis

Armando Hasudungan - YouTube 6 0

Interstitial Lung Disease (ILD) - Classification, pathophysiology, signs and symptoms

Armando Hasudungan - YouTube 5 0

Idiopathic pulmonary fibrosis

Osmosis - YouTube

4 0

Report broken media

Score: **17.3%**

1	✗
2	✗
3	✗
4	✗
5	✗
6	✗
7	✗
8	✗
9	✗
10	✗
11	✗
12	✓
13	✗
14	✗
15	✗
16	✗
17	✗
18	✗
19	✗
20	✗
21	✗
22	✗
23	✓
24	✗
25	✗
26	✗
27	✗
28	✗

29	✓
30	✗
31	✓
32	✗
33	✗
34	✗
35	✗
36	✓
37	✓
38	✗
39	✗
40	✗
41	✓
42	✗
43	✗
44	✗
45	✗
46	✗
47	✗
48	✗
49	✓
50	✗
51	✗
52	✓
53	✗
54	✗
55	✓
56	✗
57	✗
58	✓
59	✗
60	✓
61	✗
62	✗
63	✗
64	✗

65	✗
66	✗
67	✗
68	✗
69	✗
70	✗
71	✗
72	✗
73	✗
74	✗
75	✓
76	✗
77	✗
78	✗
79	✓
80	✗
81	✗
82	✓
83	✗
84	✗
85	✗
86	✗
87	✗
88	✗
89	✗
90	✗
91	✗
92	✗
93	✓
94	✗
95	✓
96	✗
97	✗
98	✗
99	✗
100	✗

101	✗
102	✗
103	✓
104	✗
105	✗
106	✓
107	✗
108	✗
109	✗
110	✗
111	-

All contents of this site are © 2024 Passmedicine Limited

Back to top

A 24-year-old male is reviewed on the trauma ward 5 days after a road traffic collision. He suffered multiple injuries most significant of which included an extradural haematoma, right-sided pneumothorax, and a femoral fracture. The patient was initially intubated, had a chest drain inserted, and underwent intramedullary nailing. The extradural haematoma was managed conservatively.

The patient was successfully extubated 3 days ago and has had his oxygen requirements progressively weaned. Today on the ward round the patient reports his breathing is improving but he has still some dyspnoea on exertion and is requiring 2L via nasal prongs. The chest drain is swinging and has on-off bubbling. There is good air entry heard throughout the chest.

What is the most appropriate course of action?

- Apply suction to the drain
- Remove the chest drain
- Reposition the drain and increase the patient oxygen delivery
- Seek a thoracic surgical opinion
- Leave the drain in situ and review in 24 hours

Submit answer

Reference ranges

Score: **16%**

1 ✗
2 ✗
3 ✗

4	✗
5	✗
6	✗
7	✗
8	✗
9	✗
10	✗
11	✗
12	✓
13	✗
14	✗
15	✗
16	✗
17	✗
18	✗
19	✗
20	✗
21	✗
22	✗
23	✓
24	✗
25	✗
26	✗
27	✗
28	✗
29	✓
30	✗
31	✓
32	✗
33	✗
34	✗
35	✗
36	✓
37	✓
38	✗
39	✗

40	✗
41	✓
42	✗
43	✗
44	✗
45	✗
46	✗
47	✗
48	✗
49	✓
50	✗
51	-
52	-
53	-
54	-
55	-
56	-
57	-
58	-
59	-

All contents of this site are © 2024 Passmedicine Limited

Back to top

A 24-year-old male is reviewed on the trauma ward 5 days after a road traffic collision. He suffered multiple injuries most significant of which included an extradural haematoma, right-sided pneumothorax, and a femoral fracture. The patient was initially intubated, had a chest drain inserted, and underwent intramedullary nailing. The extradural haematoma was managed conservatively.

The patient was successfully extubated 3 days ago and has had his oxygen requirements progressively weaned. Today on the ward round the patient reports his breathing is improving but he has still some dyspnoea on exertion and is requiring 2L via nasal prongs. The chest drain is swinging and has on-off bubbling. There is good air entry heard throughout the chest.

What is the most appropriate course of action?

Apply suction to the drain	8%
Remove the chest drain	5%
Reposition the drain and increase the patient oxygen delivery	9%
Seek a thoracic surgical opinion	54%
Leave the drain in situ and review in 24 hours	23%

When draining a pneumothorax, if after 3-5 days there is persistent air leak (e.g. bubbling chest drain) or failure of the lung to re-expand, a thoracic surgical opinion should be sought

Important for me Less important

Seeking a thoracic surgical opinion is correct as although the patient has improved initially, it has now been 5 days since the chest drain was inserted and there is still an ongoing persistent air leak with the chest drain bubbling. Further management may now be required in the form of pleurodesis or surgical resection etc.

Applying suction to chest drains is controversial and should not be used unless under specialist guidance. The persistent air leak requires a thoracic surgical opinion.

Removing the chest drain is incorrect as there is evidence of ongoing persistent air leak and therefore non-resolution of the pulmonary pathology.

Repositing of the drain is incorrect as there is no evidence that the drain has moved or become displaced. Oxygen delivery can assist resolve a pneumothorax however as it has been over 5 days further management may be required.

The drain could be left in situ and review in 24 hours however it has already been 5 days since it was originally inserted and there is evidence of a persistent leak and therefore surgical opinion should be sought.

Discuss (3) | Improve

Next question

Pneumothorax: management

The British Thoracic Society (BTS) published updated guidelines for the management of spontaneous pneumothorax in 2023.

The updated guidelines put less emphasis on the size of the pneumothorax and more emphasis on whether the patient is symptomatic and the presence of high-risk characteristics.

Decision algorithm

The first step is assessing whether the patient is symptomatic
- the BTS define minimal symptoms as '*no significant pain or breathlessness and no physiological compromise*'
- no or minimal symptoms → conservative care, regardless of pneumothorax size
- symptomatic → assess for high-risk characteristics

If a pneumothorax is symptomatic, the next step is assessment for high-risk characteristics
- high-risk characteristics are defined as follows:
  - haemodynamic compromise (suggesting a tension pneumothorax)
  - significant hypoxia
  - bilateral pneumothorax
  - underlying lung disease
  - ≥ 50 years of age with significant smoking history
  - haemothorax
- if no high-risk characteristics are present, and it is safe to intervene, then there is a choice of intervention:
  - conservative care

    - ambulatory device
    - needle aspiration
- if high-risk characteristics are present, and it is safe to intervene → chest drain

How is safety or intervention determined?

- before a needle aspiration/chest drain insertion, the safety of intervention should be assessed
- this depends on the clinical context, but is usually:
    - 2cm laterally or apically on chest x-ray, or
    - any size on CT scan which can be safely accessed with radiological support

Management options

Conservative care

- patients with a primary spontaneous pneumothorax that is managed conservatively should be reviewed every 2-4 days as an outpatient
- patients with a secondary spontaneous pneumothorax that is managed conservatively should be monitored as an inpatient
- if stable, follow-up in the outpatients department in 2-4 weeks

Ambulatory care

- an example of an ambulatory device is the Rocketµ Pleural Vent„
- it includes an 8FG catheter mounted on an 18G needle and a pigtail catheter to minimize the risk of occlusion
- ambulatory devices typically have a one-way valve and vent to prevent air and fluid return to the pleural space while allowing for controlled escape of air and drainage of fluid
- many devices also have an indication diaphragm that signals when the catheter tip enters the pleural space and continues to fluctuate with respiration, aiding in the assessment of pneumothorax resolution

Needle aspiration

- a chest drain should be inserted if needle aspiration of a pneumothorax is unsuccessful
- if resolved, discharge and follow-up in the outpatients department in 2-4 weeks

Chest drain insertion

- daily review as an inpatient
- remove drain when resolved
- discharge and follow-up in the outpatients department in 2-4 weeks

Persistentent / recurrent pneumothorax

If a patient has a persistent air leak or insufficient lung reexpansion despite chest drain insertion, or the patient has recurrent pneumothoraces, then video-assisted thoracoscopic surgery (VATS) should be considered to allow for mechanical/chemical pleurodesis +/- bullectomy.

Discharge advice

Smoking

- patients should be advised to avoid smoking to reduce the risk of further episodes - the lifetime risk of developing a pneumothorax in healthy smoking men is around 10% compared with around 0.1% in non-smoking men

Fitness to fly

- absolute contraindication, the CAA suggest patients may travel 2 weeks after successful drainage if there is no residual air. The British Thoracic Society used to recommend not travelling by air for a period of 6 weeks but this has now been changed to 1 week post check x-ray

Scuba diving

- the BTS guidelines state: '*Diving should be permanently avoided unless the patient has undergone bilateral surgical pleurectomy and has normal lung function and chest CT scan postoperatively.*'

Image gallery

123

Next question

Textbooks

High-yield textbook

Extended textbook

Links

British Thoracic Society

2 1

2023 Pleural disease guidelines

Suggest link

Report broken link

Media

How to identify pneumothorax on a chest X-ray

Medmastery - YouTube 30 1

Pneumothorax

Zero To Finals - YouTube 9 1

Pneumothorax

Osmosis - YouTube 6 1

Needle Aspiration of Pneumothorax

NEJM - YouTube 10 6

Report broken media

Score: **17.3%**

1 ✗
2 ✗
3 ✗
4 ✗
5 ✗
6 ✗
7 ✗
8 ✗

9	✗
10	✗
11	✗
12	✓
13	✗
14	✗
15	✗
16	✗
17	✗
18	✗
19	✗
20	✗
21	✗
22	✗
23	✓
24	✗
25	✗
26	✗
27	✗
28	✗
29	✓
30	✗
31	✓
32	✗
33	✗
34	✗
35	✗
36	✓
37	✓
38	✗
39	✗
40	✗
41	✓
42	✗
43	✗
44	✗

45	✗
46	✗
47	✗
48	✗
49	✓
50	✗
51	✗
52	✓
53	✗
54	✗
55	✓
56	✗
57	✗
58	✓
59	✗
60	✓
61	✗
62	✗
63	✗
64	✗
65	✗
66	✗
67	✗
68	✗
69	✗
70	✗
71	✗
72	✗
73	✗
74	✗
75	✓
76	✗
77	✗
78	✗
79	✓
80	✗

81	✗
82	✓
83	✗
84	✗
85	✗
86	✗
87	✗
88	✗
89	✗
90	✗
91	✗
92	✗
93	✓
94	✗
95	✓
96	✗
97	✗
98	✗
99	✗
100	✗
101	✗
102	✗
103	✓
104	✗
105	✗
106	✓
107	✗
108	✗
109	✗
110	✗
111	-

All contents of this site are © 2024 Passmedicine Limited

Back to top

An 82-year-old gentleman with known chronic obstructive airways disease (COPD) is about to be discharged from hospital after being admitted with an infective exacerbation. He is now off antibiotics and has just completed a seven-day course of prednisolone. He remains hypoxic on room air S_a0_2 91%.

Bloods show:

Hb	134 g/l
Platelets	$350 * 10^9$/l
WBC	$10.2 * 10^9$/l

Arterial blood gas analysis shows:

P_a0_2	7.8 kPa
P_aCO_2	6.5 kPa
HCO_3^-	30 mmol/L

The patient's wife asked about having oxygen at home. What other investigations are needed to assess whether this patient would benefit from long-term oxygen therapy?

- Oxygen saturations before and after exercise
- Pulmonary function tests
- Computed tomography (CT) of the chest
- Chest x-ray
- Echocardiogram

Submit answer

Reference ranges

Score: **16%**

1	✗
2	✗
3	✗
4	✗
5	✗
6	✗
7	✗
8	✗
9	✗
10	✗
11	✗
12	✓
13	✗
14	✗
15	✗
16	✗
17	✗
18	✗
19	✗
20	✗
21	✗
22	✗
23	✓
24	✗
25	✗
26	✗
27	✗
28	✗
29	✓
30	✗
31	✓
32	✗
33	✗

34	✗
35	✗
36	✓
37	✓
38	✗
39	✗
40	✗
41	✓
42	✗
43	✗
44	✗
45	✗
46	✗
47	✗
48	✗
49	✓
50	✗
51	-
52	-
53	-
54	-
55	-
56	-
57	-
58	-
59	-
60	-

All contents of this site are © 2024 Passmedicine Limited

An 82-year-old gentleman with known chronic obstructive airways disease (COPD) is about to be discharged from hospital after being admitted with an infective exacerbation. He is now off antibiotics and has just completed a seven-day course of prednisolone. He remains hypoxic on room air S_a0_2 91%.

Bloods show:

Hb	134 g/l
Platelets	350 * 10^9/l
WBC	10.2 * 10^9/l

Arterial blood gas analysis shows:

P_a0_2	7.8 kPa
P_aCO_2	6.5 kPa
HCO_3^-	30 mmol/L

The patient's wife asked about having oxygen at home. What other investigations are needed to assess whether this patient would benefit from long-term oxygen therapy?

- Oxygen saturations before and after exercise 19%
- Pulmonary function tests 31%
- Computed tomography (CT) of the chest 3%
- Chest x-ray 3%
- Echocardiogram 44%

Long-term oxygen therapy (LTOT) refers to the prolonged domiciliary use of oxygen for patients with medical conditions that result in a state of chronic hypoxaemia (P_a0_2 at or below 7.3kPa). The patient is assessed so that the flow rate of oxygen they receive results in a waking oxygen tension above 8kPa. LTOT is usually prescribed indefinitely and to be of benefit has to be used for a minimum of 15 hours a day including at night time.

The indications for LTOT are well established. The British Thoracic Society (BTS) advises that LTOT may be of benefit in patients with the following conditions:

- Chronic obstructive pulmonary disease
- Severe chronic asthma
- Interstitial lung disease
- Cystic fibrosis
- Bronchiectasis
- Pulmonary vascular disease
- Primary pulmonary hypertension
- Pulmonary malignancy
- Chronic heart failure

Patients with any of the above conditions can be assessed to see if they would benefit from LTOT. BTS guidelines currently state that patients should have a P_a0_2 consistently at or below 7.3kPa on air at a time when they are clinically stable (absence of exacerbation in previous five weeks).

Another group of patients who can be prescribed LTOT are those with chronic hypoxaemia and a P_a0_2 between 7.3kPa and 8kPa and the presence of either secondary polycythaemia or clinical and/or echocardiographic evidence of pulmonary hypertension.

In the above case, the patient has chronic hypoxaemia. Ideally, this patient would have his arterial blood gases analysed five weeks following this exacerbation, but assuming that his results are similar and his haemoglobin remains the same then he would require evidence of pulmonary hypertension to benefit from LTOT thus an echocardiogram is the best answer to this question.

Discuss (5) Improve

Next question

COPD: long-term oxygen therapy

The 2018 NICE guidelines on COPD clearly define which patients should be assessed for and offered long-term oxygen therapy (LTOT). Patients who receive LTOT should breathe supplementary oxygen for at least 15 hours a day. Oxygen concentrators are used to provide a fixed supply for LTOT.

Assess patients if any of the following:

- very severe airflow obstruction (FEV1 < 30% predicted). Assessment should be 'considered' for patients with severe airflow obstruction (FEV1 30-49% predicted)

- cyanosis
- polycythaemia
- peripheral oedema
- raised jugular venous pressure
- oxygen saturations less than or equal to 92% on room air

Assessment is done by measuring arterial blood gases on 2 occasions at least 3 weeks apart in patients with stable COPD on optimal management.

Offer LTOT to patients with a pO2 of < 7.3 kPa or to those with a pO2 of 7.3 - 8 kPa and one of the following:

- secondary polycythaemia
- peripheral oedema
- pulmonary hypertension

In terms of smoking, NICE advise the following:

- do not offer LTOT to people who continue to smoke despite being offered smoking cessation advice and treatment, and referral to specialist stop smoking services.

NICE suggest that a structured risk assessment is carried out before offering LTOT, including:

- the risks of falls from tripping over the equipment
- the risks of burns and fires, and the increased risk of these for people who live in homes where someone smokes (including e-cigarettes)

+ Q 123

Next question >

Textbooks

High-yield textbook

Extended textbook

Links

NICE

2018 COPD guidelines

17 6

Suggest link

Report broken link

Score: **17.3%**

1	✗
2	✗
3	✗
4	✗
5	✗
6	✗
7	✗
8	✗
9	✗
10	✗
11	✗
12	✓
13	✗
14	✗
15	✗
16	✗
17	✗
18	✗
19	✗
20	✗
21	✗
22	✗

23	✓
24	✗
25	✗
26	✗
27	✗
28	✗
29	✓
30	✗
31	✓
32	✗
33	✗
34	✗
35	✗
36	✓
37	✓
38	✗
39	✗
40	✗
41	✓
42	✗
43	✗
44	✗
45	✗
46	✗
47	✗
48	✗
49	✓
50	✗
51	✗
52	✓
53	✗
54	✗
55	✓
56	✗
57	✗
58	✓

59	✗
60	✓
61	✗
62	✗
63	✗
64	✗
65	✗
66	✗
67	✗
68	✗
69	✗
70	✗
71	✗
72	✗
73	✗
74	✗
75	✓
76	✗
77	✗
78	✗
79	✓
80	✗
81	✗
82	✓
83	✗
84	✗
85	✗
86	✗
87	✗
88	✗
89	✗
90	✗
91	✗
92	✗
93	✓
94	✗

95	✓
96	✗
97	✗
98	✗
99	✗
100	✗
101	✗
102	✗
103	✓
104	✗
105	✗
106	✓
107	✗
108	✗
109	✗
110	✗
111	-

All contents of this site are © 2024 Passmedicine Limited

A 62-year-old man with metastatic small cell lung cancer is admitted with a shortness of breath, cough and purulent sputum.

His chest x-ray shows a right lower lobe pneumonia with partial collapse of the right lung. He has a bulky primary tumour at the right hilum and extensive hilar lymphadenopathy.

He is treated with IV antibiotics, fluids and oxygen. His symptoms improve over the next 5 days and his breathing is comfortable on 2 litres of oxygen via nasal cannulae. His pain is controlled on 20mg long-acting morphine sulphate twice daily. The decision is made to discharge him to a hospice for end-of-life care. However, due to the proximity of his lung tumour to major vessels, he is at risk of a major terminal bleed.

Which medication should the hospice be advised to give in the event of a major bleed?

- Haloperidol
- Midazolam
- Morphine
- Tranexamic acid
- Vitamin K

Submit answer

Reference ranges

Score: **16%**

1 ✕
2 ✕

3	✗
4	✗
5	✗
6	✗
7	✗
8	✗
9	✗
10	✗
11	✗
12	✓
13	✗
14	✗
15	✗
16	✗
17	✗
18	✗
19	✗
20	✗
21	✗
22	✗
23	✓
24	✗
25	✗
26	✗
27	✗
28	✗
29	✓
30	✗
31	✓
32	✗
33	✗
34	✗
35	✗
36	✓
37	✓
38	✗

39	✗
40	✗
41	✓
42	✗
43	✗
44	✗
45	✗
46	✗
47	✗
48	✗
49	✓
50	✗
51	-
52	-
53	-
54	-
55	-
56	-
57	-
58	-
59	-
60	-
61	-

All contents of this site are © 2024 Passmedicine Limited

Back to top

A 62-year-old man with metastatic small cell lung cancer is admitted with a shortness of breath, cough and purulent sputum.

His chest x-ray shows a right lower lobe pneumonia with partial collapse of the right lung. He has a bulky primary tumour at the right hilum and extensive hilar lymphadenopathy.

He is treated with IV antibiotics, fluids and oxygen. His symptoms improve over the next 5 days and his breathing is comfortable on 2 litres of oxygen via nasal cannulae. His pain is controlled on 20mg long-acting morphine sulphate twice daily. The decision is made to discharge him to a hospice for end-of-life care. However, due to the proximity of his lung tumour to major vessels, he is at risk of a major terminal bleed.

Which medication should the hospice be advised to give in the event of a major bleed?

Haloperidol	3%
Midazolam	51%
Morphine	6%
Tranexamic acid	35%
Vitamin K	5%

This patient may experience a terminal catastrophic bleed due to erosion of his lung tumour through a major vessel. Patients at risk of such an event should be issued with a 'crisis pack' containing midazolam and green or blue towels which can help soak up blood whilst masking some of the colour. Midazolam can be administered intravenously if access available or otherwise intramuscularly. The aim is to minimise the anxiety and distress.

Haloperidol is a useful anxiolytic and antiemetic in end-of-life care but is not as effective in this situation. Morphine is used for pain and breathlessness in the terminal setting.

Tranexamic acid may be given is cases of slow gastrointestinal bleeding due to malignancy. Vitamin K is used to lower the INR in patients with a bleed on warfarin or with liver failure.

Reference:

Ian Back. Palliative Care Guidelines - Bleeding and Haemorrhage. 2011. Available online at: http://book.pallcare.info/index.php?tid=78

Discuss (11) Improve

Next question

Lung cancer: management

Around 13% of those diagnosed with cancer in the UK will have lung carcinoma. Of those diagnosed with lung cancer, approximately 75% will be found to have stage III/IV disease at presentation, which has huge implications on the management options available to these patients.

Lung cancer is histologically subdivided as follows:

- **Non-small cell carcinoma (NSCLC):** accounts for 85% of all lung cancers and can be further subdivided into squamous cell carcinoma, adenocarcinoma, and large cell carcinoma
- **Small cell carcinoma (SCLC):** accounts for 15% of all lung cancers. SCLC is typically more aggressive and carries a worse prognosis

The histological subtype is clinically important as the approach to management differs between NSCLC and SCLC. Treatment is also dependant upon the disease stage and patient fitness.

General management principles

- **Multi-disciplinary team (MDT):** All patients with suspected or confirmed lung cancer should be discussed at an MDT to formulate an effective treatment plan
- **Smoking Cessation:** For both subtypes of lung cancer, smoking cessation should be encouraged and supported. Patients should be informed that by stopping smoking they are increasing their chances of successful treatment and survival. To help patients stop smoking offer nicotine replacement therapy and refer to smoking cessation services

NSCLC Management

Surgical resection:

- Lobectomy (with hilar and mediastinal lymph node resection/sampling) is first-line treatment for those with stage I or II cancer who are medically fit for surgery
- This surgery is done with curative intent

Radiotherapy:

- Is first-line for those with stage I-III disease who are not suitable for surgery.
- This treatment is given with curative intent.

Chemotherapy:

- Is offered to those with stage III or IV disease to improve survival and quality of life.
- First line regimes use a combination of:
  - Third-generation chemotherapy agent: e.g. docetaxel, paclitaxel or gemcitabine
  - Platinum agent: e.g. carboplatin or cisplatin

Combination therapy:

- Adjuvant chemotherapy should be offered to patients who have undergone a **complete resection**
- Adjuvant radiotherapy is offered to patients who have had a **incomplete resection** of their tumour
- All patients with stage I-III disease who are not suitable for surgery should be considered for chemoradiotherapy

SCLC Management

Surgery is rarely used and only considered in very early stage I disease - SCLC is disseminated at presentation in almost all patients. The majority of SCLC patients are treated with chemotherapy in combination with radiotherapy.

Limited-stage SCLC:

- Limited-stage disease is defined as SCLC without distant metastasis (T1-4, N0-3, M0).
- First-line treatment involves:
  - 4-6 cycles of Cisplatin-based combination chemotherapy
  - Concurrent or adjunct thoracic radiotherapy is only considered if there has been a good response to chemotherapy

Extensive-stage SCLC:

- Extensive-stage disease is defined as SCLC with distant metastasis (T1-4, N0-3, M1).
- First-line treatment involves:

+ Platinum-based combination therapy where the patient is reassessed for a response after each cycle (up to a maximum of 6 cycles)

- Concurrent or adjunct thoracic radiotherapy can be considered if there has been a good response to chemotherapy at both the primary and metastatic sites.

Relapse after initial treatment:

- For all stages of SCLC second-line therapy can be considered in those who have relapsed. This includes:
  - Further chemotherapy (maximum 6 cycles)
  - Palliative radiotherapy to control local symptoms

Palliative care

All patients with NSCLC and SCLC who cannot be offered curative treatment should be referred to palliative care. Therapy can involve:

- Palliative radiotherapy for symptom control
- Endobronchial stenting or debulking for bronchial obstruction
- Pleural drainage or aspiration for pleural effusion
- Dexamethasone therapy for those with symptomatic brain metastasis
- Opioid therapy to relieve cough and breathlessness

Complications

- **Local disease spread:** nerve palsy; superior vena cava obstruction and pericarditis
- **Metastatic spread:** Brain, spinal cord, bone, liver and adrenal glands are common sites

Prognosis

- SCLC has a worse prognosis when compared to NSCLC
- 5-year survival is around 10%

AI + Q 123

Next question >

Textbooks

High-yield textbook

Extended textbook

Links

Radiopaedia 1 0

Lung cancer review

NICE 0 0

2011 Lung cancer: diagnosis and management

Suggest link

Report broken link

Media

Lung cancer

MedFlix - YouTube 2 0

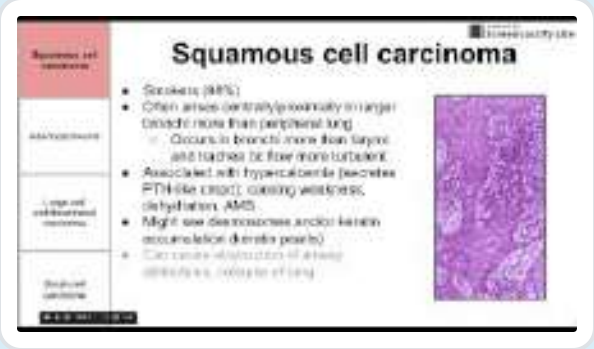

Cancers of the lung

MedLecturesMadeEasy - YouTube 1 1

Lung Cancer: An Overview

Oncology for Medical Students - YouTube 1 1

Report broken media

Score: **17.3%**

1	✗
2	✗
3	✗
4	✗
5	✗
6	✗
7	✗
8	✗
9	✗
10	✗
11	✗
12	✓
13	✗
14	✗
15	✗
16	✗
17	✗
18	✗
19	✗
20	✗
21	✗
22	✗
23	✓
24	✗
25	✗
26	✗
27	✗
28	✗
29	✓
30	✗

31	✓
32	✗
33	✗
34	✗
35	✗
36	✓
37	✓
38	✗
39	✗
40	✗
41	✓
42	✗
43	✗
44	✗
45	✗
46	✗
47	✗
48	✗
49	✓
50	✗
51	✗
52	✓
53	✗
54	✗
55	✓
56	✗
57	✗
58	✓
59	✗
60	✓
61	✗
62	✗
63	✗
64	✗
65	✗
66	✗

67	✗
68	✗
69	✗
70	✗
71	✗
72	✗
73	✗
74	✗
75	✓
76	✗
77	✗
78	✗
79	✓
80	✗
81	✗
82	✓
83	✗
84	✗
85	✗
86	✗
87	✗
88	✗
89	✗
90	✗
91	✗
92	✗
93	✓
94	✗
95	✓
96	✗
97	✗
98	✗
99	✗
100	✗
101	✗
102	✗

103	✓
104	✗
105	✗
106	✓
107	✗
108	✗
109	✗
110	✗
111	-

All contents of this site are © 2024 Passmedicine Limited

A 38-year-old woman is referred to the respiratory clinic due to a pulmonary nodule detected on a CT scan. She was admitted to her local hospital two months ago with aspiration pneumonia and treated with intravenous antibiotics. A chest X-ray demonstrated left-sided consolidation. She was also managed for alcohol withdrawal. She required three days of in hospital before being discharged with oral antibiotics and community alcohol liaison services to follow-up. Her GP repeated her chest X-ray six weeks following discharge and was concerned that an area of consolidation remained on the repeat chest X-ray. The GP, therefore, arranged for a CT chest which demonstrated a pulmonary nodule 5mm in diameter on the right side. There was no evidence of consolidation. How should this nodule be investigated or monitored?

- Urgent CT-PET
- Urgent image-guided biopsy
- CT chest in three months
- CT chest in one year
- No further investigations needed

Submit answer

Reference ranges

Score: **16%**

1	✕
2	✕
3	✕
4	✕
5	✕

6	✗
7	✗
8	✗
9	✗
10	✗
11	✗
12	✓
13	✗
14	✗
15	✗
16	✗
17	✗
18	✗
19	✗
20	✗
21	✗
22	✗
23	✓
24	✗
25	✗
26	✗
27	✗
28	✗
29	✓
30	✗
31	✓
32	✗
33	✗
34	✗
35	✗
36	✓
37	✓
38	✗
39	✗
40	✗
41	✓

42	✗
43	✗
44	✗
45	✗
46	✗
47	✗
48	✗
49	✓
50	✗
51	-
52	-
53	-
54	-
55	-
56	-
57	-
58	-
59	-
60	-
61	-
62	-

All contents of this site are © 2024 Passmedicine Limited

A 38-year-old woman is referred to the respiratory clinic due to a pulmonary nodule detected on a CT scan. She was admitted to her local hospital two months ago with aspiration pneumonia and treated with intravenous antibiotics. A chest X-ray demonstrated left-sided consolidation. She was also managed for alcohol withdrawal. She required three days of in hospital before being discharged with oral antibiotics and community alcohol liaison services to follow-up. Her GP repeated her chest X-ray six weeks following discharge and was concerned that an area of consolidation remained on the repeat chest X-ray. The GP, therefore, arranged for a CT chest which demonstrated a pulmonary nodule 5mm in diameter on the right side. There was no evidence of consolidation. How should this nodule be investigated or monitored?

Urgent CT-PET	3%
Urgent image-guided biopsy	6%
CT chest in three months	21%
CT chest in one year	42%
No further investigations needed	27%

The correct answer is CT chest in one year. As the patient has a pulmonary nodule 5mm in size there will need to be further monitoring. As it is 5-6mm in size this means that monitoring should take form in terms of a CT scan in one year.

Discuss (5) Improve

Next question

Solitary lung nodule

BTS guidelines for lung nodules:

- Nodule <5mm, or clear benign features, or unsuitable for treatment: can be discharged
- Nodule =>8mm and high risk*: then CT-PET, and if CT-PET shows high uptake then biopsy
- Nodule 5-6mm, or =>8mm and low-risk*: then CT surveillance
- CT surveillance: if 5-6mm then at 1 year, if =>6 then in three months

*To determine the risk of malignancy following CT the BTS uses the Brock model

AI + Q 123

Next question >

B I A

Textbooks

High-yield textbook

Extended textbook

Score: **17.3%**

1	✗
2	✗
3	✗
4	✗
5	✗
6	✗
7	✗
8	✗
9	✗
10	✗
11	✗
12	✓
13	✗

14	✗
15	✗
16	✗
17	✗
18	✗
19	✗
20	✗
21	✗
22	✗
23	✓
24	✗
25	✗
26	✗
27	✗
28	✗
29	✓
30	✗
31	✓
32	✗
33	✗
34	✗
35	✗
36	✓
37	✓
38	✗
39	✗
40	✗
41	✓
42	✗
43	✗
44	✗
45	✗
46	✗
47	✗
48	✗
49	✓

50	✗
51	✗
52	✓
53	✗
54	✗
55	✓
56	✗
57	✗
58	✓
59	✗
60	✓
61	✗
62	✗
63	✗
64	✗
65	✗
66	✗
67	✗
68	✗
69	✗
70	✗
71	✗
72	✗
73	✗
74	✗
75	✓
76	✗
77	✗
78	✗
79	✓
80	✗
81	✗
82	✓
83	✗
84	✗
85	✗

86	✗
87	✗
88	✗
89	✗
90	✗
91	✗
92	✗
93	✓
94	✗
95	✓
96	✗
97	✗
98	✗
99	✗
100	✗
101	✗
102	✗
103	✓
104	✗
105	✗
106	✓
107	✗
108	✗
109	✗
110	✗
111	-

All contents of this site are © 2024 Passmedicine Limited

Back to top

An 83-year-old man attends hospital with an infective exacerbation of COPD. He had become increasingly short of breath with an episode of rigors and a dry cough. He is started on salbutamol and ipratropium nebulisers and steroids but fails to improve clinically. After careful discussion, he is offered non invasive ventilation and he tolerates this well. He is slow to improve and 36 hours later, he starts to become more breathless.

On examination, he has crackles and wheeze on the right hemithorax. The left hemithorax has reduced air entry throughout and is resonant to percuss. There are no added sounds., no JVP or leg oedema that can be seen but there is accessory muscle use. He is tired and feels 'absolutely awful'. The non-invasive ventilation is currently set at IPAP 26 cm H2O and EPAP 6 cm H2O. The mask is well adjusted and there is no significant mask leak. A repeat chest x-ray is pending.

Chest X-ray (on admission): hyperinflation, no consolidation seen

ABG (admission)

pH	7.32
PaO2	7.6kPA
PaCO2	7.4 kPA
HCO3	30mmol/L

ABG (1hr after starting NIV)

pH	7.36
PaO2	9.2kPA
PaCO2	6.2 kPA
HCO3	28mmol/L

ABG (now)

pH	7.34
PaO2	6.5kPA
PaCO2	7.0 kPA
HCO3	28mmol/L

What is the cause of this deterioration?

- Poor compliance with NIV
- Patient-ventilator dyssynchrony
- Pneumothorax
- Aspiration
- Hospital acquired pneumonia

Submit answer

Reference ranges

Score: **16%**

1	✗
2	✗
3	✗
4	✗
5	✗
6	✗
7	✗
8	✗
9	✗
10	✗
11	✗
12	✓
13	✗
14	✗
15	✗
16	✗
17	✗
18	✗

19	✗
20	✗
21	✗
22	✗
23	✓
24	✗
25	✗
26	✗
27	✗
28	✗
29	✓
30	✗
31	✓
32	✗
33	✗
34	✗
35	✗
36	✓
37	✓
38	✗
39	✗
40	✗
41	✓
42	✗
43	✗
44	✗
45	✗
46	✗
47	✗
48	✗
49	✓
50	✗
51	-
52	-
53	-
54	-

55	-
56	-
57	-
58	-
59	-
60	-
61	-
62	-
63	-

All contents of this site are © 2024 Passmedicine Limited

An 83-year-old man attends hospital with an infective exacerbation of COPD. He had become increasingly short of breath with an episode of rigors and a dry cough. He is started on salbutamol and ipratropium nebulisers and steroids but fails to improve clinically. After careful discussion, he is offered non invasive ventilation and he tolerates this well. He is slow to improve and 36 hours later, he starts to become more breathless.

On examination, he has crackles and wheeze on the right hemithorax. The left hemithorax has reduced air entry throughout and is resonant to percuss. There are no added sounds., no JVP or leg oedema that can be seen but there is accessory muscle use. He is tired and feels 'absolutely awful'. The non-invasive ventilation is currently set at IPAP 26 cm H2O and EPAP 6 cm H2O. The mask is well adjusted and there is no significant mask leak. A repeat chest x-ray is pending.

Chest X-ray (on admission): hyperinflation, no consolidation seen

ABG (admission)

pH	7.32
PaO2	7.6kPA
PaCO2	7.4 kPA
HCO3	30mmol/L

ABG (1hr after starting NIV)

pH	7.36
PaO2	9.2kPA
PaCO2	6.2 kPA
HCO3	28mmol/L

ABG (now)

pH	7.34
PaO2	6.5kPA
PaCO2	7.0 kPA
HCO3	28mmol/L

What is the cause of this deterioration?

Poor compliance with NIV	4%
Patient-ventilator dyssynchrony	16%
Pneumothorax	76%
Aspiration	2%
Hospital acquired pneumonia	2%

Pneumothorax can occur following high pressure non-invasive ventilation

Important for me Less important

The patient has deteriorated from a respiratory viewpoint on NIV despite earlier improvement. First, we must consider if he is breathing against the machine (dyssynchrony) but we are told he is tolerating it well. There is no evidence to suggest that he has not complied with the NIV. He may have aspirated but there is no history of vomiting or copious secretions. He examination signs are consistent with a pneumothorax on the left side rather than a hospital acquired pneumonia. Pneumothorax is a recognised complication of NIV particularly when higher inflation pressures are used. Please not that initial pressures started are 12cm H20 IPAP and 4 cm H2O EPAP and this gentleman was on significantly higher pressures.

Discuss (6) Improve

Next question

Pneumothorax: classification and features

Pneumothorax is a condition characterized by the accumulation of air in the pleural space, resulting in the partial or complete collapse of the affected lung.

Classification

Pneumothoraces can be classified as follows:

- spontaneous pneumothorax
    - **primary spontaneous pneumothorax (PSP)**: Occurs without underlying lung disease, often in tall, thin, young individuals. PSP is associated with the rupture of subpleural blebs or bullae.

    - **secondary spontaneous pneumothorax (SSP)**: Occurs in patients with pre-existing lung disease, such as COPD, asthma, cystic fibrosis, lung cancer, Pneumocystis pneumonia. Certain connective tissue diseases such as Marfan's syndrome are also a risk factor
- traumatic pneumothorax: results from penetrating or blunt chest trauma, leading to lung injury and pleural air accumulation.
- iatrogenic pneumothorax: occurs as a complication of medical procedures, such as thoracentesis, central venous catheter placement, ventilation, including non-invasive ventilation or lung biopsy.

An important clinical entity is a **tension pneumothorax** - this describes a severe pneumothorax resulting in the displacement of mediastinal structures that may result in severe respiratory distress and haemodynamic collapse.

Catamenial pneumothorax is the cause of 3-6% of spontaneous pneumothoraces occurring in menstruating women. It is thought to be caused by endometriosis within the thorax.

Clinical features

Symptoms tend to come on suddenly:
- dyspnoea
- chest pain: often pleuritic

Signs
- hyper-resonant lung percussion
- reduced breath sounds
- reduced lung expansion
- tachypnoea
- tachycardia

In tension pneumothorax:
- respiratory distress
- tracheal deviation away from the side of the pneumothorax
- hypotension

Image gallery

123

Next question

Textbooks

High-yield textbook

Extended textbook

Media

How to identify pneumothorax on a chest X-ray

Medmastery - YouTube 4 0

Pneumothorax

Zero To Finals - YouTube

2 0

Pneumothorax

Osmosis - YouTube 2 1

Report broken media

Score: **17.3%**

1	✗
2	✗
3	✗
4	✗
5	✗
6	✗
7	✗
8	✗
9	✗
10	✗
11	✗
12	✓
13	✗
14	✗
15	✗
16	✗
17	✗
18	✗
19	✗
20	✗
21	✗
22	✗

23	✓
24	✗
25	✗
26	✗
27	✗
28	✗
29	✓
30	✗
31	✓
32	✗
33	✗
34	✗
35	✗
36	✓
37	✓
38	✗
39	✗
40	✗
41	✓
42	✗
43	✗
44	✗
45	✗
46	✗
47	✗
48	✗
49	✓
50	✗
51	✗
52	✓
53	✗
54	✗
55	✓
56	✗
57	✗
58	✓

59	✗
60	✓
61	✗
62	✗
63	✗
64	✗
65	✗
66	✗
67	✗
68	✗
69	✗
70	✗
71	✗
72	✗
73	✗
74	✗
75	✓
76	✗
77	✗
78	✗
79	✓
80	✗
81	✗
82	✓
83	✗
84	✗
85	✗
86	✗
87	✗
88	✗
89	✗
90	✗
91	✗
92	✗
93	✓
94	✗

95	✓
96	✗
97	✗
98	✗
99	✗
100	✗
101	✗
102	✗
103	✓
104	✗
105	✗
106	✓
107	✗
108	✗
109	✗
110	✗
111	-

All contents of this site are © 2024 Passmedicine Limited

You are called by the general surgical registrar for a medical consult for their patient.

A 19-year-old Caucasian male presented with a two-day history of epigastric pain associated with nausea and vomiting. He was found to have an elevated serum amylase level and thus admitted under the surgical team for management of acute pancreatitis. The surgical team have asked for a medical consult due to the patient reporting worsening productive cough.

Upon your review, the patient reports that this is his third presentation with acute pancreatitis. He does not drink alcohol and an ultrasound of the abdomen did not reveal any gallstones. The cough has been present for several months. Initially, this was a dry cough but more recently has been become productive of green sputum with no haemoptysis. He denies fever, chills, chest pain and dyspnoea. Three weeks prior to this presentation he had received a course of oral antibiotics from his General Practitioner after presenting with nasal congestion and mild facial pain. He states having had multiple courses of antibiotics in the past for similar presentations.

There is no further past medical history or family history of note.

He takes no regular medications and has been receiving simple analgesia and intravenous crystalloid fluids whilst under the care of the surgical team. He is a lifelong non-smoker and works full time in administration.

On examination his height was 178cm with a weight of 58kg, heart rate 90/minute, blood pressure 100/60 mmHg, temperature 37.2ºC, respiratory rate 16/min and oxygen saturation 94% on room air. Respiratory examination revealed early clubbing, no cervical lymphadenopathy, a central trachea, normal chest expansion, mild coarse inspiratory crepitations that improved somewhat after coughing at both posterior bases. Abdominal examination revealed mild epigastric tenderness but no signs of peritonism. Remaining clinical examination was unremarkable.

Hb	130 g/l	Na^+	136 mmol/l
Platelets	400 * 10^9/l	K^+	4 mmol/l
WBC	12 * 10^9/l	Urea	6 mmol/l
Neuts	10 * 10^9/l	Creatinine	65 µmol/l
Lymphs	1 * 10^9/l	CRP	30 mg/l
Eosin	1 * 10^9/l		

Chest x-ray was normal.

Sputum microscopy and culture results revealed *Pseudomonas aeruginosa*

Which of the following would be the most appropriate management for this patient?

- Intravenous ceftazidime and nebulised tobramycin for 14 days
- Intravenous benzylpenicillin and oral doxycycline for 7 days
- Oral ciprofloxacin for 7 days
- Nebulised saline
- Observe and repeat sputum microscopy and culture in the community once fully recovered from the acute pancreatitis

Submit answer

Reference ranges

Score: **16%**

1	✗
2	✗
3	✗
4	✗
5	✗
6	✗
7	✗
8	✗
9	✗
10	✗
11	✗
12	✓
13	✗

14 ✗
15 ✗
16 ✗
17 ✗
18 ✗
19 ✗
20 ✗
21 ✗
22 ✗
23 ✓
24 ✗
25 ✗
26 ✗
27 ✗
28 ✗
29 ✓
30 ✗
31 ✓
32 ✗
33 ✗
34 ✗
35 ✗
36 ✓
37 ✓
38 ✗
39 ✗
40 ✗
41 ✓
42 ✗
43 ✗
44 ✗
45 ✗
46 ✗
47 ✗
48 ✗
49 ✓

50	×
51	-
52	-
53	-
54	-
55	-
56	-
57	-
58	-
59	-
60	-
61	-
62	-
63	-
64	-

All contents of this site are © 2024 Passmedicine Limited

Back to top

You are called by the general surgical registrar for a medical consult for their patient.

A 19-year-old Caucasian male presented with a two-day history of epigastric pain associated with nausea and vomiting. He was found to have an elevated serum amylase level and thus admitted under the surgical team for management of acute pancreatitis. The surgical team have asked for a medical consult due to the patient reporting worsening productive cough.

Upon your review, the patient reports that this is his third presentation with acute pancreatitis. He does not drink alcohol and an ultrasound of the abdomen did not reveal any gallstones. The cough has been present for several months. Initially, this was a dry cough but more recently has been become productive of green sputum with no haemoptysis. He denies fever, chills, chest pain and dyspnoea. Three weeks prior to this presentation he had received a course of oral antibiotics from his General Practitioner after presenting with nasal congestion and mild facial pain. He states having had multiple courses of antibiotics in the past for similar presentations.

There is no further past medical history or family history of note.

He takes no regular medications and has been receiving simple analgesia and intravenous crystalloid fluids whilst under the care of the surgical team. He is a lifelong non-smoker and works full time in administration.

On examination his height was 178cm with a weight of 58kg, heart rate 90/minute, blood pressure 100/60 mmHg, temperature 37.2ºC, respiratory rate 16/min and oxygen saturation 94% on room air. Respiratory examination revealed early clubbing, no cervical lymphadenopathy, a central trachea, normal chest expansion, mild coarse inspiratory crepitations that improved somewhat after coughing at both posterior bases. Abdominal examination revealed mild epigastric tenderness but no signs of peritonism. Remaining clinical examination was unremarkable.

Hb	130 g/l	Na^+	136 mmol/l
Platelets	400 * 10^9/l	K^+	4 mmol/l
WBC	12 * 10^9/l	Urea	6 mmol/l
Neuts	10 * 10^9/l	Creatinine	65 µmol/l
Lymphs	1 * 10^9/l	CRP	30 mg/l
Eosin	1 * 10^9/l		

Chest x-ray was normal.

Sputum microscopy and culture results revealed *Pseudomonas aeruginosa*

Which of the following would be the most appropriate management for this patient?

Intravenous ceftazidime and nebulised tobramycin for 14 days	66%
Intravenous benzylpenicillin and oral doxycycline for 7 days	6%
Oral ciprofloxacin for 7 days	19%
Nebulised saline	2%
Observe and repeat sputum microscopy and culture in the community once fully recovered from the acute pancreatitis	7%

Attempts at *Pseudomonas aeruginosa* eradication are important in patients with cystic fibrosis

Important for me Less important

This patient who presents with recurrent sinusitis, recurrent pancreatitis, clubbing and signs of bronchiectasis on examination likely has undiagnosed cystic fibrosis. *Pseudomonas aeruginosa* eradication is important in such patients and should be treated aggressively.

Whilst traditionally cystic fibrosis (CF) is considered a paediatric disease, it is becoming increasingly important for adult physicians to be aware of the clinical manifestations and complications of CF for two main reasons:

- 10% of patients are still identified when they are more than 18 years of age
- With advances in diagnosis and treatment, the median age of survival for patients with CF is around 40 years, meaning you are likely to care of adult patients with CF during your clinical practice

Patients born before widespread neonatal screening became available are the cohort that may present with CF in adulthood. They also tend to have a more mild phenotype therefore not attracting medical attention earlier in life and may present with other CF complications, such as pancreatitis, sinusitis, intestinal obstruction or male infertility.

Chronic infection with *Pseudomonas aeruginosa* in patients with CF is associated with more rapid loss of lung function, frequent pulmonary exacerbations and a shorter median survival. It is also very difficult to eradicate *Pseudomonas aeruginosa* once chronic infection has been established. The key is to try to eradicate the organism once it is a first isolated, which requires acute

aggressive treatment. In this case, given the diagnosis of CF is new, it should be presumed that this is a new sputum isolate of *Pseudomonas aeruginosa* .

There is no consensus on which anti-microbial strategy is best for *Pseudomonas aeruginosa* eradication. Options include:

- Intravenous anti-pseudomonal antibiotic plus inhaled aminoglycoside for 14 days
- A prolonged course of oral Ciprofloxacin (e.g. 6 weeks)

Option 1 is the correct answer.

Option 2 is a regime used more commonly for moderate community acquired pneumonia and would not be effective at eradicating *Pseudomonas aeruginosa*

Option 3 would have anti-pseudomonal cover but the duration is too short

Option 4 may help with sputum clearance but would not eradicate the *Pseudomonas aeruginosa*

Option 5 would increase the likelihood of chronic *Pseudomonas aeruginosa* infection developing and adversely affect the patient's prognosis

Discuss (3) Improve

Next question

Cystic fibrosis: management

Management of cystic fibrosis (CF) involves a multidisciplinary approach

Key points

- regular (at least twice daily) chest physiotherapy and postural drainage. Parents are usually taught to do this. Deep breathing exercises are also useful
- high calorie diet, including high fat intake*
- patients with CF should try to minimise contact with each other to prevent cross infection with *Burkholderia cepacia* complex and *Pseudomonas aeruginosa*
- vitamin supplementation
- pancreatic enzyme supplements taken with meals
- lung transplantion
    - chronic infection with *Burkholderia cepacia* is an important CF-specific contraindication to lung transplantation

Lumacaftor/Ivacaftor (Orkambi)

- is used to treat cystic fibrosis patients who are homozygous for the delta F508 mutation
- lumacaftor increases the number of CFTR proteins that are transported to the cell surface
- ivacaftor is a potentiator of CFTR that is already at the cell surface, increasing the probability that the defective channel will be open and allow chloride ions to pass through the channel pore

*this is now the standard recommendation - previously high calorie, low-fat diets have been recommended to reduce the amount of steatorrhoea

123

Next question >

Textbooks

High-yield textbook

Extended textbook

Links

Cystic Fibrosis Trust 6 6

Nutrition for adults

NICE 9 4

2017 Cystic fibrosis: diagnosis and management

Suggest link

Report broken link

Media

[Cystic fibrosis]

Osmosis - YouTube 6 0

[Cystic fibrosis: pathology review]

Osmosis - YouTube 2 0

Report broken media

Score: **17.3%**

1	✗
2	✗
3	✗
4	✗
5	✗
6	✗
7	✗
8	✗
9	✗
10	✗
11	✗
12	✓
13	✗
14	✗
15	✗

16	✗
17	✗
18	✗
19	✗
20	✗
21	✗
22	✗
23	✓
24	✗
25	✗
26	✗
27	✗
28	✗
29	✓
30	✗
31	✓
32	✗
33	✗
34	✗
35	✗
36	✓
37	✓
38	✗
39	✗
40	✗
41	✓
42	✗
43	✗
44	✗
45	✗
46	✗
47	✗
48	✗
49	✓
50	✗
51	✗

52	✓
53	✗
54	✗
55	✓
56	✗
57	✗
58	✓
59	✗
60	✓
61	✗
62	✗
63	✗
64	✗
65	✗
66	✗
67	✗
68	✗
69	✗
70	✗
71	✗
72	✗
73	✗
74	✗
75	✓
76	✗
77	✗
78	✗
79	✓
80	✗
81	✗
82	✓
83	✗
84	✗
85	✗
86	✗
87	✗

88	✗
89	✗
90	✗
91	✗
92	✗
93	✓
94	✗
95	✓
96	✗
97	✗
98	✗
99	✗
100	✗
101	✗
102	✗
103	✓
104	✗
105	✗
106	✓
107	✗
108	✗
109	✗
110	✗
111	-

All contents of this site are © 2024 Passmedicine Limited

A 23-year-old gentleman presents with severe shortness of breath and tight-chestedness. On examination, he is very wheezy, his respiratory rate is high but he is speaking in full sentences. He is a known to have asthma and was out in a storm when he suddenly noticed shortness of breath, wheezing and felt his chest becoming tight. His asthma is normally well controlled only occasionally requiring the use of a salbutamol inhaler. He is thought to have thunderstorm asthma. What is thought to be the aetiological cause?

- Increase in cold causing exacerbation
- Electrical charge causing irritation
- Sudden spore and pollen release due to pressure changes
- Increase in winds causing exacerbation
- Anxiety triggering asthma attack

Submit answer

Reference ranges

9 ✗
10 ✗
11 ✗
12 ✓
13 ✗
14 ✗
15 ✗
16 ✗
17 ✗
18 ✗
19 ✗
20 ✗
21 ✗
22 ✗
23 ✓
24 ✗
25 ✗
26 ✗
27 ✗
28 ✗
29 ✓
30 ✗
31 ✓
32 ✗
33 ✗
34 ✗
35 ✗
36 ✓
37 ✓
38 ✗
39 ✗
40 ✗
41 ✓
42 ✗
43 ✗
44 ✗

45	✗
46	✗
47	✗
48	✗
49	✓
50	✗
51	-
52	-
53	-
54	-
55	-
56	-
57	-
58	-
59	-
60	-
61	-
62	-
63	-
64	-
65	-

All contents of this site are © 2024 Passmedicine Limited

Back to top

A 23-year-old gentleman presents with severe shortness of breath and tight-chestedness. On examination, he is very wheezy, his respiratory rate is high but he is speaking in full sentences. He is a known to have asthma and was out in a storm when he suddenly noticed shortness of breath, wheezing and felt his chest becoming tight. His asthma is normally well controlled only occasionally requiring the use of a salbutamol inhaler. He is thought to have thunderstorm asthma. What is thought to be the aetiological cause?

- Increase in cold causing exacerbation 22%
- Electrical charge causing irritation 6%
- Sudden spore and pollen release due to pressure changes 54%
- Increase in winds causing exacerbation 8%
- Anxiety triggering asthma attack 10%

The correct answer is sudden spore and pollen release due to pressure changes. Thunderstorm asthma is a rare event in which the pressure changes in a thunderstorm causes the release of pollen and spores which trigger asthma exacerbation, which can occur in people not previously known to have asthma. The wet conditions at the beginning of a thunderstorm can cause pollen grains to rupture leading to increased amounts of allergen as well. Cold air and anxiety may also provoke asthma attacks, but these causes are not specifically associated with thunderstorms.

Discuss (6) Improve

Next question

Asthma: management in adults

In 2024 NICE, the British Thoracic Society and SIGN produced joint guidelines on the management of asthma following many years of conflicting guidelines. The new guidelines represent a major step change in the management of asthma is both diagnosed and treated.

For many years patients with asthma were started on a short-acting beta-2 agonist (SABA) inhaler

before 'stepping up' to a regular inhaled corticosteroid with a SABA as required. The new guidelines now advocate the use of combined inhalers (ICS + long-acting beta-2 agonist) as reliever therapy or regularly, depending on the severity of asthma. Given the prevalence of asthma, it is likely that doctors will have to deal with patients on 'conventional' asthma treatments for many years to come. The joint guidelines therefore include guidance on how to manage these patients if their current treatment is controlling their symptoms sufficiently.

Management of adult patients aged children aged ≥ 12 years with newly diagnosed asthma

Step 1 NICE

- a low-dose inhaled corticosteroid (ICS)/formoterol combination inhaler to be taken as needed for symptom relief
  - this is termed anti-inflammatory reliever (AIR) therapy
- if the patient presents highly symptomatic (for example, regular nocturnal waking) or with a severe exacerbation:
  - start treatment with low-dose MART (maintenance and reliever therapy, see below)
  - treat the acute symptoms as appropriate (e.g. a course of oral corticosteroids may be indicated)

Step 2 NICE

- a low-dose MART
  - MART describes using an inhaled corticosteroid (ICS)/formoterol combination inhaler for daily maintenance therapy and the relief of symptoms as needed, i.e. regularly and as required

Step 3

- a moderate-dose MART

Step 4

- check the fractional exhaled nitric oxide (FeNO) level if available, and the blood eosinophil count NICE
  - if either of these is raised, refer to a specialist in asthma care
  - if neither FeNO nor eosinophil count is raised, consider a trial of either a leukotriene receptor antagonist (LTRA) or a long-acting muscarinic receptor antagonist (LAMA) used in addition to moderate-dose MART
  - if control has not improved, stop the LTRA or LAMA and start a trial of the alternative medicine (LTRA or LAMA)

Step 5

- refer people to a specialist in asthma care when asthma is not controlled despite treatment with moderate-dose MART, and trials of an LTRA and a LAMA

Transferring people aged 12 and over from other treatment pathways

There will be many people whose asthma was managed according to the previous guidelines that present with uncontrolled asthmatic symptoms. The guidelines give advice on how these people should be switched: NICE

Existing asthma treatment	New asthma treatment
SABA as required only	Low-dose ICS/formoterol combination inhaler used as needed (as-needed AIR therapy)
SABA as required + regular low-dose ICS SABA as required + regular low-dose ICS/LABA SABA as required + regular low-dose ICS + LTRA SABA as required + regular low-dose ICS/LABA + LTRA	Regular low-dose regular ICS/formoterol combination inhaler (MART therapy)
SABA as required + regular moderate-dose ICS SABA as required + regular moderate-dose ICS/LABA SABA as required + regular moderate-dose ICS + LTRA or LAMA SABA as required + regular moderate-dose ICS/LABA + LTRA or LAMA	Regular moderate-dose MART therapy
Treatment regime containing a high-dose ICS	Refer to a respiratory specialist

Next question >

Textbooks

High-yield textbook

Extended textbook

Links

NICE 👍 1 👎 0

2024 Asthma: diagnosis, monitoring and chronic asthma management (BTS, NICE, SIGN)

Suggest link

Report broken link

Media

Asthma

MedFlix - YouTube 👍 2 👎 0

Inhaler and Nebuliser Explanation

Oxford Medical Education - YouTube 👍 5 👎 1

Report broken media

Score: **17.3%**

1	✗
2	✗
3	✗
4	✗
5	✗
6	✗
7	✗
8	✗
9	✗
10	✗
11	✗
12	✓
13	✗
14	✗
15	✗
16	✗
17	✗
18	✗
19	✗
20	✗
21	✗
22	✗
23	✓
24	✗
25	✗
26	✗
27	✗
28	✗
29	✓
30	✗
31	✓

32	✗
33	✗
34	✗
35	✗
36	✓
37	✓
38	✗
39	✗
40	✗
41	✓
42	✗
43	✗
44	✗
45	✗
46	✗
47	✗
48	✗
49	✓
50	✗
51	✗
52	✓
53	✗
54	✗
55	✓
56	✗
57	✗
58	✓
59	✗
60	✓
61	✗
62	✗
63	✗
64	✗
65	✗
66	✗
67	✗

68	✗
69	✗
70	✗
71	✗
72	✗
73	✗
74	✗
75	✓
76	✗
77	✗
78	✗
79	✓
80	✗
81	✗
82	✓
83	✗
84	✗
85	✗
86	✗
87	✗
88	✗
89	✗
90	✗
91	✗
92	✗
93	✓
94	✗
95	✓
96	✗
97	✗
98	✗
99	✗
100	✗
101	✗
102	✗
103	✓

104	✗
105	✗
106	✓
107	✗
108	✗
109	✗
110	✗
111	-

All contents of this site are © 2024 Passmedicine Limited

A 45-year-old man presents to the emergency department with a 48-hour history of shortness of breath, wheezing, and chest tightness. He has a past medical history of asthma.

Upon arrival his observations are as follows; respiratory rate 30/min, oxygen saturations 88% on room air, heart rate 110/min. Auscultation revealed decreased air entry with wheeze throughout both lung fields.

Oxygen was administered via a non-rebreather mask. Nebulised salbutamol and ipratropium bromide were administered back-to-back. He also received intravenous corticosteroids and magnesium sulphate.

Following initial therapy, his oxygen saturations are 98% on 15L via a non-rebreather, his respiratory rate is 34/min, his heart rate is 108/min, and his blood pressure is 112/73mmHg. An arterial blood gas is performed.

pH	7.40	(7.35 - 7.45)
pO2	15.7kPa	(>8)
pCO2	5.0 kPa	(4.5 - 6.0)
HCO3-	22.7mEq/L	(22 - 26)
Base excess	-1.2mEq/L	(-2 to +2)

What is the most appropriate ongoing management plan for ongoing respiratory support?

- Bi-level positive airway pressure (BiPAP)
- Continue current management
- Continuous positive airway pressure (CPAP)
- Referral to intensive care to intubation and ventilation
- Wean oxygen

Submit answer

Reference ranges

Score: **16%**

1	✗
2	✗
3	✗
4	✗
5	✗
6	✗
7	✗
8	✗
9	✗
10	✗
11	✗
12	✓
13	✗
14	✗
15	✗
16	✗
17	✗
18	✗
19	✗
20	✗
21	✗
22	✗
23	✓
24	✗
25	✗
26	✗
27	✗
28	✗
29	✓
30	✗

31	✓
32	✗
33	✗
34	✗
35	✗
36	✓
37	✓
38	✗
39	✗
40	✗
41	✓
42	✗
43	✗
44	✗
45	✗
46	✗
47	✗
48	✗
49	✓
50	✗
51	-
52	-
53	-
54	-
55	-
56	-
57	-
58	-
59	-
60	-
61	-
62	-
63	-
64	-
65	-
66	-

All contents of this site are © 2024 Passmedicine Limited

A 45-year-old man presents to the emergency department with a 48-hour history of shortness of breath, wheezing, and chest tightness. He has a past medical history of asthma.

Upon arrival his observations are as follows; respiratory rate 30/min, oxygen saturations 88% on room air, heart rate 110/min. Auscultation revealed decreased air entry with wheeze throughout both lung fields.

Oxygen was administered via a non-rebreather mask. Nebulised salbutamol and ipratropium bromide were administered back-to-back. He also received intravenous corticosteroids and magnesium sulphate.

Following initial therapy, his oxygen saturations are 98% on 15L via a non-rebreather, his respiratory rate is 34/min, his heart rate is 108/min, and his blood pressure is 112/73mmHg. An arterial blood gas is performed.

pH	7.40	(7.35 - 7.45)
pO2	15.7kPa	(>8)
pCO2	5.0 kPa	(4.5 - 6.0)
HCO3-	22.7mEq/L	(22 - 26)
Base excess	-1.2mEq/L	(-2 to +2)

What is the most appropriate ongoing management plan for ongoing respiratory support?

- Bi-level positive airway pressure (BiPAP) 5%
- Continue current management 9%
- Continuous positive airway pressure (CPAP) 3%
- Referral to intensive care to intubation and ventilation 64%
- Wean oxygen 18%

Patients with features of acute life-threatening asthma who fail to respond to treatment, should be referred to intensive care for potential intubation and ventilation

Important for me Less important

Despite being tachypnoeic, this patient has a normal pCO2 which is a sign of life-threatening asthma. This is despite therapy with bronchodilators, corticosteroids, and magnesium. Therefore, this patient needs **referral to intensive care for intubation and ventilation**.

BiPAP is not generally used in the treatment of asthma as there is significant potential for air trapping so ventilation should be carried out in intensive care. Therefore this option is incorrect.

To **continue current management** would not be an appropriate response in this instance. This patient has failed to respond to therapy and is showing signs of life-threatening asthma. Therefore, this patient needs a referral to intensive care.

CPAP, similar to BiPAP, is not routinely used in the management of asthma. CPAP does not help with ventilation and therefore CO2 clearance. It also poses a significant risk of air trapping in asthmatics. Therefore, referral to intensive care would be more appropriate.

Although this patient has adequate saturations, it would be inappropriate to **wean oxygen** as this does not address the normal pCO2 which is a life-threatening sign.

Discuss (1) Improve

Next question

Acute asthma: management

The British Thoracic Society (BTS) classify patients with acute asthma into moderate, severe or life-threatening categories.

Moderate	**Severe**	**Life-threatening**
PEFR 50-75% best or predicted Speech normal RR < 25 / min Pulse < 110 bpm	PEFR 33 - 50% best or predicted Can't complete sentences RR > 25/min Pulse > 110 bpm	PEFR < 33% best or predicted Oxygen sats < 92% 'Normal' $pC0_2$ (4.6-6.0 kPa) Silent chest, cyanosis or feeble respiratory effort Bradycardia, dysrhythmia or hypotension Exhaustion, confusion or coma

Note that a patient having any one of the life-threatening features should be treated as having a life-threatening attack.

A fourth category, '**Near-fatal asthma**', is also recognised characterised by a raised $pC0_2$ and/or requiring mechanical ventilation with raised inflation pressures.

Further assessment
- the BTS guidelines recommend arterial blood gases for patients with oxygen sats < 92%
- a chest x-ray is not routinely recommended, unless:
  - life-threatening asthma
  - suspected pneumothorax
  - failure to respond to treatment

Management
- admission
  - all patients with life-threatening should be admitted in hospital
  - patients with features of severe acute asthma should also be admitted if they fail to respond to initial treatment.
  - other admission criteria include a previous near-fatal asthma attack, pregnancy, an attack occurring despite already using oral corticosteroid and presentation at night
- oxygen
  - if patients are hypoxaemic, it is important to start them on supplemental oxygen therapy
  - if patients are acutely unwell they should be started on 15L of supplemental via a non-rebreathe mask, which can then be titrated down to a flow rate where they are able to maintain a SpO,, 94-98%.
- bronchodilation with short-acting beta,,-agonists (SABA)
  - high-dose inhaled SABA e.g. salbutamol, terbutaline
  - in patients without features of life-threatening or near-fatal asthma, this can be given by a standard pressurised metered-dose inhaler (pMDI) or by an oxygen-driven nebulizer
  - in patients with features of a life-threatening exacerbation of asthma, nebulised SABA is recommended
- corticosteroid
  - all patients should be given 40-50mg of prednisolone orally (PO) daily, which should be continued for at least five days or until the patient recovers from the attack
  - during this time, patients should continue their normal medication routine including inhaled corticosteroids.
- ipratropium bromide: in patients with severe or life-threatening asthma, or in patients who have not responded to beta,,-agonist and corticosteroid treatment, nebulised ipratropium bromide, a short-acting muscarinic antagonist
- IV magnesium sulphate
  - the BTS notes that the evidence base is mixed for this treatment that is now commonly given for severe/life-threatening asthma

- IV aminophylline may be considered following consultation with senior medical staff
- patients who fail to respond require senior critical care support and should be treated in an appropriate ITU/HDU setting. Treatment options include:
  - intubation and ventilation
  - extracorporeal membrane oxygenation (ECMO)

Criteria for discharge
- been stable on their discharge medication (i.e. no nebulisers or oxygen) for 12-24 hours
- inhaler technique checked and recorded
- PEF >75% of best or predicted

123

Next question

Textbooks

High-yield textbook

Extended textbook

Links

British Thoracic Society 44 73

2019 Asthma guidelines

Suggest link Report broken link

Score: **17.3%**

1	✗
2	✗
3	✗
4	✗
5	✗
6	✗
7	✗
8	✗
9	✗
10	✗
11	✗
12	✓
13	✗
14	✗
15	✗
16	✗
17	✗
18	✗
19	✗
20	✗
21	✗
22	✗
23	✓
24	✗
25	✗
26	✗
27	✗
28	✗
29	✓
30	✗
31	✓
32	✗
33	✗
34	✗
35	✗

36	✓
37	✓
38	✗
39	✗
40	✗
41	✓
42	✗
43	✗
44	✗
45	✗
46	✗
47	✗
48	✗
49	✓
50	✗
51	✗
52	✓
53	✗
54	✗
55	✓
56	✗
57	✗
58	✓
59	✗
60	✓
61	✗
62	✗
63	✗
64	✗
65	✗
66	✗
67	✗
68	✗
69	✗
70	✗
71	✗

72	✗
73	✗
74	✗
75	✓
76	✗
77	✗
78	✗
79	✓
80	✗
81	✗
82	✓
83	✗
84	✗
85	✗
86	✗
87	✗
88	✗
89	✗
90	✗
91	✗
92	✗
93	✓
94	✗
95	✓
96	✗
97	✗
98	✗
99	✗
100	✗
101	✗
102	✗
103	✓
104	✗
105	✗
106	✓
107	✗

108	✕
109	✕
110	✕
111	-

All contents of this site are © 2024 Passmedicine Limited

A 76-year-old woman presents to clinic with shortness of breath. This has been progressing over the last 18 months and is associated with a non-productive cough. She is still able to complete her usual day-to-day tasks but struggles with more exertional activities such as gardening.

She finished chemotherapy for non-Hodgkin's lymphoma two years ago. She has no other relevant medical history.

Her current medications include allopurinol, bisoprolol, aspirin, simvastatin, paracetamol and codeine.

On examination, she has finger clubbing and diffuse fine crackles on chest auscultation.

Given the likely diagnosis, which of the following spirometry results would you expect?

- FEV1 - 1.4L (71%), FVC - 2.5L (102%), FEV1/FVC ratio - 56%, DLCO - 90% of predicted
- FEV1 - 1.3L (66%), FVC - 1.6L (65%), FEV1/FVC ratio - 81%, DLCO - 75% of predicted
- FEV1 - 1.9L (97%), FVC - 2.4L (98%), FEV1/FVC ratio - 79%, DLCO - 110% of predicted
- FEV1 - 0.9L (45%), FVC - 2.1L (86%), FEV1/FVC ratio - 42%, DLCO - 90% of predicted
- FEV1 - 0.9L (45%), FVC - 1.1L (45%), FEV1/FVC ratio - 81%, DLCO - 120% of predicted

Submit answer

Reference ranges

Score: **16%**

1 ×

2	✗
3	✗
4	✗
5	✗
6	✗
7	✗
8	✗
9	✗
10	✗
11	✗
12	✓
13	✗
14	✗
15	✗
16	✗
17	✗
18	✗
19	✗
20	✗
21	✗
22	✗
23	✓
24	✗
25	✗
26	✗
27	✗
28	✗
29	✓
30	✗
31	✓
32	✗
33	✗
34	✗
35	✗
36	✓
37	✓

38	✗
39	✗
40	✗
41	✓
42	✗
43	✗
44	✗
45	✗
46	✗
47	✗
48	✗
49	✓
50	✗
51	-
52	-
53	-
54	-
55	-
56	-
57	-
58	-
59	-
60	-
61	-
62	-
63	-
64	-
65	-
66	-
67	-

All contents of this site are © 2024 Passmedicine Limited

Back to top

A 76-year-old woman presents to clinic with shortness of breath. This has been progressing over the last 18 months and is associated with a non-productive cough. She is still able to complete her usual day-to-day tasks but struggles with more exertional activities such as gardening.

She finished chemotherapy for non-Hodgkin's lymphoma two years ago. She has no other relevant medical history.

Her current medications include allopurinol, bisoprolol, aspirin, simvastatin, paracetamol and codeine.

On examination, she has finger clubbing and diffuse fine crackles on chest auscultation.

Given the likely diagnosis, which of the following spirometry results would you expect?

- FEV1 - 1.4L (71%), FVC - 2.5L (102%), FEV1/FVC ratio - 56%, DLCO - 90% of predicted — 2%
- FEV1 - 1.3L (66%), FVC - 1.6L (65%), FEV1/FVC ratio - 81%, DLCO - 75% of predicted — 76%
- FEV1 - 1.9L (97%), FVC - 2.4L (98%), FEV1/FVC ratio - 79%, DLCO - 110% of predicted — 6%
- FEV1 - 0.9L (45%), FVC - 2.1L (86%), FEV1/FVC ratio - 42%, DLCO - 90% of predicted — 4%
- FEV1 - 0.9L (45%), FVC - 1.1L (45%), FEV1/FVC ratio - 81%, DLCO - 120% of predicted — 11%

The patient likely has a restrictive lung defect, caused by pulmonary fibrosis. This may be due to a chemotherapy agent, such as bleomycin from her chemotherapy.

Obstructive spirometry:

- FEV1 reduced (<80% predicted normal)
- FVC is usually reduced but to a lesser extent than FEV1
- FEV1/FVC ratio reduced (<0.7)

Restrictive spirometry:

- FEV 1 reduced (<80% predicted normal)
- FVC reduced (<80% predicted normal)
- FEV 1 /FVC ratio normal (>0.7)

DLCO (diffusing capacity of the lung for carbon monoxide) measures the ability of the lungs to transfer gas from inhaled air to the red blood cells in pulmonary capillaries

Decreased DLCO

Restrictive lung disease

- Idiopathic pulmonary fibrosis
- Occupational lung disease
- Hypersensitivity pneumonitis
- Miliary tuberculosis
- Pneumonectomy

Obstructive lung disease

- Cystic fibrosis
- Emphysema

Other causes

- Chronic pulmonary embolism
- Congestive heart failure
- Primary pulmonary hypertension

Increased DLCO

Causes

- Pulmonary haemorrhage
- Polycythaemia
- Left to right cardiac shunting

Answer 1 and 4 both show obstructive patterns. Answer 3 is a normal spirometry pattern. Answers 2 and 5 both show a restrictive pattern. However, answer 5 has a raised transfer factor. In drug-induced restrictive lung disease this would be low.

Discuss (4) | Improve

Next question

Pulmonary function tests

Pulmonary function tests can be used to determine whether a respiratory disease is obstructive or restrictive. The table below summarises the main findings and gives some example conditions:

Obstructive lung disease	**Restrictive lung disease**
FEV1 - significantly reduced FVC - reduced or normal FEV1% (FEV1/FVC) - reduced	FEV1 - reduced FVC - significantly reduced FEV1% (FEV1/FVC) - normal or increased
Asthma COPD Bronchiectasis Bronchiolitis obliterans	Pulmonary fibrosis Asbestosis Sarcoidosis Acute respiratory distress syndrome Infant respiratory distress syndrome Kyphoscoliosis e.g. ankylosing spondylitis Neuromuscular disorders Severe obesity

123

Next question >

Textbooks

High-yield textbook

Extended textbook

Media

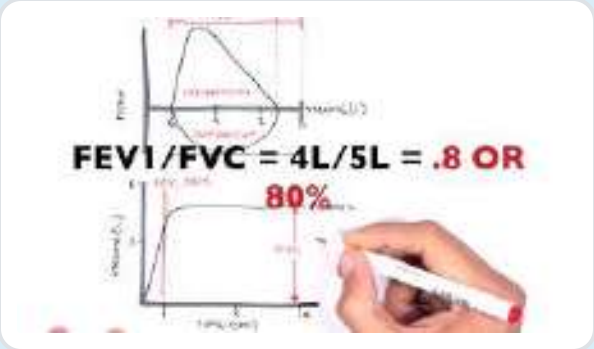

[Understanding Spirometry - Normal, Obstructive vs Restrictive]

Armando Hasudungan - YouTube 17 0

[Restrictive lung disease]

Osmosis - YouTube 4 0

[Peak Flow and Spirometry - Lung Function Tests]

Oxford Medical Education - YouTube 4 0

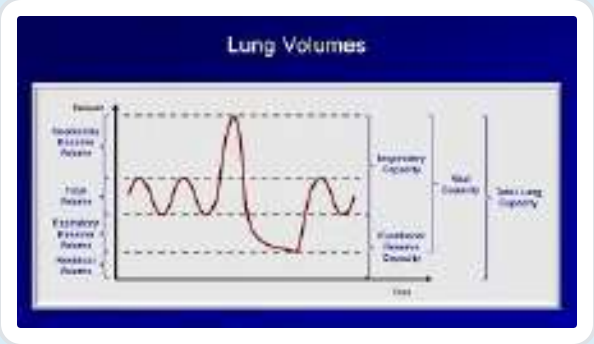

[Pulmonary Function Tests]

Strong Medicine - YouTube 4 0

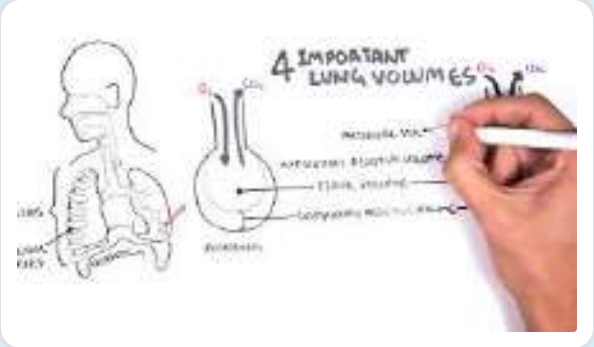

[Lung Function - Lung Volumes and Capacities]

Armando Hasudungan - YouTube 3 0

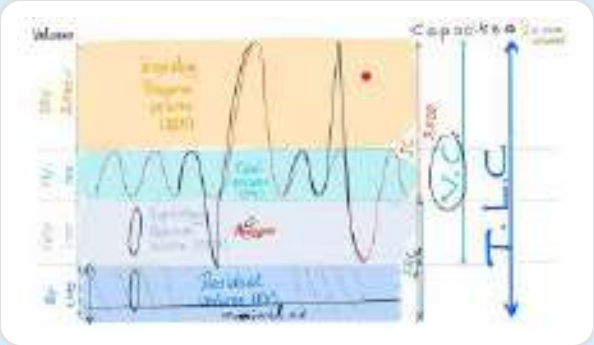

Pulmonary Function Tests (PFTs) Made Simple

Medicosis Perfectionalis - YouTube 4 1

Report broken media

Score: **17.3%**

1	✗
2	✗
3	✗
4	✗
5	✗
6	✗
7	✗
8	✗
9	✗
10	✗
11	✗
12	✓
13	✗
14	✗
15	✗
16	✗
17	✗
18	✗
19	✗
20	✗
21	✗
22	✗
23	✓
24	✗
25	✗
26	✗
27	✗

28	✗
29	✓
30	✗
31	✓
32	✗
33	✗
34	✗
35	✗
36	✓
37	✓
38	✗
39	✗
40	✗
41	✓
42	✗
43	✗
44	✗
45	✗
46	✗
47	✗
48	✗
49	✓
50	✗
51	✗
52	✓
53	✗
54	✗
55	✓
56	✗
57	✗
58	✓
59	✗
60	✓
61	✗
62	✗
63	✗

64	✗
65	✗
66	✗
67	✗
68	✗
69	✗
70	✗
71	✗
72	✗
73	✗
74	✗
75	✓
76	✗
77	✗
78	✗
79	✓
80	✗
81	✗
82	✓
83	✗
84	✗
85	✗
86	✗
87	✗
88	✗
89	✗
90	✗
91	✗
92	✗
93	✓
94	✗
95	✓
96	✗
97	✗
98	✗
99	✗

100	✗
101	✗
102	✗
103	✓
104	✗
105	✗
106	✓
107	✗
108	✗
109	✗
110	✗
111	-

All contents of this site are © 2024 Passmedicine Limited
Back to top

A 32-year-old man is admitted to the acute medical unit with acute shortness of breath. Blood cultures are positive for Staphylococcus aureus. He has a pan systolic murmur heard loudest over the left sternal edge.

A chest x-ray confirms a cavitating mass in the right lung with associated pleural effusion. You perform a pleural tap which is as follows:

pH	7.15
Protein	42 g/l
Appearance	Serous

What test can be performed to assess if the effusion is an empyema?

- Video-assisted Thoracoscopic Surgery (VATS)
- Thoracic ultrasound
- Chest x-ray
- Centrifugation of the pleural aspirate
- Plasma C-reactive protein (CRP)

Submit answer

Reference ranges

Score: **16%**

1 ✕
2 ✕

3	✗
4	✗
5	✗
6	✗
7	✗
8	✗
9	✗
10	✗
11	✗
12	✓
13	✗
14	✗
15	✗
16	✗
17	✗
18	✗
19	✗
20	✗
21	✗
22	✗
23	✓
24	✗
25	✗
26	✗
27	✗
28	✗
29	✓
30	✗
31	✓
32	✗
33	✗
34	✗
35	✗
36	✓
37	✓
38	✗

39	✗
40	✗
41	✓
42	✗
43	✗
44	✗
45	✗
46	✗
47	✗
48	✗
49	✓
50	✗
51	-
52	-
53	-
54	-
55	-
56	-
57	-
58	-
59	-
60	-
61	-
62	-
63	-
64	-
65	-
66	-
67	-
68	-

All contents of this site are © 2024 Passmedicine Limited

Back to top

A 32-year-old man is admitted to the acute medical unit with acute shortness of breath. Blood cultures are positive for Staphylococcus aureus. He has a pan systolic murmur heard loudest over the left sternal edge.

A chest x-ray confirms a cavitating mass in the right lung with associated pleural effusion. You perform a pleural tap which is as follows:

pH	7.15
Protein	42 g/l
Appearance	Serous

What test can be performed to assess if the effusion is an empyema?

- Video-assisted Thoracoscopic Surgery (VATS) 15%
- Thoracic ultrasound 22%
- Chest x-ray 1%
- Centrifugation of the pleural aspirate 58%
- Plasma C-reactive protein (CRP) 4%

If the pleural fluid is turbid or milky it should be centrifuged. If the supernatant (liquid which lies above the sediment) is clear, the turbid fluid was due to cell debris and empyema is likely

Important for me Less important

The history and clinical features are suggestive of right sided endocarditis with septic emboli to the lungs. The pleural fluid is an exudate, and the pH < 7.20 indicates that this is a complicated parapneumonic effusion which requires drainage.

Aspiration of frank pus is diagnostic of an empyema and no other investigations are required to establish the diagnosis, with the exception of pleural fluid microbiology to guide antibiotic therapy. If the aspirate does not reveal frank pus, further analysis is required to assess whether it is a complicated parapneumonic effusion. This involves measurement of the pleural fluid pH, total

protein concentration, LDH level, glucose concentration, and white cell differential.

If an effusion is not frankly purulent, but empyema is suspected, then the sample should undergo centrifugation and if the supernatant becomes clear, empyema is the most probable diagnosis; otherwise, the differential diagnosis is between lipid pleural effusions and pleural fluid analysis is required.

Discuss (8) Improve

Next question

Pleural effusion: investigation and management

The British Thoracic Society (BTS) produced guidelines in 2010 covering the investigation of patients with a pleural effusion.

Imaging
- posterioranterior (PA) chest x-rays should be performed in all patients
- ultrasound is recommended: it increases the likelihood of successful pleural aspiration and is sensitive for detecting pleural fluid septations
- contrast CT is now increasingly performed to investigate the underlying cause, particularly for exudative effusions

Pleural aspiration
- as above, ultrasound is recommended to reduce the complication rate
- a 21G needle and 50ml syringe should be used
- fluid should be sent for pH, protein, lactate dehydrogenase (LDH), cytology and microbiology

Light's criteria was developed in 1972 to help distinguish between a transudate and an exudate. The BTS recommend using the criteria for borderline cases:
- exudates have a protein level of >30 g/L, transudates have a protein level of <30 g/L
- if the protein level is between 25-35 g/L, Light's criteria should be applied. An exudate is likely if at least one of the following criteria are met:

- pleural fluid protein divided by serum protein >0.5
- pleural fluid LDH divided by serum LDH >0.6
- pleural fluid LDH more than two-thirds the upper limits of normal serum LDH

Other characteristic pleural fluid findings:

- low glucose: rheumatoid arthritis, tuberculosis
- raised amylase: pancreatitis, oesophageal perforation
- heavy blood staining: mesothelioma, pulmonary embolism, tuberculosis

Pleural infection

All patients with a pleural effusion in association with sepsis or a pneumonic illness require diagnostic pleural fluid sampling

- if the fluid is purulent or turbid/cloudy a chest tube should be placed to allow drainage
- if the fluid is clear but the **pH is less than 7.2 in patients with suspected pleural infection a chest tube should be placed**

Management of recurrent pleural effusion

Options for managing patients with recurrent pleural effusions include:

- recurrent aspiration
- pleurodesis
- indwelling pleural catheter
- drug management to alleviate symptoms e.g. opioids to relieve dyspnoea

+ Q 123

Next question ›

Textbooks

High-yield textbook

Extended textbook

Links

British Thoracic Society 17 14

2023 Pleural disease guidelines

Royal College of Physicians 13 7

2012 Pleural infection review

Suggest link Report broken link

Media

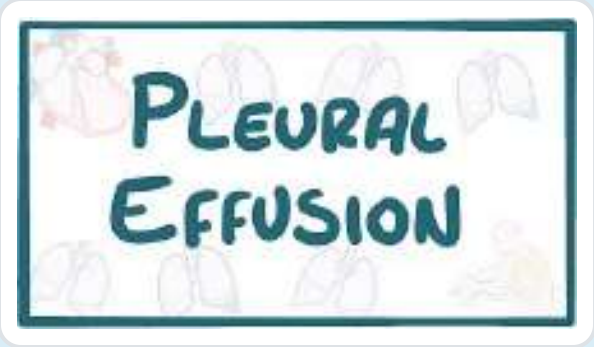

Pleural effusion

Osmosis - YouTube 8 1

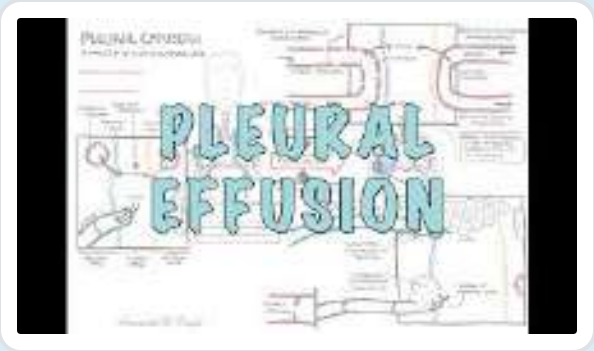

Pleural effusion

Armando Hasudungan - YouTube 6 1

Report broken media

Score: **17.3%**

1 ✗

2	✗
3	✗
4	✗
5	✗
6	✗
7	✗
8	✗
9	✗
10	✗
11	✗
12	✓
13	✗
14	✗
15	✗
16	✗
17	✗
18	✗
19	✗
20	✗
21	✗
22	✗
23	✓
24	✗
25	✗
26	✗
27	✗
28	✗
29	✓
30	✗
31	✓
32	✗
33	✗
34	✗
35	✗
36	✓
37	✓

38	✗
39	✗
40	✗
41	✓
42	✗
43	✗
44	✗
45	✗
46	✗
47	✗
48	✗
49	✓
50	✗
51	✗
52	✓
53	✗
54	✗
55	✓
56	✗
57	✗
58	✓
59	✗
60	✓
61	✗
62	✗
63	✗
64	✗
65	✗
66	✗
67	✗
68	✗
69	✗
70	✗
71	✗
72	✗
73	✗

74	✗
75	✓
76	✗
77	✗
78	✗
79	✓
80	✗
81	✗
82	✓
83	✗
84	✗
85	✗
86	✗
87	✗
88	✗
89	✗
90	✗
91	✗
92	✗
93	✓
94	✗
95	✓
96	✗
97	✗
98	✗
99	✗
100	✗
101	✗
102	✗
103	✓
104	✗
105	✗
106	✓
107	✗
108	✗
109	✗

110 ✕

111 -

All contents of this site are © 2024 Passmedicine Limited

A 70-year-old lady with a background of type 2 diabetes mellitus and alcohol abuse presents with a fever and productive cough. She reports no weight loss or haemoptysis. She was born in England and has never travelled outside of the United Kingdom. She has never smoked cigarettes. On examination, she has crackles in her right upper lobe but is otherwise well and stable. A chest radiograph reveals consolidation which is cavitating in her right upper lobe. What is the most likely diagnosis?

- Lung cancer
- Tuberculosis
- Pneumococcal pneumonia
- Klebsiella pneumonia
- Aspergillosis

Submit answer

Reference ranges

Score: **16%**

1 ✗
2 ✗
3 ✗
4 ✗
5 ✗
6 ✗
7 ✗
8 ✗

9 ✗
10 ✗
11 ✗
12 ✓
13 ✗
14 ✗
15 ✗
16 ✗
17 ✗
18 ✗
19 ✗
20 ✗
21 ✗
22 ✗
23 ✓
24 ✗
25 ✗
26 ✗
27 ✗
28 ✗
29 ✓
30 ✗
31 ✓
32 ✗
33 ✗
34 ✗
35 ✗
36 ✓
37 ✓
38 ✗
39 ✗
40 ✗
41 ✓
42 ✗
43 ✗
44 ✗

45	✗
46	✗
47	✗
48	✗
49	✓
50	✗
51	-
52	-
53	-
54	-
55	-
56	-
57	-
58	-
59	-
60	-
61	-
62	-
63	-
64	-
65	-
66	-
67	-
68	-
69	-

All contents of this site are © 2024 Passmedicine Limited

Back to top

A 70-year-old lady with a background of type 2 diabetes mellitus and alcohol abuse presents with a fever and productive cough. She reports no weight loss or haemoptysis. She was born in England and has never travelled outside of the United Kingdom. She has never smoked cigarettes. On examination, she has crackles in her right upper lobe but is otherwise well and stable. A chest radiograph reveals consolidation which is cavitating in her right upper lobe. What is the most likely diagnosis?

Lung cancer	1%
Tuberculosis	6%
Pneumococcal pneumonia	2%
Klebsiella pneumonia	83%
Aspergillosis	8%

Klebsiella most commonly causes a cavitating pneumonia in the upper lobes, mainly in diabetics and alcoholics

Important for me Less important

Klebsiella pneumonia is particularly associated with diabetic and alcoholic patients. It leads to a cavitating upper lobe pneumonia. Differentials for this lady would include lung cancer and tuberculosis but these would usually be associated with weight loss and travel to eastern Europe or Asia respectively.

Discuss (4) Improve

Next question

Klebsiella

Klebsiella pneumoniae is a Gram-negative rod that is part of the normal gut flora. It can cause a number of infections in humans including pneumonia (typically following aspiration) and urinary

tract infections.

Features of *Klebsiella* pneumonia

- more common in alcoholic and diabetics
- may occur following aspiration
- 'red-currant jelly' sputum
- often affects upper lobes

Prognosis

- commonly causes lung abscess formation and empyema
- mortality is 30-50%

A human neutrophil interacting with *Klebsiella pneumoniae* (pink), a multidrug-resistant bacterium that causes severe hospital infections. Credit: NIAID

AI + Q 123

Next question >

Textbooks

High-yield textbook

Extended textbook

Media

Klebsiella

Osmosis - YouTube 3 0

Klebsiella, Enterobacter, Serratia

SketchyMedical - YouTube 3 1

Report broken media

Score: **17.3%**

1 ✗
2 ✗
3 ✗
4 ✗
5 ✗

6	✗
7	✗
8	✗
9	✗
10	✗
11	✗
12	✓
13	✗
14	✗
15	✗
16	✗
17	✗
18	✗
19	✗
20	✗
21	✗
22	✗
23	✓
24	✗
25	✗
26	✗
27	✗
28	✗
29	✓
30	✗
31	✓
32	✗
33	✗
34	✗
35	✗
36	✓
37	✓
38	✗
39	✗
40	✗
41	✓

42	✗
43	✗
44	✗
45	✗
46	✗
47	✗
48	✗
49	✓
50	✗
51	✗
52	✓
53	✗
54	✗
55	✓
56	✗
57	✗
58	✓
59	✗
60	✓
61	✗
62	✗
63	✗
64	✗
65	✗
66	✗
67	✗
68	✗
69	✗
70	✗
71	✗
72	✗
73	✗
74	✗
75	✓
76	✗
77	✗

78	✗
79	✓
80	✗
81	✗
82	✓
83	✗
84	✗
85	✗
86	✗
87	✗
88	✗
89	✗
90	✗
91	✗
92	✗
93	✓
94	✗
95	✓
96	✗
97	✗
98	✗
99	✗
100	✗
101	✗
102	✗
103	✓
104	✗
105	✗
106	✓
107	✗
108	✗
109	✗
110	✗
111	-

All contents of this site are © 2024 Passmedicine Limited

A 65-year-old man presents to his GP after his wife complains he snores very loudly and occasionally stops breathing at night. He also falls asleep easily during the day while watching television or reading. He had bilateral tonsillectomies and adenoidectomy as a child. On examination, his height is 1.80m and his weight is 100kg. He has lost 15kg of weight in the last six months but his symptoms have persisted. His GP refers him for a sleep study which is suggestive of moderate sleep apnoea.

What initial management option should be recommended?

- Further weight loss and repeat sleep study thereafter
- Lifestyle advice including sleep hygiene
- Mandibular advancement splint
- Referral for CPAP
- Referral to ENT for surgery

Submit answer

Reference ranges

Score: **16%**

1	✗
2	✗
3	✗
4	✗
5	✗
6	✗

7 ✗
8 ✗
9 ✗
10 ✗
11 ✗
12 ✓
13 ✗
14 ✗
15 ✗
16 ✗
17 ✗
18 ✗
19 ✗
20 ✗
21 ✗
22 ✗
23 ✓
24 ✗
25 ✗
26 ✗
27 ✗
28 ✗
29 ✓
30 ✗
31 ✓
32 ✗
33 ✗
34 ✗
35 ✗
36 ✓
37 ✓
38 ✗
39 ✗
40 ✗
41 ✓
42 ✗

43	✗
44	✗
45	✗
46	✗
47	✗
48	✗
49	✓
50	✗
51	-
52	-
53	-
54	-
55	-
56	-
57	-
58	-
59	-
60	-
61	-
62	-
63	-
64	-
65	-
66	-
67	-
68	-
69	-
70	-

All contents of this site are © 2024 Passmedicine Limited

Back to top

A 65-year-old man presents to his GP after his wife complains he snores very loudly and occasionally stops breathing at night. He also falls asleep easily during the day while watching television or reading. He had bilateral tonsillectomies and adenoidectomy as a child. On examination, his height is 1.80m and his weight is 100kg. He has lost 15kg of weight in the last six months but his symptoms have persisted. His GP refers him for a sleep study which is suggestive of moderate sleep apnoea.

What initial management option should be recommended?

- Further weight loss and repeat sleep study thereafter 11%
- Lifestyle advice including sleep hygiene 5%
- Mandibular advancement splint 12%
- Referral for CPAP 70%
- Referral to ENT for surgery 1%

Following weight loss, CPAP is the first-line treatment for moderate/severe obstructive sleep apnoea

Important for me Less important

Patients with symptoms suggestive of obstructive sleep apnoea (OSA) that affect their quality of life should be offered **continuous positive airway pressure (CPAP)** if they have moderate or severe OSA, in addition to lifestyle advice.

Weight loss as part of lifestyle advice may be appropriate as first-line treatment for patients with mild sleep apnoea. However, this patient has already tried to lose weight without any benefit. Furthermore, they have moderate sleep apnoea and should be offered CPAP alongside lifestyle advice. Patients who feel that their OSA has resolved following lifestyle modification can have a trial of stopping treatment for two weeks and then an evaluation of their symptoms or a repeat sleep study.

Lifestyle advice regarding sleep hygiene, reducing alcohol and smoking and weight loss is important but NICE recommends that it should be provided alongside CPAP in patients with moderate to severe OSA.

A **mandibular advancement splint** is not first-line in treating sleep apnoea but can be offered to those who do not tolerate CPAP and have good dental health. This patient should thus be offered CPAP first.

CPAP is first-line for sleep apnoea, but **referral to ENT** may be appropriate if he is unable to tolerate CPAP or other interventions first. An ENT physician may recommend tonsillectomy or other oropharyngeal surgery.

Discuss (1) Improve

Next question

Obstructive sleep apnoea/hypopnoea syndrome

Predisposing factors
- obesity
- macroglossia: acromegaly, hypothyroidism, amyloidosis
- large tonsils
- Marfan's syndrome

The partner often complains of excessive snoring and may report periods of apnoea.

Consequence
- daytime somnolence
- compensated respiratory acidosis
- hypertension

Assessment of sleepiness
- Epworth Sleepiness Scale - questionnaire completed by patient +/- partner
- Multiple Sleep Latency Test (MSLT) - measures the time to fall asleep in a dark room (using EEG criteria)

Diagnostic tests
- sleep studies (polysomnography) - ranging from monitoring of pulse oximetry at night to full polysomnography where a wide variety of physiological factors are measured including EEG, respiratory airflow, thoraco-abdominal movement, snoring and pulse oximetry

Management

- weight loss
- continuous positive airway pressure (CPAP) is first line for moderate or severe OSAHS
- intra-oral devices (e.g. mandibular advancement) may be used if CPAP is not tolerated or for patients with mild OSAHS where there is no daytime sleepiness
- the DVLA should be informed if OSAHS is causing excessive daytime sleepiness
- limited evidence to support use of pharmacological agents

123

Next question

Textbooks

High-yield textbook

Extended textbook

Links

Clinical Knowledge Summaries 4 4

Obstructive sleep apnoea guidelines

NICE 8 5

2021 Obstructive sleep apnoea/hypopnoea syndrome and obesity hypoventilation syndrome guidelines

Suggest link Report broken link

Media

[Sleep apnea]

Osmosis - YouTube 3 0

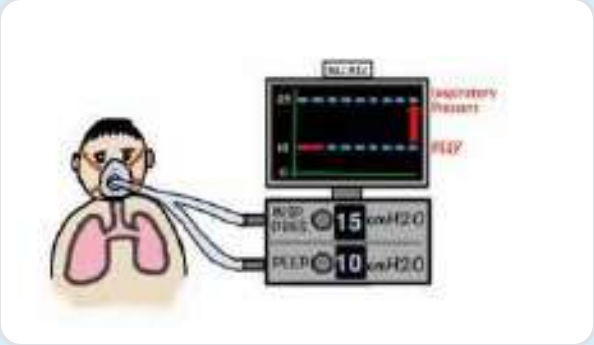

[CPAP and Non-Invasive Ventilation in 5 minutes]

Nick Smith - YouTube 2 0

[Obstructive Sleep Apnoea]

Zero To Finals - YouTube 1 0

[Understanding Obstructive Sleep Apnea Syndrome]

Rhesus Medicine - YouTube 0 0

Report broken media

Score: **17.3%**

1 ✗
2 ✗
3 ✗
4 ✗

5	✗
6	✗
7	✗
8	✗
9	✗
10	✗
11	✗
12	✓
13	✗
14	✗
15	✗
16	✗
17	✗
18	✗
19	✗
20	✗
21	✗
22	✗
23	✓
24	✗
25	✗
26	✗
27	✗
28	✗
29	✓
30	✗
31	✓
32	✗
33	✗
34	✗
35	✗
36	✓
37	✓
38	✗
39	✗
40	✗

41	✓
42	✗
43	✗
44	✗
45	✗
46	✗
47	✗
48	✗
49	✓
50	✗
51	✗
52	✓
53	✗
54	✗
55	✓
56	✗
57	✗
58	✓
59	✗
60	✓
61	✗
62	✗
63	✗
64	✗
65	✗
66	✗
67	✗
68	✗
69	✗
70	✗
71	✗
72	✗
73	✗
74	✗
75	✓
76	✗

77	✗
78	✗
79	✓
80	✗
81	✗
82	✓
83	✗
84	✗
85	✗
86	✗
87	✗
88	✗
89	✗
90	✗
91	✗
92	✗
93	✓
94	✗
95	✓
96	✗
97	✗
98	✗
99	✗
100	✗
101	✗
102	✗
103	✓
104	✗
105	✗
106	✓
107	✗
108	✗
109	✗
110	✗
111	-

All contents of this site are © 2024 Passmedicine Limited

A 57-year-old male presents with a three-month history of unintentional weight loss (13kg over 3 months) and a chronic non-productive cough. He has just returned from a months holiday in India. He denies haemoptysis or chest pain. He is a lifelong smoker. He has no past medical history except a period of generalised limb weakness two years ago when he was referred to outpatient neurology clinic and diagnosed with Lambert-Eaton myasthenic syndrome following investigations. His blood tests are unremarkable. However, his chest x-ray demonstrates a rounded opacity in his right midzone, about 4 cm from his right main bronchus.

What is the most likely diagnosis?

- Tuberculosis
- Aspergilloma
- Small cell lung carcinoma
- Non-small cell carcinoma
- *Pneumocystis jirovecii* infection

Submit answer

Reference ranges

Score: **16%**

1 ✕
2 ✕
3 ✕
4 ✕
5 ✕

6	✗
7	✗
8	✗
9	✗
10	✗
11	✗
12	✓
13	✗
14	✗
15	✗
16	✗
17	✗
18	✗
19	✗
20	✗
21	✗
22	✗
23	✓
24	✗
25	✗
26	✗
27	✗
28	✗
29	✓
30	✗
31	✓
32	✗
33	✗
34	✗
35	✗
36	✓
37	✓
38	✗
39	✗
40	✗
41	✓

42	✗
43	✗
44	✗
45	✗
46	✗
47	✗
48	✗
49	✓
50	✗
51	-
52	-
53	-
54	-
55	-
56	-
57	-
58	-
59	-
60	-
61	-
62	-
63	-
64	-
65	-
66	-
67	-
68	-
69	-
70	-
71	-

All contents of this site are © 2024 Passmedicine Limited

A 57-year-old male presents with a three-month history of unintentional weight loss (13kg over 3 months) and a chronic non-productive cough. He has just returned from a months holiday in India. He denies haemoptysis or chest pain. He is a lifelong smoker. He has no past medical history except a period of generalised limb weakness two years ago when he was referred to outpatient neurology clinic and diagnosed with Lambert-Eaton myasthenic syndrome following investigations. His blood tests are unremarkable. However, his chest x-ray demonstrates a rounded opacity in his right midzone, about 4 cm from his right main bronchus.

What is the most likely diagnosis?

Tuberculosis	2%
Aspergilloma	4%
Small cell lung carcinoma	81%
Non-small cell carcinoma	12%
Pneumocystis jirovecii infection	1%

The patient was treated four years ago for Lambert-Eaton syndrome (LEMS), a neurological disorder characterised by limb weakness that improves with exercise, affecting proximal muscles more than distal muscle. It is caused by antibodies directed against voltage-gated calcium channels and has a strong association with malignancy. Up to half of all LEMS patients has an underlying malignancy, the most common of which is small cell lung carcinoma. Neurological symptoms often precede malignancy diagnosis by around 5 years.

1. O'Neill JH, Murray NM, Newsom-Davis J. The Lambert-Eaton myasthenic syndrome. A review of 50 cases. Brain. 1988;111 (Pt 3):577

Lung cancer: small cell

Features

- usually central
- arise from APUD* cells
- associated with ectopic ADH, ACTH secretion
- ADH → hyponatraemia
- ACTH → Cushing's syndrome
- ACTH secretion can cause bilateral adrenal hyperplasia, the high levels of cortisol can lead to hypokalaemic alkalosis
- Lambert-Eaton syndrome: antibodies to voltage gated calcium channels causing myasthenic like syndrome

Management

- usually metastatic disease by time of diagnosis
- patients with very early stage disease (T1-2a, N0, M0) are now considered for surgery. NICE support this approach in their 2011 guidelines
- however, most patients with limited disease receive a combination of chemotherapy and radiotherapy
- patients with more extensive disease are offered palliative chemotherapy

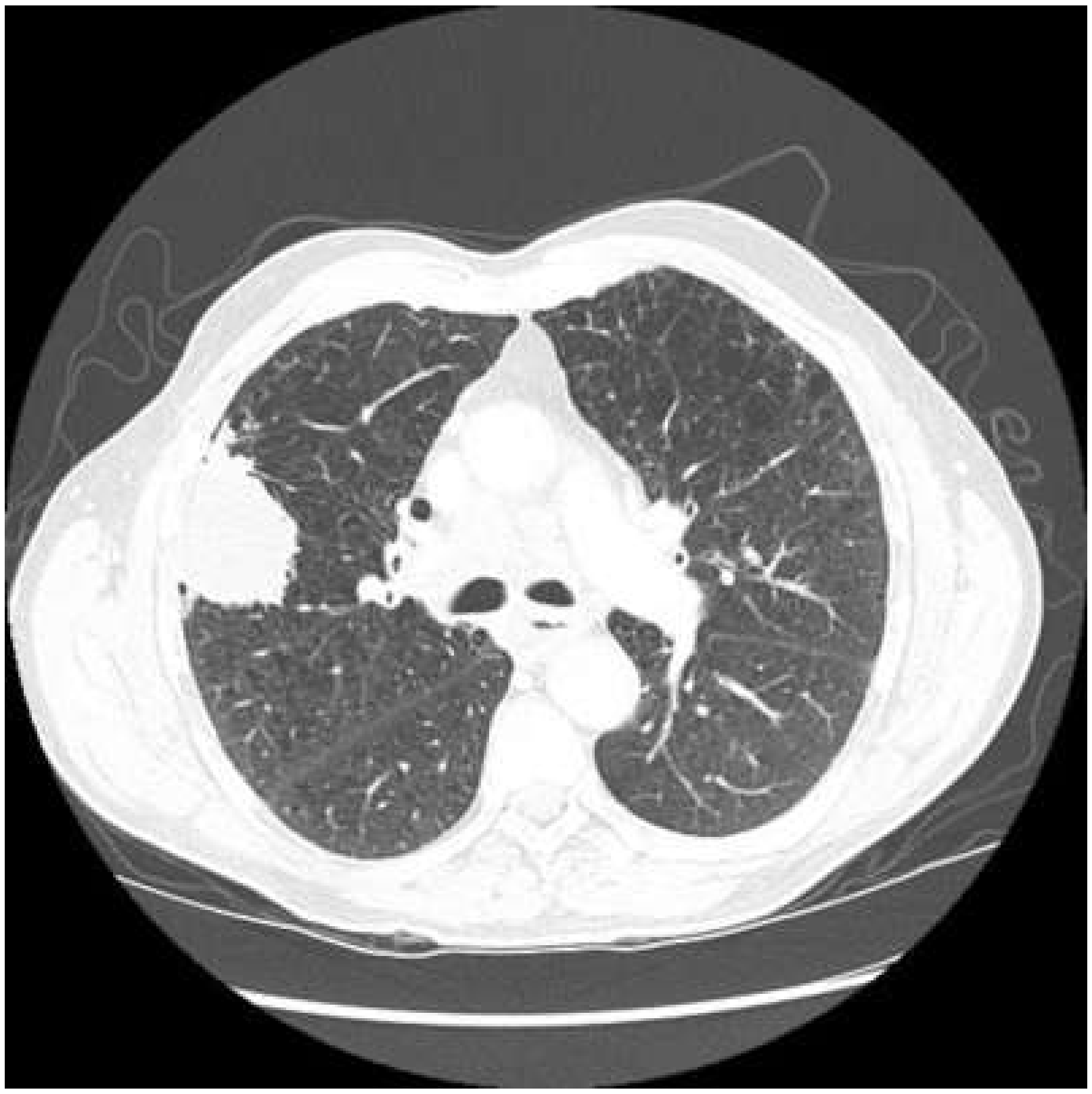

© Image used on license from Radiopaedia

CT scan showing small cell lung cancer with multiple pulmonary nodules and extensive mediastinal nodal metastases.

*an acronym for

- Amine - high amine content
- Precursor Uptake - high uptake of amine precursors
- Decarboxylase - high content of the enzyme decarboxylase

123

Next question

Textbooks

High-yield textbook

Extended textbook

Links

SIGN 3 5

2014 Lung cancer management guidelines

NICE 4 4

2011 Lung cancer guidelines

Suggest link

Report broken link

Media

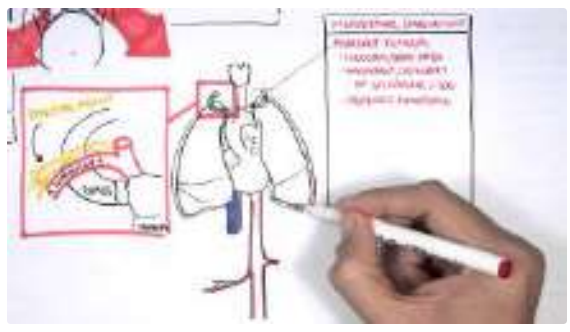

[Lung cancer]

Armando Hasudungan - YouTube 1 0

[Lung cancer]

MedFlix - YouTube 1 0

[Lung Cancer: An Overview]

Oncology for Medical Students - YouTube 1 0

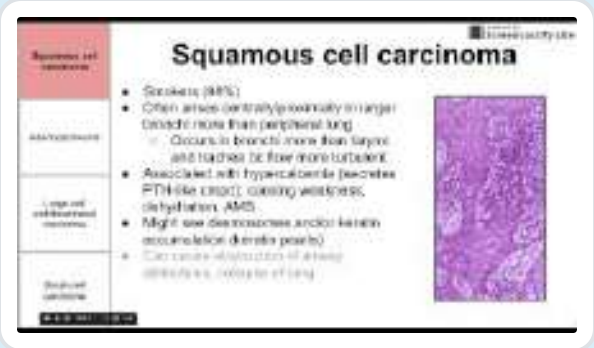

[Cancers of the lung]

MedLecturesMadeEasy - YouTube 3 2

Report broken media

Score: **17.3%**

1 ✕
2 ✕
3 ✕
4 ✕
5 ✕
6 ✕
7 ✕

8	✗
9	✗
10	✗
11	✗
12	✓
13	✗
14	✗
15	✗
16	✗
17	✗
18	✗
19	✗
20	✗
21	✗
22	✗
23	✓
24	✗
25	✗
26	✗
27	✗
28	✗
29	✓
30	✗
31	✓
32	✗
33	✗
34	✗
35	✗
36	✓
37	✓
38	✗
39	✗
40	✗
41	✓
42	✗
43	✗

44	✗
45	✗
46	✗
47	✗
48	✗
49	✓
50	✗
51	✗
52	✓
53	✗
54	✗
55	✓
56	✗
57	✗
58	✓
59	✗
60	✓
61	✗
62	✗
63	✗
64	✗
65	✗
66	✗
67	✗
68	✗
69	✗
70	✗
71	✗
72	✗
73	✗
74	✗
75	✓
76	✗
77	✗
78	✗
79	✓

80	✗
81	✗
82	✓
83	✗
84	✗
85	✗
86	✗
87	✗
88	✗
89	✗
90	✗
91	✗
92	✗
93	✓
94	✗
95	✓
96	✗
97	✗
98	✗
99	✗
100	✗
101	✗
102	✗
103	✓
104	✗
105	✗
106	✓
107	✗
108	✗
109	✗
110	✗
111	-

All contents of this site are © 2024 Passmedicine Limited

A 32-year-old taxi driver attends the emergency department with pleuritic right-sided chest pain. He is a current smoker of 15 cigarettes/day. He reports feeling unwell for 10 days with a cough and fever. The chest pain started gradually over the last 2 days becoming slowly more severe. A chest x-ray shows right sided consolidation and an effusion. He is commenced on penicillin antibiotics. Pleural aspirate under ultrasound guidance shows a simple effusion and the following results:

Appearance	Serous
pH	7.30
Protein	46 g/l
LDH	400 IU/l
Glucose	3.7mmol/l
Gram stain	No organisms or malignant cells seen
Culture	No growth

What is the next best step?

- Intercostal drain
- Continue antibiotics and observe
- CT thorax with contrast
- Repeat pleural aspirate in 24 hours
- Further investigation with bronchoscopy

Submit answer

Reference ranges

Score: **16%**

1	✗
2	✗
3	✗
4	✗
5	✗
6	✗
7	✗
8	✗
9	✗
10	✗
11	✗
12	✓
13	✗
14	✗
15	✗
16	✗
17	✗
18	✗
19	✗
20	✗
21	✗
22	✗
23	✓
24	✗
25	✗
26	✗
27	✗
28	✗
29	✓
30	✗
31	✓
32	✗
33	✗
34	✗

35	✗
36	✓
37	✓
38	✗
39	✗
40	✗
41	✓
42	✗
43	✗
44	✗
45	✗
46	✗
47	✗
48	✗
49	✓
50	✗
51	-
52	-
53	-
54	-
55	-
56	-
57	-
58	-
59	-
60	-
61	-
62	-
63	-
64	-
65	-
66	-
67	-
68	-
69	-
70	-
71	-
72	-

All contents of this site are © 2024 Passmedicine Limited

A 32-year-old taxi driver attends the emergency department with pleuritic right-sided chest pain. He is a current smoker of 15 cigarettes/day. He reports feeling unwell for 10 days with a cough and fever. The chest pain started gradually over the last 2 days becoming slowly more severe. A chest x-ray shows right sided consolidation and an effusion. He is commenced on penicillin antibiotics. Pleural aspirate under ultrasound guidance shows a simple effusion and the following results:

Appearance	Serous
pH	7.30
Protein	46 g/l
LDH	400 IU/l
Glucose	3.7mmol/l
Gram stain	No organisms or malignant cells seen
Culture	No growth

What is the next best step?

- Intercostal drain 20%
- Continue antibiotics and observe 50%
- CT thorax with contrast 24%
- Repeat pleural aspirate in 24 hours 2%
- Further investigation with bronchoscopy 3%

This patient has evidence of pneumonia. The unilateral effusion is confirmed as an exudate and can be assumed to be a parapneumonic effusion. There is no indication for chest drain currently (purulent fluid, pH<7.2, organisms on Gram stain or culture) so he can continue antibiotics and be observed. If he fails to improve he would need repeat pleural sampling. If there was no clear infective cause a CT thorax with contrast would be performed to look for underlying malignancy. Bronchoscopy is only performed when there is suspicion of bronchial obstruction.

Discuss (6) Improve

Next question

Pleural effusion: investigation and management

The British Thoracic Society (BTS) produced guidelines in 2010 covering the investigation of patients with a pleural effusion.

Imaging
- posterioranterior (PA) chest x-rays should be performed in all patients
- ultrasound is recommended: it increases the likelihood of successful pleural aspiration and is sensitive for detecting pleural fluid septations
- contrast CT is now increasingly performed to investigate the underlying cause, particularly for exudative effusions

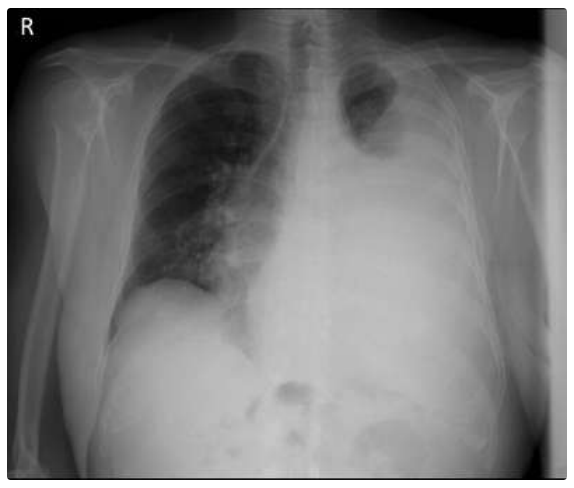

Pleural aspiration
- as above, ultrasound is recommended to reduce the complication rate
- a 21G needle and 50ml syringe should be used
- fluid should be sent for pH, protein, lactate dehydrogenase (LDH), cytology and microbiology

Light's criteria was developed in 1972 to help distinguish between a transudate and an exudate. The BTS recommend using the criteria for borderline cases:
- exudates have a protein level of >30 g/L, transudates have a protein level of <30 g/L
- if the protein level is between 25-35 g/L, Light's criteria should be applied. An exudate is likely if at least one of the following criteria are met:
  - pleural fluid protein divided by serum protein >0.5
  - pleural fluid LDH divided by serum LDH >0.6
  - pleural fluid LDH more than two-thirds the upper limits of normal serum LDH

Other characteristic pleural fluid findings:
- low glucose: rheumatoid arthritis, tuberculosis

- raised amylase: pancreatitis, oesophageal perforation
- heavy blood staining: mesothelioma, pulmonary embolism, tuberculosis

Pleural infection

All patients with a pleural effusion in association with sepsis or a pneumonic illness require diagnostic pleural fluid sampling

- if the fluid is purulent or turbid/cloudy a chest tube should be placed to allow drainage
- if the fluid is clear but the **pH is less than 7.2 in patients with suspected pleural infection a chest tube should be placed**

Management of recurrent pleural effusion

Options for managing patients with recurrent pleural effusions include:

- recurrent aspiration
- pleurodesis
- indwelling pleural catheter
- drug management to alleviate symptoms e.g. opioids to relieve dyspnoea

+ Q 123

Next question ›

Textbooks

High-yield textbook

Extended textbook

Links

British Thoracic Society 17 14

2023 Pleural disease guidelines

Royal College of Physicians 13 7

2012 Pleural infection review

Suggest link | Report broken link

Media

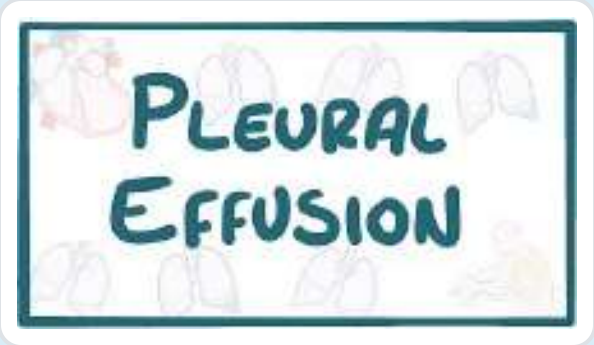

Pleural effusion

Osmosis - YouTube 8 1

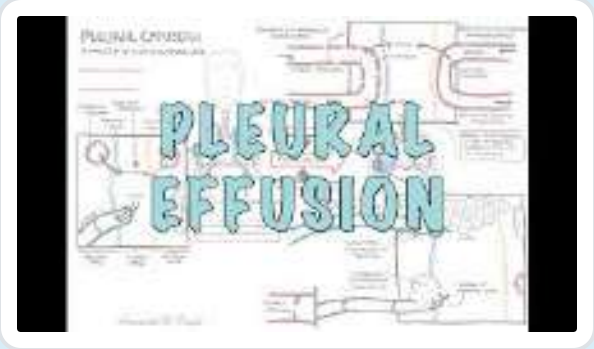

Pleural effusion

Armando Hasudungan - YouTube 6 1

Report broken media

Score: **17.3%**

1 ✗
2 ✗
3 ✗
4 ✗
5 ✗
6 ✗
7 ✗

8	✗
9	✗
10	✗
11	✗
12	✓
13	✗
14	✗
15	✗
16	✗
17	✗
18	✗
19	✗
20	✗
21	✗
22	✗
23	✓
24	✗
25	✗
26	✗
27	✗
28	✗
29	✓
30	✗
31	✓
32	✗
33	✗
34	✗
35	✗
36	✓
37	✓
38	✗
39	✗
40	✗
41	✓
42	✗
43	✗

44	✗
45	✗
46	✗
47	✗
48	✗
49	✓
50	✗
51	✗
52	✓
53	✗
54	✗
55	✓
56	✗
57	✗
58	✓
59	✗
60	✓
61	✗
62	✗
63	✗
64	✗
65	✗
66	✗
67	✗
68	✗
69	✗
70	✗
71	✗
72	✗
73	✗
74	✗
75	✓
76	✗
77	✗
78	✗
79	✓

80	✗
81	✗
82	✓
83	✗
84	✗
85	✗
86	✗
87	✗
88	✗
89	✗
90	✗
91	✗
92	✗
93	✓
94	✗
95	✓
96	✗
97	✗
98	✗
99	✗
100	✗
101	✗
102	✗
103	✓
104	✗
105	✗
106	✓
107	✗
108	✗
109	✗
110	✗
111	-

All contents of this site are © 2024 Passmedicine Limited

A 45-year-old lady presented to clinic with a four-month history of worsening cough with blood-stained sputum and exertional dyspnoea. She reported having lost over 8 kg in weight during this time, with a reduced appetite. She started smoking as a teenager and currently has 15 cigarettes daily. She has been diagnosed with small cell lung cancer. Her staging CT reveals a classification of T1a N2 M0. She attends for a follow-up appointment to see you in the oncology clinic. Which of the following treatment options should be considered first line?

- Pembrolizumab
- Cisplatin
- Consider surgery
- Thoracic radiotherapy
- Palliation of symptoms

Submit answer

Reference ranges

Score: **16%**

1 ✗
2 ✗
3 ✗
4 ✗
5 ✗
6 ✗
7 ✗
8 ✗

9 ✗
10 ✗
11 ✗
12 ✓
13 ✗
14 ✗
15 ✗
16 ✗
17 ✗
18 ✗
19 ✗
20 ✗
21 ✗
22 ✗
23 ✓
24 ✗
25 ✗
26 ✗
27 ✗
28 ✗
29 ✓
30 ✗
31 ✓
32 ✗
33 ✗
34 ✗
35 ✗
36 ✓
37 ✓
38 ✗
39 ✗
40 ✗
41 ✓
42 ✗
43 ✗
44 ✗

45	✗
46	✗
47	✗
48	✗
49	✓
50	✗
51	-
52	-
53	-
54	-
55	-
56	-
57	-
58	-
59	-
60	-
61	-
62	-
63	-
64	-
65	-
66	-
67	-
68	-
69	-
70	-
71	-
72	-
73	-

All contents of this site are © 2024 Passmedicine Limited

Back to top

A 45-year-old lady presented to clinic with a four-month history of worsening cough with blood-stained sputum and exertional dyspnoea. She reported having lost over 8 kg in weight during this time, with a reduced appetite. She started smoking as a teenager and currently has 15 cigarettes daily. She has been diagnosed with small cell lung cancer. Her staging CT reveals a classification of T1a N2 M0. She attends for a follow-up appointment to see you in the oncology clinic. Which of the following treatment options should be considered first line?

- Pembrolizumab 7%
- Cisplatin 33%
- Consider surgery 42%
- Thoracic radiotherapy 15%
- Palliation of symptoms 3%

Stage	Treatment
Early stage (T1-2a,N0,M0)	Surgery
Early stage (T1-2a,N0,M0)- Limited disease (T1-4,N0-3,M0)	4-6 cycles cisplatin based chemotherapy carboplatin if poor renal function/poor performance status +/- radiotherapy
Extensive disease (T1-4, N0-3, M1a/b)	6 cycles platinum based combination chemotherapy + thoracic radiotherapy if good response

Pembrolizumab is an example of an immunosuppressant therapy currently being researched for use in non-small cell lung cancer.

NICE 2011 Lung cancer guideline 121
Pembrolizumab for the Treatment of NonSmall-Cell Lung Cancer NEJMhttp://www.nejm.org/doi/full/10.1056/NEJMoa1501824

Discuss (7) Improve

Next question >

Lung cancer: small cell

Features

- usually central
- arise from APUD* cells
- associated with ectopic ADH, ACTH secretion
- ADH → hyponatraemia
- ACTH → Cushing's syndrome
- ACTH secretion can cause bilateral adrenal hyperplasia, the high levels of cortisol can lead to hypokalaemic alkalosis
- Lambert-Eaton syndrome: antibodies to voltage gated calcium channels causing myasthenic like syndrome

Management

- usually metastatic disease by time of diagnosis
- patients with very early stage disease (T1-2a, N0, M0) are now considered for surgery. NICE support this approach in their 2011 guidelines
- however, most patients with limited disease receive a combination of chemotherapy and radiotherapy
- patients with more extensive disease are offered palliative chemotherapy

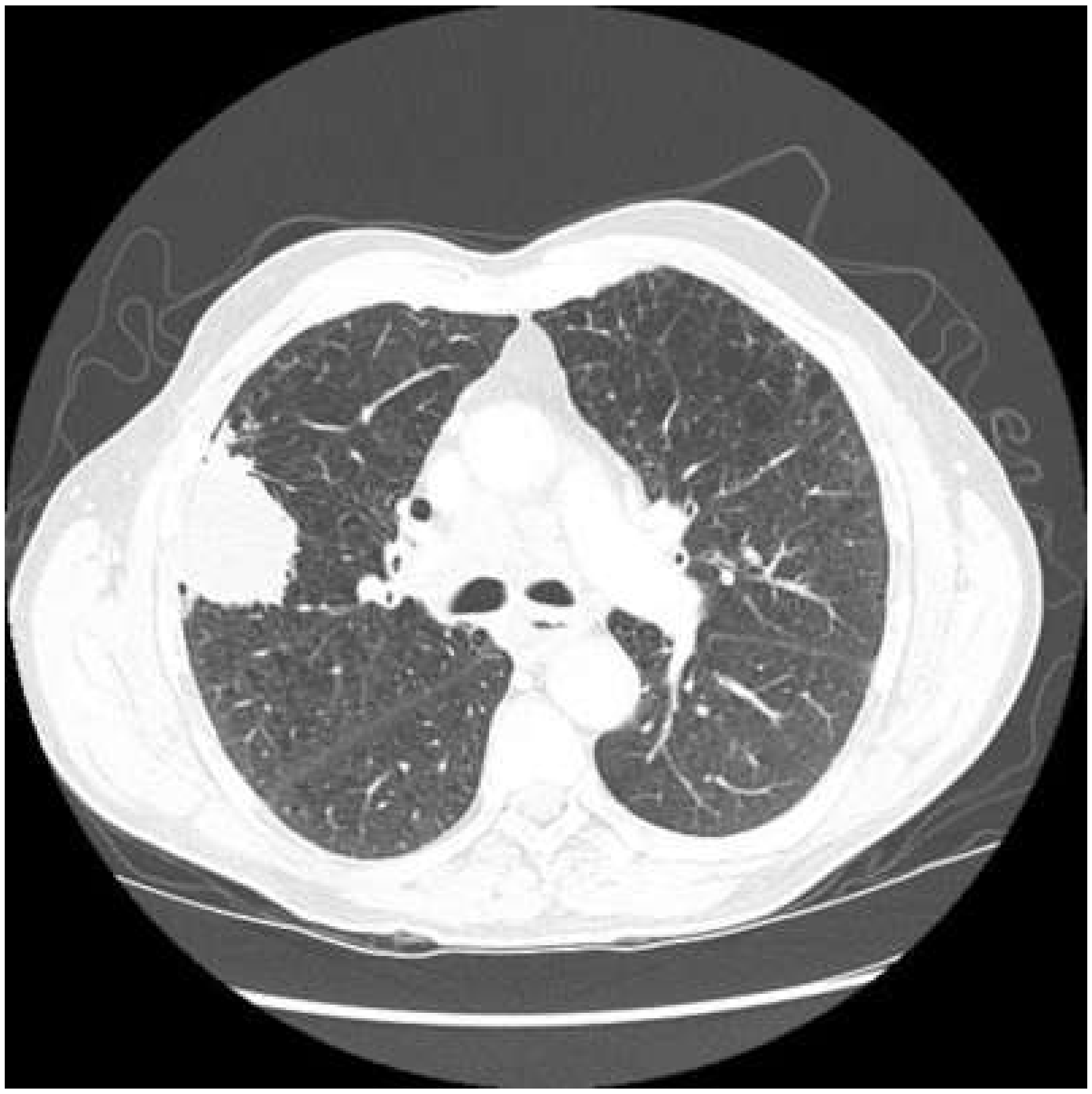

© Image used on license from Radiopaedia

CT scan showing small cell lung cancer with multiple pulmonary nodules and extensive mediastinal nodal metastases.

*an acronym for

- Amine - high amine content
- Precursor Uptake - high uptake of amine precursors
- Decarboxylase - high content of the enzyme decarboxylase

123

Next question

Textbooks

High-yield textbook

Extended textbook

Links

SIGN 3 5

2014 Lung cancer management guidelines

NICE 4 4

2011 Lung cancer guidelines

Suggest link

Report broken link

Media

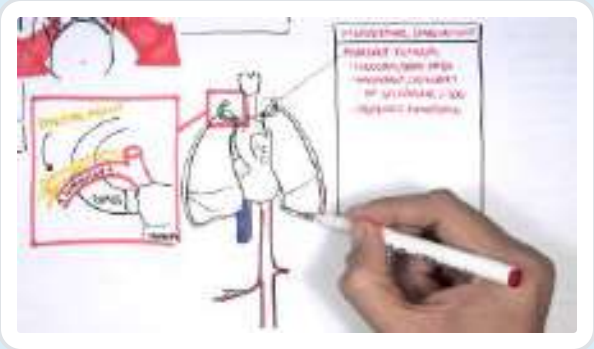

Lung cancer

Armando Hasudungan - YouTube 1 0

Lung cancer

MedFlix - YouTube 1 0

Lung Cancer: An Overview

Oncology for Medical Students - YouTube 1 0

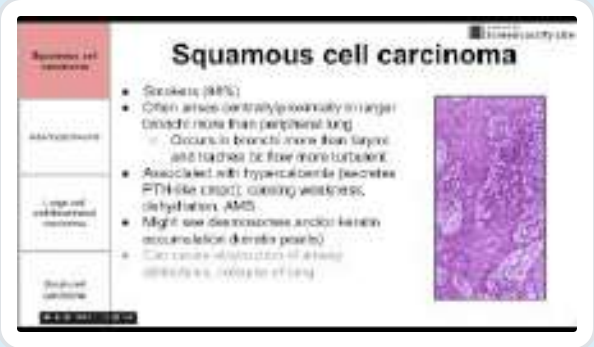

Cancers of the lung

MedLecturesMadeEasy - YouTube 3 2

Report broken media

Score: **17.3%**

1 ✗
2 ✗
3 ✗
4 ✗

5	✗
6	✗
7	✗
8	✗
9	✗
10	✗
11	✗
12	✓
13	✗
14	✗
15	✗
16	✗
17	✗
18	✗
19	✗
20	✗
21	✗
22	✗
23	✓
24	✗
25	✗
26	✗
27	✗
28	✗
29	✓
30	✗
31	✓
32	✗
33	✗
34	✗
35	✗
36	✓
37	✓
38	✗
39	✗
40	✗

41 ✓
42 ✗
43 ✗
44 ✗
45 ✗
46 ✗
47 ✗
48 ✗
49 ✓
50 ✗
51 ✗
52 ✓
53 ✗
54 ✗
55 ✓
56 ✗
57 ✗
58 ✓
59 ✗
60 ✓
61 ✗
62 ✗
63 ✗
64 ✗
65 ✗
66 ✗
67 ✗
68 ✗
69 ✗
70 ✗
71 ✗
72 ✗
73 ✗
74 ✗
75 ✓
76 ✗

77	✗
78	✗
79	✓
80	✗
81	✗
82	✓
83	✗
84	✗
85	✗
86	✗
87	✗
88	✗
89	✗
90	✗
91	✗
92	✗
93	✓
94	✗
95	✓
96	✗
97	✗
98	✗
99	✗
100	✗
101	✗
102	✗
103	✓
104	✗
105	✗
106	✓
107	✗
108	✗
109	✗
110	✗
111	-

All contents of this site are © 2024 Passmedicine Limited

A 28-year-old presents to Accident and Emergency with symptoms of increasing shortness of breath, wheeze and a cough.

This is her first hospital attendance with asthma which is usually well controlled. She has a past medical history of perennial rhinitis.

She has no known drug allergies and takes beclomethasone (200 micrograms inhaled twice a day) and salbutamol which she rarely uses. She has never smoked

On examination her respiratory rate is 24, her pulse is 98 bpm and has widespread wheeze on auscultation of her chest. Her oxygen saturations on air are 93%. She is quiet, anxious and seems disoriented.

Blood tests reveal a raised white cell count of 11 x 10^9/L, her chest x-ray is normal.

She is started on nebulised salbutamol and ipratropium bromide and given an oral dose of prednisolone.

An arterial blood gas is taken 5 minutes after being started on 40% oxygen:

pH	7.36
PaO2	16.0 kPa
PaCO2	5.98 kPa
Bicarbonate	19 mmol/l

What would be the most appropriate next step?

- Secure a cannula and give 200mg of hydrocortisone IV
- Start empirical antibiotics
- Magnesium infusion
- Arrange a review by an anaesthetists/intensivist

Repeat an arterial blood gas after 10 minutes

Submit answer

Reference ranges

Score: **16%**

1	✗
2	✗
3	✗
4	✗
5	✗
6	✗
7	✗
8	✗
9	✗
10	✗
11	✗
12	✓
13	✗
14	✗
15	✗
16	✗
17	✗
18	✗
19	✗
20	✗
21	✗
22	✗
23	✓
24	✗
25	✗

26	✗
27	✗
28	✗
29	✓
30	✗
31	✓
32	✗
33	✗
34	✗
35	✗
36	✓
37	✓
38	✗
39	✗
40	✗
41	✓
42	✗
43	✗
44	✗
45	✗
46	✗
47	✗
48	✗
49	✓
50	✗
51	-
52	-
53	-
54	-
55	-
56	-
57	-
58	-
59	-
60	-
61	-
62	-

63 -
64 -
65 -
66 -
67 -
68 -
69 -
70 -
71 -
72 -
73 -
74 -

All contents of this site are © 2024 Passmedicine Limited

A 28-year-old presents to Accident and Emergency with symptoms of increasing shortness of breath, wheeze and a cough.

This is her first hospital attendance with asthma which is usually well controlled. She has a past medical history of perennial rhinitis.

She has no known drug allergies and takes beclomethasone (200 micrograms inhaled twice a day) and salbutamol which she rarely uses. She has never smoked

On examination her respiratory rate is 24, her pulse is 98 bpm and has widespread wheeze on auscultation of her chest. Her oxygen saturations on air are 93%. She is quiet, anxious and seems disoriented.

Blood tests reveal a raised white cell count of 11 x 10^9/L, her chest x-ray is normal.

She is started on nebulised salbutamol and ipratropium bromide and given an oral dose of prednisolone.

An arterial blood gas is taken 5 minutes after being started on 40% oxygen:

pH	7.36
PaO2	16.0 kPa
PaCO2	5.98 kPa
Bicarbonate	19 mmol/l

What would be the most appropriate next step?

Secure a cannula and give 200mg of hydrocortisone IV	8%
Start empirical antibiotics	2%
Magnesium infusion	22%
Arrange a review by an anaesthetists/intensivist	62%

Repeat an arterial blood gas after 10 minutes 6%

The PaCO2 level which is at the upper limit of normal is very worrying and categorises this patient as having life-threatening asthma according to British Thoracic Society (BTS) guidelines. While a magnesium infusion may be of benefit, the description that she is anxious and possibly disoriented are concerning features and may indicate that shes tiring. In light of this getting a timely review by an anaesthetist/intensivist is of the utmost importance and should be the next immediate step. Giving hydrocortisone intravenously is unlikely to be of any benefit and considering antibiotics is not a priority in this situation where time is of the essence. Hence waiting another 10 minutes to do another arterial blood gas with to preceding action may potentially be fatal.

Discuss (4) Improve

Next question

Acute asthma: management

The British Thoracic Society (BTS) classify patients with acute asthma into moderate, severe or life-threatening categories.

Moderate	Severe	Life-threatening
PEFR 50-75% best or predicted Speech normal RR < 25 / min Pulse < 110 bpm	PEFR 33 - 50% best or predicted Can't complete sentences RR > 25/min Pulse > 110 bpm	PEFR < 33% best or predicted Oxygen sats < 92% 'Normal' $pC0_2$ (4.6-6.0 kPa) Silent chest, cyanosis or feeble respiratory effort Bradycardia, dysrhythmia or hypotension Exhaustion, confusion or coma

Note that a patient having any one of the life-threatening features should be treated as having a life-threatening attack.

A fourth category, '**Near-fatal asthma**', is also recognised characterised by a raised $pC0_2$ and/or requiring mechanical ventilation with raised inflation pressures.

Further assessment

- the BTS guidelines recommend arterial blood gases for patients with oxygen sats < 92%
- a chest x-ray is not routinely recommended, unless:
    - life-threatening asthma
    - suspected pneumothorax
    - failure to respond to treatment

Management

- admission
    - all patients with life-threatening should be admitted in hospital
    - patients with features of severe acute asthma should also be admitted if they fail to respond to initial treatment.
    - other admission criteria include a previous near-fatal asthma attack, pregnancy, an attack occurring despite already using oral corticosteroid and presentation at night
- oxygen
    - if patients are hypoxaemic, it is important to start them on supplemental oxygen therapy
    - if patients are acutely unwell they should be started on 15L of supplemental via a non-rebreathe mask, which can then be titrated down to a flow rate where they are able to maintain a SpO,, 94-98%.
- bronchodilation with short-acting beta,,-agonists (SABA)
    - high-dose inhaled SABA e.g. salbutamol, terbutaline
    - in patients without features of life-threatening or near-fatal asthma, this can be given by a standard pressurised metered-dose inhaler (pMDI) or by an oxygen-driven nebulizer
    - in patients with features of a life-threatening exacerbation of asthma, nebulised SABA is recommended
- corticosteroid
    - all patients should be given 40-50mg of prednisolone orally (PO) daily, which should be continued for at least five days or until the patient recovers from the attack
    - during this time, patients should continue their normal medication routine including inhaled corticosteroids.
- ipratropium bromide: in patients with severe or life-threatening asthma, or in patients who have not responded to beta,,-agonist and corticosteroid treatment, nebulised ipratropium bromide, a short-acting muscarinic antagonist
- IV magnesium sulphate
    - the BTS notes that the evidence base is mixed for this treatment that is now commonly given for severe/life-threatening asthma
- IV aminophylline may be considered following consultation with senior medical staff
- patients who fail to respond require senior critical care support and should be treated in an appropriate ITU/HDU setting. Treatment options include:
    - intubation and ventilation
    - extracorporeal membrane oxygenation (ECMO)

Criteria for discharge

- been stable on their discharge medication (i.e. no nebulisers or oxygen) for 12-24 hours
- inhaler technique checked and recorded
- PEF >75% of best or predicted

AI + Q 123

Next question >

B I A

Textbooks

High-yield textbook

Extended textbook

Links

British Thoracic Society 44 73

2019 Asthma guidelines

Suggest link Report broken link

Score: **17.3%**

1 ✗
2 ✗
3 ✗
4 ✗
5 ✗
6 ✗

7	✗
8	✗
9	✗
10	✗
11	✗
12	✓
13	✗
14	✗
15	✗
16	✗
17	✗
18	✗
19	✗
20	✗
21	✗
22	✗
23	✓
24	✗
25	✗
26	✗
27	✗
28	✗
29	✓
30	✗
31	✓
32	✗
33	✗
34	✗
35	✗
36	✓
37	✓
38	✗
39	✗
40	✗
41	✓
42	✗

43	✗
44	✗
45	✗
46	✗
47	✗
48	✗
49	✓
50	✗
51	✗
52	✓
53	✗
54	✗
55	✓
56	✗
57	✗
58	✓
59	✗
60	✓
61	✗
62	✗
63	✗
64	✗
65	✗
66	✗
67	✗
68	✗
69	✗
70	✗
71	✗
72	✗
73	✗
74	✗
75	✓
76	✗
77	✗
78	✗

79	✓
80	✗
81	✗
82	✓
83	✗
84	✗
85	✗
86	✗
87	✗
88	✗
89	✗
90	✗
91	✗
92	✗
93	✓
94	✗
95	✓
96	✗
97	✗
98	✗
99	✗
100	✗
101	✗
102	✗
103	✓
104	✗
105	✗
106	✓
107	✗
108	✗
109	✗
110	✗
111	-

All contents of this site are © 2024 Passmedicine Limited

Back to top

A 57-year-old woman is admitted with an infective exacerbation of bronchiectasis. Multiple sputum cultures in the community have grown *Pseudomonas aeruginosa* and her GP had started oral ciprofloxacin. However, despite 4 days of this, she has developed worsening breathlessness, hypoxia, and fever and is now requiring oxygen.

Widespread coarse crepitations are heard and her chest x-ray demonstrates bilateral infiltrates.

What is the most appropriate course of action?

- Add IV clarithromycin
- Add IV vancomycin
- Add high-dose trimethoprim/sulphamethoxazole and prednisolone
- Change to IV ertapenem
- Change to IV piperacillin-tazobactam

Submit answer

Reference ranges

Score: **16%**

1 ✗
2 ✗
3 ✗
4 ✗
5 ✗
6 ✗

7	✗
8	✗
9	✗
10	✗
11	✗
12	✓
13	✗
14	✗
15	✗
16	✗
17	✗
18	✗
19	✗
20	✗
21	✗
22	✗
23	✓
24	✗
25	✗
26	✗
27	✗
28	✗
29	✓
30	✗
31	✓
32	✗
33	✗
34	✗
35	✗
36	✓
37	✓
38	✗
39	✗
40	✗
41	✓
42	✗

43	✗
44	✗
45	✗
46	✗
47	✗
48	✗
49	✓
50	✗
51	-
52	-
53	-
54	-
55	-
56	-
57	-
58	-
59	-
60	-
61	-
62	-
63	-
64	-
65	-
66	-
67	-
68	-
69	-
70	-
71	-
72	-
73	-
74	-
75	-

All contents of this site are © 2024 Passmedicine Limited

A 57-year-old woman is admitted with an infective exacerbation of bronchiectasis. Multiple sputum cultures in the community have grown *Pseudomonas aeruginosa* and her GP had started oral ciprofloxacin. However, despite 4 days of this, she has developed worsening breathlessness, hypoxia, and fever and is now requiring oxygen.

Widespread coarse crepitations are heard and her chest x-ray demonstrates bilateral infiltrates.

What is the most appropriate course of action?

Add IV clarithromycin	7%
Add IV vancomycin	5%
Add high-dose trimethoprim/sulphamethoxazole and prednisolone	14%
Change to IV ertapenem	11%
Change to IV piperacillin-tazobactam	63%

Appropriate treatment of *Pseudomonas* positive bronchiectasis failing to respond to ciprofloxacin includes IV tazocin, ceftazidime, aztreonam or meropenem

Important for me Less important

The correct answer is **change to IV piperacillin-tazobactam**. *Pseudomonas aeruginosa* is a recognised cause of complex respiratory tract infections in patients with bronchiectasis or cystic fibrosis. Where oral treatment with ciprofloxacin fails, options include IV piperacillin-tazobactam, ceftazidime, or meropenem.

Add IV clarithromycin is incorrect. This is active against common pathogens causing community-acquired pneumonia as well as some atypical organisms. However, in this case, an organism has been isolated and it would be more appropriate to convert to IV therapy active against this. The combination of clarithromycin with quinolones also increases the risk of QT interval prolongation.

Add IV vancomycin is incorrect. This has purely gram-positive cover and is not active against *Pseudomonas aeruginosa*.

Add high-dose trimethoprim/sulphamethoxazole and prednisolone is incorrect. This would be

the optimal treatment for *Pneumocystis jirovecii* which can cause severe bilateral pneumonia. However, it is most commonly seen as an opportunistic infection in patients with impaired cell-mediated immunity, classically patients with HIV infection. In this case, there is no suggestion of significant immunocompromise and a typical pathogen has been isolated. It is therefore more appropriate to target therapy against this organism.

Change to IV ertapenem is incorrect. Ertapenem is a carbapenem (the same class as meropenem) with extremely broad-spectrum antimicrobial activity. However, the main difference between ertapenem and meropenem is that the former lacks activity against *Pseudomonas* species. It would therefore not be effective in this case.

Discuss (3) Improve

Next question

Bronchiectasis: management

Bronchiectasis describes a permanent dilatation of the airways secondary to chronic infection or inflammation. After assessing for treatable causes (e.g. immune deficiency) management is as follows:

- physical training (e.g. inspiratory muscle training) - has a good evidence base for patients with non-cystic fibrosis bronchiectasis
- postural drainage
- antibiotics for exacerbations + long-term rotating antibiotics in severe cases
- bronchodilators in selected cases
- immunisations
- surgery in selected cases (e.g. Localised disease)

Most common organisms isolated from patients with bronchiectasis:

- *Haemophilus influenzae* (most common)
- *Pseudomonas aeruginosa*
- Klebsiella spp.
- *Streptococcus pneumoniae*

AI + Q 123

Next question

Textbooks

High-yield textbook

Extended textbook

Links

British Thoracic Society 1 0

2018 Bronchiectasis guidelines

Clinical Knowledge Summaries 1 1

Bronchiectasis guidelines

Suggest link Report broken link

Media

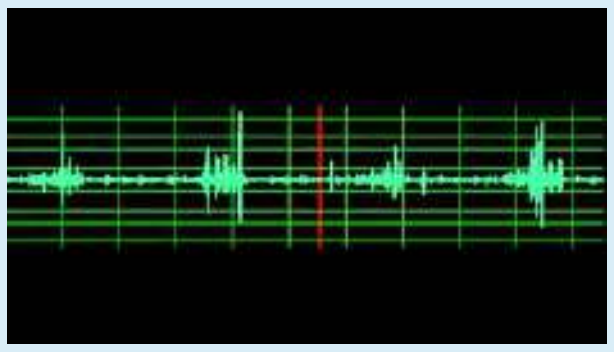

Bronchiectasis crackles - REQUIRES HEADPHONES

Thinklabs - YouTube 4 0

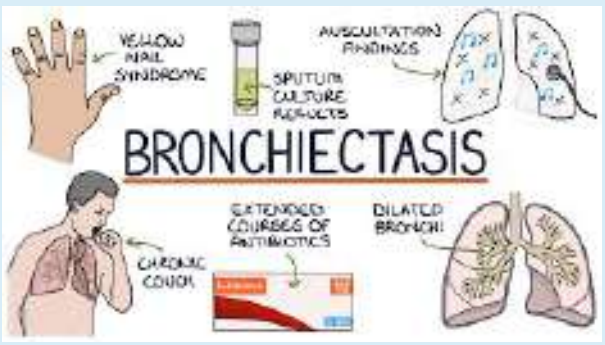

Bronchiectasis

Zero To Finals - YouTube 0 0

Bronchiectasis - causes, pathophysiology, signs and symptoms, investigations and treatment

Armando Hasudungan - YouTube 3 1

Report broken media

Score: **17.3%**

1	✗
2	✗
3	✗
4	✗
5	✗
6	✗
7	✗
8	✗
9	✗
10	✗
11	✗
12	✓
13	✗
14	✗
15	✗
16	✗
17	✗
18	✗
19	✗
20	✗
21	✗
22	✗
23	✓
24	✗

25	✗
26	✗
27	✗
28	✗
29	✓
30	✗
31	✓
32	✗
33	✗
34	✗
35	✗
36	✓
37	✓
38	✗
39	✗
40	✗
41	✓
42	✗
43	✗
44	✗
45	✗
46	✗
47	✗
48	✗
49	✓
50	✗
51	✗
52	✓
53	✗
54	✗
55	✓
56	✗
57	✗
58	✓
59	✗
60	✓

61	✗
62	✗
63	✗
64	✗
65	✗
66	✗
67	✗
68	✗
69	✗
70	✗
71	✗
72	✗
73	✗
74	✗
75	✓
76	✗
77	✗
78	✗
79	✓
80	✗
81	✗
82	✓
83	✗
84	✗
85	✗
86	✗
87	✗
88	✗
89	✗
90	✗
91	✗
92	✗
93	✓
94	✗
95	✓
96	✗

97	✗
98	✗
99	✗
100	✗
101	✗
102	✗
103	✓
104	✗
105	✗
106	✓
107	✗
108	✗
109	✗
110	✗
111	-

All contents of this site are © 2024 Passmedicine Limited

Back to top

A 45-year-old woman presents to the emergency department with abdominal pain. It is severe and progressed to its maximum intensity over six hours. She has not noticed any associated vomiting or diarrhoea. She last opened her bowels yesterday. She has a history of alcoholic liver disease and has had previous admissions for decompensated liver failure. She is not jaundiced or confused currently. She has generalised abdominal tenderness, worse towards the epigastrium. A chest X-ray demonstrates a right-sided pleural effusion. It is aspirated and found to have a protein count of 37g/l. What is the most likely cause of the effusion?

- Meig's syndrome
- Hepatic failure
- Pancreatitis
- Nephrotic syndrome
- Metastatic cancer

Submit answer

Reference ranges

Score: **16%**

1 ✕
2 ✕
3 ✕
4 ✕
5 ✕
6 ✕
7 ✕

8	✗
9	✗
10	✗
11	✗
12	✓
13	✗
14	✗
15	✗
16	✗
17	✗
18	✗
19	✗
20	✗
21	✗
22	✗
23	✓
24	✗
25	✗
26	✗
27	✗
28	✗
29	✓
30	✗
31	✓
32	✗
33	✗
34	✗
35	✗
36	✓
37	✓
38	✗
39	✗
40	✗
41	✓
42	✗
43	✗

44	✗
45	✗
46	✗
47	✗
48	✗
49	✓
50	✗
51	-
52	-
53	-
54	-
55	-
56	-
57	-
58	-
59	-
60	-
61	-
62	-
63	-
64	-
65	-
66	-
67	-
68	-
69	-
70	-
71	-
72	-
73	-
74	-
75	-
76	-

All contents of this site are © 2024 Passmedicine Limited

Back to top

A 45-year-old woman presents to the emergency department with abdominal pain. It is severe and progressed to its maximum intensity over six hours. She has not noticed any associated vomiting or diarrhoea. She last opened her bowels yesterday. She has a history of alcoholic liver disease and has had previous admissions for decompensated liver failure. She is not jaundiced or confused currently. She has generalised abdominal tenderness, worse towards the epigastrium. A chest X-ray demonstrates a right-sided pleural effusion. It is aspirated and found to have a protein count of 37g/l. What is the most likely cause of the effusion?

Meig's syndrome	22%
Hepatic failure	9%
Pancreatitis	55%
Nephrotic syndrome	1%
Metastatic cancer	13%

The correct answer is pancreatitis. This is a patient with epigastric abdominal pain and an exudative pleural effusion on a background of heavy alcohol intake. Exudative effusions occur due to increased leakiness of pleural capillaries. This can be due to infection, inflammation or malignancy. Of the available options, this includes pancreatitis and metastatic cancer. Transudates are caused by increased venous pressure, occurring in cardiac failure, renal failure, hepatic failure, as well as in Meig's syndrome, hypothyroidism and fluid overload. Given the epigastric pain and alcohol history, pancreatitis is a more likely cause than cancer and should be confirmed with serum and fluid amylase.

Discuss (4) Improve

Next question

Pleural effusion: investigation and management

The British Thoracic Society (BTS) produced guidelines in 2010 covering the investigation of patients with a pleural effusion.

Imaging

- posterioranterior (PA) chest x-rays should be performed in all patients
- ultrasound is recommended: it increases the likelihood of successful pleural aspiration and is sensitive for detecting pleural fluid septations
- contrast CT is now increasingly performed to investigate the underlying cause, particularly for exudative effusions

Pleural aspiration

- as above, ultrasound is recommended to reduce the complication rate
- a 21G needle and 50ml syringe should be used
- fluid should be sent for pH, protein, lactate dehydrogenase (LDH), cytology and microbiology

Light's criteria was developed in 1972 to help distinguish between a transudate and an exudate. The BTS recommend using the criteria for borderline cases:

- exudates have a protein level of >30 g/L, transudates have a protein level of <30 g/L
- if the protein level is between 25-35 g/L, Light's criteria should be applied. An exudate is likely if at least one of the following criteria are met:
  - pleural fluid protein divided by serum protein >0.5
  - pleural fluid LDH divided by serum LDH >0.6
  - pleural fluid LDH more than two-thirds the upper limits of normal serum LDH

Other characteristic pleural fluid findings:

- low glucose: rheumatoid arthritis, tuberculosis
- raised amylase: pancreatitis, oesophageal perforation
- heavy blood staining: mesothelioma, pulmonary embolism, tuberculosis

Pleural infection

All patients with a pleural effusion in association with sepsis or a pneumonic illness require diagnostic pleural fluid sampling

- if the fluid is purulent or turbid/cloudy a chest tube should be placed to allow drainage

- if the fluid is clear but the **pH is less than 7.2 in patients with suspected pleural infection a chest tube should be placed**

Management of recurrent pleural effusion

Options for managing patients with recurrent pleural effusions include:
- recurrent aspiration
- pleurodesis
- indwelling pleural catheter
- drug management to alleviate symptoms e.g. opioids to relieve dyspnoea

+ Q 123

Next question >

Textbooks

High-yield textbook

Extended textbook

Links

British Thoracic Society 17 14

2023 Pleural disease guidelines

Royal College of Physicians 13 7

2012 Pleural infection review

Suggest link Report broken link

Media

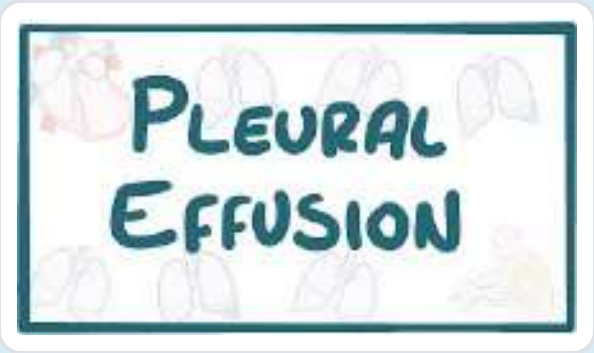

Pleural effusion

Osmosis - YouTube 8 1

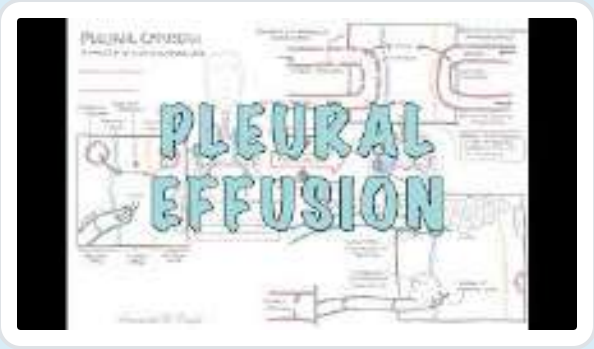

Pleural effusion

Armando Hasudungan - YouTube 6 1

Report broken media

Score: **17.3%**

1 ✗
2 ✗
3 ✗
4 ✗
5 ✗
6 ✗
7 ✗
8 ✗
9 ✗
10 ✗
11 ✗
12 ✓
13 ✗
14 ✗
15 ✗

16	✗
17	✗
18	✗
19	✗
20	✗
21	✗
22	✗
23	✓
24	✗
25	✗
26	✗
27	✗
28	✗
29	✓
30	✗
31	✓
32	✗
33	✗
34	✗
35	✗
36	✓
37	✓
38	✗
39	✗
40	✗
41	✓
42	✗
43	✗
44	✗
45	✗
46	✗
47	✗
48	✗
49	✓
50	✗
51	✗

52 ✓
53 ✗
54 ✗
55 ✓
56 ✗
57 ✗
58 ✓
59 ✗
60 ✓
61 ✗
62 ✗
63 ✗
64 ✗
65 ✗
66 ✗
67 ✗
68 ✗
69 ✗
70 ✗
71 ✗
72 ✗
73 ✗
74 ✗
75 ✓
76 ✗
77 ✗
78 ✗
79 ✓
80 ✗
81 ✗
82 ✓
83 ✗
84 ✗
85 ✗
86 ✗
87 ✗

88	✗
89	✗
90	✗
91	✗
92	✗
93	✓
94	✗
95	✓
96	✗
97	✗
98	✗
99	✗
100	✗
101	✗
102	✗
103	✓
104	✗
105	✗
106	✓
107	✗
108	✗
109	✗
110	✗
111	-

All contents of this site are © 2024 Passmedicine Limited

PassMedicine

A 62-year-old gentleman presents to clinic with increasing shortness of breath on exertion. His symptoms have progressed over three months and he has now become concerned as he is struggling to walk through the park without stopping to catch his breath. He has also noticed a new, raised lesion on his chin. He has a few unexplained temperatures within the last week as well and has noticed mild joint pain. He assumed that the latter was arthritis but has not suffered from this before. He has a past medical history of hypertension, glaucoma and has been hospitalised with pneumonia within the last year.

On examination, he has a 1cm wide, raised lesion on his chin which is purple in colour with some telangiectasia. He does not have a fever currently and his observations are all within normal limits. There is no finger clubbing. There is bilateral cervical lymphadenopathy and auscultation demonstrates bibasal fine inspiratory crackles. These do not shift with coughing. A chest X-ray is requested. What is it most likely to show?

- Cavitating lesion
- Pleural effusion
- Bilateral consolidation
- Bilateral hilar lymphadenopathy
- Apical fibrosis

Submit answer

Reference ranges

Score: **16%**

1 ✗
2 ✗

3	✗
4	✗
5	✗
6	✗
7	✗
8	✗
9	✗
10	✗
11	✗
12	✓
13	✗
14	✗
15	✗
16	✗
17	✗
18	✗
19	✗
20	✗
21	✗
22	✗
23	✓
24	✗
25	✗
26	✗
27	✗
28	✗
29	✓
30	✗
31	✓
32	✗
33	✗
34	✗
35	✗
36	✓
37	✓
38	✗

39	✗
40	✗
41	✓
42	✗
43	✗
44	✗
45	✗
46	✗
47	✗
48	✗
49	✓
50	✗
51	-
52	-
53	-
54	-
55	-
56	-
57	-
58	-
59	-
60	-
61	-
62	-
63	-
64	-
65	-
66	-
67	-
68	-
69	-
70	-
71	-
72	-
73	-
74	-
75	-
76	-
77	-

All contents of this site are © 2024 Passmedicine Limited
Back to top

A 62-year-old gentleman presents to clinic with increasing shortness of breath on exertion. His symptoms have progressed over three months and he has now become concerned as he is struggling to walk through the park without stopping to catch his breath. He has also noticed a new, raised lesion on his chin. He has a few unexplained temperatures within the last week as well and has noticed mild joint pain. He assumed that the latter was arthritis but has not suffered from this before. He has a past medical history of hypertension, glaucoma and has been hospitalised with pneumonia within the last year.

On examination, he has a 1cm wide, raised lesion on his chin which is purple in colour with some telangiectasia. He does not have a fever currently and his observations are all within normal limits. There is no finger clubbing. There is bilateral cervical lymphadenopathy and auscultation demonstrates bibasal fine inspiratory crackles. These do not shift with coughing. A chest X-ray is requested. What is it most likely to show?

Cavitating lesion	10%
Pleural effusion	5%
Bilateral consolidation	5%
Bilateral hilar lymphadenopathy	73%
Apical fibrosis	7%

The correct answer is bilateral hilar lymphadenopathy. This is a patient who has presented with typical symptoms and signs of sarcoidosis: progressive exertional dyspnoea, arthralgia, unexplained pyrexia and fine inspiratory crepitations that do not shift on coughing. The absence of a cough, the fact that the crepitations do not shift, and the absence of clubbing all make bronchiectasis a much less likely diagnosis. The skin lesion described is likely to be lupus pernio. The most common X-ray finding in sarcoidosis is bilateral hilar lymphadenopathy, but pleural effusions can also occur. However, pleural effusion is not supported by the examination findings. Again, the fact that the crepitations are basal makes apical fibrosis a less likely finding to see on imaging, and hilar lymphadenopathy is a far more common radiological sign.

Discuss (10) Improve

Sarcoidosis: investigation

There is no one diagnostic test for sarcoidosis and hence diagnosis is still largely clinical. ACE levels have a sensitivity of 60% and specificity of 70% and are therefore not reliable in the diagnosis of sarcoidosis although they may have a role in monitoring disease activity. Routine bloods may show hypercalcaemia (seen in 10% if patients) and a raised ESR

A chest x-ray may show the following changes:
- stage 0 = normal
- stage 1 = bilateral hilar lymphadenopathy (BHL)
- stage 2 = BHL + interstitial infiltrates
- stage 3 = diffuse interstitial infiltrates only
- stage 4 = diffuse fibrosis

Other investigations
- spirometry: may show a restrictive defect
- tissue biopsy: non-caseating granulomas
- gallium-67 scan - not used routinely
- the Kveim test (where part of the spleen from a patient with known sarcoidosis is injected under the skin) is no longer performed due to concerns about cross-infection

AI + Q 123

Textbooks

High-yield textbook

Extended textbook

Media

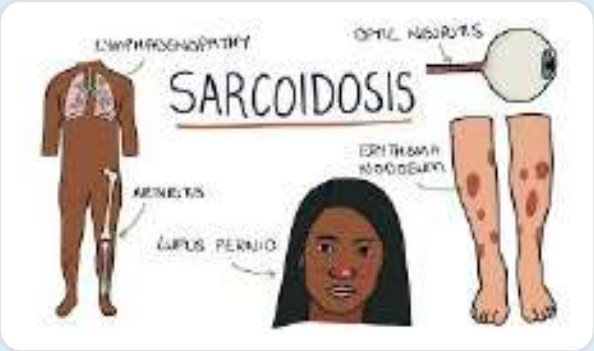

[Sarcoidosis]

Sarcoidosis - YouTube 👍 7 👎 0

[Sarcoidosis]

Osmosis - YouTube 👍 4 👎 0

Report broken media

Score: **17.3%**

1 ✗
2 ✗
3 ✗
4 ✗
5 ✗
6 ✗
7 ✗

8	✗
9	✗
10	✗
11	✗
12	✓
13	✗
14	✗
15	✗
16	✗
17	✗
18	✗
19	✗
20	✗
21	✗
22	✗
23	✓
24	✗
25	✗
26	✗
27	✗
28	✗
29	✓
30	✗
31	✓
32	✗
33	✗
34	✗
35	✗
36	✓
37	✓
38	✗
39	✗
40	✗
41	✓
42	✗
43	✗

44	✗
45	✗
46	✗
47	✗
48	✗
49	✓
50	✗
51	✗
52	✓
53	✗
54	✗
55	✓
56	✗
57	✗
58	✓
59	✗
60	✓
61	✗
62	✗
63	✗
64	✗
65	✗
66	✗
67	✗
68	✗
69	✗
70	✗
71	✗
72	✗
73	✗
74	✗
75	✓
76	✗
77	✗
78	✗
79	✓

80	✗
81	✗
82	✓
83	✗
84	✗
85	✗
86	✗
87	✗
88	✗
89	✗
90	✗
91	✗
92	✗
93	✓
94	✗
95	✓
96	✗
97	✗
98	✗
99	✗
100	✗
101	✗
102	✗
103	✓
104	✗
105	✗
106	✓
107	✗
108	✗
109	✗
110	✗
111	-

All contents of this site are © 2024 Passmedicine Limited

PassMedicine

A 65-year-old woman is admitted to the Emergency Department after collapsing in a department store. A chest x-ray is done shortly after arriving in the department:

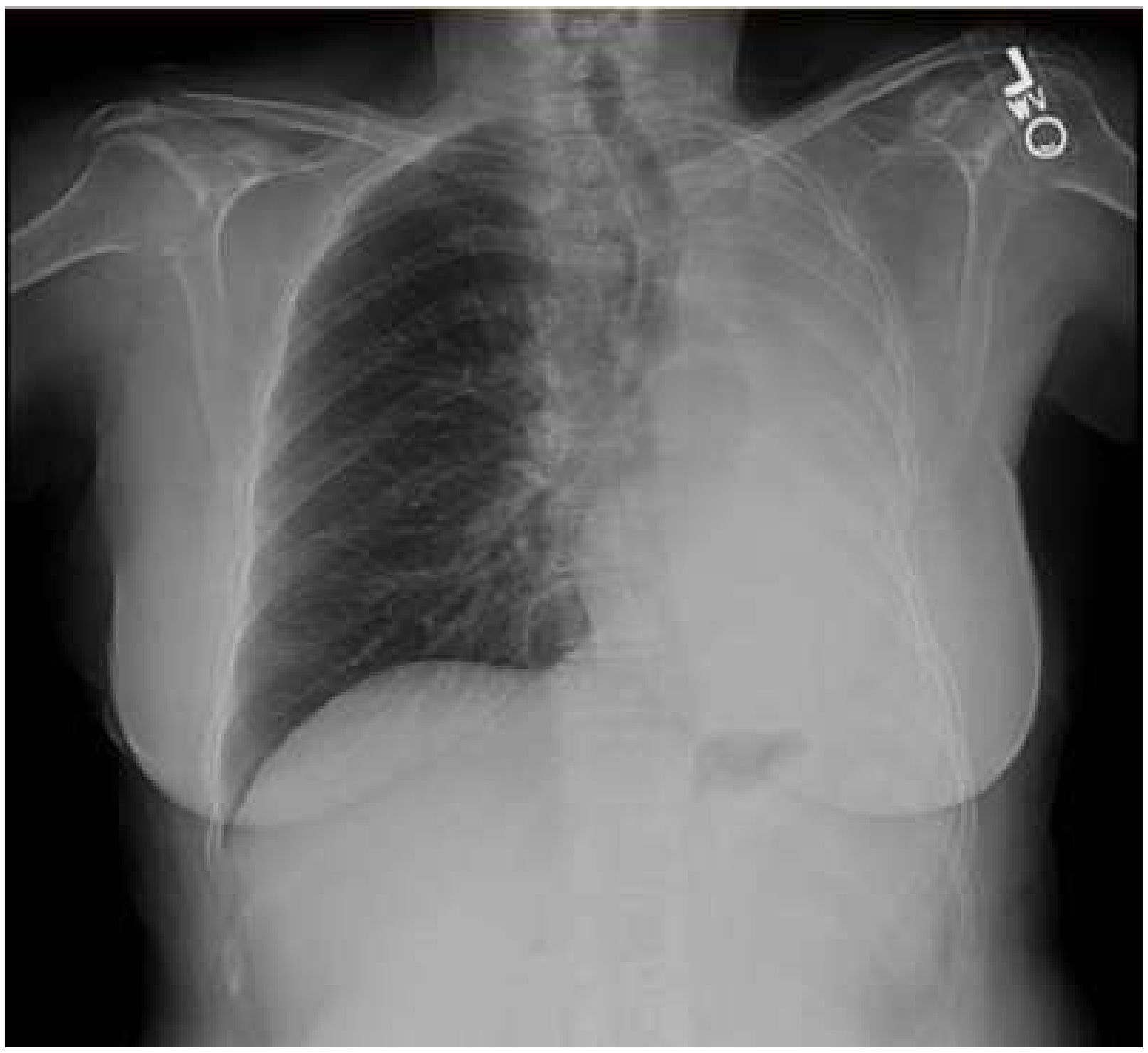

© Image used on license from Radiopaedia

What is the most likely explanation for the abnormality on the left side?

- Rotated film
- Massive pleural effusion
- Pneumonectomy
- Mesothelioma
- Pneumonia

Submit answer

Reference ranges

Score: **16%**

1	✗
2	✗
3	✗
4	✗
5	✗
6	✗
7	✗
8	✗
9	✗
10	✗
11	✗
12	✓
13	✗
14	✗
15	✗
16	✗
17	✗
18	✗
19	✗
20	✗
21	✗
22	✗
23	✓
24	✗
25	✗
26	✗
27	✗
28	✗
29	✓
30	✗

31	✓
32	✗
33	✗
34	✗
35	✗
36	✓
37	✓
38	✗
39	✗
40	✗
41	✓
42	✗
43	✗
44	✗
45	✗
46	✗
47	✗
48	✗
49	✓
50	✗
51	-
52	-
53	-
54	-
55	-
56	-
57	-
58	-
59	-
60	-
61	-
62	-
63	-
64	-
65	-
66	-
67	-
68	-

69 -
70 -
71 -
72 -
73 -
74 -
75 -
76 -
77 -
78 -

All contents of this site are © 2024 Passmedicine Limited Back to top

A 65-year-old woman is admitted to the Emergency Department after collapsing in a department store. A chest x-ray is done shortly after arriving in the department:

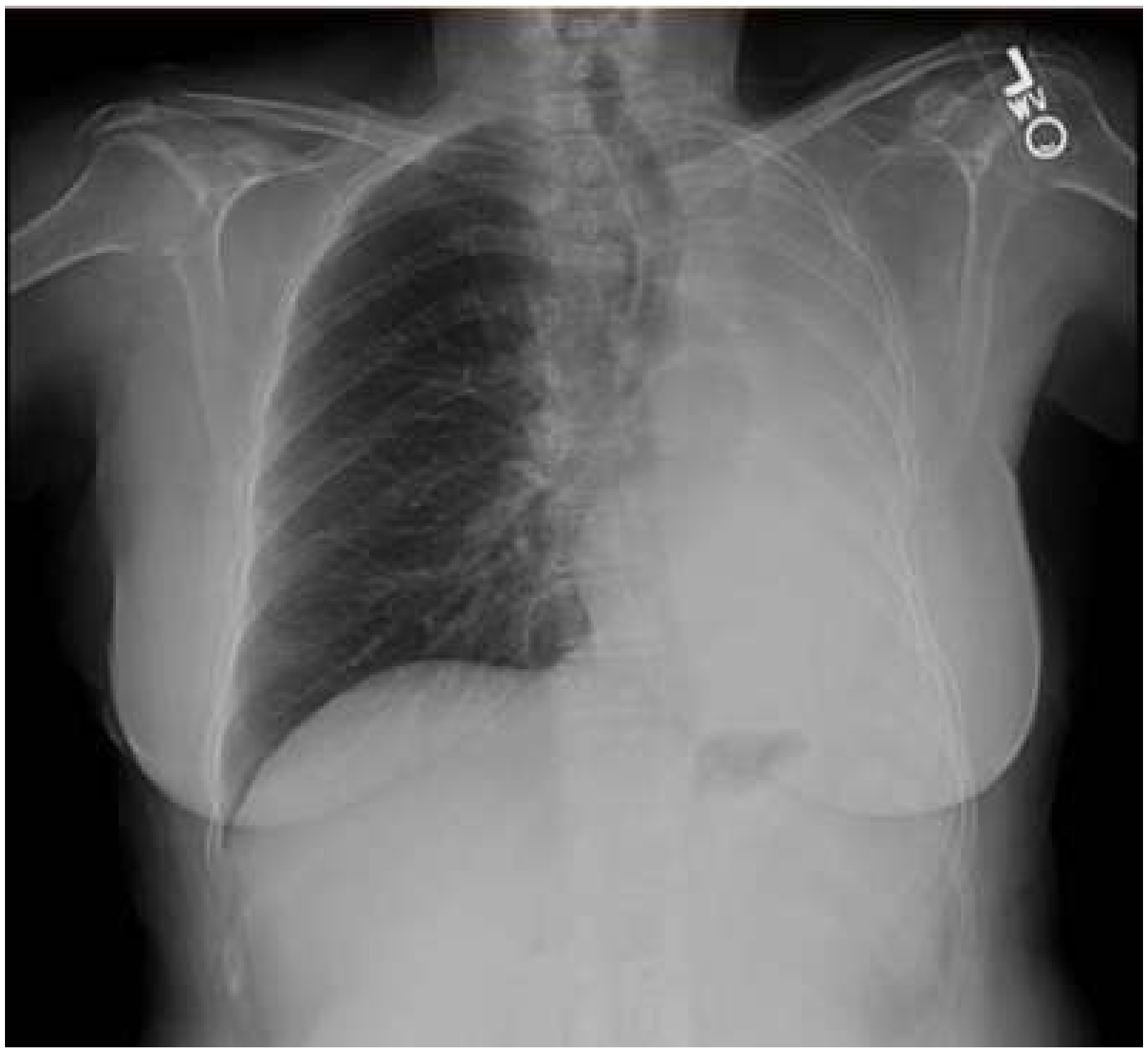

© Image used on license from Radiopaedia

What is the most likely explanation for the abnormality on the left side?

Rotated film	1%
Massive pleural effusion	10%
Pneumonectomy	84%
Mesothelioma	3%
Pneumonia	2%

The key to making the correct diagnosis is to look at the trachea. In the film it is clearly pulled to the left side. This makes a diagnosis of pleural effusion, pneumonia or mesothelioma unlikely. A rotated film would not give such dramatic findings.

Chest x-ray: white lung lesions

There are numerous causes of white shadowing in the lungs including:

- consolidation
- pleural effusion
- collapse
- pneumonectomy
- specific lesions e.g. tumours
- fluid e.g. pulmonary oedema

If there is a 'white-out' of a hemithorax it is useful to assess the position of the trachea - is it central, pulled or pushed from the side of opacification.

Trachea pulled toward the white-out	Trachea central	Trachea pushed away from the white-out
Pneumonectomy Complete lung collapse e.g. endobronchial intubation Pulmonary hypoplasia	Consolidation Pulmonary oedema (usually bilateral) Mesothelioma	Pleural effusion Diaphragmatic hernia Large thoracic mass

© Image used on license from Radiopaedia

Lung collapse - note how the trachea is pulled towards the side of the white-out

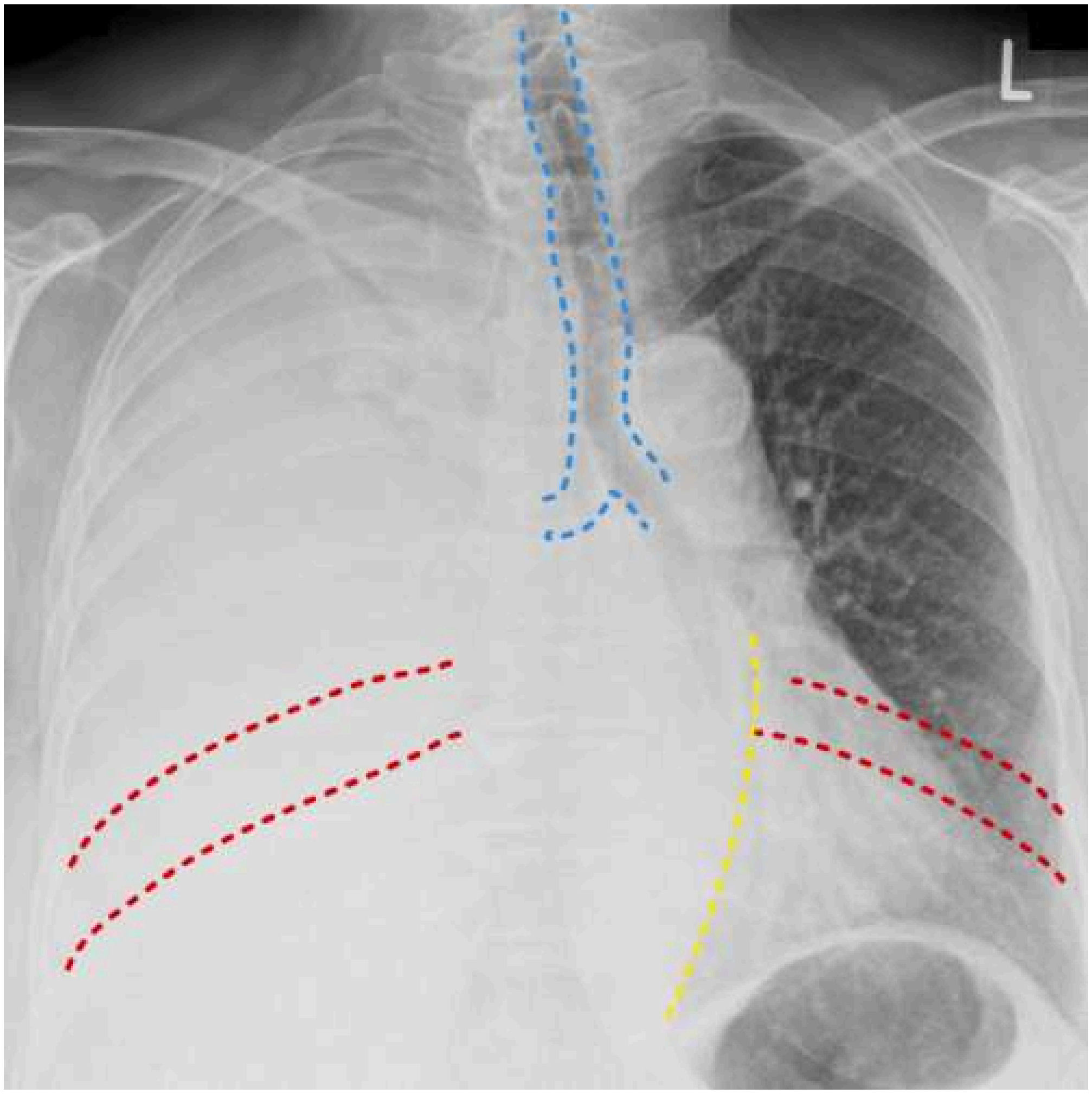

© Image used on license from Radiopaedia

Pleural effusion - note how the trachea (blue) is pushed away the side of the white-out. The other signs of a positive mass effect include leftward bowing of the azygo-oesophageal recess (yellow) and splaying of the ribs on the right (red)

For more information check out the link to the superb Radiology Masterclass website.

+ Q 123

Next question >

B I A T↕

Textbooks

High-yield textbook

Extended textbook

Links

Wiki Radiography 13 4

Example of right upper lobe consolidation

Radiology Masterclass 42 6

Fantastic radiology teaching website

Suggest link Report broken link

Score: **17.3%**

1	✗
2	✗
3	✗
4	✗
5	✗
6	✗
7	✗
8	✗
9	✗
10	✗
11	✗
12	✓
13	✗
14	✗
15	✗
16	✗
17	✗
18	✗
19	✗
20	✗
21	✗
22	✗
23	✓
24	✗
25	✗
26	✗
27	✗
28	✗
29	✓
30	✗
31	✓
32	✗
33	✗
34	✗
35	✗

36	✓
37	✓
38	✗
39	✗
40	✗
41	✓
42	✗
43	✗
44	✗
45	✗
46	✗
47	✗
48	✗
49	✓
50	✗
51	✗
52	✓
53	✗
54	✗
55	✓
56	✗
57	✗
58	✓
59	✗
60	✓
61	✗
62	✗
63	✗
64	✗
65	✗
66	✗
67	✗
68	✗
69	✗
70	✗
71	✗

72	✗
73	✗
74	✗
75	✓
76	✗
77	✗
78	✗
79	✓
80	✗
81	✗
82	✓
83	✗
84	✗
85	✗
86	✗
87	✗
88	✗
89	✗
90	✗
91	✗
92	✗
93	✓
94	✗
95	✓
96	✗
97	✗
98	✗
99	✗
100	✗
101	✗
102	✗
103	✓
104	✗
105	✗
106	✓
107	✗

108	✕
109	✕
110	✕
111	-

All contents of this site are © 2024 Passmedicine Limited

A 56-year-old woman with severe asthma attends with two days of shortness of breath and a tight feeling in her chest. She has a history of multiple exacerbations and was intubated three months ago for a severe exacerbation. She usually takes montelukast, beclometasone and salbutamol.

On arrival, she is cyanosed and saturating at 92% in air. There is accessory muscle use and she is not able to vocalise beyond groans. Her respiratory rate is 22/min and there is quiet wheeze heard bilaterally in the chest. She has failed to respond to nebulisers, steroids and magnesium sulfate. She is planned for intubation and initiation of aminophylline.

Hb	156 g/l	Na^+	145 mmol/l
Platelets	561 * 10^9/l	K^+	3.2 mmol/l
WBC	10.0 * 10^9/l	Urea	4.5 mmol/l
Neuts	7.6 * 10^9/l	Creatinine	65 µmol/l
Lymphs	0.8 * 10^9/l	CRP	32 mg/l
Eosin	1.4 * 10^9/l		
Chest x-ray	hyperexpanded film with no consolidation or pneumothorax		

What recording is essential when administering aminophylline?

- Liver function tests
- Aminophylline levels
- Repeat potassium
- Serial ECGs
- Cardiac monitor

Submit answer

Reference ranges

Score: **16%**

1	✗
2	✗
3	✗
4	✗
5	✗
6	✗
7	✗
8	✗
9	✗
10	✗
11	✗
12	✓
13	✗
14	✗
15	✗
16	✗
17	✗
18	✗
19	✗
20	✗
21	✗
22	✗
23	✓
24	✗
25	✗
26	✗
27	✗
28	✗
29	✓
30	✗
31	✓
32	✗
33	✗
34	✗

35	✗
36	✓
37	✓
38	✗
39	✗
40	✗
41	✓
42	✗
43	✗
44	✗
45	✗
46	✗
47	✗
48	✗
49	✓
50	✗
51	-
52	-
53	-
54	-
55	-
56	-
57	-
58	-
59	-
60	-
61	-
62	-
63	-
64	-
65	-
66	-
67	-
68	-
69	-
70	-
71	-
72	-

73 -
74 -
75 -
76 -
77 -
78 -
79 -

All contents of this site are © 2024 Passmedicine Limited Back to top

A 56-year-old woman with severe asthma attends with two days of shortness of breath and a tight feeling in her chest. She has a history of multiple exacerbations and was intubated three months ago for a severe exacerbation. She usually takes montelukast, beclometasone and salbutamol.

On arrival, she is cyanosed and saturating at 92% in air. There is accessory muscle use and she is not able to vocalise beyond groans. Her respiratory rate is 22/min and there is quiet wheeze heard bilaterally in the chest. She has failed to respond to nebulisers, steroids and magnesium sulfate. She is planned for intubation and initiation of aminophylline.

Hb	156 g/l	Na^+	145 mmol/l
Platelets	561 * 10^9/l	K^+	3.2 mmol/l
WBC	10.0 * 10^9/l	Urea	4.5 mmol/l
Neuts	7.6 * 10^9/l	Creatinine	65 µmol/l
Lymphs	0.8 * 10^9/l	CRP	32 mg/l
Eosin	1.4 * 10^9/l		
Chest x-ray	hyperexpanded film with no consolidation or pneumothorax		

What recording is essential when administering aminophylline?

- Liver function tests 5%
- Aminophylline levels 9%
- Repeat potassium 12%
- Serial ECGs 15%
- Cardiac monitor 58%

Aminophylline loading dose should be done with cardiac monitoring

Important for me Less important

Aminophylline is a methylxanthine and acts as a phosphodiesterase inhibitor and adenosine receptor antagonist. It therefore can act oppositely to adenosine in the heart and induce

tachyarrhythmias. Therefore, for loading of aminophylline, a cardiac monitor needs to be applied. Aminophylline levels would be needed if this patient was already taking theophylline and are used to check maintenance levels. Aminophylline can induce hypokalaemia but this is less important than cardiac monitoring. Aminophylline can induce the liver but monitoring of LFTs is not usually required.

Discuss (2) Improve

Next question

Aminophylline infusions

Aminophylline infusions are used in the management of acute asthma and chronic obstructive pulmonary disease (COPD).

For patients not already treated with xanthines (theophylline or aminophylline) a loading dose is given:

- dose: 5mg/kg
- given by slow intravenous injection over at least 20 minutes

For the maintenance infusion 1g of aminophylline is added to 1 litre of normal saline to give a solution of 1 mg/ml.

- dose: 500-700mcg/kg/hour. If elderly: 300mcg/kg/hour
- plasma theophylline concentrations should be monitored

AI + Q 123

Next question

Textbooks

High-yield textbook

Extended textbook

Score: **17.3%**

1	✗
2	✗
3	✗
4	✗
5	✗
6	✗
7	✗
8	✗
9	✗
10	✗
11	✗
12	✓
13	✗
14	✗
15	✗
16	✗
17	✗
18	✗
19	✗
20	✗
21	✗
22	✗
23	✓
24	✗
25	✗
26	✗
27	✗

28	✗
29	✓
30	✗
31	✓
32	✗
33	✗
34	✗
35	✗
36	✓
37	✓
38	✗
39	✗
40	✗
41	✓
42	✗
43	✗
44	✗
45	✗
46	✗
47	✗
48	✗
49	✓
50	✗
51	✗
52	✓
53	✗
54	✗
55	✓
56	✗
57	✗
58	✓
59	✗
60	✓
61	✗
62	✗
63	✗

64	✗
65	✗
66	✗
67	✗
68	✗
69	✗
70	✗
71	✗
72	✗
73	✗
74	✗
75	✓
76	✗
77	✗
78	✗
79	✓
80	✗
81	✗
82	✓
83	✗
84	✗
85	✗
86	✗
87	✗
88	✗
89	✗
90	✗
91	✗
92	✗
93	✓
94	✗
95	✓
96	✗
97	✗
98	✗
99	✗

100	✗
101	✗
102	✗
103	✓
104	✗
105	✗
106	✓
107	✗
108	✗
109	✗
110	✗
111	-

All contents of this site are © 2024 Passmedicine Limited

Back to top

A 67-year-old retired plumber is seen in the respiratory clinic following an incidental finding of a chest x-ray ordered by his general practitioner. He recently recovered from an infection with *Mycobacterium tuberculosis* 6 weeks ago and reports to have been feeling well since with no complications. The remainder of his past medical history includes mild gastritis and hypertension.

On examination, his observations are recorded as follows:

- Temperature 36.1ºC
- Heart rate 89bpm
- Respiratory rate 22 breaths/min
- Blood pressure 118/65mmHg
- Saturations 99% on room air

On auscultation, chest sounds are clear and heart sounds are normal. Calves are soft and non-tender.

A repeat chest x-ray is ordered (shown below):

© Image used on license from Radiopaedia

What is the single biggest risk factor for this patient's investigation findings?

- *Mycobacterium tuberculosis*
- Asbestos

- ○ Aspergillus ×
- ○ Silica ×
- ○ Tobacco ×

Submit answer

Reference ranges ∨

Score: **16%**

1	✗
2	✗
3	✗
4	✗
5	✗
6	✗
7	✗
8	✗
9	✗
10	✗
11	✗
12	✓
13	✗
14	✗
15	✗
16	✗
17	✗
18	✗
19	✗
20	✗
21	✗

22	✗
23	✓
24	✗
25	✗
26	✗
27	✗
28	✗
29	✓
30	✗
31	✓
32	✗
33	✗
34	✗
35	✗
36	✓
37	✓
38	✗
39	✗
40	✗
41	✓
42	✗
43	✗
44	✗
45	✗
46	✗
47	✗
48	✗
49	✓
50	✗
51	-
52	-
53	-
54	-
55	-
56	-
57	-
58	-

59 -
60 -
61 -
62 -
63 -
64 -
65 -
66 -
67 -
68 -
69 -
70 -
71 -
72 -
73 -
74 -
75 -
76 -
77 -
78 -
79 -
80 -

All contents of this site are © 2024 Passmedicine Limited
Back to top

A 67-year-old retired plumber is seen in the respiratory clinic following an incidental finding of a chest x-ray ordered by his general practitioner. He recently recovered from an infection with *Mycobacterium tuberculosis* 6 weeks ago and reports to have been feeling well since with no complications. The remainder of his past medical history includes mild gastritis and hypertension.

On examination, his observations are recorded as follows:

- Temperature 36.1°C
- Heart rate 89bpm
- Respiratory rate 22 breaths/min
- Blood pressure 118/65mmHg
- Saturations 99% on room air

On auscultation, chest sounds are clear and heart sounds are normal. Calves are soft and non-tender.

A repeat chest x-ray is ordered (shown below):

© Image used on license from Radiopaedia

What is the single biggest risk factor for this patient's investigation findings?

Mycobacterium tuberculosis	3%
Asbestos	77%

Aspergillus	6%
Silica	11%
Tobacco	2%

This chest x-ray demonstrates multiple pleural plaques. They appear as slightly opacified pleural markings of a variety of different shapes with a visible contrast between their outlining border and adjacent normal lung markings. This patient's pleural plaques are most visible in the lateral aspect of the left upper zone and throughout the middle zone of the right lung. Pleural plaques are areas of thickened pleural tissue which arise secondary to asbestos exposure. This patient is a retired plumber and it is likely that his profession was the means of exposure to asbestos. The development of pleural plaques is not immediate and can take up to 20-40 years until visible on imaging. Pleural plaques do not undergo malignant change. Therefore, no follow-up is required for these patients.

Mycobacterium tuberculosis can cause a variety of lung pathology ranging from miliary tuberculosis to parenchymal calcification and necrosis. The infection does not give rise to pleural plaques as demonstrated in this chest x-ray, making it incorrect.

Aspergillus is a fungal infection responsible for a variety of different presentations including invasive aspergillosis and aspergillomas. An aspergilloma is a round mass of the fungus Aspergillus that occupies existing lung cavities such as those from previous *Mycobacterium tuberculosis* infections. It can be detected on a chest x-ray as a spherical or ovoid mass, commonly in the upper zones of the lung.

Silica exposure can lead to silicosis, the progressive inflammation of lung tissue. Stonemasons, mining, pottery and ceramics are the most common routes of silica exposure. Silicosis commonly causes an upper zone pulmonary fibrosis which is not seen here.

Tobacco use is most commonly associated with chronic obstructive pulmonary disease and malignancy (usually squamous cell carcinoma of the lung or small cell carcinoma). Asbestos and tobacco exposure are synergistic with one another the risk of malignancy. However, tobacco use alone is not associated with pleural plaques.

Discuss (2) | Improve

Next question

Asbestos and the lung

Asbestos can cause a variety of lung diseases from benign pleural plaques to mesothelioma.

Pleural plaques

Pleural plaques are benign and do not undergo malignant change. They, therefore don't require any follow-up. They are the most common form of asbestos-related lung disease and generally occur after a latent period of 20-40 years.

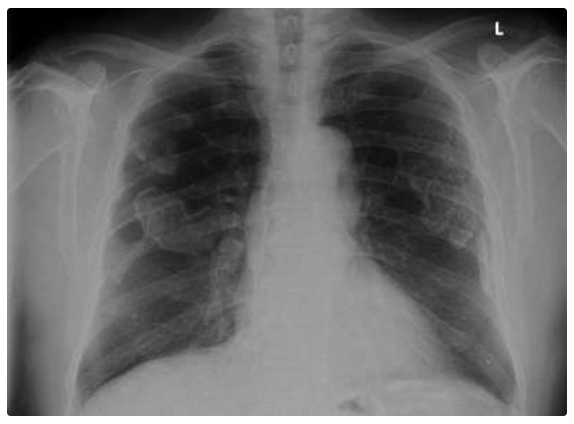

Pleural thickening

Asbestos exposure may cause diffuse pleural thickening in a similar pattern to that seen following an empyema or haemothorax. The underlying pathophysiology is not fully understood.

Asbestosis

The severity of asbestosis is related to the length of exposure. This is in contrast to mesothelioma where even very limited exposure can cause disease. The latent period is typically 15-30 years. Asbestosis typically causes lower lobe fibrosis.

Features

- dyspnoea and reduced exercise tolerance
- clubbing
- bilateral end-inspiratory crackles
- lung function tests show a restrictive pattern with reduced gas transfer

It is treated conservatively - no interventions offer a significant benefit.

Mesothelioma

Mesothelioma is a malignant disease of the pleura. Crocidolite (blue) asbestos is the most dangerous form.

Possible features

- progressive shortness-of-breath

- chest pain
- pleural effusion

Patients are usually offered palliative chemotherapy and there is also a limited role for surgery and radiotherapy. Unfortunately, the prognosis is very poor, with a median survival from diagnosis of 8-14 months.

Lung cancer

Whilst mesothelioma is in some ways synonymous with asbestos, lung cancer is actually the most common form of cancer associated with asbestos exposure. It also has a synergistic effect with cigarette smoke in terms of the increased risk. Therefore, smoking cessation is very important as the risk of lung cancer in smokers who have a history of asbestos exposure is very high.

+ Q 123

Next question

Textbooks

High-yield textbook

Extended textbook

Score: **17.3%**

1	✗
2	✗
3	✗
4	✗
5	✗
6	✗
7	✗
8	✗
9	✗
10	✗
11	✗
12	✓
13	✗
14	✗
15	✗
16	✗
17	✗
18	✗
19	✗
20	✗
21	✗
22	✗
23	✓
24	✗
25	✗
26	✗
27	✗
28	✗
29	✓
30	✗
31	✓
32	✗
33	✗

34	✗
35	✗
36	✓
37	✓
38	✗
39	✗
40	✗
41	✓
42	✗
43	✗
44	✗
45	✗
46	✗
47	✗
48	✗
49	✓
50	✗
51	✗
52	✓
53	✗
54	✗
55	✓
56	✗
57	✗
58	✓
59	✗
60	✓
61	✗
62	✗
63	✗
64	✗
65	✗
66	✗
67	✗
68	✗
69	✗

70	✗
71	✗
72	✗
73	✗
74	✗
75	✓
76	✗
77	✗
78	✗
79	✓
80	✗
81	✗
82	✓
83	✗
84	✗
85	✗
86	✗
87	✗
88	✗
89	✗
90	✗
91	✗
92	✗
93	✓
94	✗
95	✓
96	✗
97	✗
98	✗
99	✗
100	✗
101	✗
102	✗
103	✓
104	✗
105	✗

106	✓
107	✗
108	✗
109	✗
110	✗
111	-

All contents of this site are © 2024 Passmedicine Limited

A 65-year-old man presents to the respiratory clinic with worsening haemoptysis the past 3 months. He is also concerned as he has noticed a loss of 6kg in the past 2 months. He previously completed a course of tuberculosis (TB) treatment 20 years ago, and he is currently a smoker, with a 50 pack year history.

On examination he is cachectic. Temperature is 36.8ºC, heart rate 80 bpm, respiratory rate 18 breaths per minute. There are decreased breath sounds and dullness to percussion over the right upper lobe, and conjunctival pallor. His fingers are clubbed. The rest of his examination is unremarkable.

Investigations:

Na+	131 mmol/l
K+	4.3 mmol/l
Urea	6.1 mmol/l
Creatinine	102 µmol/l
Serum corrected calcium	2.35 mmol/l
Serum bilirubin	21 µmol/l
Serum alkaline phosphatase	85 IU/l
Serum aspartate aminotransferase	16 IU/l
C Reactive protein (CRP)	15 mg/l
Haemoglobin	110 g/l
Mean Corpuscle Volume	77 fL
White cell count	11.2 x 10^9/L
Neutrophils	7.5 x 10^9/L
Eosinophils	1.9 x 10^9/L
Lymphocytes	1.1 x 10^9/L
Basophils	0.0 x 10^9/L
Platelets	490 x 10^9/L
INR	1.0

Chest x-ray: Intracavitary mass in the right upper zone

What is the next most useful diagnostic test?

- Aspergillus precipitins
- Bronchoalveolar lavage
- Sputum cultures
- Bronchoscopy and biopsy
- Skin prick test

Submit answer

Reference ranges

Score: **16%**

1	✗
2	✗
3	✗
4	✗
5	✗
6	✗
7	✗
8	✗
9	✗
10	✗
11	✗
12	✓
13	✗
14	✗
15	✗
16	✗

17	✗
18	✗
19	✗
20	✗
21	✗
22	✗
23	✓
24	✗
25	✗
26	✗
27	✗
28	✗
29	✓
30	✗
31	✓
32	✗
33	✗
34	✗
35	✗
36	✓
37	✓
38	✗
39	✗
40	✗
41	✓
42	✗
43	✗
44	✗
45	✗
46	✗
47	✗
48	✗
49	✓
50	✗
51	-
52	-

53	-
54	-
55	-
56	-
57	-
58	-
59	-
60	-
61	-
62	-
63	-
64	-
65	-
66	-
67	-
68	-
69	-
70	-
71	-
72	-
73	-
74	-
75	-
76	-
77	-
78	-
79	-
80	-
81	-

All contents of this site are © 2024 Passmedicine Limited

A 65-year-old man presents to the respiratory clinic with worsening haemoptysis the past 3 months. He is also concerned as he has noticed a loss of 6kg in the past 2 months. He previously completed a course of tuberculosis (TB) treatment 20 years ago, and he is currently a smoker, with a 50 pack year history.

On examination he is cachectic. Temperature is 36.8ºC, heart rate 80 bpm, respiratory rate 18 breaths per minute. There are decreased breath sounds and dullness to percussion over the right upper lobe, and conjunctival pallor. His fingers are clubbed. The rest of his examination is unremarkable.

Investigations:

Na+	131 mmol/l
K+	4.3 mmol/l
Urea	6.1 mmol/l
Creatinine	102 µmol/l
Serum corrected calcium	2.35 mmol/l
Serum bilirubin	21 µmol/l
Serum alkaline phosphatase	85 IU/l
Serum aspartate aminotransferase	16 IU/l
C Reactive protein (CRP)	15 mg/l
Haemoglobin	110 g/l
Mean Corpuscle Volume	77 fL
White cell count	11.2 x 10^9/L
Neutrophils	7.5 x 10^9/L
Eosinophils	1.9 x 10^9/L
Lymphocytes	1.1 x 10^9/L
Basophils	0.0 x 10^9/L
Platelets	490 x 10^9/L
INR	1.0

Chest x-ray: Intracavitary mass in the right upper zone

What is the next most useful diagnostic test?

- Aspergillus precipitins 59%
- Bronchoalveolar lavage 12%
- Sputum cultures 5%
- Bronchoscopy and biopsy 23%
- Skin prick test 2%

This gentleman has haemoptysis, weight loss, previous TB and a mass in the right upper zone. The differentials would include recurrent TB, malignancy or an aspergilloma. In view of his eosinophilia in the differentials, the most likely diagnosis would be an aspergilloma, where a fungal ball of aspergilli grows in a pre-existing pulmonary cavity unchecked, as the immune system is unable to penetrate the cavity.

The diagnosis of aspergillosis includes the finding of eosinophilia on the full blood count, as well as raised IgE. Skin prick tests for aspergillus spp. may not be positive in patients with an aspergilloma. Serological tests for aspergillus precipitins are more sensitive than sputum cultures for diagnosing aspergillomas. Bronchoalveolar lavage and bronchoscopy are less effective in diagnosing aspergillomas. Another useful test is a CT scan of the chest, which can also reveal malignancy if suspected.

Discuss (13) Improve

Next question

Allergic bronchopulmonary aspergillosis

Allergic bronchopulmonary aspergillosis results from an allergy to *Aspergillus spores*. In the exam questions often give a history of bronchiectasis and eosinophilia.

Features

- bronchoconstriction: wheeze, cough, dyspnoea. Patients may have a previous label of asthma
- bronchiectasis (proximal)

Investigations

- eosinophilia
- flitting CXR changes
- positive radioallergosorbent (RAST) test to Aspergillus
- positive IgG precipitins (not as positive as in aspergilloma)
- raised IgE

Management

- oral glucocorticoids
- itraconazole is sometimes introduced as a second-line agent

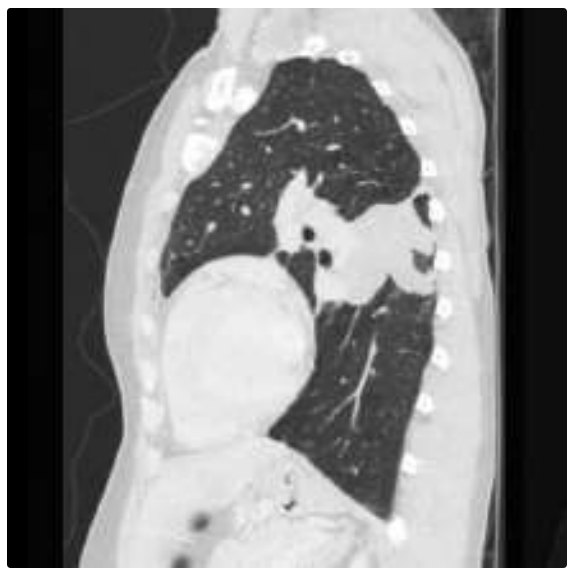

123

Next question

Textbooks

High-yield textbook

Extended textbook

Score: **17.3%**

1	✗
2	✗
3	✗
4	✗
5	✗
6	✗
7	✗
8	✗
9	✗
10	✗
11	✗
12	✓
13	✗
14	✗
15	✗
16	✗
17	✗
18	✗
19	✗
20	✗
21	✗
22	✗
23	✓
24	✗
25	✗
26	✗
27	✗
28	✗
29	✓
30	✗
31	✓
32	✗
33	✗
34	✗

35	✗
36	✓
37	✓
38	✗
39	✗
40	✗
41	✓
42	✗
43	✗
44	✗
45	✗
46	✗
47	✗
48	✗
49	✓
50	✗
51	✗
52	✓
53	✗
54	✗
55	✓
56	✗
57	✗
58	✓
59	✗
60	✓
61	✗
62	✗
63	✗
64	✗
65	✗
66	✗
67	✗
68	✗
69	✗
70	✗

71	✗
72	✗
73	✗
74	✗
75	✓
76	✗
77	✗
78	✗
79	✓
80	✗
81	✗
82	✓
83	✗
84	✗
85	✗
86	✗
87	✗
88	✗
89	✗
90	✗
91	✗
92	✗
93	✓
94	✗
95	✓
96	✗
97	✗
98	✗
99	✗
100	✗
101	✗
102	✗
103	✓
104	✗
105	✗
106	✓

107	✕
108	✕
109	✕
110	✕
111	-

All contents of this site are © 2024 Passmedicine Limited

A 71-year-old woman is admitted with shortness-of-breath to the acute medical unit. Her carers report that she has been feverish and confused for the past two days:

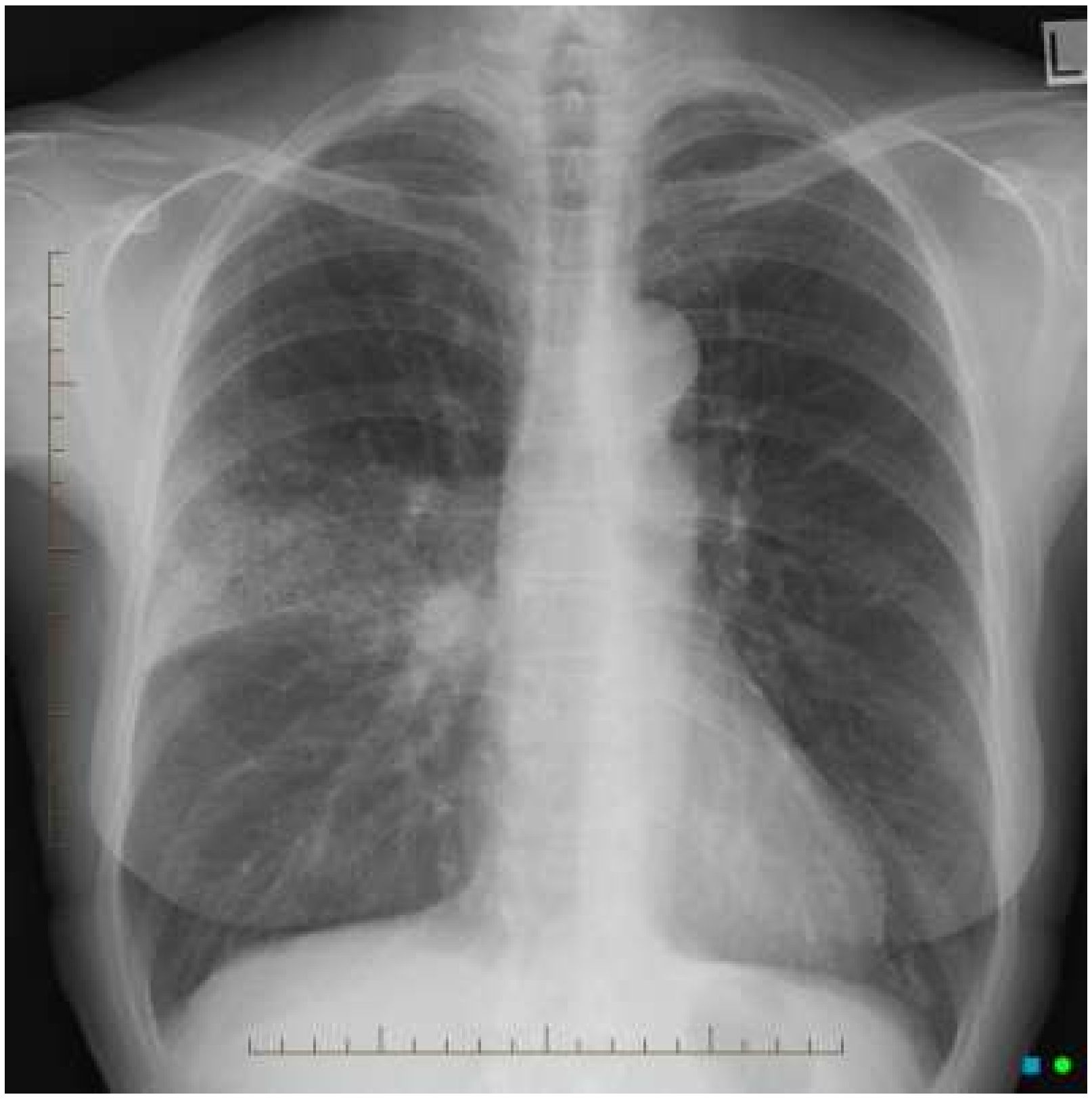

© Image used on license from Radiopaedia

What is the main finding on the film?

- Bronchiectasis
- Right middle lobe consolidation
- Tuberculosis
- Pulmonary abscess
- Right upper lobe consolidation

Submit answer

Reference ranges

Score: **16%**

1	✗
2	✗
3	✗
4	✗
5	✗
6	✗
7	✗
8	✗
9	✗
10	✗
11	✗
12	✓
13	✗
14	✗
15	✗
16	✗
17	✗
18	✗
19	✗
20	✗
21	✗
22	✗
23	✓
24	✗
25	✗
26	✗
27	✗
28	✗
29	✓
30	✗

31	✓
32	✗
33	✗
34	✗
35	✗
36	✓
37	✓
38	✗
39	✗
40	✗
41	✓
42	✗
43	✗
44	✗
45	✗
46	✗
47	✗
48	✗
49	✓
50	✗
51	-
52	-
53	-
54	-
55	-
56	-
57	-
58	-
59	-
60	-
61	-
62	-
63	-
64	-
65	-
66	-
67	-
68	-

69 -
70 -
71 -
72 -
73 -
74 -
75 -
76 -
77 -
78 -
79 -
80 -
81 -
82 -

All contents of this site are © 2024 Passmedicine Limited

Back to top

A 71-year-old woman is admitted with shortness-of-breath to the acute medical unit. Her carers report that she has been feverish and confused for the past two days:

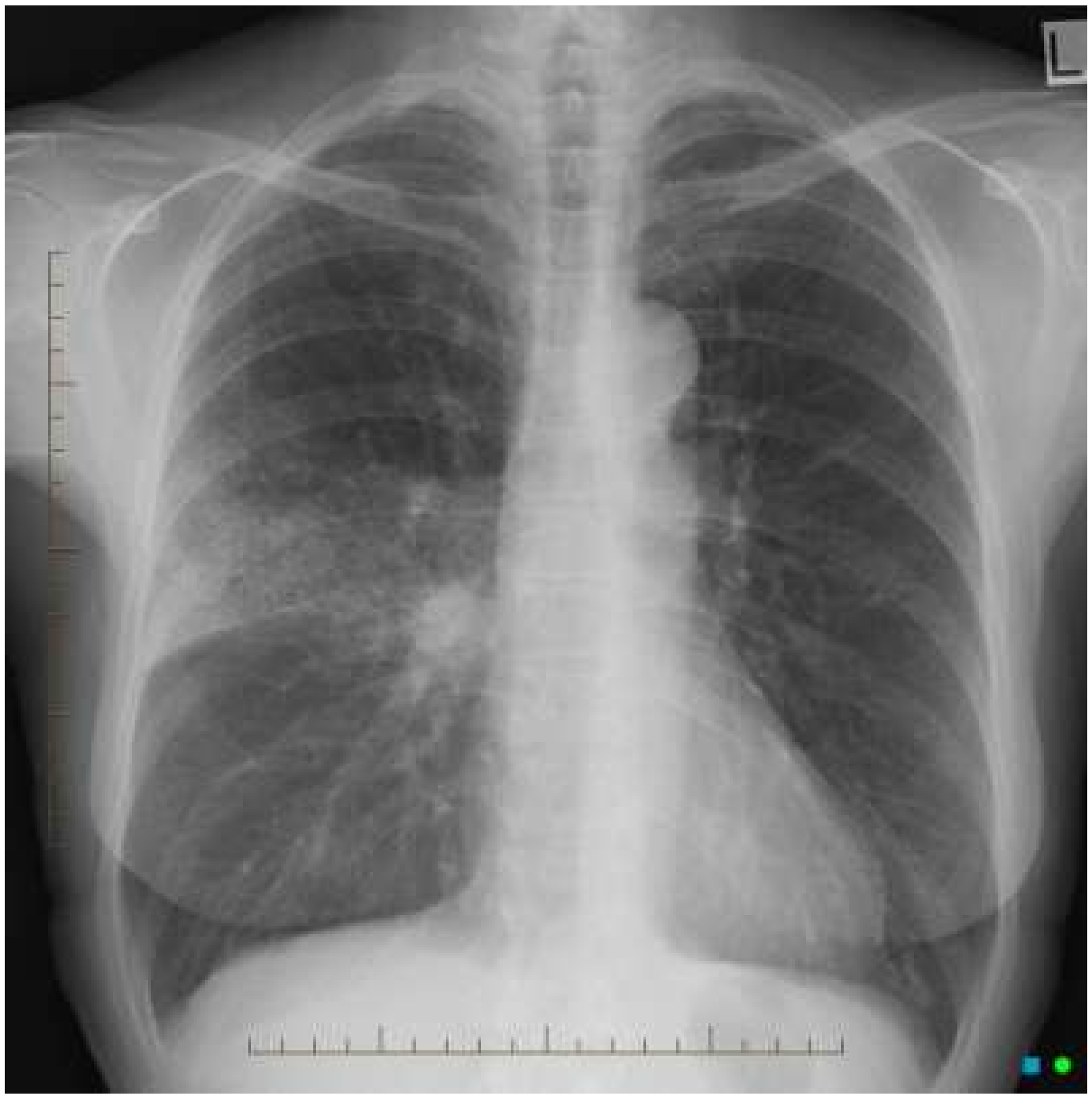

© Image used on license from Radiopaedia

What is the main finding on the film?

Bronchiectasis	1%
Right middle lobe consolidation	67%
Tuberculosis	1%
Pulmonary abscess	2%
Right upper lobe consolidation	29%

This film demonstrates classical signs of right upper lobe consolidation - abnormal opacity within the right upper lobe abutting the horizontal fissure.

Please see the Wiki Radiography link for further examples of right upper lobe consolidation.

Discuss (8) | Improve

Next question

Chest x-ray: white lung lesions

There are numerous causes of white shadowing in the lungs including:

- consolidation
- pleural effusion
- collapse
- pneumonectomy
- specific lesions e.g. tumours
- fluid e.g. pulmonary oedema

If there is a 'white-out' of a hemithorax it is useful to assess the position of the trachea - is it central, pulled or pushed from the side of opacification.

Trachea pulled toward the white-out	Trachea central	Trachea pushed away from the white-out
Pneumonectomy Complete lung collapse e.g. endobronchial intubation Pulmonary hypoplasia	Consolidation Pulmonary oedema (usually bilateral) Mesothelioma	Pleural effusion Diaphragmatic hernia Large thoracic mass

© Image used on license from Radiopaedia

Lung collapse - note how the trachea is pulled towards the side of the white-out

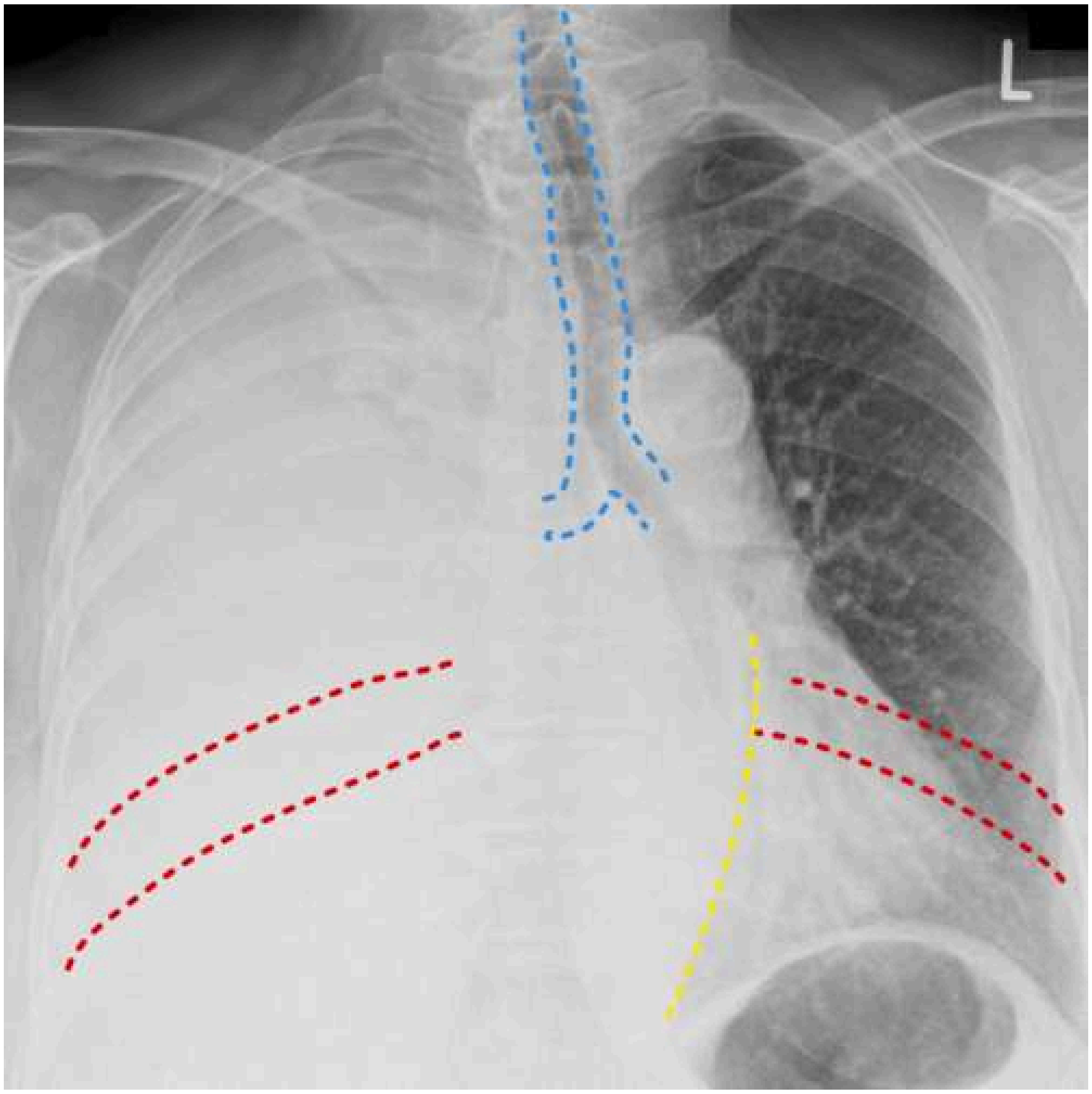

© Image used on license from Radiopaedia

Pleural effusion - note how the trachea (blue) is pushed away the side of the white-out. The other signs of a positive mass effect include leftward bowing of the azygo-oesophageal recess (yellow) and splaying of the ribs on the right (red)

For more information check out the link to the superb Radiology Masterclass website.

123

Next question

Textbooks

High-yield textbook

Extended textbook

Links

Wiki Radiography 13 4

Example of right upper lobe consolidation

Radiology Masterclass 42 6

Fantastic radiology teaching website

Suggest link Report broken link

Score: **17.3%**

1	✗
2	✗
3	✗
4	✗
5	✗
6	✗
7	✗
8	✗
9	✗
10	✗
11	✗
12	✓
13	✗
14	✗
15	✗
16	✗
17	✗
18	✗
19	✗
20	✗
21	✗
22	✗
23	✓
24	✗
25	✗
26	✗
27	✗
28	✗
29	✓
30	✗
31	✓
32	✗
33	✗
34	✗
35	✗

36	✓
37	✓
38	✗
39	✗
40	✗
41	✓
42	✗
43	✗
44	✗
45	✗
46	✗
47	✗
48	✗
49	✓
50	✗
51	✗
52	✓
53	✗
54	✗
55	✓
56	✗
57	✗
58	✓
59	✗
60	✓
61	✗
62	✗
63	✗
64	✗
65	✗
66	✗
67	✗
68	✗
69	✗
70	✗
71	✗

72	✗
73	✗
74	✗
75	✓
76	✗
77	✗
78	✗
79	✓
80	✗
81	✗
82	✓
83	✗
84	✗
85	✗
86	✗
87	✗
88	✗
89	✗
90	✗
91	✗
92	✗
93	✓
94	✗
95	✓
96	✗
97	✗
98	✗
99	✗
100	✗
101	✗
102	✗
103	✓
104	✗
105	✗
106	✓
107	✗

108	✕
109	✕
110	✕
111	-

All contents of this site are © 2024 Passmedicine Limited

A 70-year-old homeless woman is admitted to the Emergency Department after being found unconscious by staff at a local homeless shelter. She has a history of alcohol excess according to staff. On arrival in the department she appears to be intoxicated and confused. On examination you noticed heavy tar staining of the fingers and a pulse of 110/min which is irregularly irregular. Her respiratory rate is 16/min with oxygen saturations of 92% on room air. Breath sounds are reduced on the left side of the chest. A chest x-ray shows the following:

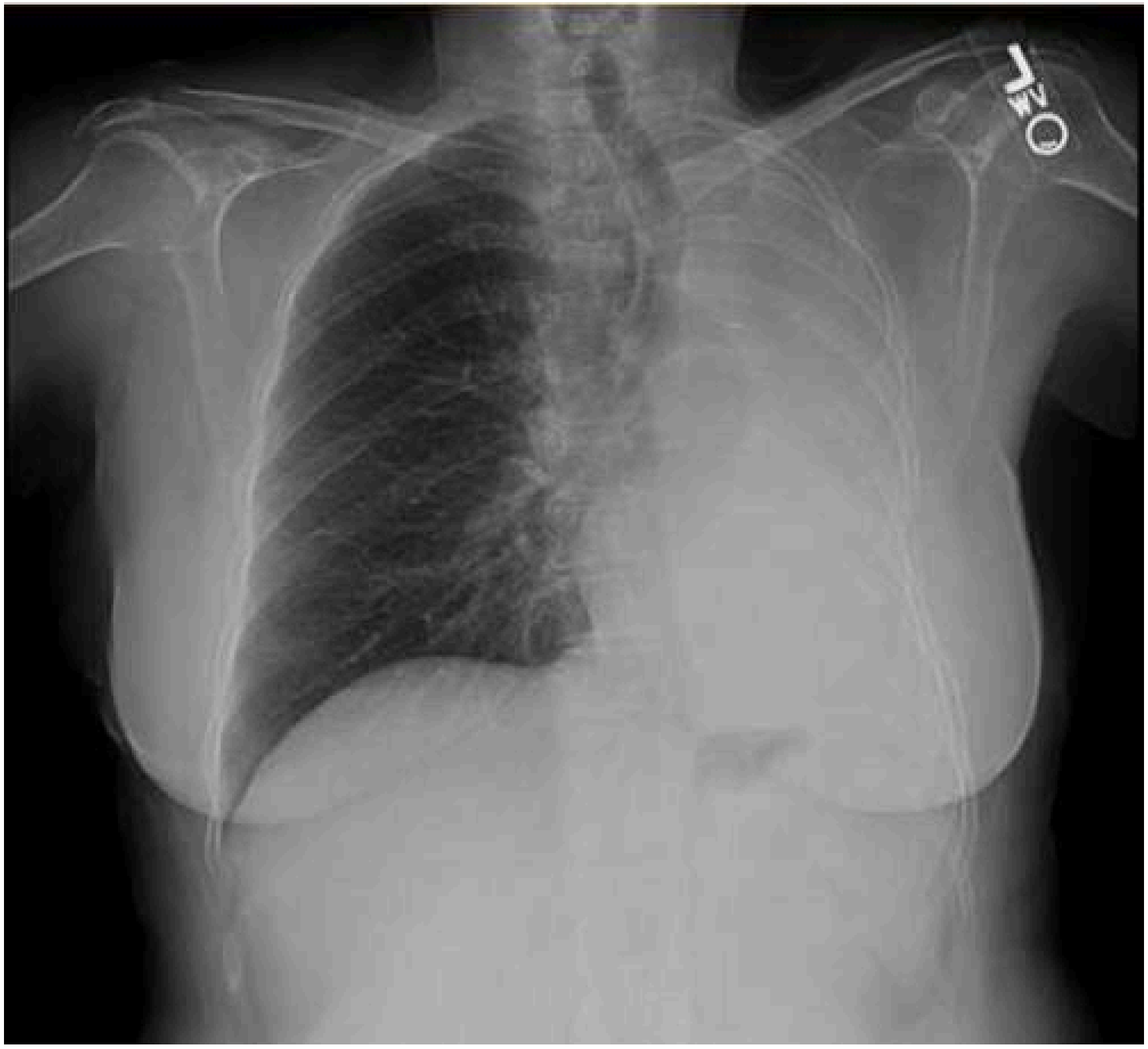

© Image used on license from Radiopaedia

What is the most likely diagnosis?

- Pleural effusion
- Pneumonia
- Pneumonectomy
- Diaphragmatic hernia

Mesothelioma

Submit answer

Reference ranges

Score: **16%**

1	✗
2	✗
3	✗
4	✗
5	✗
6	✗
7	✗
8	✗
9	✗
10	✗
11	✗
12	✓
13	✗
14	✗
15	✗
16	✗
17	✗
18	✗
19	✗
20	✗
21	✗
22	✗
23	✓
24	✗
25	✗

26	✗
27	✗
28	✗
29	✓
30	✗
31	✓
32	✗
33	✗
34	✗
35	✗
36	✓
37	✓
38	✗
39	✗
40	✗
41	✓
42	✗
43	✗
44	✗
45	✗
46	✗
47	✗
48	✗
49	✓
50	✗
51	-
52	-
53	-
54	-
55	-
56	-
57	-
58	-
59	-
60	-
61	-
62	-

63 -
64 -
65 -
66 -
67 -
68 -
69 -
70 -
71 -
72 -
73 -
74 -
75 -
76 -
77 -
78 -
79 -
80 -
81 -
82 -
83 -

All contents of this site are © 2024 Passmedicine Limited
Back to top

PassMedicine

A 70-year-old homeless woman is admitted to the Emergency Department after being found unconscious by staff at a local homeless shelter. She has a history of alcohol excess according to staff. On arrival in the department she appears to be intoxicated and confused. On examination you noticed heavy tar staining of the fingers and a pulse of 110/min which is irregularly irregular. Her respiratory rate is 16/min with oxygen saturations of 92% on room air. Breath sounds are reduced on the left side of the chest. A chest x-ray shows the following:

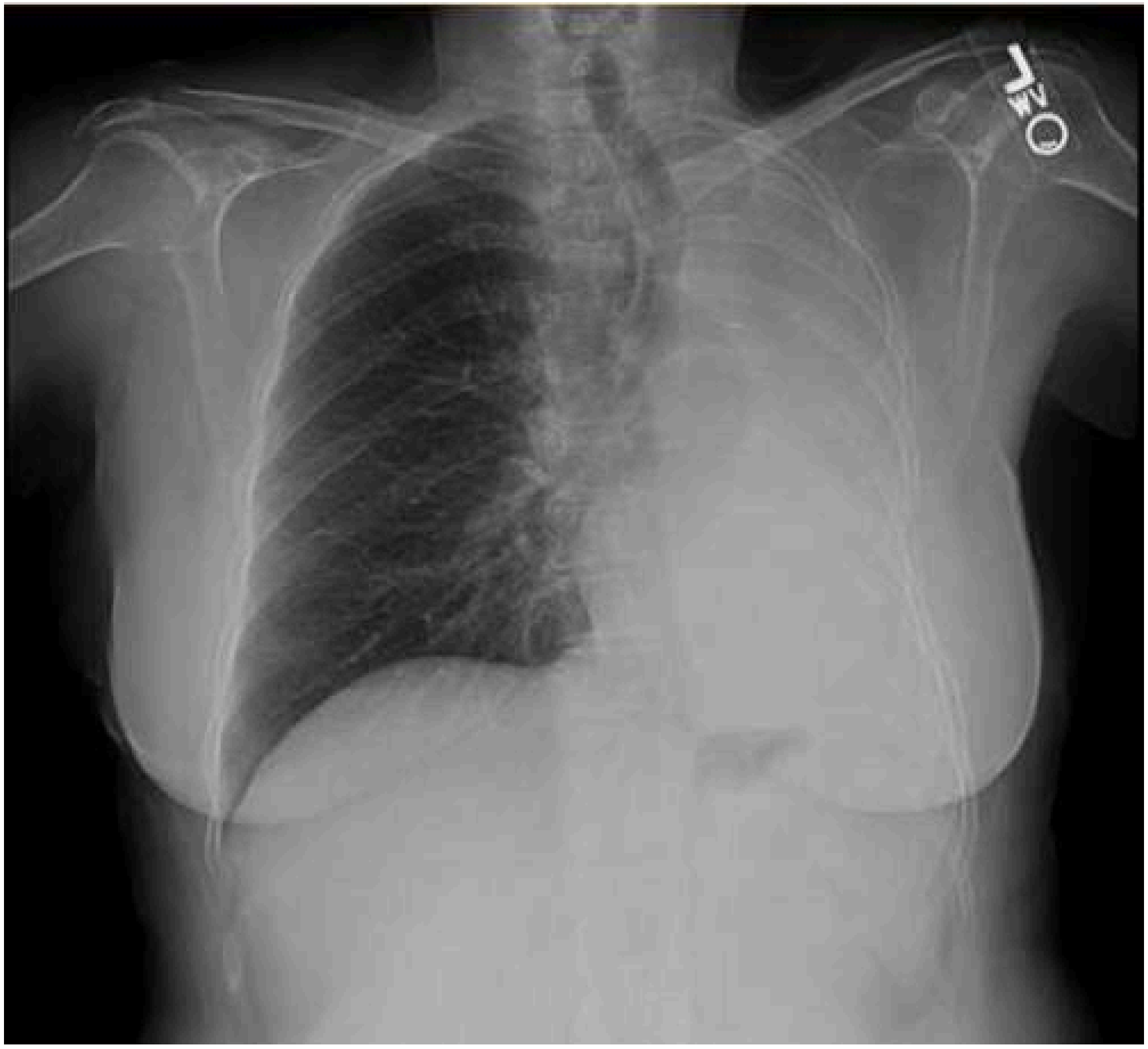

© Image used on license from Radiopaedia

What is the most likely diagnosis?

Pleural effusion	10%
Pneumonia	5%
Pneumonectomy	78%
Diaphragmatic hernia	2%

Mesothelioma 5%

The x-ray shows an opacified left hemithorax with mediastinal and tracheal shift towards the affected side. Crowding of the ribs over the affected side with compensatory overinflation of normal lung is also seen.

Discuss (4) Improve

Next question

Chest x-ray: white lung lesions

There are numerous causes of white shadowing in the lungs including:

- consolidation
- pleural effusion
- collapse
- pneumonectomy
- specific lesions e.g. tumours
- fluid e.g. pulmonary oedema

If there is a 'white-out' of a hemithorax it is useful to assess the position of the trachea - is it central, pulled or pushed from the side of opacification.

Trachea pulled toward the white-out	Trachea central	Trachea pushed away from the white-out
Pneumonectomy Complete lung collapse e.g. endobronchial intubation Pulmonary hypoplasia	Consolidation Pulmonary oedema (usually bilateral) Mesothelioma	Pleural effusion Diaphragmatic hernia Large thoracic mass

© Image used on license from Radiopaedia

Lung collapse - note how the trachea is pulled towards the side of the white-out

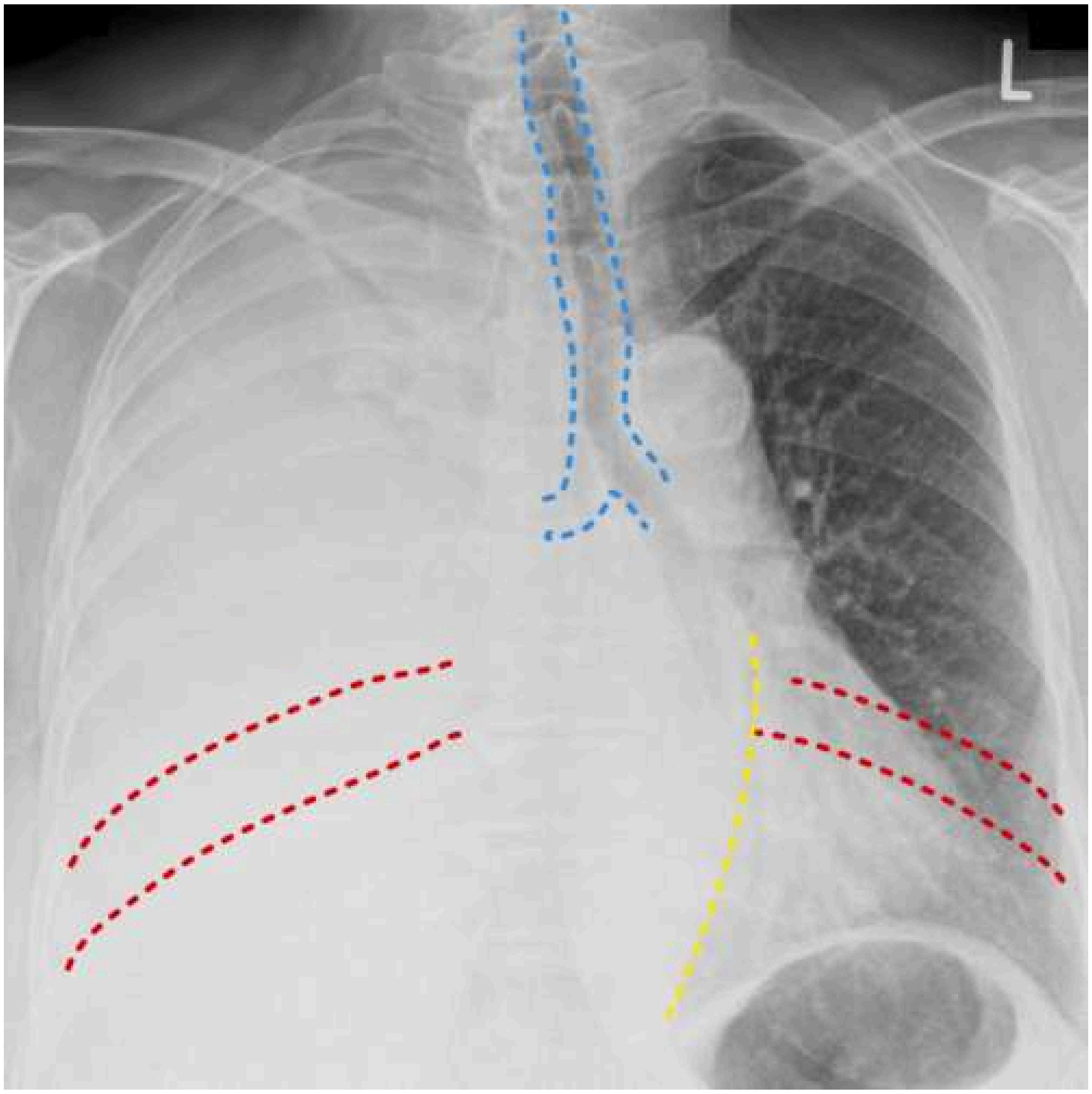

© Image used on license from Radiopaedia

Pleural effusion - note how the trachea (blue) is pushed away the side of the white-out. The other signs of a positive mass effect include leftward bowing of the azygo-oesophageal recess (yellow) and splaying of the ribs on the right (red)

For more information check out the link to the superb Radiology Masterclass website.

+ Q 123

Next question >

B I A

Textbooks

High-yield textbook

Extended textbook

Links

Wiki Radiography 13 4

Example of right upper lobe consolidation

Radiology Masterclass 42 6

Fantastic radiology teaching website

Suggest link Report broken link

Score: **17.3%**

1	✗
2	✗
3	✗
4	✗
5	✗
6	✗
7	✗
8	✗
9	✗
10	✗
11	✗
12	✓
13	✗
14	✗
15	✗
16	✗
17	✗
18	✗
19	✗
20	✗
21	✗
22	✗
23	✓
24	✗
25	✗
26	✗
27	✗
28	✗
29	✓
30	✗
31	✓
32	✗
33	✗
34	✗
35	✗

36	✓
37	✓
38	✗
39	✗
40	✗
41	✓
42	✗
43	✗
44	✗
45	✗
46	✗
47	✗
48	✗
49	✓
50	✗
51	✗
52	✓
53	✗
54	✗
55	✓
56	✗
57	✗
58	✓
59	✗
60	✓
61	✗
62	✗
63	✗
64	✗
65	✗
66	✗
67	✗
68	✗
69	✗
70	✗
71	✗

72	✗
73	✗
74	✗
75	✓
76	✗
77	✗
78	✗
79	✓
80	✗
81	✗
82	✓
83	✗
84	✗
85	✗
86	✗
87	✗
88	✗
89	✗
90	✗
91	✗
92	✗
93	✓
94	✗
95	✓
96	✗
97	✗
98	✗
99	✗
100	✗
101	✗
102	✗
103	✓
104	✗
105	✗
106	✓
107	✗

108 ✕

109 ✕

110 ✕

111 -

All contents of this site are © 2024 Passmedicine Limited

A 75-year-old man is admitted to the Emergency Department with dyspnoea. A chest x-ray is performed upon arrival:

© Image used on license from Radiopaedia

What is the main finding on the film?

- Bronchiectasis
- Right sided pleural effusion
- Right upper lobe consolidation
- Pulmonary oedema
- Right middle lobe collapse

Submit answer

Reference ranges

Score: **16%**

1	✗
2	✗
3	✗
4	✗
5	✗
6	✗
7	✗
8	✗
9	✗
10	✗
11	✗
12	✓
13	✗
14	✗
15	✗
16	✗
17	✗
18	✗
19	✗
20	✗
21	✗
22	✗
23	✓
24	✗
25	✗
26	✗
27	✗
28	✗
29	✓
30	✗
31	✓
32	✗
33	✗
34	✗

35	✗
36	✓
37	✓
38	✗
39	✗
40	✗
41	✓
42	✗
43	✗
44	✗
45	✗
46	✗
47	✗
48	✗
49	✓
50	✗
51	-
52	-
53	-
54	-
55	-
56	-
57	-
58	-
59	-
60	-
61	-
62	-
63	-
64	-
65	-
66	-
67	-
68	-
69	-
70	-
71	-
72	-

73	-
74	-
75	-
76	-
77	-
78	-
79	-
80	-
81	-
82	-
83	-
84	-

All contents of this site are © 2024 Passmedicine Limited
Back to top

A 75-year-old man is admitted to the Emergency Department with dyspnoea. A chest x-ray is performed upon arrival:

© Image used on license from Radiopaedia

What is the main finding on the film?

Bronchiectasis	1%
Right sided pleural effusion	1%
Right upper lobe consolidation	61%
Pulmonary oedema	2%
Right middle lobe collapse	36%

This film demonstrates classical signs of right upper lobe consolidation - abnormal opacity within the right upper lobe abutting the horizontal fissure.

Discuss (6) | Improve

Next question >

Chest x-ray: white lung lesions

There are numerous causes of white shadowing in the lungs including:

- consolidation
- pleural effusion
- collapse
- pneumonectomy
- specific lesions e.g. tumours
- fluid e.g. pulmonary oedema

If there is a 'white-out' of a hemithorax it is useful to assess the position of the trachea - is it central, pulled or pushed from the side of opacification.

Trachea pulled toward the white-out	**Trachea central**	**Trachea pushed away from the white-out**
Pneumonectomy Complete lung collapse e.g. endobronchial intubation Pulmonary hypoplasia	Consolidation Pulmonary oedema (usually bilateral) Mesothelioma	Pleural effusion Diaphragmatic hernia Large thoracic mass

© Image used on license from Radiopaedia

Lung collapse - note how the trachea is pulled towards the side of the white-out

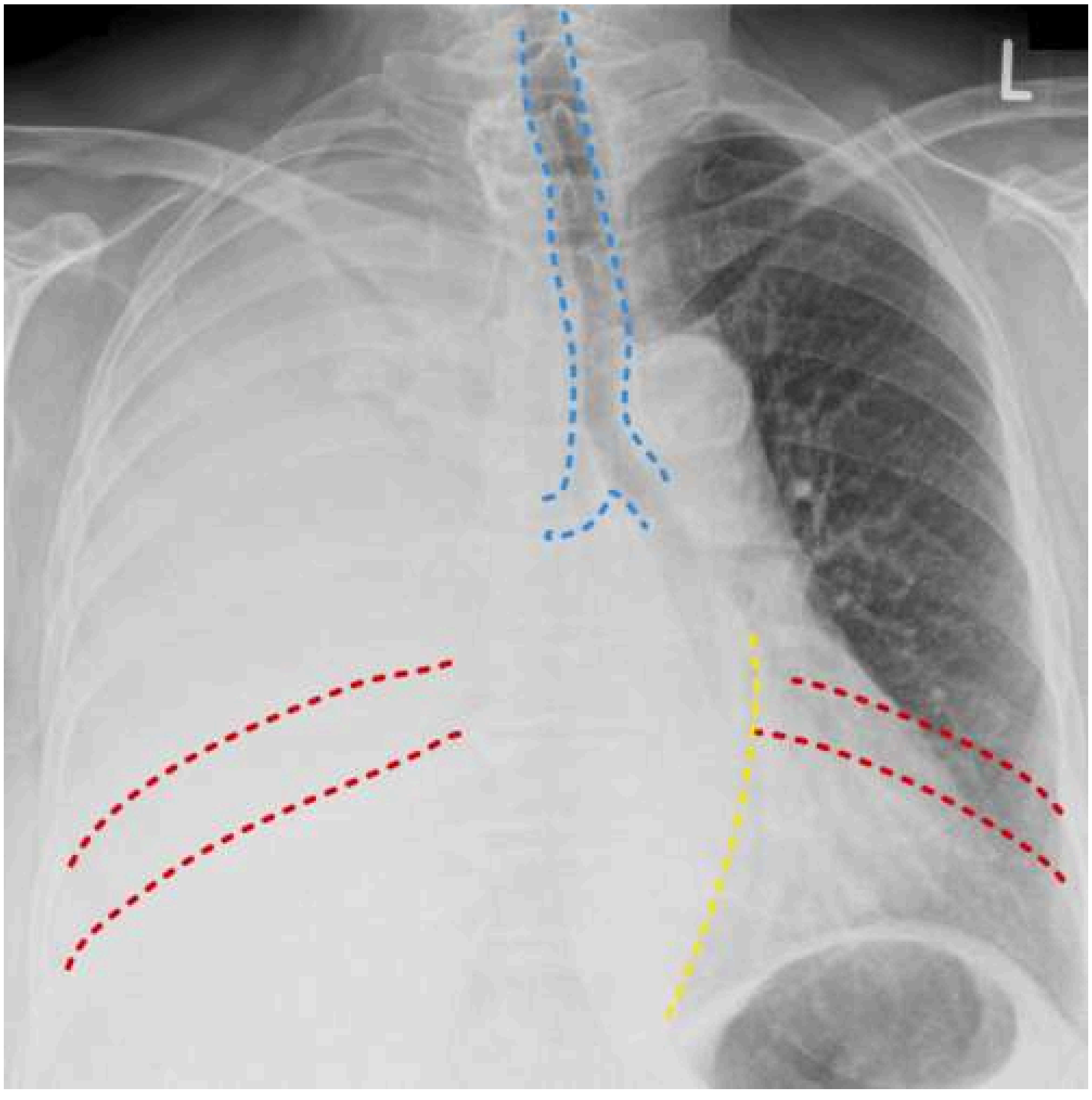

© Image used on license from Radiopaedia

Pleural effusion - note how the trachea (blue) is pushed away the side of the white-out. The other signs of a positive mass effect include leftward bowing of the azygo-oesophageal recess (yellow) and splaying of the ribs on the right (red)

For more information check out the link to the superb Radiology Masterclass website.

123

Next question

Textbooks

High-yield textbook

Extended textbook

Links

Wiki Radiography 13 4

Example of right upper lobe consolidation

Radiology Masterclass 42 6

Fantastic radiology teaching website

Suggest link Report broken link

Score: **17.3%**

1	✗
2	✗
3	✗
4	✗
5	✗
6	✗
7	✗
8	✗
9	✗
10	✗
11	✗
12	✓
13	✗
14	✗
15	✗
16	✗
17	✗
18	✗
19	✗
20	✗
21	✗
22	✗
23	✓
24	✗
25	✗
26	✗
27	✗
28	✗
29	✓
30	✗
31	✓
32	✗
33	✗
34	✗
35	✗

36 ✓
37 ✓
38 ✗
39 ✗
40 ✗
41 ✓
42 ✗
43 ✗
44 ✗
45 ✗
46 ✗
47 ✗
48 ✗
49 ✓
50 ✗
51 ✗
52 ✓
53 ✗
54 ✗
55 ✓
56 ✗
57 ✗
58 ✓
59 ✗
60 ✓
61 ✗
62 ✗
63 ✗
64 ✗
65 ✗
66 ✗
67 ✗
68 ✗
69 ✗
70 ✗
71 ✗

72	✗
73	✗
74	✗
75	✓
76	✗
77	✗
78	✗
79	✓
80	✗
81	✗
82	✓
83	✗
84	✗
85	✗
86	✗
87	✗
88	✗
89	✗
90	✗
91	✗
92	✗
93	✓
94	✗
95	✓
96	✗
97	✗
98	✗
99	✗
100	✗
101	✗
102	✗
103	✓
104	✗
105	✗
106	✓
107	✗

108	✕
109	✕
110	✕
111	-

All contents of this site are © 2024 Passmedicine Limited

A 66-year-old man is referred to the Acute Medical Assessment Unit for progressive shortness of breath by their GP. Previous medical history includes ischaemic heart disease, left ventricular hypertrophy with reduced ejection fraction, hypertension and type 2 diabetes. He is a retired dockworker and has smoked 20 cigarettes a day for the last 50 years.

Hb	150 g/L	Male: (135-180) Female: (115 - 160)
Platelets	254 * 10^9/L	(150 - 400)
WBC	11.6 * 10^9/L	(4.0 - 11.0)
Na^+	132 mmol/L	(135 - 145)
K^+	3.9 mmol/L	(3.5 - 5.0)
Urea	6.5 mmol/L	(2.0 - 7.0)
Creatinine	119 µmol/L	(55 - 120)
CRP	15 mg/L	(< 5)

A chest x-ray shows bilateral pleural effusions, cardiomyopathy and pleural plaques.

He is admitted for intravenous diuresis to treat his pleural effusions. He initially responds to treatment but there is a significant residual pleural effusion on the right-hand side.

What investigation would you undertake next for the residual right-sided pleural effusion?

- Bronchoscopy
- Chest drain with a sample of pleural fluid sent for investigation
- Continue diuresis and review
- Diagnostic aspiration
- High resolution computed tomography of the thorax

Submit answer

Reference ranges

Score: **16%**

1	✗
2	✗
3	✗
4	✗
5	✗
6	✗
7	✗
8	✗
9	✗
10	✗
11	✗
12	✓
13	✗
14	✗
15	✗
16	✗
17	✗
18	✗
19	✗
20	✗
21	✗
22	✗
23	✓
24	✗
25	✗
26	✗
27	✗
28	✗
29	✓
30	✗

31	✓
32	✗
33	✗
34	✗
35	✗
36	✓
37	✓
38	✗
39	✗
40	✗
41	✓
42	✗
43	✗
44	✗
45	✗
46	✗
47	✗
48	✗
49	✓
50	✗
51	-
52	-
53	-
54	-
55	-
56	-
57	-
58	-
59	-
60	-
61	-
62	-
63	-
64	-
65	-
66	-
67	-
68	-

69	-
70	-
71	-
72	-
73	-
74	-
75	-
76	-
77	-
78	-
79	-
80	-
81	-
82	-
83	-
84	-
85	-

All contents of this site are © 2024 Passmedicine Limited

Back to top

A 66-year-old man is referred to the Acute Medical Assessment Unit for progressive shortness of breath by their GP. Previous medical history includes ischaemic heart disease, left ventricular hypertrophy with reduced ejection fraction, hypertension and type 2 diabetes. He is a retired dockworker and has smoked 20 cigarettes a day for the last 50 years.

Hb	150 g/L	Male: (135-180) Female: (115 - 160)
Platelets	254 * 10^9/L	(150 - 400)
WBC	11.6 * 10^9/L	(4.0 - 11.0)
Na^+	132 mmol/L	(135 - 145)
K^+	3.9 mmol/L	(3.5 - 5.0)
Urea	6.5 mmol/L	(2.0 - 7.0)
Creatinine	119 µmol/L	(55 - 120)
CRP	15 mg/L	(< 5)

A chest x-ray shows bilateral pleural effusions, cardiomyopathy and pleural plaques.

He is admitted for intravenous diuresis to treat his pleural effusions. He initially responds to treatment but there is a significant residual pleural effusion on the right-hand side.

What investigation would you undertake next for the residual right-sided pleural effusion?

- Bronchoscopy 2%
- Chest drain with a sample of pleural fluid sent for investigation 25%
- Continue diuresis and review 4%
- Diagnostic aspiration 55%
- High resolution computed tomography of the thorax 14%

In the assessment of a pleural effusions, if the clinical picture suggests a transudate, then you should treat the cause initially. If this does not resolve the effusion then perform a diagnostic aspiration

Important for me Less important

Diagnostic aspiration is correct. A pleural aspiration is appropriate now that a malignant or exudate pleural effusion is suspected. Initially, the bilateral pleural effusions were suspected to be transudate due to the patient's cardiovascular history and were treated with diuresis. However, the residual effusion, which fails to resolve despite the resolution of the left-sided effusion, needs further investigation. This can either be a small or large volume aspiration depending on the patient's clinical picture and degree of respiratory compromise. A small volume would be for diagnostic purposes, if the patient remains compromised by the effusion, for example, work of breathing, oxygen requirement or exercise tolerance, then a large volume aspiration can be performed. It is very important to ensure that you have all the sampling equipment ready at the time of the intervention as multiple sample collection devices are often required. A chest drain may be required based on the results of the diagnosis aspiration.

Bronchoscopy is incorrect as this does not investigate pleural effusions. Uses for bronchoscopy include; suspected tumour, biopsy (including end-bronchial ultrasound), foreign body, infection or inflammation. Indications for this include localised wheeze from a possible foreign body, haemoptysis, biopsy of proximal tumour seen on CT, mucus sample collection for atypical infections and diagnosis of sarcoidosis.

Chest drain with a sample of pleural fluid sent for investigation is incorrect. The initial investigation for a possible malignant or exudate effusion would be a pleural aspiration and a review of samples taken. Should this continue to be a transudate effusion chest drain insertion would not be the next step.

Continue diuresis and review is incorrect. The initial suspicion was that the patient had bilateral transudate effusions. These do not need aspiration of the fluid and the patient was treated with a diuretic. However, there has been a failure to resolve unilaterally and given the patient's pleural plaques and, likely asbestos exposure in his employment, further investigation is warranted.

High resolution computed tomography of the thorax is incorrect. This investigation would be more appropriate to investigate idiopathic interstitial pneumonia, asbestosis, inflammation, drug reaction or diffuse alveolar damage.

Discuss (4) Improve

Next question

Pleural effusion: investigation and management

The British Thoracic Society (BTS) produced guidelines in 2010 covering the investigation of patients with a pleural effusion.

Imaging
- posterioranterior (PA) chest x-rays should be performed in all patients
- ultrasound is recommended: it increases the likelihood of successful pleural aspiration and is sensitive for detecting pleural fluid septations
- contrast CT is now increasingly performed to investigate the underlying cause, particularly for exudative effusions

Pleural aspiration
- as above, ultrasound is recommended to reduce the complication rate
- a 21G needle and 50ml syringe should be used
- fluid should be sent for pH, protein, lactate dehydrogenase (LDH), cytology and microbiology

Light's criteria was developed in 1972 to help distinguish between a transudate and an exudate. The BTS recommend using the criteria for borderline cases:
- exudates have a protein level of >30 g/L, transudates have a protein level of <30 g/L
- if the protein level is between 25-35 g/L, Light's criteria should be applied. An exudate is likely if at least one of the following criteria are met:
  - pleural fluid protein divided by serum protein >0.5
  - pleural fluid LDH divided by serum LDH >0.6
  - pleural fluid LDH more than two-thirds the upper limits of normal serum LDH

Other characteristic pleural fluid findings:
- low glucose: rheumatoid arthritis, tuberculosis
- raised amylase: pancreatitis, oesophageal perforation
- heavy blood staining: mesothelioma, pulmonary embolism, tuberculosis

Pleural infection

All patients with a pleural effusion in association with sepsis or a pneumonic illness require diagnostic pleural fluid sampling

- if the fluid is purulent or turbid/cloudy a chest tube should be placed to allow drainage
- if the fluid is clear but the **pH is less than 7.2 in patients with suspected pleural infection a chest tube should be placed**

Management of recurrent pleural effusion

Options for managing patients with recurrent pleural effusions include:

- recurrent aspiration
- pleurodesis
- indwelling pleural catheter
- drug management to alleviate symptoms e.g. opioids to relieve dyspnoea

AI + Q 123

Next question >

Textbooks

High-yield textbook

Extended textbook

Links

British Thoracic Society 17 14

2023 Pleural disease guidelines

Royal College of Physicians

13 7

2012 Pleural infection review

Suggest link

Report broken link

Media

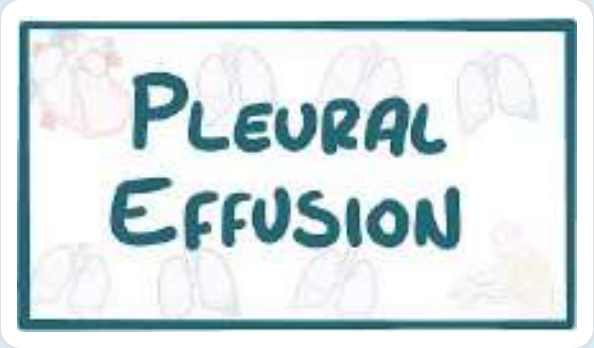

Pleural effusion

Osmosis - YouTube 8 1

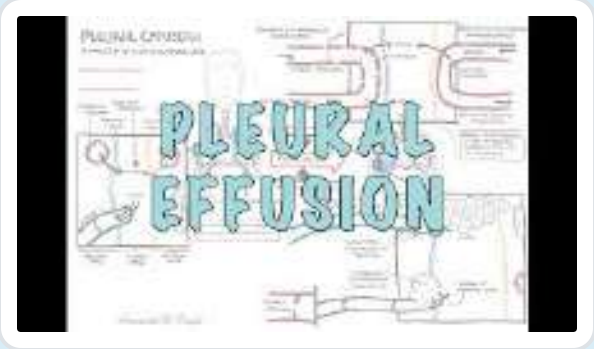

Pleural effusion

Armando Hasudungan - YouTube 6 1

Report broken media

Score: **17.3%**

1 ✕
2 ✕
3 ✕
4 ✕
5 ✕
6 ✕
7 ✕
8 ✕
9 ✕
10 ✕
11 ✕

12	✓
13	✗
14	✗
15	✗
16	✗
17	✗
18	✗
19	✗
20	✗
21	✗
22	✗
23	✓
24	✗
25	✗
26	✗
27	✗
28	✗
29	✓
30	✗
31	✓
32	✗
33	✗
34	✗
35	✗
36	✓
37	✓
38	✗
39	✗
40	✗
41	✓
42	✗
43	✗
44	✗
45	✗
46	✗
47	✗

48	✗
49	✓
50	✗
51	✗
52	✓
53	✗
54	✗
55	✓
56	✗
57	✗
58	✓
59	✗
60	✓
61	✗
62	✗
63	✗
64	✗
65	✗
66	✗
67	✗
68	✗
69	✗
70	✗
71	✗
72	✗
73	✗
74	✗
75	✓
76	✗
77	✗
78	✗
79	✓
80	✗
81	✗
82	✓
83	✗

84	✗
85	✗
86	✗
87	✗
88	✗
89	✗
90	✗
91	✗
92	✗
93	✓
94	✗
95	✓
96	✗
97	✗
98	✗
99	✗
100	✗
101	✗
102	✗
103	✓
104	✗
105	✗
106	✓
107	✗
108	✗
109	✗
110	✗
111	-

All contents of this site are © 2024 Passmedicine Limited

Back to top

You are reviewing a 70-year-old man in the respiratory outpatient clinic.

He recently presented to the hospital with dyspnea. This has been gradually getting worse over several months and then acutely worsened in the days leading up to his hospital admission. His exercise tolerance had changed from a baseline MRC dyspnoea score of 3 to 5. There was an associated productive cough of white sputum. There was no history of a purulent cough, fevers or chest pain. He is a smoker with a 50 pack year history and his previous jobs were in administration. He has no pets. He denies any other medical or surgical conditions.

Examination at the time of hospital presentation revealed reduced breath sounds globally, expiratory wheeze and fine bibasal crepitations that did not change with coughing.

You reviewed this gentleman in the hospital and he was managed as a non-infective exacerbation of newly diagnosed chronic obstructive pulmonary disease, with nebulized bronchodilators and a short course of prednisolone. He was discharged on a combination Glycopyrronium and Indacaterol inhaler and you had arranged further outpatient investigations.

The results of these tests are available in today's clinic:

Tests	Result
FEV1	108% predicted
FVC	107% predicted
Total lung capacity	121% predicted
Diffusion capacity for carbon monoxide	36% predicted
High-resolution CT thorax	centrilobular emphysematous change in the upper lobes bilaterally. There are subpleural reticular opacities and honeycombing in both lung bases, with no traction bronchiectasis or ground glass opacities

Whilst his dyspnoea is improved, he still has an MRC dyspnoea score of 3-4. Repeat examination today in the clinic is unchanged from his examination findings in hospital.

The patient and his wife are very concerned about the deterioration in his breathing.

Which of the following is correct regarding his condition?

- He has combined pulmonary fibrosis and emphysema (CPFE)
- He has emphysema with non-specific interstitial pneumonia (NSIP)
- His risk of developing lung cancer is similar when compared to patients with emphysema alone
- His risk of developing pulmonary arterial hypertension is similar when compared to patients with emphysema alone
- The changes seen in the upper lobes on the high resolution CT thorax are atypical for smoking related emphysema.

Submit answer

Reference ranges

Score: **16%**

1	✗
2	✗
3	✗
4	✗
5	✗
6	✗
7	✗
8	✗
9	✗
10	✗
11	✗
12	✓
13	✗

14 ✗
15 ✗
16 ✗
17 ✗
18 ✗
19 ✗
20 ✗
21 ✗
22 ✗
23 ✓
24 ✗
25 ✗
26 ✗
27 ✗
28 ✗
29 ✓
30 ✗
31 ✓
32 ✗
33 ✗
34 ✗
35 ✗
36 ✓
37 ✓
38 ✗
39 ✗
40 ✗
41 ✓
42 ✗
43 ✗
44 ✗
45 ✗
46 ✗
47 ✗
48 ✗
49 ✓

50	✗
51	-
52	-
53	-
54	-
55	-
56	-
57	-
58	-
59	-
60	-
61	-
62	-
63	-
64	-
65	-
66	-
67	-
68	-
69	-
70	-
71	-
72	-
73	-
74	-
75	-
76	-
77	-
78	-
79	-
80	-
81	-
82	-
83	-
84	-
85	-
86	-

All contents of this site are © 2024 Passmedicine Limited

You are reviewing a 70-year-old man in the respiratory outpatient clinic.

He recently presented to the hospital with dyspnea. This has been gradually getting worse over several months and then acutely worsened in the days leading up to his hospital admission. His exercise tolerance had changed from a baseline MRC dyspnoea score of 3 to 5. There was an associated productive cough of white sputum. There was no history of a purulent cough, fevers or chest pain. He is a smoker with a 50 pack year history and his previous jobs were in administration. He has no pets. He denies any other medical or surgical conditions.

Examination at the time of hospital presentation revealed reduced breath sounds globally, expiratory wheeze and fine bibasal crepitations that did not change with coughing.

You reviewed this gentleman in the hospital and he was managed as a non-infective exacerbation of newly diagnosed chronic obstructive pulmonary disease, with nebulized bronchodilators and a short course of prednisolone. He was discharged on a combination Glycopyrronium and Indacaterol inhaler and you had arranged further outpatient investigations.

The results of these tests are available in today's clinic:

Tests	Result
FEV1	108% predicted
FVC	107% predicted
Total lung capacity	121% predicted
Diffusion capacity for carbon monoxide	36% predicted
High-resolution CT thorax	centrilobular emphysematous change in the upper lobes bilaterally. There are subpleural reticular opacities and honeycombing in both lung bases, with no traction bronchiectasis or ground glass opacities

Whilst his dyspnoea is improved, he still has an MRC dyspnoea score of 3-4. Repeat examination today in the clinic is unchanged from his examination findings in hospital.

The patient and his wife are very concerned about the deterioration in his breathing.

Which of the following is correct regarding his condition?

- He has combined pulmonary fibrosis and emphysema (CPFE) — 66%
- He has emphysema with non-specific interstitial pneumonia (NSIP) — 21%
- His risk of developing lung cancer is similar when compared to patients with emphysema alone — 3%
- His risk of developing pulmonary arterial hypertension is similar when compared to patients with emphysema alone — 3%
- The changes seen in the upper lobes on the high resolution CT thorax are atypical for smoking related emphysema. — 8%

Combined pulmonary fibrosis and emphysema (CPFE) has a much higher rate of lung cancer than emphysema alone

Important for me Less important

This gentleman has a syndrome called combined pulmonary fibrosis and emphysema (CPFE). Patients with CPFE have significantly higher rates of lung cancer compared to those with emphysema (or idiopathic pulmonary fibrosis) alone. They also have an increased risk of developing pulmonary arterial hypertension, which is often less responsive to medical treatments, meaning lung transplantation should be considered in such cases.

CPFE is characterized by exertional dyspnoea, upper-lobe emphysema and lower-lobe fibrosis, preserved lung volume and severely reduced capacity of gas exchange. The preserved lung volumes are thought to arise because of the counterbalanced effects of hyperinflation from emphysema and the restrictive effects of pulmonary fibrosis. Both mechanisms lead to reduced gas exchange, hence the significantly reduced DLCO.

Option A - the correct answer

Options B - the HRCT findings of basal predominance fibrosis and honeycombing is consistent with a usual interstitial pneumonia (UIP) pattern. Traction bronchiectasis may or may not be present in UIP. Non-specific interstitial pneumonia (NSIP) is radiologically characterized by symmetric bilateral areas of ground-glass opacity with superimposed fine reticular opacities but with no or only minimal honeycombing

Options C and D - as described above, patients with CPFE have a significantly higher risk of

developing lung cancer and/or pulmonary arterial hypertension

Option E - Emphysema secondary to smoking is typically upper lobe predominant, centrilobular and commonly manifests as small, localized areas of low attenuation within the central portion of the secondary pulmonary lobule on HRCT

Discuss (3) | Improve

Next question

COPD: features

Chronic obstructive pulmonary disease (COPD) is one of the most common diagnoses encountered in medical practice. COPD is an umbrella term encompassing the older terms chronic bronchitis and emphysema. In the vast majority of cases, COPD is caused by smoking. Some patients with more mild disease may just need to use a bronchodilator occasionally whereas other patients may have several hospital admissions a year secondary to infective exacerbations.

Features

- cough: often productive
- dyspnoea
- wheeze
- in severe cases, right-sided heart failure may develop resulting in peripheral oedema

The following investigations are recommended in patients with suspected COPD:

- post-bronchodilator spirometry to demonstrate airflow obstruction: FEV1/FVC ratio less than 70%
- chest x-ray
  - hyperinflation
  - bullae: if large, may sometimes mimic a pneumothorax
  - flat hemidiaphragm
  - also important to exclude lung cancer
- full blood count: exclude secondary polycythaemia
- body mass index (BMI) calculation

The severity of COPD is categorised using the FEV1*:

Post-bronchodilator FEV1/FVC	FEV1 (of predicted)	Severity
< 0.7	> 80%	Stage 1 - Mild**
< 0.7	50-79%	Stage 2 - Moderate
< 0.7	30-49%	Stage 3 - Severe
< 0.7	< 30%	Stage 4 - Very severe

Measuring peak expiratory flow is of limited value in COPD, as it may underestimate the degree of airflow obstruction.

*note that the grading system has changed following the 2010 NICE guidelines. If the FEV1 is greater than 80% predicted but the post-bronchodilator FEV1/FVC is < 0.7 then this is classified as Stage 1 - mild

**symptoms should be present to diagnose COPD in these patients

+ Q 123

Next question >

Textbooks

High-yield textbook

Extended textbook

Links

Clinical Knowledge Summaries 2 5

Chronic obstructive pulmonary disease

NICE

2018 COPD management diagram

4 5

NICE

2018 COPD guidelines

9 2

Suggest link

Report broken link

Media

Chronic bronchitis

Osmosis - YouTube 3 0

All about COPD (for Medical Students)

MedFlix - YouTube 1 0

Understanding COPD

Armando Hasudungan - YouTube 0 0

Report broken media

Score: **17.3%**

1	✗
2	✗
3	✗
4	✗
5	✗
6	✗
7	✗
8	✗
9	✗
10	✗
11	✗
12	✓
13	✗
14	✗
15	✗
16	✗
17	✗
18	✗
19	✗
20	✗
21	✗
22	✗
23	✓
24	✗
25	✗
26	✗
27	✗
28	✗
29	✓
30	✗
31	✓
32	✗
33	✗
34	✗
35	✗

36	✓
37	✓
38	✗
39	✗
40	✗
41	✓
42	✗
43	✗
44	✗
45	✗
46	✗
47	✗
48	✗
49	✓
50	✗
51	✗
52	✓
53	✗
54	✗
55	✓
56	✗
57	✗
58	✓
59	✗
60	✓
61	✗
62	✗
63	✗
64	✗
65	✗
66	✗
67	✗
68	✗
69	✗
70	✗
71	✗

72	✗
73	✗
74	✗
75	✓
76	✗
77	✗
78	✗
79	✓
80	✗
81	✗
82	✓
83	✗
84	✗
85	✗
86	✗
87	✗
88	✗
89	✗
90	✗
91	✗
92	✗
93	✓
94	✗
95	✓
96	✗
97	✗
98	✗
99	✗
100	✗
101	✗
102	✗
103	✓
104	✗
105	✗
106	✓
107	✗

108	✕
109	✕
110	✕
111	-

All contents of this site are © 2024 Passmedicine Limited

A 76-year-old man presented with vague lower abdominal pain. He was known to have underlying type 2 diabetes mellitus,hypertension and severe chronic obstructive pulmonary disease(COPD). He was a smoker with 50 pack years smoking history.

A CT abdomen was taken which showed diverticular disease of the colon. Incidentally it also showed a 2.5 cm mass in the periphery of the lower lobe of the left lung. Subsequently he underwent a positron emission tomography(PET) scan which showed the lung lesion with standardised uptake value(SUV) of 12.5 which was highly suspicious of cancer. There was no evidence of spread to lymph nodes or distant sites. A CT guided biopsy of the lung lesion was done which showed squamous cell carcinoma. His performance status was 2 in Eastern Cooperative Oncology Group(ECOG) scale. His lung functions showed an FEV1 of 0.8L(25% predicted) and FVC of 1.3L(30% predicted). TLCO was 30% predicted.

Which of the following is a suitable choice of treatment for him?

- Lobectomy
- Chemotherapy
- Radical radiotherapy
- Lobectomy+chemotherapy
- Best supportive care

Submit answer

Reference ranges

Score: **16%**

1 ×

2	✗
3	✗
4	✗
5	✗
6	✗
7	✗
8	✗
9	✗
10	✗
11	✗
12	✓
13	✗
14	✗
15	✗
16	✗
17	✗
18	✗
19	✗
20	✗
21	✗
22	✗
23	✓
24	✗
25	✗
26	✗
27	✗
28	✗
29	✓
30	✗
31	✓
32	✗
33	✗
34	✗
35	✗
36	✓
37	✓

38	✗
39	✗
40	✗
41	✓
42	✗
43	✗
44	✗
45	✗
46	✗
47	✗
48	✗
49	✓
50	✗
51	-
52	-
53	-
54	-
55	-
56	-
57	-
58	-
59	-
60	-
61	-
62	-
63	-
64	-
65	-
66	-
67	-
68	-
69	-
70	-
71	-
72	-
73	-
74	-
75	-
76	-

77 -
78 -
79 -
80 -
81 -
82 -
83 -
84 -
85 -
86 -
87 -

All contents of this site are © 2024 Passmedicine Limited

A 76-year-old man presented with vague lower abdominal pain. He was known to have underlying type 2 diabetes mellitus,hypertension and severe chronic obstructive pulmonary disease(COPD). He was a smoker with 50 pack years smoking history.

A CT abdomen was taken which showed diverticular disease of the colon. Incidentally it also showed a 2.5 cm mass in the periphery of the lower lobe of the left lung. Subsequently he underwent a positron emission tomography(PET) scan which showed the lung lesion with standardised uptake value(SUV) of 12.5 which was highly suspicious of cancer. There was no evidence of spread to lymph nodes or distant sites. A CT guided biopsy of the lung lesion was done which showed squamous cell carcinoma. His performance status was 2 in Eastern Cooperative Oncology Group(ECOG) scale. His lung functions showed an FEV1 of 0.8L(25% predicted) and FVC of 1.3L(30% predicted). TLCO was 30% predicted.

Which of the following is a suitable choice of treatment for him?

Lobectomy	12%
Chemotherapy	21%
Radical radiotherapy	23%
Lobectomy+chemotherapy	31%
Best supportive care	13%

This is a stage IB lung cancer. Surgery is the best curative option provided the lung functions and performance status are suitable for surgery.

NICE guidelines says- 'Patients who have poor lung function but are otherwise suitable for radical radiotherapy should still be offered radiotherapy, provided the volume of irradiated lung is small'.

European Society for Medical Oncology (ESMO) guidelines-2014 says 'in those patients who are not suitable for surgery and with a peripheral tumour(like the patient in the question), Stereotactic Ablative Radiotherapy(SABR) given at a biologically equivalent dose of >100Gy is the preferred treatment of choice.

A systematic review comparing outcomes of SABR and surgery in patients with severe COPD revealed a higher 30-day mortality following surgery but similar overall survival at 1 and 3 years. NCCN(National Comprehensive Cancer Network) guidelines-2015 for non-small cell lung cancer says SABR is an appropriate option for patients with high surgical risk. SABR and sublobar resection both achieve comparable cancer specific survival and primary tumour control.

Reference:
1) https://www.nice.org.uk/guidance/cg121/resources/lung-cancer-diagnosis-and-management-35109444863941
2) ESMO (European society for medical oncology) consensus guidelines-2014
http://annonc.oxfordjournals.org/content/25/8/1462.full.pdf+html
3) NCCN(National Comprehensive Cancer Network) guidelines-2015 for non-small cell lung cancer.

Discuss (8) Improve

Next question >

Lung cancer: non-small cell management

Management
- only 20% suitable for surgery
  - mediastinoscopy performed prior to surgery as CT does not always show mediastinal lymph node involvement
- curative or palliative radiotherapy
- poor response to chemotherapy

Surgery contraindications
- assess general health
- stage IIIb or IV (i.e. metastases present)
- FEV1 < 1.5 litres is considered a general cut-off point*
- malignant pleural effusion
- tumour near hilum
- vocal cord paralysis
- SVC obstruction

* However if FEV1 < 1.5 for lobectomy or < 2.0 for pneumonectomy then some authorities advocate further lung function tests as operations may still go ahead based on the results

AI + Q 123

Next question

Textbooks

High-yield textbook

Extended textbook

Links

SIGN 2 3

2014 Lung cancer management guidelines

Radiopaedia 8 2

Lung cancer review

Suggest link

Report broken link

Media

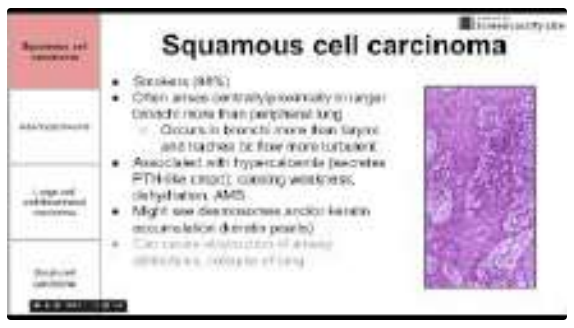

Cancers of the lung

MedLecturesMadeEasy - YouTube 2 0

Lung cancer

MedFlix - YouTube 2 1

Report broken media

Score: **17.3%**

1	✗
2	✗
3	✗
4	✗
5	✗
6	✗
7	✗
8	✗
9	✗
10	✗
11	✗
12	✓
13	✗
14	✗
15	✗
16	✗
17	✗
18	✗
19	✗
20	✗
21	✗
22	✗
23	✓
24	✗
25	✗
26	✗
27	✗

28	✗
29	✓
30	✗
31	✓
32	✗
33	✗
34	✗
35	✗
36	✓
37	✓
38	✗
39	✗
40	✗
41	✓
42	✗
43	✗
44	✗
45	✗
46	✗
47	✗
48	✗
49	✓
50	✗
51	✗
52	✓
53	✗
54	✗
55	✓
56	✗
57	✗
58	✓
59	✗
60	✓
61	✗
62	✗
63	✗

64	✗
65	✗
66	✗
67	✗
68	✗
69	✗
70	✗
71	✗
72	✗
73	✗
74	✗
75	✓
76	✗
77	✗
78	✗
79	✓
80	✗
81	✗
82	✓
83	✗
84	✗
85	✗
86	✗
87	✗
88	✗
89	✗
90	✗
91	✗
92	✗
93	✓
94	✗
95	✓
96	✗
97	✗
98	✗
99	✗

100	✗
101	✗
102	✗
103	✓
104	✗
105	✗
106	✓
107	✗
108	✗
109	✗
110	✗
111	-

All contents of this site are © 2024 Passmedicine Limited

Back to top

A 64 year-old female patient with known chronic obstructive pulmonary disease presents for routine review at respiratory outpatients. She is currently taking inhaled tiotropium and salmeterol/fluticasone at optimal doses. You note she has had two exacerbations in the previous 12 months requiring oral steroids and antibiotics. A recent high resolution CT showed severe emphysema affecting all lobes.

Her ABGs in clinic today is a follows:

pH	7.38
pO2	7.91 kPa
pCO2	6.7 kPa
HCO3	30.1 mmol/L
Sats	88%

Her blood tests today show:

Hb	16.6 g/dL
Platelets	256 x 10 9 /L
WCC	6.7 x 10 9 /L

How would you optimise her management further?

- Refer to lung volume reduction surgery
- Make no changes to current management
- Consider long term oxygen therapy
- Start prophylactic antibiotics
- Refer for assessment for home non-invasive ventilation

Submit answer

Reference ranges

Score: **16%**

1	✗
2	✗
3	✗
4	✗
5	✗
6	✗
7	✗
8	✗
9	✗
10	✗
11	✗
12	✓
13	✗
14	✗
15	✗
16	✗
17	✗
18	✗
19	✗
20	✗
21	✗
22	✗
23	✓
24	✗
25	✗
26	✗
27	✗
28	✗
29	✓
30	✗

31	✓
32	✗
33	✗
34	✗
35	✗
36	✓
37	✓
38	✗
39	✗
40	✗
41	✓
42	✗
43	✗
44	✗
45	✗
46	✗
47	✗
48	✗
49	✓
50	✗
51	-
52	-
53	-
54	-
55	-
56	-
57	-
58	-
59	-
60	-
61	-
62	-
63	-
64	-
65	-
66	-
67	-
68	-

69 -
70 -
71 -
72 -
73 -
74 -
75 -
76 -
77 -
78 -
79 -
80 -
81 -
82 -
83 -
84 -
85 -
86 -
87 -
88 -

All contents of this site are © 2024 Passmedicine Limited
Back to top

A 64 year-old female patient with known chronic obstructive pulmonary disease presents for routine review at respiratory outpatients. She is currently taking inhaled tiotropium and salmeterol/fluticasone at optimal doses. You note she has had two exacerbations in the previous 12 months requiring oral steroids and antibiotics. A recent high resolution CT showed severe emphysema affecting all lobes.

Her ABGs in clinic today is a follows:

pH	7.38
pO2	7.91 kPa
pCO2	6.7 kPa
HCO3	30.1 mmol/L
Sats	88%

Her blood tests today show:

Hb	16.6 g/dL
Platelets	256 x 10 9 /L
WCC	6.7 x 10 9 /L

How would you optimise her management further?

- Refer to lung volume reduction surgery 14%
- Make no changes to current management 8%
- Consider long term oxygen therapy 57%
- Start prophylactic antibiotics 8%
- Refer for assessment for home non-invasive ventilation 13%

This lady is polycythaemic and has a resting pO2 less than 8.0kPa and therefore is a candidate for long term oxygen therapy. It may be prudent to repeat an ABG in one month to ensure a findings are similar prior to staring oxygen.

COPD: long-term oxygen therapy

The 2018 NICE guidelines on COPD clearly define which patients should be assessed for and offered long-term oxygen therapy (LTOT). Patients who receive LTOT should breathe supplementary oxygen for at least 15 hours a day. Oxygen concentrators are used to provide a fixed supply for LTOT.

Assess patients if any of the following:

- very severe airflow obstruction (FEV1 < 30% predicted). Assessment should be 'considered' for patients with severe airflow obstruction (FEV1 30-49% predicted)
- cyanosis
- polycythaemia
- peripheral oedema
- raised jugular venous pressure
- oxygen saturations less than or equal to 92% on room air

Assessment is done by measuring arterial blood gases on 2 occasions at least 3 weeks apart in patients with stable COPD on optimal management.

Offer LTOT to patients with a pO2 of < 7.3 kPa or to those with a pO2 of 7.3 - 8 kPa and one of the following:

- secondary polycythaemia
- peripheral oedema
- pulmonary hypertension

In terms of smoking, NICE advise the following:

- do not offer LTOT to people who continue to smoke despite being offered smoking cessation advice and treatment, and referral to specialist stop smoking services.

NICE suggest that a structured risk assessment is carried out before offering LTOT, including:

- the risks of falls from tripping over the equipment
- the risks of burns and fires, and the increased risk of these for people who live in homes where someone smokes (including e-cigarettes)

123

Next question

Textbooks

High-yield textbook

Extended textbook

Links

NICE

17 6

2018 COPD guidelines

Suggest link

Report broken link

Score: **17.3%**

1 ✗
2 ✗
3 ✗
4 ✗
5 ✗
6 ✗
7 ✗
8 ✗

9	✗
10	✗
11	✗
12	✓
13	✗
14	✗
15	✗
16	✗
17	✗
18	✗
19	✗
20	✗
21	✗
22	✗
23	✓
24	✗
25	✗
26	✗
27	✗
28	✗
29	✓
30	✗
31	✓
32	✗
33	✗
34	✗
35	✗
36	✓
37	✓
38	✗
39	✗
40	✗
41	✓
42	✗
43	✗
44	✗

45	✗
46	✗
47	✗
48	✗
49	✓
50	✗
51	✗
52	✓
53	✗
54	✗
55	✓
56	✗
57	✗
58	✓
59	✗
60	✓
61	✗
62	✗
63	✗
64	✗
65	✗
66	✗
67	✗
68	✗
69	✗
70	✗
71	✗
72	✗
73	✗
74	✗
75	✓
76	✗
77	✗
78	✗
79	✓
80	✗

81	✗
82	✓
83	✗
84	✗
85	✗
86	✗
87	✗
88	✗
89	✗
90	✗
91	✗
92	✗
93	✓
94	✗
95	✓
96	✗
97	✗
98	✗
99	✗
100	✗
101	✗
102	✗
103	✓
104	✗
105	✗
106	✓
107	✗
108	✗
109	✗
110	✗
111	-

All contents of this site are © 2024 Passmedicine Limited

A 72-year-old man was admitted to hospital with an exacerbation of his longstanding chronic obstructive airways disease. The patient's regular treatment for COPD included home oxygen, home bronchodilator nebulisers and high-dose inhaled steroids. Normal exercise tolerance was very limited with the patient becoming profoundly breathless after mobilising only short distances around his house. Following an admission to the intensive care unit for respiratory support the previous winter the patient had expressed a wish that he would not want non-invasive ventilation or intubation in the future and stated that control of his symptoms was his priority.

Treatment with prednisolone, nebulised bronchodilators and antibiotics was started on admission. Having been profoundly dyspneoic at rest at admission the patient's symptoms improved gradually over the next week until the patient returned to his baseline of dyspnoea on minimal physical exertion. He again requests if there is any other treatments that can ameliorate his symptoms.

Recent investigations are summarised below.

Forced vital capacity: 115 % predicted
Forced expiratory volume (1s): 34 % predicted
FEV1 / FVC: 30 % predicted

Haemoglobin	170 g / dL
White cell count	15.8 * 10^9/l
Platelets	167 * 10^9/l
Urea	6.7 mmol / L
Creatinine	98 micromol / L
Sodium	140 mmol / L
Potassium	4.1 mmol / L
Packed cell volume	0.42

What treatment is the best choice for relief of dyspnoea in this patient?

- Short-acting liquid morphine sulphate prn
- Venesection

- Diazepam 2mg qds
- High-flow oxygen (15L, 100%)
- Refer to thoracic surgery for consideration of pleurodesis

Submit answer

Reference ranges

Score: **16%**

1	✗
2	✗
3	✗
4	✗
5	✗
6	✗
7	✗
8	✗
9	✗
10	✗
11	✗
12	✓
13	✗
14	✗
15	✗
16	✗
17	✗
18	✗
19	✗
20	✗
21	✗

22	✗
23	✓
24	✗
25	✗
26	✗
27	✗
28	✗
29	✓
30	✗
31	✓
32	✗
33	✗
34	✗
35	✗
36	✓
37	✓
38	✗
39	✗
40	✗
41	✓
42	✗
43	✗
44	✗
45	✗
46	✗
47	✗
48	✗
49	✓
50	✗
51	-
52	-
53	-
54	-
55	-
56	-
57	-
58	-

59	-
60	-
61	-
62	-
63	-
64	-
65	-
66	-
67	-
68	-
69	-
70	-
71	-
72	-
73	-
74	-
75	-
76	-
77	-
78	-
79	-
80	-
81	-
82	-
83	-
84	-
85	-
86	-
87	-
88	-
89	-

All contents of this site are © 2024 Passmedicine Limited

Back to top

A 72-year-old man was admitted to hospital with an exacerbation of his longstanding chronic obstructive airways disease. The patient's regular treatment for COPD included home oxygen, home bronchodilator nebulisers and high-dose inhaled steroids. Normal exercise tolerance was very limited with the patient becoming profoundly breathless after mobilising only short distances around his house. Following an admission to the intensive care unit for respiratory support the previous winter the patient had expressed a wish that he would not want non-invasive ventilation or intubation in the future and stated that control of his symptoms was his priority.

Treatment with prednisolone, nebulised bronchodilators and antibiotics was started on admission. Having been profoundly dyspneoic at rest at admission the patient's symptoms improved gradually over the next week until the patient returned to his baseline of dyspnoea on minimal physical exertion. He again requests if there is any other treatments that can ameliorate his symptoms.

Recent investigations are summarised below.

Forced vital capacity: 115 % predicted
Forced expiratory volume (1s): 34 % predicted
FEV1 / FVC: 30 % predicted

Haemoglobin	170 g / dL
White cell count	15.8 * 10^9/l
Platelets	167 * 10^9/l
Urea	6.7 mmol / L
Creatinine	98 micromol / L
Sodium	140 mmol / L
Potassium	4.1 mmol / L
Packed cell volume	0.42

What treatment is the best choice for relief of dyspnoea in this patient?

- Short-acting liquid morphine sulphate prn — 60%
- Venesection — 12%

Diazepam 2mg qds	10%
High-flow oxygen (15L, 100%)	9%
Refer to thoracic surgery for consideration of pleurodesis	9%

The patient has end-stage COPD and has himself indicated that control of symptoms is his priority. As such, consideration of the use of opioid or benzodiazepine medications for symptomatic relief of breathlessness is appropriate. A recent prospective study demonstrated that lower dose opioid use (< 30 mg daily oral morphine equivalent) does not increase risk of hospitalisation or increase mortality in patients with COPD on long-term oxygen therapy.

Clinical Knowledge Summaries also support this approach:

> *Offer an opioid as first-line treatment to help breathlessness in people with end-stage chronic obstructive pulmonary disease (COPD) that is unresponsive to other medical treatment.*

Benzodiazepines were shown to not increase admission rates but did increase mortality. The patients packed cell volume is normal; therefore venesection has no role in this case

.

Ekstrom M, Bornefalk-Hermansson A, Abernethy A, Currow D. Safety of benzodiazepines and opioids in very severe respiratory disease. BMJ 2014;348:g445.

Discuss (5) Improve

Next question

COPD: stable management

NICE updated its guidelines on the management of chronic obstructive pulmonary disease (COPD) in 2018.

General management

- >smoking cessation advice: including offering nicotine replacement therapy, varenicline or bupropion
- annual influenza vaccination
- one-off pneumococcal vaccination
- pulmonary rehabilitation to all people who view themselves as functionally disabled by COPD (usually Medical Research Council [MRC] grade 3 and above)

Bronchodilator therapy

- a short-acting beta2-agonist (SABA) or short-acting muscarinic antagonist (SAMA) is first-line treatment
- for patients who remain breathless or have exacerbations despite using short-acting bronchodilators the next step is determined by whether the patient has '*asthmatic features/features suggesting steroid responsiveness*'

There are a number of criteria NICE suggest to determine whether a patient has asthmatic/steroid responsive features:

- any previous, secure diagnosis of asthma or of atopy
- a higher blood eosinophil count - note that NICE recommend a full blood count for all patients as part of the work-up
- substantial variation in FEV1 over time (at least 400 ml)
- substantial diurnal variation in peak expiratory flow (at least 20%)

Interestingly NICE do not recommend formal reversibility testing as one of the criteria. In the guidelines they state that '*routine spirometric reversibility testing is not necessary as part of the diagnostic process or to plan initial therapy with bronchodilators or corticosteroids. It may be unhelpful or misleading...*'. They then go on to discuss why they have reached this conclusion. Please see the guidelines for more details.

No asthmatic features/features suggesting steroid responsiveness

- add a long-acting beta2-agonist (LABA) + long-acting muscarinic antagonist (LAMA)
    - if already taking a SAMA, discontinue and switch to a SABA

Asthmatic features/features suggesting steroid responsiveness

- LABA + inhaled corticosteroid (ICS)
- if patients remain breathless or have exacerbations offer triple therapy i.e. LAMA + LABA + ICS
    - if already taking a SAMA, discontinue and switch to a SABA
- NICE recommend the use of combined inhalers where possible

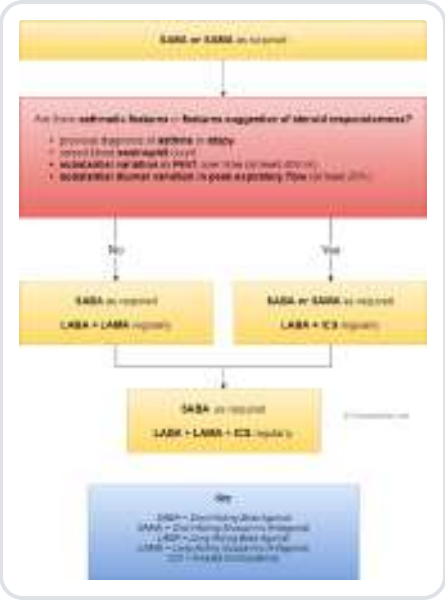

Oral theophylline

- NICE only recommends theophylline after trials of short and long-acting bronchodilators or to people who cannot used inhaled therapy
- the dose should be reduced if macrolide or fluoroquinolone antibiotics are co-prescribed

Oral prophylactic antibiotic therapy

- azithromycin prophylaxis is recommended in select patients
- patients should not smoke, have optimised standard treatments and continue to have exacerbations
- other prerequisites include a CT thorax (to exclude bronchiectasis) and sputum culture (to exclude atypical infections and tuberculosis)
- LFTs and an ECG to exclude QT prolongation should also be done as azithromycin can prolong the QT interval

Standby medication: NICE recommend offering a short course of oral corticosteroids and oral antibiotics to keep at home if: NICE

- have had an exacerbation within the last year
- understand how to take the medication, and are aware of associated risks and benefits
- know to when to seek help and when to ask for replacements once medication has been used

Mucolytics

- should be 'considered' in patients with a chronic productive cough and continued if symptoms improve

Phosphodiesterase-4 (PDE-4) inhibitors NICE

- oral PDE-4 inhibitors such as roflumilast reduce the risk of COPD exacerbations in patients with severe COPD and a history of frequent COPD exacerbations
- NICE recommend if:
    - the disease is severe, defined as a forced expiratory volume in 1 second (FEV1) after a bronchodilator of less than 50% of predicted normal, and
    - the person has had 2 or more exacerbations in the previous 12 months despite triple inhaled therapy with a long-acting muscarinic antagonist, a long-acting beta-2 agonist and an inhaled corticosteroid

Cor pulmonale

- features include peripheral oedema, raised jugular venous pressure, systolic parasternal heave, loud P2
- use a loop diuretic for oedema, consider long-term oxygen therapy
- ACE-inhibitors, calcium channel blockers and alpha blockers are not recommended by NICE

Factors which may improve survival in patients with stable COPD

- smoking cessation - the single most important intervention in patients who are still smoking
- long term oxygen therapy in patients who fit criteria
- lung volume reduction surgery in selected patients

+ Q 123

Next question >

Textbooks

High-yield textbook

Extended textbook

Links

Global Initiative for Chronic Obstructive Lung Disease 14 32

GOLD criteria 2017

NICE 33 30

2018 COPD guidelines

NICE

15 10

[Roflumilast NICE recommendations]

NICE 65 18

[2018 COPD management diagram]

Suggest link · Report broken link

Media

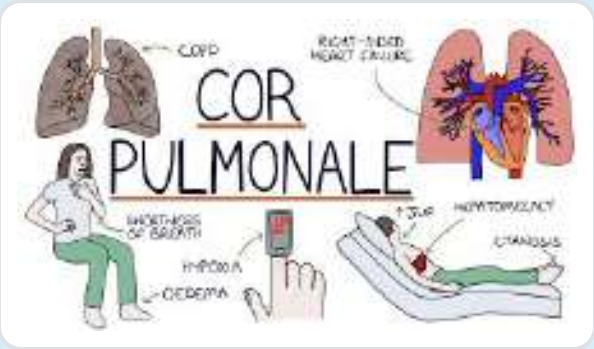

Cor pulmonale

Zero To Finals - YouTube 5 0

Chronic bronchitis

Osmosis - YouTube 3 0

Cor pulmonale

Osmosis - YouTube 1 0

Understanding COPD

Armando Hasudungan - YouTube 0 0

All about COPD (for Medical Students)

MedFlix - YouTube 3 1

Report broken media

Score: **17.3%**

1	✗
2	✗
3	✗
4	✗
5	✗
6	✗
7	✗
8	✗
9	✗
10	✗
11	✗
12	✓
13	✗
14	✗
15	✗
16	✗
17	✗
18	✗
19	✗
20	✗
21	✗
22	✗
23	✓

24	✗
25	✗
26	✗
27	✗
28	✗
29	✓
30	✗
31	✓
32	✗
33	✗
34	✗
35	✗
36	✓
37	✓
38	✗
39	✗
40	✗
41	✓
42	✗
43	✗
44	✗
45	✗
46	✗
47	✗
48	✗
49	✓
50	✗
51	✗
52	✓
53	✗
54	✗
55	✓
56	✗
57	✗
58	✓
59	✗

60	✓
61	✗
62	✗
63	✗
64	✗
65	✗
66	✗
67	✗
68	✗
69	✗
70	✗
71	✗
72	✗
73	✗
74	✗
75	✓
76	✗
77	✗
78	✗
79	✓
80	✗
81	✗
82	✓
83	✗
84	✗
85	✗
86	✗
87	✗
88	✗
89	✗
90	✗
91	✗
92	✗
93	✓
94	✗
95	✓

96	✗
97	✗
98	✗
99	✗
100	✗
101	✗
102	✗
103	✓
104	✗
105	✗
106	✓
107	✗
108	✗
109	✗
110	✗
111	-

All contents of this site are © 2024 Passmedicine Limited

A 63 year old gentleman presented to the acute medical unit with a 3 day history of increasing shortness of breath and cough. He is known to have chronic obstructive pulmonary disease (COPD) and is treated as an infective exacerbation of COPD.
He has a past medical history of ischaemic heart disease, type 2 diabetes mellitus, hypothyroidism, hypercholesterolaemia, hypertension, epilepsy and osteoarthritis.

Despite nebulisers, steroids and antibiotics, he remains acutely breathless and his oxygen saturations are only 83% on air.
Blood gas analysis is as follows:

pH	7.21
pCO2	10.1 kPa
pO2	7.3 kPa
BE	-4.2 mmol/l
HCO3-	36 mEq/l

You opt to try non invasive ventilation (NIV) and he is transferred to the NIV unit. Initial settings on NIV are IPAP (inspiratory positive airways pressure) 10 cm H2O and EPAP (expiratory positive airways pressure) 4 cm H2O. He remains tachypnoeic and has oxygen saturations of 88%. His repeat blood gas after 1 hour is as follows:

pH	7.25
pCO2	9.9 kPa
pO2	9.3 kPa
BE	-4.0 mmol/l
HCO3-	35 mEq/l

Firstly, how would you adjust the NIV settings?

- Increase IPAP by 2 cm H2O
- Increase EPAP by 2 cm H2O
- Increase IPAP and EPAP by 2 cm H2O

- No change in settings
- Add extra inspired oxygen to NIV at 24%

Submit answer

Reference ranges

Score: **16%**

1	✗
2	✗
3	✗
4	✗
5	✗
6	✗
7	✗
8	✗
9	✗
10	✗
11	✗
12	✓
13	✗
14	✗
15	✗
16	✗
17	✗
18	✗
19	✗
20	✗
21	✗
22	✗
23	✓

24	✗
25	✗
26	✗
27	✗
28	✗
29	✓
30	✗
31	✓
32	✗
33	✗
34	✗
35	✗
36	✓
37	✓
38	✗
39	✗
40	✗
41	✓
42	✗
43	✗
44	✗
45	✗
46	✗
47	✗
48	✗
49	✓
50	✗
51	-
52	-
53	-
54	-
55	-
56	-
57	-
58	-
59	-
60	-

61 -
62 -
63 -
64 -
65 -
66 -
67 -
68 -
69 -
70 -
71 -
72 -
73 -
74 -
75 -
76 -
77 -
78 -
79 -
80 -
81 -
82 -
83 -
84 -
85 -
86 -
87 -
88 -
89 -
90 -

All contents of this site are © 2024 Passmedicine Limited
Back to top

A 63 year old gentleman presented to the acute medical unit with a 3 day history of increasing shortness of breath and cough. He is known to have chronic obstructive pulmonary disease (COPD) and is treated as an infective exacerbation of COPD.
He has a past medical history of ischaemic heart disease, type 2 diabetes mellitus, hypothyroidism, hypercholesterolaemia, hypertension, epilepsy and osteoarthritis.

Despite nebulisers, steroids and antibiotics, he remains acutely breathless and his oxygen saturations are only 83% on air.
Blood gas analysis is as follows:

pH	7.21
pCO2	10.1 kPa
pO2	7.3 kPa
BE	-4.2 mmol/l
HCO3-	36 mEq/l

You opt to try non invasive ventilation (NIV) and he is transferred to the NIV unit. Initial settings on NIV are IPAP (inspiratory positive airways pressure) 10 cm H2O and EPAP (expiratory positive airways pressure) 4 cm H2O. He remains tachypnoeic and has oxygen saturations of 88%. His repeat blood gas after 1 hour is as follows:

pH	7.25
pCO2	9.9 kPa
pO2	9.3 kPa
BE	-4.0 mmol/l
HCO3-	35 mEq/l

Firstly, how would you adjust the NIV settings?

- Increase IPAP by 2 cm H2O — 49%
- Increase EPAP by 2 cm H2O — 20%
- Increase IPAP and EPAP by 2 cm H2O — 16%

No change in settings 11%

Add extra inspired oxygen to NIV at 24% 4%

This gentleman is in type 2 respiratory failure secondary to an infective exacerbation of COPD. Initial treatment has failed and NIV is commenced. This helps somewhat initially, but an adjustment in NIV settings is required for optimisation. Given that his main issue is CO2 retention, an increase in IPAP is the correct response as this helps 'blow off' CO2. increasing EPAP splints the airways open and is effectively PEEP and therefore increases oxygenation. This is not particularly required in this gentleman as, although his pO2 is low, this is probably approaching normal for a COPD patient.

Discuss (3) | Improve

Next question

Non-invasive ventilation

The British Thoracic Society (BTS) published guidelines in 2002 on the use of non-invasive ventilation in acute respiratory failure. Following these the Royal College of Physicians published guidelines in 2008.

Non-invasive ventilation - key indications

- COPD with respiratory acidosis pH 7.25-7.35
    - the BTS guidelines state that NIV can be used in patients who are more acidotic (i.e. pH < 7.25) but that a greater degree of monitoring is required (e.g. HDU) and a lower threshold for intubation and ventilation should be used
- type II respiratory failure secondary to chest wall deformity, neuromuscular disease or obstructive sleep apnoea
- cardiogenic pulmonary oedema unresponsive to CPAP
- weaning from tracheal intubation

Recommended initial settings for bi-level pressure support in COPD

- Expiratory Positive Airway Pressure (EPAP): 4-5 cm H2O
- Inspiratory Positive Airway Pressure (IPAP): RCP advocate 10 cm H20 whilst BTS suggest 12-15 cm H2O
- back up rate: 15 breaths/min
- back up inspiration:expiration ratio: 1:3

123

Next question

Textbooks

High-yield textbook

Extended textbook

Links

British Thoracic Society 12 4

2016 BTS/ICS Guidelines for the Ventilatory Management of Acute Hypercapnic Respiratory Failure in Adults

Suggest link Report broken link

Media

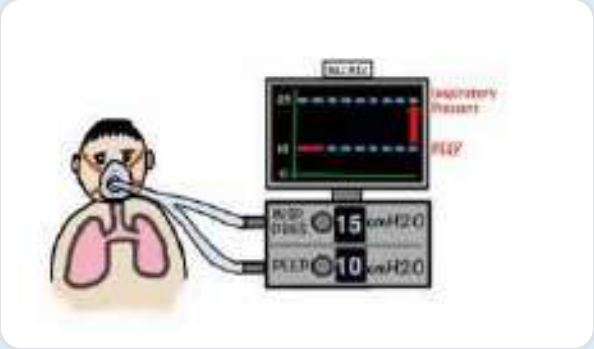

CPAP and Non-Invasive Ventilation in 5 minutes

Nick Smith - YouTube 31 2

Clinical Skills: BiPAP and CPAP

Osmosis - YouTube

3 7

Report broken media

Score: **17.3%**

1	✗
2	✗
3	✗
4	✗
5	✗
6	✗
7	✗
8	✗
9	✗
10	✗
11	✗
12	✓
13	✗
14	✗
15	✗
16	✗
17	✗
18	✗
19	✗
20	✗
21	✗
22	✗
23	✓
24	✗
25	✗
26	✗
27	✗
28	✗

29	✓
30	✗
31	✓
32	✗
33	✗
34	✗
35	✗
36	✓
37	✓
38	✗
39	✗
40	✗
41	✓
42	✗
43	✗
44	✗
45	✗
46	✗
47	✗
48	✗
49	✓
50	✗
51	✗
52	✓
53	✗
54	✗
55	✓
56	✗
57	✗
58	✓
59	✗
60	✓
61	✗
62	✗
63	✗
64	✗

65	✗
66	✗
67	✗
68	✗
69	✗
70	✗
71	✗
72	✗
73	✗
74	✗
75	✓
76	✗
77	✗
78	✗
79	✓
80	✗
81	✗
82	✓
83	✗
84	✗
85	✗
86	✗
87	✗
88	✗
89	✗
90	✗
91	✗
92	✗
93	✓
94	✗
95	✓
96	✗
97	✗
98	✗
99	✗
100	✗

101	✗
102	✗
103	✓
104	✗
105	✗
106	✓
107	✗
108	✗
109	✗
110	✗
111	-

All contents of this site are © 2024 Passmedicine Limited

A 91-year-old man is admitted into hospital with a severe exacerbation of his COPD. He is breathless on rest and although alert and orientated, is starting to become drowsy. His observation reveal a temperature of 37.9ºC, a heart rate of 82 beats per minute, blood pressure of 116/74 mmHg, respiratory rate of 28 breaths per minute and oxygen saturations of 84% on a 28% Venturi mask.

An arterial blood gas is performed and reveals a PaO2 of 9.0 kPa, PCO2 of 11.4kPa, HCO3 of 31 mmol/l and a pH of 7.29.

A decision is made to commence the man on non-invasive ventilation - which of the following is the most appropriate management for this patient?

- Inspiratory positive airways pressure (IPAP) of 10cm water and expiratory positive airways pressure (EPAP) of 4cm water at 60% flow rate of oxygen
- Inspiratory positive airways pressure (IPAP) of 10cm water and expiratory positive airways pressure (EPAP) of 4cm water at 20% flow rate of oxygen
- Inspiratory positive airways pressure (IPAP) of 10cm water and expiratory positive airways pressure (EPAP) of 4cm water at 40% flow rate of oxygen
- Inspiratory positive airways pressure (IPAP) of 10cm water and expiratory positive airways pressure (EPAP) of 6cm water at 40% flow rate of oxygen
- Inspiratory positive airways pressure (IPAP) of 4cm water and expiratory positive airways pressure (EPAP) of 10cm water at 40% flow rate of oxygen

Submit answer

Reference ranges

Score: **16%**

1 ✗
2 ✗
3 ✗
4 ✗
5 ✗
6 ✗
7 ✗
8 ✗
9 ✗
10 ✗
11 ✗
12 ✓
13 ✗
14 ✗
15 ✗
16 ✗
17 ✗
18 ✗
19 ✗
20 ✗
21 ✗
22 ✗
23 ✓
24 ✗
25 ✗
26 ✗
27 ✗
28 ✗
29 ✓
30 ✗
31 ✓
32 ✗
33 ✗
34 ✗
35 ✗

36	✓
37	✓
38	✗
39	✗
40	✗
41	✓
42	✗
43	✗
44	✗
45	✗
46	✗
47	✗
48	✗
49	✓
50	✗
51	-
52	-
53	-
54	-
55	-
56	-
57	-
58	-
59	-
60	-
61	-
62	-
63	-
64	-
65	-
66	-
67	-
68	-
69	-
70	-
71	-
72	-
73	-

74 -
75 -
76 -
77 -
78 -
79 -
80 -
81 -
82 -
83 -
84 -
85 -
86 -
87 -
88 -
89 -
90 -
91 -

All contents of this site are © 2024 Passmedicine Limited
Back to top

A 91-year-old man is admitted into hospital with a severe exacerbation of his COPD. He is breathless on rest and although alert and orientated, is starting to become drowsy. His observation reveal a temperature of 37.9ºC, a heart rate of 82 beats per minute, blood pressure of 116/74 mmHg, respiratory rate of 28 breaths per minute and oxygen saturations of 84% on a 28% Venturi mask.

An arterial blood gas is performed and reveals a PaO2 of 9.0 kPa, PCO2 of 11.4kPa, HCO3 of 31 mmol/l and a pH of 7.29.

A decision is made to commence the man on non-invasive ventilation - which of the following is the most appropriate management for this patient?

- Inspiratory positive airways pressure (IPAP) of 10cm water and expiratory positive airways pressure (EPAP) of 4cm water at 60% flow rate of oxygen — 12%
- Inspiratory positive airways pressure (IPAP) of 10cm water and expiratory positive airways pressure (EPAP) of 4cm water at 20% flow rate of oxygen — 19%
- Inspiratory positive airways pressure (IPAP) of 10cm water and expiratory positive airways pressure (EPAP) of 4cm water at 40% flow rate of oxygen — 58%
- Inspiratory positive airways pressure (IPAP) of 10cm water and expiratory positive airways pressure (EPAP) of 6cm water at 40% flow rate of oxygen — 7%
- Inspiratory positive airways pressure (IPAP) of 4cm water and expiratory positive airways pressure (EPAP) of 10cm water at 40% flow rate of oxygen — 4%

The British Thoracic Guidelines state that oxygen saturations of 90-92%, with an initial non-invasive ventilation setting of Inspiratory positive airways pressure (IPAP) of 10cm water and expiratory positive airways pressure (EPAP) of 4cm water. To assess the effect of the treatment, an arterial blood gas should be taken an hour after the non-invasive ventilation is set up.

Discuss (11) | Improve

Next question

Non-invasive ventilation

The British Thoracic Society (BTS) published guidelines in 2002 on the use of non-invasive ventilation in acute respiratory failure. Following these the Royal College of Physicians published guidelines in 2008.

Non-invasive ventilation - key indications

- COPD with respiratory acidosis pH 7.25-7.35
    - the BTS guidelines state that NIV can be used in patients who are more acidotic (i.e. pH < 7.25) but that a greater degree of monitoring is required (e.g. HDU) and a lower threshold for intubation and ventilation should be used
- type II respiratory failure secondary to chest wall deformity, neuromuscular disease or obstructive sleep apnoea
- cardiogenic pulmonary oedema unresponsive to CPAP
- weaning from tracheal intubation

Recommended initial settings for bi-level pressure support in COPD

- Expiratory Positive Airway Pressure (EPAP): 4-5 cm H2O
- Inspiratory Positive Airway Pressure (IPAP): RCP advocate 10 cm H20 whilst BTS suggest 12-15 cm H2O
- back up rate: 15 breaths/min
- back up inspiration:expiration ratio: 1:3

+ Q 123

Next question >

Textbooks

High-yield textbook

Extended textbook

Links

British Thoracic Society 12 4

2016 BTS/ICS Guidelines for the Ventilatory Management of Acute Hypercapnic Respiratory Failure in Adults

Suggest link Report broken link

Media

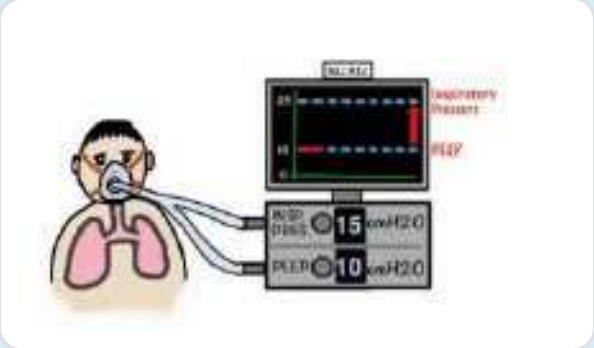

CPAP and Non-Invasive Ventilation in 5 minutes

Nick Smith - YouTube 31 2

Clinical Skills: BiPAP and CPAP

Osmosis - YouTube 3 7

Report broken media

Score: **17.3%**

1 ✗
2 ✗
3 ✗
4 ✗
5 ✗
6 ✗
7 ✗
8 ✗
9 ✗

10	✗
11	✗
12	✓
13	✗
14	✗
15	✗
16	✗
17	✗
18	✗
19	✗
20	✗
21	✗
22	✗
23	✓
24	✗
25	✗
26	✗
27	✗
28	✗
29	✓
30	✗
31	✓
32	✗
33	✗
34	✗
35	✗
36	✓
37	✓
38	✗
39	✗
40	✗
41	✓
42	✗
43	✗
44	✗
45	✗

46 ✗
47 ✗
48 ✗
49 ✓
50 ✗
51 ✗
52 ✓
53 ✗
54 ✗
55 ✓
56 ✗
57 ✗
58 ✓
59 ✗
60 ✓
61 ✗
62 ✗
63 ✗
64 ✗
65 ✗
66 ✗
67 ✗
68 ✗
69 ✗
70 ✗
71 ✗
72 ✗
73 ✗
74 ✗
75 ✓
76 ✗
77 ✗
78 ✗
79 ✓
80 ✗
81 ✗

82	✓
83	✗
84	✗
85	✗
86	✗
87	✗
88	✗
89	✗
90	✗
91	✗
92	✗
93	✓
94	✗
95	✓
96	✗
97	✗
98	✗
99	✗
100	✗
101	✗
102	✗
103	✓
104	✗
105	✗
106	✓
107	✗
108	✗
109	✗
110	✗
111	-

All contents of this site are © 2024 Passmedicine Limited

Back to top

A 24 year-old student was referred to the Acute Medical Unit by his general practitioner with a 4-week history of increasing cough and breathlessness. The cough was generally non-productive but he had coughed up a small amount of blood on 3 occasions. His past medical history consisted only of asthma which was well controlled with a salbutamol inhaler. There was no family history of venous thromboembolism. His recent travel history included a trip to Sierra Leone 3 months ago. He was a non-smoker and drank 20 units of alcohol per week.

On examination, his temperature was 37.6oC, heart rate 80 beats per minute, blood pressure 124/88 mmHg, respiratory rate 22 breaths per minute and oxygen saturations 92% on room air. He was able to talk in full sentences. A few bibasal crackles were evident on auscultation of the chest. His JVP was not elevated and heart sounds were normal.

Investigations:

Haemoglobin	144 g/L (130-180)
White cell count	7.0 * 10^9/l
Neutrophil count	3.5 * 10^9/l
Lymphocyte count	1.6 * 10^9/l
Eosinophil count	1.3* 10^9/l
Platelets	330 * 10^9/l

Sodium	138 mmol/L
Potassium	3.9 mmol/L
Urea	7.0 mmol/L
Creatinine	65 mol/L
Alkaline phosphatase	40 IU/L
Alanine aminotransferase	33 IU/L
Gamma-glutyl transferase	18 IU/L
Bilirubin	14 mol/L
Albumin	40 g/L

Chest x-ray: Bilateral lower zone haziness
ECG: Normal sinus rhythm

What is the most appropriate treatment for the underlying condition?

- ○ Mebendazole ×
- ○ Low molecular weight heparin ×
- ○ Fluconazole ×
- ○ Doxycycline ×
- ○ Artesunate ×

Submit answer

Reference ranges

Score: **16%**

1	✗
2	✗
3	✗
4	✗
5	✗
6	✗
7	✗
8	✗
9	✗
10	✗
11	✗
12	✓
13	✗
14	✗
15	✗
16	✗

17	✗
18	✗
19	✗
20	✗
21	✗
22	✗
23	✓
24	✗
25	✗
26	✗
27	✗
28	✗
29	✓
30	✗
31	✓
32	✗
33	✗
34	✗
35	✗
36	✓
37	✓
38	✗
39	✗
40	✗
41	✓
42	✗
43	✗
44	✗
45	✗
46	✗
47	✗
48	✗
49	✓
50	✗
51	-
52	-

```
-
-
-
-
-
-
-
-
-
-
-
-
-
-
-
-
-
-
-
-
-
-
-
-
-
-
-
-
-
-
-
-
-
-
-
-
-
-
-
-
```

All contents of this site are © 2024 Passmedicine Limited

A 24 year-old student was referred to the Acute Medical Unit by his general practitioner with a 4-week history of increasing cough and breathlessness. The cough was generally non-productive but he had coughed up a small amount of blood on 3 occasions. His past medical history consisted only of asthma which was well controlled with a salbutamol inhaler. There was no family history of venous thromboembolism. His recent travel history included a trip to Sierra Leone 3 months ago. He was a non-smoker and drank 20 units of alcohol per week.

On examination, his temperature was 37.6oC, heart rate 80 beats per minute, blood pressure 124/88 mmHg, respiratory rate 22 breaths per minute and oxygen saturations 92% on room air. He was able to talk in full sentences. A few bibasal crackles were evident on auscultation of the chest. His JVP was not elevated and heart sounds were normal.

Investigations:

Haemoglobin	144 g/L (130-180)
White cell count	7.0 * 10^9/l
Neutrophil count	3.5 * 10^9/l
Lymphocyte count	1.6 * 10^9/l
Eosinophil count	1.3* 10^9/l
Platelets	330 * 10^9/l

Sodium	138 mmol/L
Potassium	3.9 mmol/L
Urea	7.0 mmol/L
Creatinine	65 mol/L
Alkaline phosphatase	40 IU/L
Alanine aminotransferase	33 IU/L
Gamma-glutyl transferase	18 IU/L
Bilirubin	14 mol/L
Albumin	40 g/L

Chest x-ray: Bilateral lower zone haziness
ECG: Normal sinus rhythm

What is the most appropriate treatment for the underlying condition?

- Mebendazole 54%
- Low molecular weight heparin 3%
- Fluconazole 20%
- Doxycycline 18%
- Artesunate 5%

This patient has presented with features of eosinophilic pneumonia secondary to parasite infection, also known as Loefflers syndrome. The most likely causative organism in this case is the roundworm *Ascaris lumbricoides*, which can cause Loefflers syndrome during the pulmonary migration phase of its life cycle. The clinical features and eosinophilia could also point to idiopathic pulmonary eosinophilia or allergic bronchopulmonary aspergillosis, but the treatment for both of these (corticosteroids) is not listed as a potential answer. The chest x-ray findings and normal ECG make pulmonary embolism a less likely diagnosis.

Discuss (6) Improve

Next question

Pulmonary eosinophilia

Pulmonary eosinophilia describes a situation where there are increased numbers of eosinophils in the lung airways and parenchyma. This is generally associated with a blood eosinophilia.

Causes of pulmonary eosinophilia
- Churg-Strauss syndrome
- allergic bronchopulmonary aspergillosis (ABPA)
- Loffler's syndrome
- eosinophilic pneumonia
- hypereosinophilic syndrome
- tropical pulmonary eosinophilia
- drugs: nitrofurantoin, sulphonamides
- less common: Wegener's granulomatosis

Loffler's syndrome

- transient CXR shadowing and blood eosinophilia
- thought to be due to parasites such as *Ascaris lumbricoides* causing an alveolar reaction
- presents with a fever, cough and night sweats which often last for less than 2 weeks.
- generally a self-limiting disease

Acute eosinophilic pneumonia

- highly responsive to steroids

Tropical pulmonary eosinophilia

- associated with *Wuchereria bancrofti* infection

AI + Q 123

Next question >

Textbooks

High-yield textbook

Extended textbook

Score: **17.3%**

1 ✗
2 ✗
3 ✗
4 ✗

5	✗
6	✗
7	✗
8	✗
9	✗
10	✗
11	✗
12	✓
13	✗
14	✗
15	✗
16	✗
17	✗
18	✗
19	✗
20	✗
21	✗
22	✗
23	✓
24	✗
25	✗
26	✗
27	✗
28	✗
29	✓
30	✗
31	✓
32	✗
33	✗
34	✗
35	✗
36	✓
37	✓
38	✗
39	✗
40	✗

41	✓
42	✗
43	✗
44	✗
45	✗
46	✗
47	✗
48	✗
49	✓
50	✗
51	✗
52	✓
53	✗
54	✗
55	✓
56	✗
57	✗
58	✓
59	✗
60	✓
61	✗
62	✗
63	✗
64	✗
65	✗
66	✗
67	✗
68	✗
69	✗
70	✗
71	✗
72	✗
73	✗
74	✗
75	✓
76	✗

77	✗
78	✗
79	✓
80	✗
81	✗
82	✓
83	✗
84	✗
85	✗
86	✗
87	✗
88	✗
89	✗
90	✗
91	✗
92	✗
93	✓
94	✗
95	✓
96	✗
97	✗
98	✗
99	✗
100	✗
101	✗
102	✗
103	✓
104	✗
105	✗
106	✓
107	✗
108	✗
109	✗
110	✗
111	-

All contents of this site are © 2024 Passmedicine Limited

A 63-year-old man has a check chest x-ray 6 weeks after being treated for community-acquired pneumonia. He reports feeling much better in himself from a chest point of view. However, he has noticed his face has been getting rounder and he has put on weight, particularly in his abdominal region. He has also noticed purplish stripes on his abdomen which has alarmed him.

He has recently been diagnosed with hypertension and reports his GP told him he was borderline diabetic. His medications at present are ramipril. He drinks 4-6 units of alcohol per week, has a 40 pack-year smoking history and is a retired salesman.

Initial chest x-ray	Bibasal patch opacification in keeping with pneumonia. Clinical correlation advised.
Check chest x-ray	Compared to the previous x-ray, the consolidation has resolved. However, there is a right hilar mass suspicious for malignancy. Further investigation advised.

The patient has been informed of his chest x-ray results and understands that he will be referred urgently to the lung cancer clinic.

Given the presentation, what type of lung cancer is the patient likely to have?

- Metastatic deposits
- Mesothelioma
- Adenocarcinoma of the lung
- Squamous cell lung cancer
- Small cell lung cancer

Submit answer

Reference ranges

Score: **16%**

1	✗
2	✗
3	✗
4	✗
5	✗
6	✗
7	✗
8	✗
9	✗
10	✗
11	✗
12	✓
13	✗
14	✗
15	✗
16	✗
17	✗
18	✗
19	✗
20	✗
21	✗
22	✗
23	✓
24	✗
25	✗
26	✗
27	✗
28	✗
29	✓
30	✗
31	✓
32	✗
33	✗
34	✗

35	✗
36	✓
37	✓
38	✗
39	✗
40	✗
41	✓
42	✗
43	✗
44	✗
45	✗
46	✗
47	✗
48	✗
49	✓
50	✗
51	-
52	-
53	-
54	-
55	-
56	-
57	-
58	-
59	-
60	-
61	-
62	-
63	-
64	-
65	-
66	-
67	-
68	-
69	-
70	-
71	-
72	-

73	-
74	-
75	-
76	-
77	-
78	-
79	-
80	-
81	-
82	-
83	-
84	-
85	-
86	-
87	-
88	-
89	-
90	-
91	-
92	-
93	-

All contents of this site are © 2024 Passmedicine Limited
Back to top

A 63-year-old man has a check chest x-ray 6 weeks after being treated for community-acquired pneumonia. He reports feeling much better in himself from a chest point of view. However, he has noticed his face has been getting rounder and he has put on weight, particularly in his abdominal region. He has also noticed purplish stripes on his abdomen which has alarmed him.

He has recently been diagnosed with hypertension and reports his GP told him he was borderline diabetic. His medications at present are ramipril. He drinks 4-6 units of alcohol per week, has a 40 pack-year smoking history and is a retired salesman.

Initial chest x-ray	Bibasal patch opacification in keeping with pneumonia. Clinical correlation advised.
Check chest x-ray	Compared to the previous x-ray, the consolidation has resolved. However, there is a right hilar mass suspicious for malignancy. Further investigation advised.

The patient has been informed of his chest x-ray results and understands that he will be referred urgently to the lung cancer clinic.

Given the presentation, what type of lung cancer is the patient likely to have?

- Metastatic deposits 1%
- Mesothelioma 1%
- Adenocarcinoma of the lung 7%
- Squamous cell lung cancer 13%
- Small cell lung cancer 79%

Small cell lung carcinoma secreting ACTH can cause Cushing's syndrome

Important for me Less important

This man has a significant smoking history and the repeat chest x-ray has revealed a suspicious mass, highlighting the importance of getting a follow-up x-ray for patients 6 weeks after community-acquired pneumonia (to check for resolution and any evidence of underlying lesions).

The central adipose deposition, 'moon face', new hypertension and impaired glucose tolerance are all in keeping with Cushing's syndrome, This is a paraneoplastic phenomenon seen in small cell lung cancer due to the tumour secreting ACTH.

If these were metastatic deposits, the chest x-ray would show multiple lesions rather than a solitary hilar mass.

Mesothelioma is a cancer of the pleura due to asbestos exposure. There is nothing in the vignette to suggest asbestos exposure. In questions where asbestosis exposure may be relevant, the occupation of the patient is usually that of a plumber or builder.

Adenocarcinoma of the lung is associated with gynaecomastia.

Squamous cell lung cancers can secrete parathyroid hormone-related peptide which causes hypercalcaemia.

Discuss | Improve

Next question

Lung cancer: paraneoplastic features

Small cell
- ADH
- ACTH - not typical, hypertension, hyperglycaemia, hypokalaemia, alkalosis and muscle weakness are more common than buffalo hump etc
- Lambert-Eaton syndrome

Squamous cell
- parathyroid hormone-related protein (PTH-rp) secretion causing hypercalcaemia
- clubbing
- hypertrophic pulmonary osteoarthropathy (HPOA)
- hyperthyroidism due to ectopic TSH

Adenocarcinoma
- gynaecomastia
- hypertrophic pulmonary osteoarthropathy (HPOA)

© Image used on license from Radiopaedia

Hypertrophic pulmonary osteoarthropathy is a proliferative periostisis involving that typically involves the long bones. It is often painful.

*whilst it is traditionally taught that HPOA is most common with squamous cell carcinoma some studies indicate that adenocarcinoma is the most common cause e.g. https://www.ncbi.nlm.nih.gov/pmc/articles/PMC4049689/

AI + Q 123

Next question >

Textbooks

High-yield textbook

Extended textbook

Links

Mayo Clinic 👍 8 👎 8

[Paraneoplastic Syndromes: An Approach to Diagnosis and Treatment]

Suggest link

Report broken link

Media

Lung cancer

MedFlix - YouTube 👍 6 👎 0

Lung Cancer: An Overview

Oncology for Medical Students - YouTube 👍 3 👎 0

Hypercalcemia in malignancy

Armando Hasudungan - YouTube 👍 3 👎 1

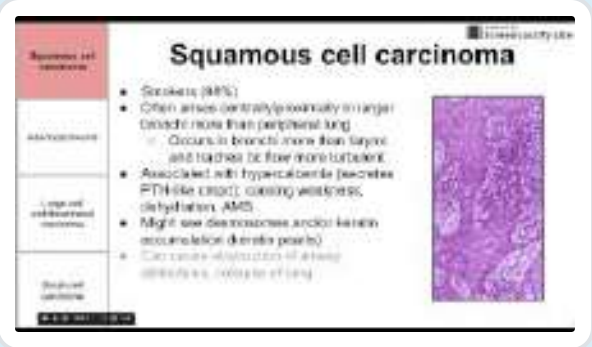

Cancers of the lung

MedLecturesMadeEasy - YouTube 2 2

Report broken media

Score: **17.3%**

1	✗
2	✗
3	✗
4	✗
5	✗
6	✗
7	✗
8	✗
9	✗
10	✗
11	✗
12	✓
13	✗
14	✗
15	✗
16	✗
17	✗
18	✗
19	✗
20	✗
21	✗
22	✗
23	✓
24	✗
25	✗
26	✗
27	✗

28	✗
29	✓
30	✗
31	✓
32	✗
33	✗
34	✗
35	✗
36	✓
37	✓
38	✗
39	✗
40	✗
41	✓
42	✗
43	✗
44	✗
45	✗
46	✗
47	✗
48	✗
49	✓
50	✗
51	✗
52	✓
53	✗
54	✗
55	✓
56	✗
57	✗
58	✓
59	✗
60	✓
61	✗
62	✗
63	✗

64	✗
65	✗
66	✗
67	✗
68	✗
69	✗
70	✗
71	✗
72	✗
73	✗
74	✗
75	✓
76	✗
77	✗
78	✗
79	✓
80	✗
81	✗
82	✓
83	✗
84	✗
85	✗
86	✗
87	✗
88	✗
89	✗
90	✗
91	✗
92	✗
93	✓
94	✗
95	✓
96	✗
97	✗
98	✗
99	✗

100	✗
101	✗
102	✗
103	✓
104	✗
105	✗
106	✓
107	✗
108	✗
109	✗
110	✗
111	-

All contents of this site are © 2024 Passmedicine Limited

Back to top

A 58-year-old gentleman presents with shortness of breath and haemoptysis which has worsened over ten days. He is currently coughing up an estimated 200ml of fresh red blood every day. He has night sweats and feels cold and sweaty at times. He has not lost any weight and was well prior to this.

He has mild COPD and takes fostair twice a day with no exacerbations in the past 5 years. He moved to the UK 15 years ago but lived 10 years in Louisiana as a mining operator extracting minerals with exposure to bats and birds during this time. He drinks 10 units of alcohol a week and was born in Syria where he received a BCG vaccine as a child. He has not been around any ill contacts and lives with his wife and two children. There is no recent foreign travel and he keeps no pets.

On examination, he has crepitations in the right side mid and upper zones. He has palpable lymph nodes in his axillae and neck but his abdomen is non tender with no hepatosplenomegaly. He is breathing rapidly and appears cachectic. His observations show temperature 38.3ºC, respiratory rate 28/min, heart rate 98/min, saturations 88% in air. An arterial blood gas has not been done.

Hb	110 g/l	Na^+	139 mmol/l
Platelets	450 * 10^9/l	K^+	3.4 mmol/l
WBC	13 * 10^9/l	Urea	4.1 mmol/l
Neuts	9.8 * 10^9/l	Creatinine	78 µmol/l
Lymphs	0.78 * 10^9/l	CRP	130 mg/l
Eosin	0.1 * 10^9/l		
HIV serology	negative		

Sputum culture	no acid fast bacilli or other growth seen
Chest x-ray	bilateral hilar lymphadenopathy with patchy right upper zone consolidation
Beta-D-glucan	strongly positive

What is the likely diagnosis?

- Aspergillosis
- Tuberculosis

- Histoplasmosis ×
- *Pneumocystis jirovecii* ×
- Lung carcinoma ×

Submit answer

Reference ranges

Score: **16%**

1	✗
2	✗
3	✗
4	✗
5	✗
6	✗
7	✗
8	✗
9	✗
10	✗
11	✗
12	✓
13	✗
14	✗
15	✗
16	✗
17	✗
18	✗
19	✗
20	✗
21	✗

22	✗
23	✓
24	✗
25	✗
26	✗
27	✗
28	✗
29	✓
30	✗
31	✓
32	✗
33	✗
34	✗
35	✗
36	✓
37	✓
38	✗
39	✗
40	✗
41	✓
42	✗
43	✗
44	✗
45	✗
46	✗
47	✗
48	✗
49	✓
50	✗
51	-
52	-
53	-
54	-
55	-
56	-
57	-
58	-

59 -
60 -
61 -
62 -
63 -
64 -
65 -
66 -
67 -
68 -
69 -
70 -
71 -
72 -
73 -
74 -
75 -
76 -
77 -
78 -
79 -
80 -
81 -
82 -
83 -
84 -
85 -
86 -
87 -
88 -
89 -
90 -
91 -
92 -
93 -
94 -

All contents of this site are © 2024 Passmedicine Limited
Back to top

A 58-year-old gentleman presents with shortness of breath and haemoptysis which has worsened over ten days. He is currently coughing up an estimated 200ml of fresh red blood every day. He has night sweats and feels cold and sweaty at times. He has not lost any weight and was well prior to this.

He has mild COPD and takes fostair twice a day with no exacerbations in the past 5 years. He moved to the UK 15 years ago but lived 10 years in Louisiana as a mining operator extracting minerals with exposure to bats and birds during this time. He drinks 10 units of alcohol a week and was born in Syria where he received a BCG vaccine as a child. He has not been around any ill contacts and lives with his wife and two children. There is no recent foreign travel and he keeps no pets.

On examination, he has crepitations in the right side mid and upper zones. He has palpable lymph nodes in his axillae and neck but his abdomen is non tender with no hepatosplenomegaly. He is breathing rapidly and appears cachectic. His observations show temperature 38.3ºC, respiratory rate 28/min, heart rate 98/min, saturations 88% in air. An arterial blood gas has not been done.

Hb	110 g/l	Na^+	139 mmol/l
Platelets	450 * 10^9/l	K^+	3.4 mmol/l
WBC	13 * 10^9/l	Urea	4.1 mmol/l
Neuts	9.8 * 10^9/l	Creatinine	78 µmol/l
Lymphs	0.78 * 10^9/l	CRP	130 mg/l
Eosin	0.1 * 10^9/l		
HIV serology	negative		

Sputum culture	no acid fast bacilli or other growth seen
Chest x-ray	bilateral hilar lymphadenopathy with patchy right upper zone consolidation
Beta-D-glucan	strongly positive

What is the likely diagnosis?

- Aspergillosis 40%
- Tuberculosis 5%

Histoplasmosis 45%

Pneumocystis jirovecii 7%

Lung carcinoma 3%

Histoplasmosis can affect the lung and present with acute respiratory failure

Important for me Less important

This gentleman has an acute history of respiratory failure with deterioration. All the causes above are possible but he is not HIV positive so *pneumocystis* is unlikely. This presentation is very acute for lung carcinoma. He has been vaccinated against tuberculosis.

The raised Beta-D-glucan suggests a fungal cause of infection. Given his previous exposure to bats and their droppings in the Mississippi area, he is likely to have developed invasive histoplasmosis which is known to present many years after initial exposure to the fungus.

Discuss (11) Improve

Next question

Histoplasmosis

Histoplasmosis is due to the fungus *Histoplasma capsulatum*. It is most commonly encountered in the Mississippi and Ohio River valleys.

Features

- URTI symptoms
- retrosternal pain

Management

- amphotericin or itraconazole are the pharmacological agents of choice for histoplasmosis

123

Next question

Textbooks

High-yield textbook

Extended textbook

Score: **17.3%**

1	✗
2	✗
3	✗
4	✗
5	✗
6	✗
7	✗
8	✗
9	✗
10	✗
11	✗
12	✓
13	✗
14	✗
15	✗
16	✗
17	✗
18	✗
19	✗

20	✗
21	✗
22	✗
23	✓
24	✗
25	✗
26	✗
27	✗
28	✗
29	✓
30	✗
31	✓
32	✗
33	✗
34	✗
35	✗
36	✓
37	✓
38	✗
39	✗
40	✗
41	✓
42	✗
43	✗
44	✗
45	✗
46	✗
47	✗
48	✗
49	✓
50	✗
51	✗
52	✓
53	✗
54	✗
55	✓

56	✗
57	✗
58	✓
59	✗
60	✓
61	✗
62	✗
63	✗
64	✗
65	✗
66	✗
67	✗
68	✗
69	✗
70	✗
71	✗
72	✗
73	✗
74	✗
75	✓
76	✗
77	✗
78	✗
79	✓
80	✗
81	✗
82	✓
83	✗
84	✗
85	✗
86	✗
87	✗
88	✗
89	✗
90	✗
91	✗

92 ✗
93 ✓
94 ✗
95 ✓
96 ✗
97 ✗
98 ✗
99 ✗
100 ✗
101 ✗
102 ✗
103 ✓
104 ✗
105 ✗
106 ✓
107 ✗
108 ✗
109 ✗
110 ✗
111 -

All contents of this site are © 2024 Passmedicine Limited

Back to top

An 18-year-old male is referred to the medical assessment unit by the emergency department.

He presents with a 3-day history of a cough productive of green sputum, haemoptysis, subjective fevers, exertional dyspnea and right-sided pleuritic chest pain. This is the third presentation in 12 months. The first time he presented to his general practitioner and his symptoms improved with a course of oral amoxicillin. The second presentation was a few months ago where he required inpatient management with intravenous antibiotics. He failed to attend follow up as he became busy with his studies. Over the last 12 months, he has also noticed increasing lethargy and weight loss. He denies any other past medical or surgical history. He admits to smoking when he goes out with his friends at the weekends and to binge drinking at the weekends. There is no history of intravenous or other illicit drug use.

He was born in Nigeria and has been living in the United Kingdom for the last 12 months. He is studying for his undergraduate degree in mathematics and also works part-time in a restaurant.

On examination, observations revealed a respiratory rate of 19/min, oxygen saturation 94% on air, heart rate 110/min, blood pressure 100/60 mmHg and a temperature of 38ºC. Examination of the respiratory system revealed no clubbing or cervical lymphadenopathy. There were reduced breath sounds and dullness to percussion at the right base. Cardiovascular examination was normal. Calves were soft and non-tender, with no pedal oedema.

Hb	140 g/l	Na^+	136 mmol/l
Platelets	400 * 10^9/l	K^+	4 mmol/l
WBC	12 * 10^9/l	Urea	6 mmol/l
Neuts	11 * 10^9/l	Creatinine	70 µmol/l
Lymphs	1 * 10^9/l	CRP	30 mg/l

Chest x-ray showed an elevated right hemidiaphragm, depressed right hilum and obliteration of the right costophrenic angle.

Computed tomography (CT) of the thorax is obtained. This shows a small right pleural effusion, right lower lobe collapse and a smooth round mass in the proximal right main bronchus, partially obscuring its lumen, which had marked post-contrast enhancement. There was no hilar or mediastinal lymphadenopathy.

Three early morning sputum samples are sent which are negative for acid-fast bacilli. Mycobacterial culture is awaited. No malignant cells were seen on sputum cytology.

Bronchoscopy is performed and biopsy of the mass is obtained.

What is the most likely histological diagnosis?

- Adenocarcinoma
- Squamous cell carcinoma
- Small cell carcinoma
- Large cell carcinoma
- Carcinoid tumour

Submit answer

Reference ranges

Score: **16%**

1	✗
2	✗
3	✗
4	✗
5	✗
6	✗
7	✗
8	✗
9	✗
10	✗
11	✗
12	✓
13	✗
14	✗

15	✗
16	✗
17	✗
18	✗
19	✗
20	✗
21	✗
22	✗
23	✓
24	✗
25	✗
26	✗
27	✗
28	✗
29	✓
30	✗
31	✓
32	✗
33	✗
34	✗
35	✗
36	✓
37	✓
38	✗
39	✗
40	✗
41	✓
42	✗
43	✗
44	✗
45	✗
46	✗
47	✗
48	✗
49	✓
50	✗

```
-
-
-
-
-
-
-
-
-
-
-
-
-
-
-
-
-
-
-
-
-
-
-
-
-
-
-
-
-
-
-
-
-
-
-
-
-
-
-
-
```

91 -
92 -
93 -
94 -
95 -

All contents of this site are © 2024 Passmedicine Limited

An 18-year-old male is referred to the medical assessment unit by the emergency department.

He presents with a 3-day history of a cough productive of green sputum, haemoptysis, subjective fevers, exertional dyspnea and right-sided pleuritic chest pain. This is the third presentation in 12 months. The first time he presented to his general practitioner and his symptoms improved with a course of oral amoxicillin. The second presentation was a few months ago where he required inpatient management with intravenous antibiotics. He failed to attend follow up as he became busy with his studies. Over the last 12 months, he has also noticed increasing lethargy and weight loss. He denies any other past medical or surgical history. He admits to smoking when he goes out with his friends at the weekends and to binge drinking at the weekends. There is no history of intravenous or other illicit drug use.

He was born in Nigeria and has been living in the United Kingdom for the last 12 months. He is studying for his undergraduate degree in mathematics and also works part-time in a restaurant.

On examination, observations revealed a respiratory rate of 19/min, oxygen saturation 94% on air, heart rate 110/min, blood pressure 100/60 mmHg and a temperature of 38ºC. Examination of the respiratory system revealed no clubbing or cervical lymphadenopathy. There were reduced breath sounds and dullness to percussion at the right base. Cardiovascular examination was normal. Calves were soft and non-tender, with no pedal oedema.

Hb	140 g/l	Na^+	136 mmol/l
Platelets	400 * 10^9/l	K^+	4 mmol/l
WBC	12 * 10^9/l	Urea	6 mmol/l
Neuts	11 * 10^9/l	Creatinine	70 µmol/l
Lymphs	1 * 10^9/l	CRP	30 mg/l

Chest x-ray showed an elevated right hemidiaphragm, depressed right hilum and obliteration of the right costophrenic angle.

Computed tomography (CT) of the thorax is obtained. This shows a small right pleural effusion, right lower lobe collapse and a smooth round mass in the proximal right main bronchus, partially obscuring its lumen, which had marked post-contrast enhancement. There was no hilar or mediastinal lymphadenopathy.

Three early morning sputum samples are sent which are negative for acid-fast bacilli. Mycobacterial culture is awaited. No malignant cells were seen on sputum cytology.

Bronchoscopy is performed and biopsy of the mass is obtained.

What is the most likely histological diagnosis?

Adenocarcinoma	25%
Squamous cell carcinoma	15%
Small cell carcinoma	12%
Large cell carcinoma	7%
Carcinoid tumour	41%

Bronchial carcinoid is the most common lung cancer in adolescents and can present with recurrent pneumonia

Important for me Less important

Bronchial carcinoid is a rare form of lung cancer but is much more common in younger patients, typically presenting in late adolescence. They are typically slow growing, well-differentiated tumours, explaining the protracted history we see in this patient. The majority (approximately 75%) of bronchial carcinoid tumours arise in the proximal airways, hence why symptoms include dyspnea, wheeze, cough, haemoptysis and/or recurrent pneumonia. Patients may receive several courses of antibiotics to treat recurrent pneumonia before the tumour is diagnosed, as in this case.

Studies have shown a positive association with smoking and the development of bronchial carcinoid, but causality has not been proven as with smoking and more common types of lung cancer.

Cavitation is rare. Pleural effusion is also uncommon but may be seen as a complication of pneumonia caused by the obstruction from the tumour. The chest x-ray description, in this case, is consistent with right lower lobe collapse and a right pleural effusion.

Only 5-20 per cent of typical low-grade lung neuroendocrine tumours (NETs) are associated with hilar or mediastinal adenopathy. Another clue in this case to carcinoid is that contrast-enhanced CT scans frequently show marked enhancement due to the vascular nature of the tumours.

Lung NETs tend to produce lower quantities of serotonin compared to intestinal NETs, which explains why lung NETs have lower rates of carcinoid syndrome, which is characterized by flushing, diarrhoea, bronchospasm and can reflect metastases to the liver.

Option 1-4 - unlikely given the patient's age, relatively light smoking history and absence of lymphadenopathy. Central carcinomas are more likely to provide positive sputum cytology for malignant cells, whereas that is not the case with central bronchial carcinoid due to an intact bronchial mucosa usually overlying NETs.

Option 5 - the correct answer

Discuss (5) | Improve

Next question >

Lung cancer: features

Features

- persistent cough
- haemoptysis
- dyspnoea
- chest pain
- weight loss and anorexia
- hoarseness
    - seen with Pancoast tumours pressing on the recurrent laryngeal nerve
- superior vena cava syndrome

Examination findings

- a fixed, monophonic wheeze may be noted
- supraclavicular lymphadenopathy or persistent cervical lymphadenopathy
- clubbing

Paraneoplastic features:

Small cell	Squamous cell	Adenocarcinoma
• ADH • ACTH - not typical, hypertension, hyperglycaemia, hypokalaemia, alkalosis and muscle weakness are more common than buffalo hump etc • Lambert-Eaton syndrome	• parathyroid hormone-related protein (PTH-rp) secretion causing hypercalcaemia • clubbing • hypertrophic pulmonary osteoarthropathy (HPOA) • hyperthyroidism due to ectopic TSH	• gynaecomastia • hypertrophic pulmonary osteoarthropathy (HPOA)

Complications

- hoarseness
- stridor

A thrombocytosis may be noted on bloods.

+ Q 123

Next question >

Textbooks

High-yield textbook

Extended textbook

Media

[Lung cancer]

MedFlix - YouTube 3 0

[Lung Cancer: An Overview]

Oncology for Medical Students - YouTube 1 0

[Lung cancer]

Osmosis - YouTube 1 0

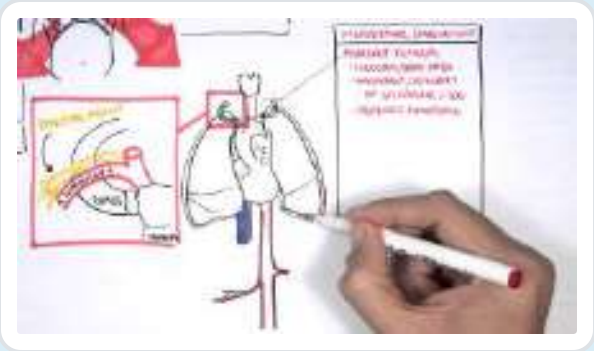

[Lung cancer]

Armando Hasudungan - YouTube 0 0

Report broken media

Score: **17.3%**

1 ✗
2 ✗
3 ✗
4 ✗

5	✗
6	✗
7	✗
8	✗
9	✗
10	✗
11	✗
12	✓
13	✗
14	✗
15	✗
16	✗
17	✗
18	✗
19	✗
20	✗
21	✗
22	✗
23	✓
24	✗
25	✗
26	✗
27	✗
28	✗
29	✓
30	✗
31	✓
32	✗
33	✗
34	✗
35	✗
36	✓
37	✓
38	✗
39	✗
40	✗

41	✓
42	✗
43	✗
44	✗
45	✗
46	✗
47	✗
48	✗
49	✓
50	✗
51	✗
52	✓
53	✗
54	✗
55	✓
56	✗
57	✗
58	✓
59	✗
60	✓
61	✗
62	✗
63	✗
64	✗
65	✗
66	✗
67	✗
68	✗
69	✗
70	✗
71	✗
72	✗
73	✗
74	✗
75	✓
76	✗

77	✗
78	✗
79	✓
80	✗
81	✗
82	✓
83	✗
84	✗
85	✗
86	✗
87	✗
88	✗
89	✗
90	✗
91	✗
92	✗
93	✓
94	✗
95	✓
96	✗
97	✗
98	✗
99	✗
100	✗
101	✗
102	✗
103	✓
104	✗
105	✗
106	✓
107	✗
108	✗
109	✗
110	✗
111	-

All contents of this site are © 2024 Passmedicine Limited

A 60-year-old man comes to his GP complaining of cough and dyspnoea on exertion. He has had the cough for over 2 years, but it has gotten worse recently along with increasing shortness of breath. He has no haemoptysis, chest pain or leg swelling. The patient has a 60 pack-year smoking history and drinks a moderate amount of alcohol. His temperature is 37.2ºC, blood pressure is 140/80 mmHg, pulse is 80/min, and respirations are 20/min.

Chest x-ray shows prominent bronchovascular markings and mild diaphragmatic flattening. Pulmonary function test results are as follows:

Forced expiratory volume in 1 second	67% of predicted
Forced vital capacity	95% of predicted
FEV1/FVC ratio	0.65

Carbon monoxide diffusion capacity is 100% of predicted value.

Which of the following is the most likely cause of this patients symptoms?

- Asbestosis
- Chronic bronchitis
- Panacinar emphysema
- Pulmonary fibrosis
- Rheumatoid lung

Submit answer

Reference ranges

Score: **16%**

1	✗
2	✗
3	✗
4	✗
5	✗
6	✗
7	✗
8	✗
9	✗
10	✗
11	✗
12	✓
13	✗
14	✗
15	✗
16	✗
17	✗
18	✗
19	✗
20	✗
21	✗
22	✗
23	✓
24	✗
25	✗
26	✗
27	✗
28	✗
29	✓
30	✗
31	✓
32	✗
33	✗
34	✗

35	✗
36	✓
37	✓
38	✗
39	✗
40	✗
41	✓
42	✗
43	✗
44	✗
45	✗
46	✗
47	✗
48	✗
49	✓
50	✗
51	-
52	-
53	-
54	-
55	-
56	-
57	-
58	-
59	-
60	-
61	-
62	-
63	-
64	-
65	-
66	-
67	-
68	-
69	-
70	-
71	-
72	-

73 -
74 -
75 -
76 -
77 -
78 -
79 -
80 -
81 -
82 -
83 -
84 -
85 -
86 -
87 -
88 -
89 -
90 -
91 -
92 -
93 -
94 -
95 -
96 -

All contents of this site are © 2024 Passmedicine Limited
Back to top

A 60-year-old man comes to his GP complaining of cough and dyspnoea on exertion. He has had the cough for over 2 years, but it has gotten worse recently along with increasing shortness of breath. He has no haemoptysis, chest pain or leg swelling. The patient has a 60 pack-year smoking history and drinks a moderate amount of alcohol. His temperature is 37.2ºC, blood pressure is 140/80 mmHg, pulse is 80/min, and respirations are 20/min.

Chest x-ray shows prominent bronchovascular markings and mild diaphragmatic flattening. Pulmonary function test results are as follows:

Forced expiratory volume in 1 second	67% of predicted
Forced vital capacity	95% of predicted
FEV1/FVC ratio	0.65

Carbon monoxide diffusion capacity is 100% of predicted value.

Which of the following is the most likely cause of this patients symptoms?

- Asbestosis 1%
- Chronic bronchitis 53%
- Panacinar emphysema 40%
- Pulmonary fibrosis 4%
- Rheumatoid lung 1%

The patients pulmonary function test (PFT) findings are consistent with obstructive lung disease. The carbon monoxide diffusing capacity of the lung (DLCO) measures the lungs ability to transfer gas to the blood. This patients normal DLCO indicates intact alveolar and capillary structure.

The patients chronic smoking, productive cough, dyspnoea on exertion and decreased FEV1/FVC ratio suggests COPD. COPD is a group of chronic disorders; the main subtypes being emphysema or chronic bronchitis. Patients with predominant emphysema are generally thin with severe dyspnoea, hyperinflated chest, decreased vascular markings, decreased DLCO (due to alveolar destruction) and moderate oxygen desaturation.

Patients with predominant chronic bronchitis have chronic productive cough for 3 months over 2 consecutive years not due to other causes (e.g. bronchiectasis). It usually presents with prominent bronchovascular markings, mildly flattened diaphragm and normal DLCO (as seen in this patient).

Choices 1, 4 & 5: These conditions are examples of restrictive lung diseases that cause reduced lung volumes, normal FEV1/FVC ratio, decreased FVC and low DLCO.

Choice 3: Panacinar emphysema is typical for α-1-antitrypsin deficiency; centriacinar emphysema is more characteristic for smoking-induced COPD. Panacinar emphysema usually causes a low DLCO.

Discuss (7) | Improve

Next question ›

Obstructive vs. restrictive lung diseases

	Obstructive	**Restrictive**
Spirometry	FEV1/FVC < 80%	FEV1/FVC > 80%
Examples	Chronic obstructive pulmonary disease • chronic bronchitis • emphysema: including alpha-1 antitrypsin deficiency Asthma Bronchiectasis	Intrapulmonary • idiopathic pulmonary fibrosis • extrinsic allergic alveolitis • coal worker's pneumoconiosis/progressive massive fibrosis • silicosis • sarcoidosis • histiocytosis • drug-induced fibrosis: amiodarone, bleomycin, methotrexate • asbestosis Extrapulmonary • neuromuscular disease: polio, myasthenia gravis • obesity • scoliosis

123

Next question >

Textbooks

High-yield textbook

Extended textbook

Media

Restrictive lung disease

Osmosis - YouTube 4 0

Peak Flow and Spirometry - Lung Function Tests

Oxford Medical Education - YouTube 4 0

Report broken media

Score: **17.3%**

1	✗
2	✗
3	✗
4	✗
5	✗
6	✗
7	✗
8	✗
9	✗
10	✗
11	✗
12	✓
13	✗
14	✗
15	✗
16	✗
17	✗
18	✗
19	✗
20	✗
21	✗
22	✗
23	✓
24	✗
25	✗
26	✗
27	✗
28	✗
29	✓
30	✗
31	✓
32	✗
33	✗
34	✗

35	✗
36	✓
37	✓
38	✗
39	✗
40	✗
41	✓
42	✗
43	✗
44	✗
45	✗
46	✗
47	✗
48	✗
49	✓
50	✗
51	✗
52	✓
53	✗
54	✗
55	✓
56	✗
57	✗
58	✓
59	✗
60	✓
61	✗
62	✗
63	✗
64	✗
65	✗
66	✗
67	✗
68	✗
69	✗
70	✗

71 ✗
72 ✗
73 ✗
74 ✗
75 ✓
76 ✗
77 ✗
78 ✗
79 ✓
80 ✗
81 ✗
82 ✓
83 ✗
84 ✗
85 ✗
86 ✗
87 ✗
88 ✗
89 ✗
90 ✗
91 ✗
92 ✗
93 ✓
94 ✗
95 ✓
96 ✗
97 ✗
98 ✗
99 ✗
100 ✗
101 ✗
102 ✗
103 ✓
104 ✗
105 ✗
106 ✓

107	✕
108	✕
109	✕
110	✕
111	-

All contents of this site are © 2024 Passmedicine Limited

A 58-year-old woman presents to the acute medical take with chest pain and ongoing coryzal symptoms for the last few weeks. The chest pain is retrosternal in origin, dull in character, around 3/10 intensity and does not radiate. When questioned, the patient is having a cough with white sputum and small streaks of blood, which she says has become worse over the last two weeks.

For the past two years, she has been working in the Mississippi river basin with a team of geologists. She has never smoked, does not keep any pets and has not travelled anywhere else.

On examination, she is pyrexial at 38ºC, has bibasal crepitations with increased vocal resonance and dullness to percussion at both bases.

Troponin	3 ng/L	(<14)

Chest x-ray	Airspace shadowing with consolidation involving multiple lung segments

What is the best management option?

- Co-trimoxazole
- Fluconazole
- Itraconazole
- Ivermectin
- Pentamidine

Submit answer

Reference ranges

Score: **16%**

1	✗
2	✗
3	✗
4	✗
5	✗
6	✗
7	✗
8	✗
9	✗
10	✗
11	✗
12	✓
13	✗
14	✗
15	✗
16	✗
17	✗
18	✗
19	✗
20	✗
21	✗
22	✗
23	✓
24	✗
25	✗
26	✗
27	✗
28	✗
29	✓
30	✗
31	✓
32	✗
33	✗
34	✗
35	✗

36	✓
37	✓
38	✗
39	✗
40	✗
41	✓
42	✗
43	✗
44	✗
45	✗
46	✗
47	✗
48	✗
49	✓
50	✗
51	-
52	-
53	-
54	-
55	-
56	-
57	-
58	-
59	-
60	-
61	-
62	-
63	-
64	-
65	-
66	-
67	-
68	-
69	-
70	-
71	-
72	-
73	-

74 -
75 -
76 -
77 -
78 -
79 -
80 -
81 -
82 -
83 -
84 -
85 -
86 -
87 -
88 -
89 -
90 -
91 -
92 -
93 -
94 -
95 -
96 -
97 -

All contents of this site are © 2024 Passmedicine Limited
Back to top

A 58-year-old woman presents to the acute medical take with chest pain and ongoing coryzal symptoms for the last few weeks. The chest pain is retrosternal in origin, dull in character, around 3/10 intensity and does not radiate. When questioned, the patient is having a cough with white sputum and small streaks of blood, which she says has become worse over the last two weeks.

For the past two years, she has been working in the Mississippi river basin with a team of geologists. She has never smoked, does not keep any pets and has not travelled anywhere else.

On examination, she is pyrexial at 38ºC, has bibasal crepitations with increased vocal resonance and dullness to percussion at both bases.

Troponin	3 ng/L	(<14)

Chest x-ray	Airspace shadowing with consolidation involving multiple lung segments

What is the best management option?

- Co-trimoxazole 13%
- Fluconazole 5%
- Itraconazole 58%
- Ivermectin 18%
- Pentamidine 6%

Amphotericin or itraconazole are the pharmacological agents of choice for histoplasmosis

Important for me Less important

Itraconazole is the correct answer as this is the preferred treatment for histoplasmosis. The main clue for the diagnosis of histoplasmosis is the endemic nature of the fungal spores to Mississippi with 80% of residents in this area having positive *Histoplasma* serology, but most remaining asymptomatic. This woman has chest symptoms so requires active treatment. If an individual is immunocompromised then the histoplasmosis can progress to involve the central nervous system.

Co-trimoxazole is an incorrect option as this is the first-line treatment option for *Pneumocystis carinii* pneumonia (PCP).

Pentamidine is incorrect as this is indicated for the treatment of *Pneumocystis carinii* (PCP).

Fluconazole is an incorrect option, even though this is an antifungal agent like Itraconazole, it is less effective.

Ivermectin is incorrect as this is an anti-parasitic drug, not anti-protozoal, working effectively against *Strongyloides* and severe scabies infestations.

Discuss (2) Improve

Next question

Histoplasmosis

Histoplasmosis is due to the fungus *Histoplasma capsulatum*. It is most commonly encountered in the Mississippi and Ohio River valleys.

Features
- URTI symptoms
- retrosternal pain

Management
- amphotericin or itraconazole are the pharmacological agents of choice for histoplasmosis

123

Next question

Textbooks

High-yield textbook

Extended textbook

Score: **17.3%**

1	✗
2	✗
3	✗
4	✗
5	✗
6	✗
7	✗
8	✗
9	✗
10	✗
11	✗
12	✓
13	✗
14	✗
15	✗
16	✗
17	✗
18	✗
19	✗
20	✗
21	✗
22	✗
23	✓
24	✗
25	✗

26	✗
27	✗
28	✗
29	✓
30	✗
31	✓
32	✗
33	✗
34	✗
35	✗
36	✓
37	✓
38	✗
39	✗
40	✗
41	✓
42	✗
43	✗
44	✗
45	✗
46	✗
47	✗
48	✗
49	✓
50	✗
51	✗
52	✓
53	✗
54	✗
55	✓
56	✗
57	✗
58	✓
59	✗
60	✓
61	✗

62	✗
63	✗
64	✗
65	✗
66	✗
67	✗
68	✗
69	✗
70	✗
71	✗
72	✗
73	✗
74	✗
75	✓
76	✗
77	✗
78	✗
79	✓
80	✗
81	✗
82	✓
83	✗
84	✗
85	✗
86	✗
87	✗
88	✗
89	✗
90	✗
91	✗
92	✗
93	✓
94	✗
95	✓
96	✗
97	✗

98	✗
99	✗
100	✗
101	✗
102	✗
103	✓
104	✗
105	✗
106	✓
107	✗
108	✗
109	✗
110	✗
111	-

All contents of this site are © 2024 Passmedicine Limited

A normally fit and well 32-year-old black woman complains of a fever and tiredness over the past month. Her temperature is 38.2ºC, blood pressure is 115/70 mmHg, pulse is 75/min and respirations are 18/min.

On examination there were multiple non-tender cervical and axillary lymph notes. Lung auscultation reveals fine crackles throughout bilaterally. A chest x-ray film demonstrated hilar lymphadenopathy with diffuse interstitial infiltrates. A subsequent lymph node biopsy showed non-caseating granulomas.

Which of the following is the most appropriate therapy?

- Supportive therapy
- Methotrexate
- Ciclosporin
- Glucocorticoids
- Infliximab

Submit answer

Reference ranges

Score: **16%**

1 ×
2 ×
3 ×
4 ×
5 ×

6	✗
7	✗
8	✗
9	✗
10	✗
11	✗
12	✓
13	✗
14	✗
15	✗
16	✗
17	✗
18	✗
19	✗
20	✗
21	✗
22	✗
23	✓
24	✗
25	✗
26	✗
27	✗
28	✗
29	✓
30	✗
31	✓
32	✗
33	✗
34	✗
35	✗
36	✓
37	✓
38	✗
39	✗
40	✗
41	✓

42	✗
43	✗
44	✗
45	✗
46	✗
47	✗
48	✗
49	✓
50	✗
51	-
52	-
53	-
54	-
55	-
56	-
57	-
58	-
59	-
60	-
61	-
62	-
63	-
64	-
65	-
66	-
67	-
68	-
69	-
70	-
71	-
72	-
73	-
74	-
75	-
76	-
77	-
78	-
79	-
80	-

81	-
82	-
83	-
84	-
85	-
86	-
87	-
88	-
89	-
90	-
91	-
92	-
93	-
94	-
95	-
96	-
97	-
98	-

All contents of this site are © 2024 Passmedicine Limited

Back to top

A normally fit and well 32-year-old black woman complains of a fever and tiredness over the past month. Her temperature is 38.2ºC, blood pressure is 115/70 mmHg, pulse is 75/min and respirations are 18/min.

On examination there were multiple non-tender cervical and axillary lymph notes. Lung auscultation reveals fine crackles throughout bilaterally. A chest x-ray film demonstrated hilar lymphadenopathy with diffuse interstitial infiltrates. A subsequent lymph node biopsy showed non-caseating granulomas.

Which of the following is the most appropriate therapy?

Supportive therapy	22%
Methotrexate	2%
Ciclosporin	2%
Glucocorticoids	74%
Infliximab	1%

Indications for corticosteroid treatment for sarcoidosis are: parenchymal lung disease, uveitis, hypercalcaemia and neurological or cardiac involvement

Important for me Less important

The patient's presentation is consistent with sarcoidosis. Characteristically the patient is usually asymptomatic, with disease detection occurring via an abnormal chest x-ray film which demonstrates bilateral symmetric hilar adenopathy usually with para-tracheal adenopathy and/or parenchymal infiltrates. In this case, the patient has reached the threshold for starting steroid treatment. None of the other medications have been shown to be beneficial in treating this grade of sarcoidosis.

Discuss (5) Improve

Next question

Sarcoidosis: management

Sarcoidosis is a multisystem disorder of unknown aetiology characterised by non-caseating granulomas. It is more common in young adults and in people of African descent.

Indications for steroids

- patients with chest x-ray stage 2 or 3 disease who are symptomatic. Patients with asymptomatic and stable stage 2 or 3 disease who have only mildly abnormal lung function do not require treatment
- hypercalcaemia
- eye, heart or neuro involvement

123

Next question

Textbooks

High-yield textbook

Extended textbook

Links

Radiopaedia 8 6

Pulmonary sarcoidosis staging

Suggest link Report broken link

Media

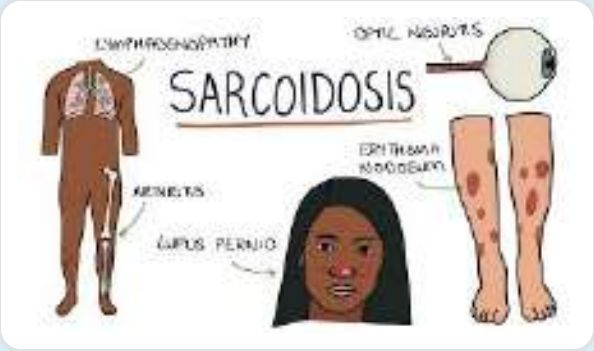

Sarcoidosis

Sarcoidosis - YouTube 6 0

Sarcoidosis

Osmosis - YouTube 4 0

Report broken media

Score: **17.3%**

1 ✗
2 ✗
3 ✗
4 ✗
5 ✗
6 ✗
7 ✗
8 ✗
9 ✗
10 ✗
11 ✗
12 ✓
13 ✗
14 ✗
15 ✗
16 ✗
17 ✗

18	✗
19	✗
20	✗
21	✗
22	✗
23	✓
24	✗
25	✗
26	✗
27	✗
28	✗
29	✓
30	✗
31	✓
32	✗
33	✗
34	✗
35	✗
36	✓
37	✓
38	✗
39	✗
40	✗
41	✓
42	✗
43	✗
44	✗
45	✗
46	✗
47	✗
48	✗
49	✓
50	✗
51	✗
52	✓
53	✗

54 ✗
55 ✓
56 ✗
57 ✗
58 ✓
59 ✗
60 ✓
61 ✗
62 ✗
63 ✗
64 ✗
65 ✗
66 ✗
67 ✗
68 ✗
69 ✗
70 ✗
71 ✗
72 ✗
73 ✗
74 ✗
75 ✓
76 ✗
77 ✗
78 ✗
79 ✓
80 ✗
81 ✗
82 ✓
83 ✗
84 ✗
85 ✗
86 ✗
87 ✗
88 ✗
89 ✗

90	✗
91	✗
92	✗
93	✓
94	✗
95	✓
96	✗
97	✗
98	✗
99	✗
100	✗
101	✗
102	✗
103	✓
104	✗
105	✗
106	✓
107	✗
108	✗
109	✗
110	✗
111	-

All contents of this site are © 2024 Passmedicine Limited

Back to top

A 38-year-old man presents to his general practitioner with shortness of breath and a productive cough of yellow sputum. He normally has a dry cough only. This is his third episode this year and he has received four courses of steroids and antibiotics. He is has only ever smoked once or twice at university. He works in a factory producing computer parts.

He was fully vaccinated as a child and well until 3 years ago and is otherwise well. He has no other past medical history.

On examination, he has scattered wheeze but no crepitations. He has a resonant hyperinflated chest and respiratory rate is 28 breaths per minute with saturations of 94% in air. There is no clubbing or cyanosis. He is awaiting lung function testing.

Hb	140g/l	Na^+	138 mmol/l
Platelets	340 * 10^9/l	K^+	4.7 mmol/l
WBC	14.1 * 10^9/l	Urea	6.2 mmol/l
Neuts	12 * 10^9/l	Creatinine	89 µmol/l
Lymphs	3.2 * 10^9/l	CRP	50 mg/l
Eosin	1.0 * 10^9/l		

Chest x-ray	hyperinflated lung fields, flattened hemidiaphragm, no consolidation seen
Sputum culture	*Moraxella* spp

What additional test would benefit the patient?

- Alpha-1-antitrypsin
- Sweat test
- CFTR genotyping
- Saccharin test
- Immunoglobulins

Submit answer

Reference ranges

Score: **16%**

1	✗
2	✗
3	✗
4	✗
5	✗
6	✗
7	✗
8	✗
9	✗
10	✗
11	✗
12	✓
13	✗
14	✗
15	✗
16	✗
17	✗
18	✗
19	✗
20	✗
21	✗
22	✗
23	✓
24	✗
25	✗
26	✗

27	✗
28	✗
29	✓
30	✗
31	✓
32	✗
33	✗
34	✗
35	✗
36	✓
37	✓
38	✗
39	✗
40	✗
41	✓
42	✗
43	✗
44	✗
45	✗
46	✗
47	✗
48	✗
49	✓
50	✗
51	-
52	-
53	-
54	-
55	-
56	-
57	-
58	-
59	-
60	-
61	-
62	-
63	-

64 -
65 -
66 -
67 -
68 -
69 -
70 -
71 -
72 -
73 -
74 -
75 -
76 -
77 -
78 -
79 -
80 -
81 -
82 -
83 -
84 -
85 -
86 -
87 -
88 -
89 -
90 -
91 -
92 -
93 -
94 -
95 -
96 -
97 -
98 -
99 -

All contents of this site are © 2024 Passmedicine Limited
Back to top

PassMedicine

A 38-year-old man presents to his general practitioner with shortness of breath and a productive cough of yellow sputum. He normally has a dry cough only. This is his third episode this year and he has received four courses of steroids and antibiotics. He is has only ever smoked once or twice at university. He works in a factory producing computer parts.

He was fully vaccinated as a child and well until 3 years ago and is otherwise well. He has no other past medical history.

On examination, he has scattered wheeze but no crepitations. He has a resonant hyperinflated chest and respiratory rate is 28 breaths per minute with saturations of 94% in air. There is no clubbing or cyanosis. He is awaiting lung function testing.

Hb	140g/l	Na^+	138 mmol/l
Platelets	340 * 10^9/l	K^+	4.7 mmol/l
WBC	14.1 * 10^9/l	Urea	6.2 mmol/l
Neuts	12 * 10^9/l	Creatinine	89 µmol/l
Lymphs	3.2 * 10^9/l	CRP	50 mg/l
Eosin	1.0 * 10^9/l		

Chest x-ray	hyperinflated lung fields, flattened hemidiaphragm, no consolidation seen
Sputum culture	*Moraxella* spp

What additional test would benefit the patient?

- Alpha-1-antitrypsin 67%
- Sweat test 7%
- CFTR genotyping 9%
- Saccharin test 8%
- Immunoglobulins 10%

COPD in a non smoker should prompt suspicion of alpha-1 antitrypsin deficiency

Important for me Less important

This young man has recurrent infective episodes with wheeze. The main differentials are cystic fibrosis, bronchiectasis and COPD. Importantly, he was well as a child and only recently has developed these episodes as an adult. He has some smoke exposure and is clearly hyperinflated with wheeze and no crepitations. He has no other features of cystic fibrosis/bronchiectasis. These features point towards COPD. The main cause of COPD is smoking but young patients with severe alpha-1-antitrypsin deficiency can develop COPD even in the absence of cigarette smoking.

The sweat test and CFTR genotyping will diagnose cystic fibrosis. Saccharin testing is positive in ciliary dyskinesias and low immunoglobulins can cause bronchiectasis. The only test above that would explain this early COPD picture is the alpha-1-antitrypsin test.

Discuss (4) Improve

Next question

Alpha-1 antitrypsin deficiency

Alpha-1 antitrypsin (A1AT) deficiency is a common inherited condition caused by a lack of a protease inhibitor (Pi) normally produced by the liver. The role of A1AT is to protect cells from enzymes such as neutrophil elastase. It classically causes emphysema (i.e. chronic obstructive pulmonary disease) in patients who are young and non-smokers.

Genetics

- located on chromosome 14
- inherited in an autosomal recessive / co-dominant fashion*
- alleles classified by their electrophoretic mobility - M for normal, S for slow, and Z for very slow
- normal: PiMM
- heterozygous: PiMZ
  - evidence base is conflicting re: risk of emphsema
  - however, if non-smoker low risk of developing emphsema but may pass on A1AT gene to children
- homozygous PiSS: 50% normal A1AT levels
- homozygous PiZZ: 10% normal A1AT levels

Features

- patients who manifest disease usually have PiZZ genotype

- lungs: panacinar emphysema, most marked in lower lobes
- liver: cirrhosis and hepatocellular carcinoma in adults, cholestasis in children

Investigations

- A1AT concentrations
- spirometry: obstructive picture

Management

- no smoking
- supportive: bronchodilators, physiotherapy
- intravenous alpha1-antitrypsin protein concentrates
- surgery: lung volume reduction surgery, lung transplantation

*trusted sources are split on which is a more accurate description

123

Next question

Textbooks

High-yield textbook

Extended textbook

Media

Alpha-1 antitrypsin deficiency

Osmosis - YouTube 👍 5 👎 0

[Emphysema (chronic obstructive pulmonary disease) - centriacinar, panacinar, paraseptal]

Osmosis - YouTube 👍 3 👎 0

[Alpha-1 antitrypsin deficiency]

Zero To Finals - YouTube 👍 0 👎 0

Report broken media

Score: **17.3%**

1	✗
2	✗
3	✗
4	✗
5	✗
6	✗
7	✗
8	✗
9	✗
10	✗
11	✗
12	✓
13	✗
14	✗
15	✗

16 ✗
17 ✗
18 ✗
19 ✗
20 ✗
21 ✗
22 ✗
23 ✓
24 ✗
25 ✗
26 ✗
27 ✗
28 ✗
29 ✓
30 ✗
31 ✓
32 ✗
33 ✗
34 ✗
35 ✗
36 ✓
37 ✓
38 ✗
39 ✗
40 ✗
41 ✓
42 ✗
43 ✗
44 ✗
45 ✗
46 ✗
47 ✗
48 ✗
49 ✓
50 ✗
51 ✗

52 ✓
53 ✗
54 ✗
55 ✓
56 ✗
57 ✗
58 ✓
59 ✗
60 ✓
61 ✗
62 ✗
63 ✗
64 ✗
65 ✗
66 ✗
67 ✗
68 ✗
69 ✗
70 ✗
71 ✗
72 ✗
73 ✗
74 ✗
75 ✓
76 ✗
77 ✗
78 ✗
79 ✓
80 ✗
81 ✗
82 ✓
83 ✗
84 ✗
85 ✗
86 ✗
87 ✗

88	✗
89	✗
90	✗
91	✗
92	✗
93	✓
94	✗
95	✓
96	✗
97	✗
98	✗
99	✗
100	✗
101	✗
102	✗
103	✓
104	✗
105	✗
106	✓
107	✗
108	✗
109	✗
110	✗
111	-

All contents of this site are © 2024 Passmedicine Limited

A 71-year-old man presents to the hospital with a 4-month history of progressive shortness of breath. His wife brought him into the hospital today as he can no longer walk up the stairs without having to take a break. He has a past medical history of hypertension, hypercholesterolaemia and diet-controlled type 2 diabetes.

On examination, he has a heart rate of 101 beats/min with a blood pressure of 140/98mmHg. His oxygen saturations are 90% on air with a respiratory rate of 27 breaths/min. There is reduced air entry throughout the right lung field.

A chest x-ray is requested, as shown below:

© Image used on license from Radiopaedia

What is the most likely diagnosis?

- Congestive heart failure
- Mesothelioma
- Parapneumonic effusion

- Pulmonary embolism ×
- Pulmonary metastases ×

Submit answer

Reference ranges

Score: **16%**

1	✗
2	✗
3	✗
4	✗
5	✗
6	✗
7	✗
8	✗
9	✗
10	✗
11	✗
12	✓
13	✗
14	✗
15	✗
16	✗
17	✗
18	✗
19	✗
20	✗
21	✗
22	✗
23	✓

24	✗
25	✗
26	✗
27	✗
28	✗
29	✓
30	✗
31	✓
32	✗
33	✗
34	✗
35	✗
36	✓
37	✓
38	✗
39	✗
40	✗
41	✓
42	✗
43	✗
44	✗
45	✗
46	✗
47	✗
48	✗
49	✓
50	✗
51	-
52	-
53	-
54	-
55	-
56	-
57	-
58	-
59	-
60	-

61 -
62 -
63 -
64 -
65 -
66 -
67 -
68 -
69 -
70 -
71 -
72 -
73 -
74 -
75 -
76 -
77 -
78 -
79 -
80 -
81 -
82 -
83 -
84 -
85 -
86 -
87 -
88 -
89 -
90 -
91 -
92 -
93 -
94 -
95 -
96 -
97 -
98 -
99 -
100 -

All contents of this site are © 2024 Passmedicine Limited

A 71-year-old man presents to the hospital with a 4-month history of progressive shortness of breath. His wife brought him into the hospital today as he can no longer walk up the stairs without having to take a break. He has a past medical history of hypertension, hypercholesterolaemia and diet-controlled type 2 diabetes.

On examination, he has a heart rate of 101 beats/min with a blood pressure of 140/98mmHg. His oxygen saturations are 90% on air with a respiratory rate of 27 breaths/min. There is reduced air entry throughout the right lung field.

A chest x-ray is requested, as shown below:

© Image used on license from Radiopaedia

What is the most likely diagnosis?

- Congestive heart failure 9%
- Mesothelioma 50%
- Parapneumonic effusion 33%

Pulmonary embolism 1%

Pulmonary metastases 6%

This patient has evidence of pleural thickening along the borders of the right lung which is most clear when making a comparison to the left lung field. There is also an associated pleural effusion on the right side with a visible fluid level that abuts the right costophrenic and costocardiac angles. Overall, this significantly reduces the volume of the right lung. This is most likely in keeping with a diagnosis of **mesothelioma** a rare pleural malignancy that is largely associated with asbestos exposure. The age of onset is typically between 60-85 years of age and presents with dyspnoea, cough and chest pain. Chest x-ray findings of mesothelioma include unilateral pleural thickening, reduced lung volume size and lower zone interstitial fibrosis.

Congestive heart failure can present with pleural effusions. However, more common chest x-ray findings include cardiomegaly, pulmonary venous congestion and bilateral pulmonary infiltrates. The unilateral findings on this patient's chest x-ray are more suggestive of an alternative diagnosis.

A **parapneumonic effusion** is a complication of viral or bacterial pneumonia when fluid collects in the pleural space due to increased permeability of the visceral pleura. Chest x-ray findings may be similar with signs of pleural effusion and an overall reduced lung volume. However, pleural thickening is not a feature of a parapneumonic effusion.

A **pulmonary embolism** (PE) does not frequently give rise to chest x-ray signs but can cause pleural effusions and Hampton hump sign (a wedge-shaped opacification secondary to lung infarction). However, the insidious onset of symptoms and pleural thickening make PE less likely.

Pulmonary metastases are relatively common but are not usually symptomatic unless advanced. Rather, the patient will experience constitutional symptoms and those of the primary malignancy. Chest x-ray findings of pulmonary metastases usually include multiple round nodules located in the peripheral lung fields. Unilateral pleural thickening with an associated effusion is unlikely to present pulmonary metastases.

Discuss (2) Improve

Next question ›

Mesothelioma

Mesothelioma is a cancer of the mesothelial layer of the pleural cavity that is strongly associated with asbestos exposure. In a small percentage of cases, other mesothelial layers such as those in

the abdomen may be affected.

Features

- Dyspnoea, weight loss, chest wall pain
- Clubbing
- 30% present as painless pleural effusion
- Only 20% have pre-existing asbestosis
- History of asbestos exposure in 85-90%, latent period of 30-40 years

Basics

- Malignancy of mesothelial cells of pleura
- Metastases to contralateral lung and peritoneum
- Right lung affected more often than left

Investigation/diagnosis

- suspicion is normally raised by a chest x-ray showing either a pleural effusion or pleural thickening
- the next step is normally a pleural CT
- if a pleural effusion is present fluid should be sent for MC&S, biochemistry and cytology (but cytology is only helpful in 20-30% of cases)
- local anaesthetic thoracoscopy is increasingly used to investigate cytology negative exudative effusions as it has a high diagnostic yield (around 95%)
- if an area of pleural nodularity is seen on CT then an image-guided pleural biopsy may be used

Management

- Symptomatic
- Industrial compensation
- Chemotherapy, Surgery if operable
- Prognosis poor, median survival 12 months

Next question

Textbooks

High-yield textbook

Extended textbook

Links

British Thoracic Society 1 2

2018 Investigation and Management of Pleural Mesothelioma

British Thoracic Society 5 0

2023 Pleural disease guidelines

Suggest link Report broken link

Media

Mesothelioma

Osmosis - YouTube 2 0

Report broken media

Score: **17.3%**

1	✗
2	✗
3	✗
4	✗
5	✗
6	✗
7	✗
8	✗
9	✗
10	✗
11	✗
12	✓
13	✗
14	✗
15	✗
16	✗
17	✗
18	✗
19	✗
20	✗
21	✗
22	✗
23	✓
24	✗
25	✗
26	✗
27	✗
28	✗
29	✓
30	✗
31	✓
32	✗
33	✗
34	✗

35	✗
36	✓
37	✓
38	✗
39	✗
40	✗
41	✓
42	✗
43	✗
44	✗
45	✗
46	✗
47	✗
48	✗
49	✓
50	✗
51	✗
52	✓
53	✗
54	✗
55	✓
56	✗
57	✗
58	✓
59	✗
60	✓
61	✗
62	✗
63	✗
64	✗
65	✗
66	✗
67	✗
68	✗
69	✗
70	✗

71	✗
72	✗
73	✗
74	✗
75	✓
76	✗
77	✗
78	✗
79	✓
80	✗
81	✗
82	✓
83	✗
84	✗
85	✗
86	✗
87	✗
88	✗
89	✗
90	✗
91	✗
92	✗
93	✓
94	✗
95	✓
96	✗
97	✗
98	✗
99	✗
100	✗
101	✗
102	✗
103	✓
104	✗
105	✗
106	✓

107	✕
108	✕
109	✕
110	✕
111	-

All contents of this site are © 2024 Passmedicine Limited

A 76-year-old retired boiler engineer presents with a 3-week history of a cough following a coryzal illness. He was a heavy smoker until around five years ago. An x-ray is performed:

© Image used on license from Radiopaedia

What does the chest x-ray demonstrate?

- Chronic obstructive pulmonary disease
- Bronchiectasis
- Asbestosis
- Pleural plaques
- Lung cancer

Submit answer

Reference ranges

Score: **16%**

1	✗
2	✗
3	✗
4	✗
5	✗
6	✗
7	✗
8	✗
9	✗
10	✗
11	✗
12	✓
13	✗
14	✗
15	✗
16	✗
17	✗
18	✗
19	✗
20	✗
21	✗
22	✗
23	✓
24	✗
25	✗
26	✗
27	✗
28	✗
29	✓
30	✗
31	✓
32	✗
33	✗

34	✗
35	✗
36	✓
37	✓
38	✗
39	✗
40	✗
41	✓
42	✗
43	✗
44	✗
45	✗
46	✗
47	✗
48	✗
49	✓
50	✗
51	-
52	-
53	-
54	-
55	-
56	-
57	-
58	-
59	-
60	-
61	-
62	-
63	-
64	-
65	-
66	-
67	-
68	-
69	-
70	-
71	-

72 -
73 -
74 -
75 -
76 -
77 -
78 -
79 -
80 -
81 -
82 -
83 -
84 -
85 -
86 -
87 -
88 -
89 -
90 -
91 -
92 -
93 -
94 -
95 -
96 -
97 -
98 -
99 -
100 -
101 -

All contents of this site are © 2024 Passmedicine Limited
Back to top

A 76-year-old retired boiler engineer presents with a 3-week history of a cough following a coryzal illness. He was a heavy smoker until around five years ago. An x-ray is performed:

© Image used on license from Radiopaedia

What does the chest x-ray demonstrate?

Chronic obstructive pulmonary disease	1%
Bronchiectasis	1%
Asbestosis	13%
Pleural plaques	83%
Lung cancer	2%

The correct answer is **Pleural plaques**. Pleural plaques are areas of fibrous thickening on the pleura (the lining of the lungs) and are often associated with exposure to asbestos. They are usually asymptomatic and do not typically affect lung function. The chest x-ray in the question shows bilateral pleural thickening, which is characteristic of pleural plaques. Their presence can indicate past exposure to asbestos, which would be consistent with the patient's history as a boiler

engineer.

The first incorrect option is **Chronic obstructive pulmonary disease (COPD)**. Although the patient has a history of heavy smoking, which is a leading risk factor for COPD, this condition would not typically manifest as pleural plaques on an x-ray. Instead, one might expect to see hyperinflation of the lungs or potentially bullae (areas of emphysematous change), neither of which are evident in this image.

Next, we have **Bronchiectasis**, another incorrect choice. Bronchiectasis refers to permanent enlargement and damage to the airways (bronchi), often caused by recurrent infection or inflammation. On an x-ray, bronchiectasis may present as ring-like or tram-line shadows due to abnormally dilated bronchi; however, these signs are not visible in this case.

Asbestosis is also suggested but it is not correct either. Asbestosis refers specifically to interstitial lung disease caused by inhalation of asbestos fibres. While it shares a common cause with pleural plaques (asbestos exposure), its radiographic appearance differs significantly. Asbestosis typically presents as small irregular opacities predominantly in lower lobes and subpleural areas, rather than the discrete areas of pleural thickening seen here.

Lastly, **Lung cancer** was proposed as an option but it too does not fit with the findings on this x-ray. Lung cancers can take various forms on imaging - from solitary pulmonary nodules to larger masses - but they generally do not appear as bilateral pleural thickening like that seen in this image.

Asbestos and the lung

Asbestos can cause a variety of lung diseases from benign pleural plaques to mesothelioma.

Pleural plaques

Pleural plaques are benign and do not undergo malignant change. They, therefore don't require any follow-up. They are the most common form of asbestos-related lung disease and generally occur after a latent period of 20-40 years.

Pleural thickening

Asbestos exposure may cause diffuse pleural thickening in a similar pattern to that seen following an empyema or haemothorax. The underlying pathophysiology is not fully understood.

Asbestosis

The severity of asbestosis is related to the length of exposure. This is in contrast to mesothelioma where even very limited exposure can cause disease. The latent period is typically 15-30 years. Asbestosis typically causes lower lobe fibrosis.

Features
- dyspnoea and reduced exercise tolerance
- clubbing
- bilateral end-inspiratory crackles
- lung function tests show a restrictive pattern with reduced gas transfer

It is treated conservatively - no interventions offer a significant benefit.

Mesothelioma

Mesothelioma is a malignant disease of the pleura. Crocidolite (blue) asbestos is the most dangerous form.

Possible features
- progressive shortness-of-breath
- chest pain
- pleural effusion

Patients are usually offered palliative chemotherapy and there is also a limited role for surgery and radiotherapy. Unfortunately, the prognosis is very poor, with a median survival from diagnosis of 8-14 months.

Lung cancer

Whilst mesothelioma is in some ways synonymous with asbestos, lung cancer is actually the most common form of cancer associated with asbestos exposure. It also has a synergistic effect with cigarette smoke in terms of the increased risk. Therefore, smoking cessation is very important as the risk of lung cancer in smokers who have a history of asbestos exposure is very high.

AI + Q 123

Next question >

Textbooks

High-yield textbook

Extended textbook

Score: **17.3%**

1	✗
2	✗
3	✗
4	✗
5	✗
6	✗
7	✗
8	✗
9	✗
10	✗
11	✗
12	✓
13	✗
14	✗
15	✗
16	✗
17	✗
18	✗
19	✗
20	✗
21	✗
22	✗
23	✓
24	✗
25	✗
26	✗
27	✗
28	✗
29	✓
30	✗
31	✓
32	✗
33	✗
34	✗
35	✗

36	✓
37	✓
38	✗
39	✗
40	✗
41	✓
42	✗
43	✗
44	✗
45	✗
46	✗
47	✗
48	✗
49	✓
50	✗
51	✗
52	✓
53	✗
54	✗
55	✓
56	✗
57	✗
58	✓
59	✗
60	✓
61	✗
62	✗
63	✗
64	✗
65	✗
66	✗
67	✗
68	✗
69	✗
70	✗
71	✗

72	✗
73	✗
74	✗
75	✓
76	✗
77	✗
78	✗
79	✓
80	✗
81	✗
82	✓
83	✗
84	✗
85	✗
86	✗
87	✗
88	✗
89	✗
90	✗
91	✗
92	✗
93	✓
94	✗
95	✓
96	✗
97	✗
98	✗
99	✗
100	✗
101	✗
102	✗
103	✓
104	✗
105	✗
106	✓
107	✗

108	✕
109	✕
110	✕
111	-

All contents of this site are © 2024 Passmedicine Limited

A 68-year-old gentleman is presenting to the emergency department with a two month history of productive cough. He tells you that over the past week he is getting increasingly worse and feels feverish. He informs you that it is not unusual for him to cough copious amounts, but this time is much worse, and is wondering if he has an infection brewing. He also informs you that he is regularly under the care of the respiratory team, as he is suffering from a lung condition, however he cannot disclose further information. He is a non-smoker.

He appears sweaty and his temperature is 38.2ºC. He has a heart rate of 103/min and his capillary refill time is 3 seconds. Blood pressure is 102/54 mmHg. Examination indicates coarse crackles bilaterally and on the R mid-zone. Heart sounds are normal with no added sounds.

A chest x-ray is performed indicating increasing bronchovascular markings with bilateral consolidation.

You review his medicines and note that he is on salbutamol and ipratropium nebulisers, carbocisteine, aspirin and ramipril. You also notice that he is on ciprofloxacin, and when you enquire further he tells you that he has been on ciprofloxacin for 14 days so far as prescribed by the respiratory team because of an organism isolated in his sputum. You chase that up, and find out that he has previously grown *Pseudomonas aeruginosa*.

What antibiotic would you prescribe to this patient in this setting, given his status as penicillin allergic:

- Intravenous meropenem
- Intravenous co-amoxiclav
- Intravenous tazocin
- Intravenous metronidazole
- Nebulised colomycin

Submit answer

Reference ranges

Score: **16%**

1	✗
2	✗
3	✗
4	✗
5	✗
6	✗
7	✗
8	✗
9	✗
10	✗
11	✗
12	✓
13	✗
14	✗
15	✗
16	✗
17	✗
18	✗
19	✗
20	✗
21	✗
22	✗
23	✓
24	✗
25	✗
26	✗
27	✗
28	✗
29	✓
30	✗

31	✓
32	✗
33	✗
34	✗
35	✗
36	✓
37	✓
38	✗
39	✗
40	✗
41	✓
42	✗
43	✗
44	✗
45	✗
46	✗
47	✗
48	✗
49	✓
50	✗
51	-
52	-
53	-
54	-
55	-
56	-
57	-
58	-
59	-
60	-
61	-
62	-
63	-
64	-
65	-
66	-
67	-
68	-

69	-
70	-
71	-
72	-
73	-
74	-
75	-
76	-
77	-
78	-
79	-
80	-
81	-
82	-
83	-
84	-
85	-
86	-
87	-
88	-
89	-
90	-
91	-
92	-
93	-
94	-
95	-
96	-
97	-
98	-
99	-
100	-
101	-
102	-

All contents of this site are © 2024 Passmedicine Limited
Back to top

A 68-year-old gentleman is presenting to the emergency department with a two month history of productive cough. He tells you that over the past week he is getting increasingly worse and feels feverish. He informs you that it is not unusual for him to cough copious amounts, but this time is much worse, and is wondering if he has an infection brewing. He also informs you that he is regularly under the care of the respiratory team, as he is suffering from a lung condition, however he cannot disclose further information. He is a non-smoker.

He appears sweaty and his temperature is 38.2ºC. He has a heart rate of 103/min and his capillary refill time is 3 seconds. Blood pressure is 102/54 mmHg. Examination indicates coarse crackles bilaterally and on the R mid-zone. Heart sounds are normal with no added sounds.

A chest x-ray is performed indicating increasing bronchovascular markings with bilateral consolidation.

You review his medicines and note that he is on salbutamol and ipratropium nebulisers, carbocisteine, aspirin and ramipril. You also notice that he is on ciprofloxacin, and when you enquire further he tells you that he has been on ciprofloxacin for 14 days so far as prescribed by the respiratory team because of an organism isolated in his sputum. You chase that up, and find out that he has previously grown *Pseudomonas aeruginosa*.

What antibiotic would you prescribe to this patient in this setting, given his status as penicillin allergic:

- Intravenous meropenem — 52%
- Intravenous co-amoxiclav — 2%
- Intravenous tazocin — 23%
- Intravenous metronidazole — 4%
- Nebulised colomycin — 20%

Appropriate treatment of *Pseudomonas* positive bronchiectasis failing to respond to ciprofloxacin includes IV tazocin, ceftazidime, aztreonam or meropenem

Important for me Less important

It is not uncommon in daily practice to meet patients that are aware of the fact that they suffer from a particular issue (in the case of this patient respiratory) without being able to exactly explain it (bronchiectasis). There are certain clues in this history pointing to a long term condition such as bronchiectasis (absence of smoking, bilateral crackles, copious productive cough, growth of pseudomonas, recent use of ciprofloxacin). As ciprofloxacin orally for 14 days has not worked for this patient the BTS guidelines suggest for the use of IV tazocin, ceftazidime, aztreonam or meropenem - given his penicillin allergic status, the safest choice is meropenem. Nebulised colomycin has a place in the treatment of these patients, not however in the acute setting.

Discuss (7) | Improve

Next question >

Bronchiectasis: management

Bronchiectasis describes a permanent dilatation of the airways secondary to chronic infection or inflammation. After assessing for treatable causes (e.g. immune deficiency) management is as follows:

- physical training (e.g. inspiratory muscle training) - has a good evidence base for patients with non-cystic fibrosis bronchiectasis
- postural drainage
- antibiotics for exacerbations + long-term rotating antibiotics in severe cases
- bronchodilators in selected cases
- immunisations
- surgery in selected cases (e.g. Localised disease)

Most common organisms isolated from patients with bronchiectasis:

- *Haemophilus influenzae* (most common)
- *Pseudomonas aeruginosa*
- Klebsiella spp.
- *Streptococcus pneumoniae*

+ Q 123

Next question >

Textbooks

High-yield textbook

Extended textbook

Links

British Thoracic Society

2018 Bronchiectasis guidelines

1 0

Clinical Knowledge Summaries

Bronchiectasis guidelines

1 1

Suggest link

Report broken link

Media

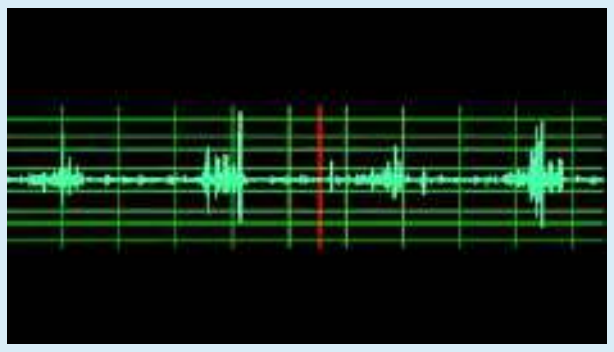

Bronchiectasis crackles - REQUIRES HEADPHONES

Thinklabs - YouTube

4 0

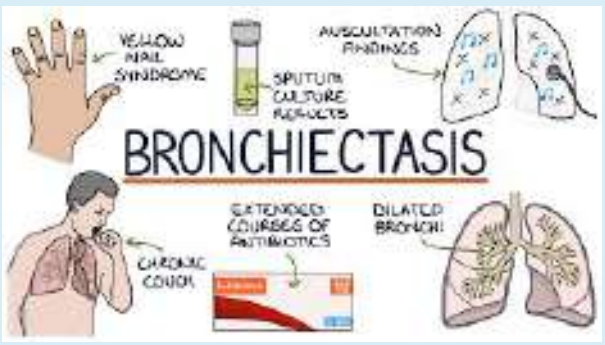

Bronchiectasis

Zero To Finals - YouTube

0 0

Bronchiectasis - causes, pathophysiology, signs and symptoms, investigations and treatment

Armando Hasudungan - YouTube 3 1

Report broken media

Score: **17.3%**

1	✗
2	✗
3	✗
4	✗
5	✗
6	✗
7	✗
8	✗
9	✗
10	✗
11	✗
12	✓
13	✗
14	✗
15	✗
16	✗
17	✗
18	✗
19	✗
20	✗
21	✗
22	✗
23	✓
24	✗

25	✗
26	✗
27	✗
28	✗
29	✓
30	✗
31	✓
32	✗
33	✗
34	✗
35	✗
36	✓
37	✓
38	✗
39	✗
40	✗
41	✓
42	✗
43	✗
44	✗
45	✗
46	✗
47	✗
48	✗
49	✓
50	✗
51	✗
52	✓
53	✗
54	✗
55	✓
56	✗
57	✗
58	✓
59	✗
60	✓

61	✗
62	✗
63	✗
64	✗
65	✗
66	✗
67	✗
68	✗
69	✗
70	✗
71	✗
72	✗
73	✗
74	✗
75	✓
76	✗
77	✗
78	✗
79	✓
80	✗
81	✗
82	✓
83	✗
84	✗
85	✗
86	✗
87	✗
88	✗
89	✗
90	✗
91	✗
92	✗
93	✓
94	✗
95	✓
96	✗

97	✗
98	✗
99	✗
100	✗
101	✗
102	✗
103	✓
104	✗
105	✗
106	✓
107	✗
108	✗
109	✗
110	✗
111	-

All contents of this site are © 2024 Passmedicine Limited

Back to top

An 82-year-old man is admitted with a three day history of increasing breathlessness, His past medical history includes ischaemic heart disease and rheumatoid arthritis. His current medications include aspirin, atorvastatin, bisoprolol, ramipril and methotrexate. On examination his heart rate is 80/min, blood pressure 111/80 mmHg, respiratory rate 24/min and oxygen saturations 89% on room air. There are reduced breath sounds on the right side of his chest.

A chest x-ray is ordered:

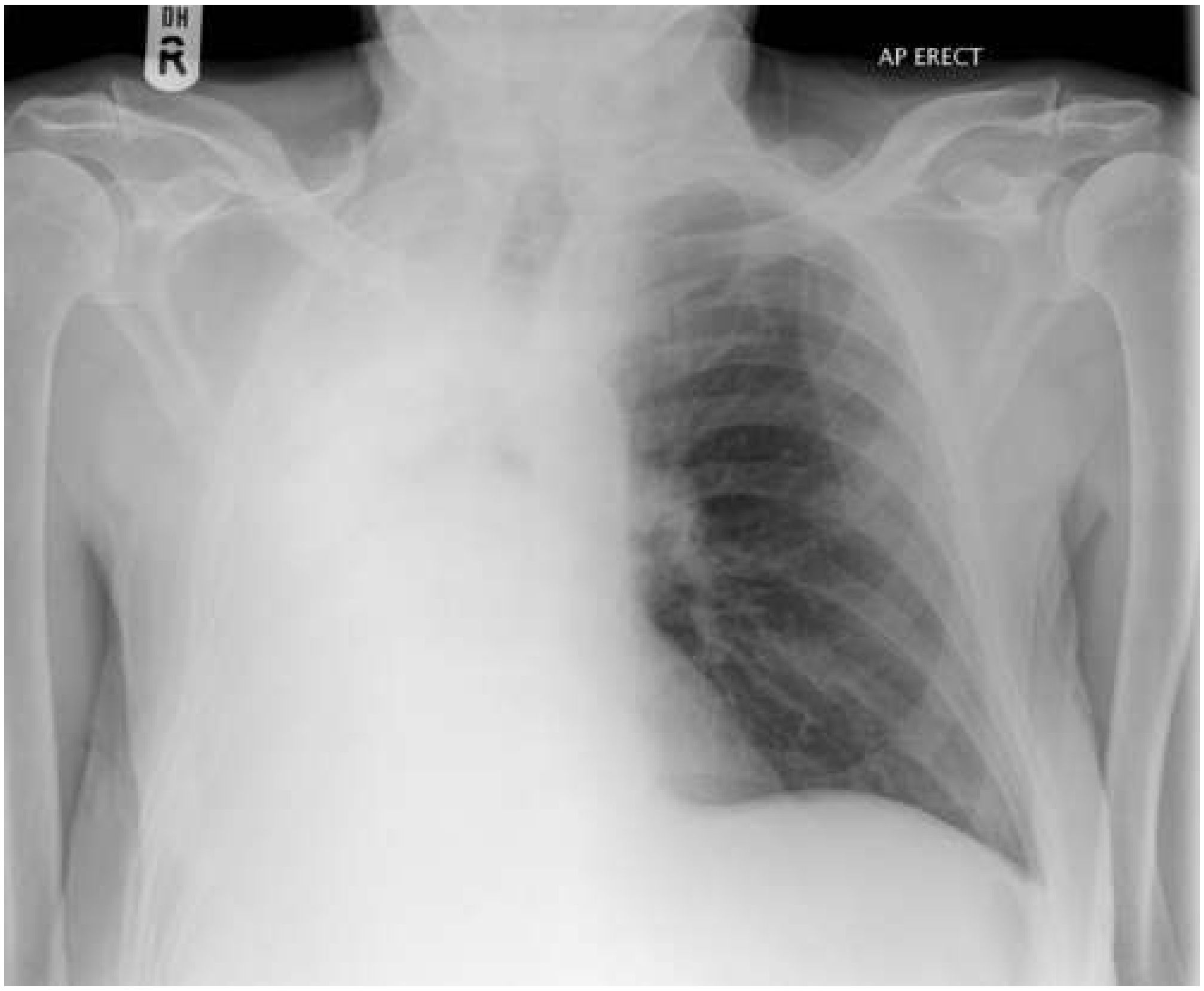

© Image used on license from Radiopaedia

What is the most likely diagnosis?

- Mesothelioma
- Methotrexate-induced pneumonitis
- Multilobar pneumonia
- Massive pleural effusion

- [ ] Lung collapse

Submit answer

Reference ranges

Score: **16%**

1	✗
2	✗
3	✗
4	✗
5	✗
6	✗
7	✗
8	✗
9	✗
10	✗
11	✗
12	✓
13	✗
14	✗
15	✗
16	✗
17	✗
18	✗
19	✗
20	✗
21	✗
22	✗
23	✓
24	✗
25	✗

26	✗
27	✗
28	✗
29	✓
30	✗
31	✓
32	✗
33	✗
34	✗
35	✗
36	✓
37	✓
38	✗
39	✗
40	✗
41	✓
42	✗
43	✗
44	✗
45	✗
46	✗
47	✗
48	✗
49	✓
50	✗
51	-
52	-
53	-
54	-
55	-
56	-
57	-
58	-
59	-
60	-
61	-
62	-

```
-
-
-
-
-
-
-
-
-
-
-
-
-
-
-
-
-
-
-
-
-
-
-
-
-
-
-
-
-
-
-
-
-
-
-
-
-
-
-
-
```

103 -

All contents of this site are © 2024 Passmedicine Limited

An 82-year-old man is admitted with a three day history of increasing breathlessness, His past medical history includes ischaemic heart disease and rheumatoid arthritis. His current medications include aspirin, atorvastatin, bisoprolol, ramipril and methotrexate. On examination his heart rate is 80/min, blood pressure 111/80 mmHg, respiratory rate 24/min and oxygen saturations 89% on room air. There are reduced breath sounds on the right side of his chest.

A chest x-ray is ordered:

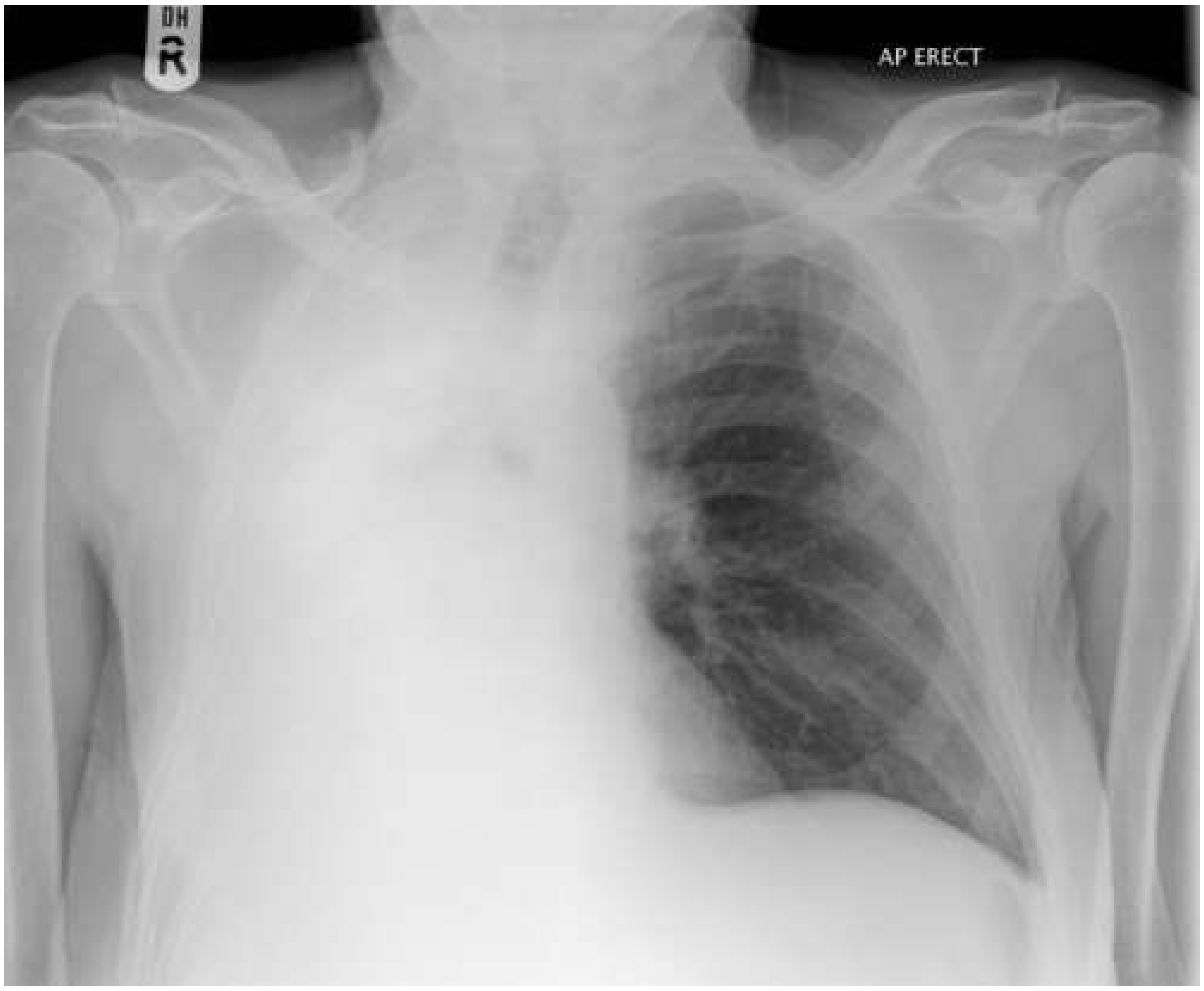

© Image used on license from Radiopaedia

What is the most likely diagnosis?

Mesothelioma	1%
Methotrexate-induced pneumonitis	2%
Multilobar pneumonia	1%
Massive pleural effusion	12%

Lung collapse 84%

The key to making the diagnosis, as with all white-outs, is to look at the position of the trachea. In this x-ray it is pulled towards the opacity making the diagnosis of a lung collapse likely.

Discuss (2) Improve

Next question

Chest x-ray: white lung lesions

There are numerous causes of white shadowing in the lungs including:

- consolidation
- pleural effusion
- collapse
- pneumonectomy
- specific lesions e.g. tumours
- fluid e.g. pulmonary oedema

If there is a 'white-out' of a hemithorax it is useful to assess the position of the trachea - is it central, pulled or pushed from the side of opacification.

Trachea pulled toward the white-out	Trachea central	Trachea pushed away from the white-out
Pneumonectomy Complete lung collapse e.g. endobronchial intubation Pulmonary hypoplasia	Consolidation Pulmonary oedema (usually bilateral) Mesothelioma	Pleural effusion Diaphragmatic hernia Large thoracic mass

© Image used on license from Radiopaedia

Lung collapse - note how the trachea is pulled towards the side of the white-out

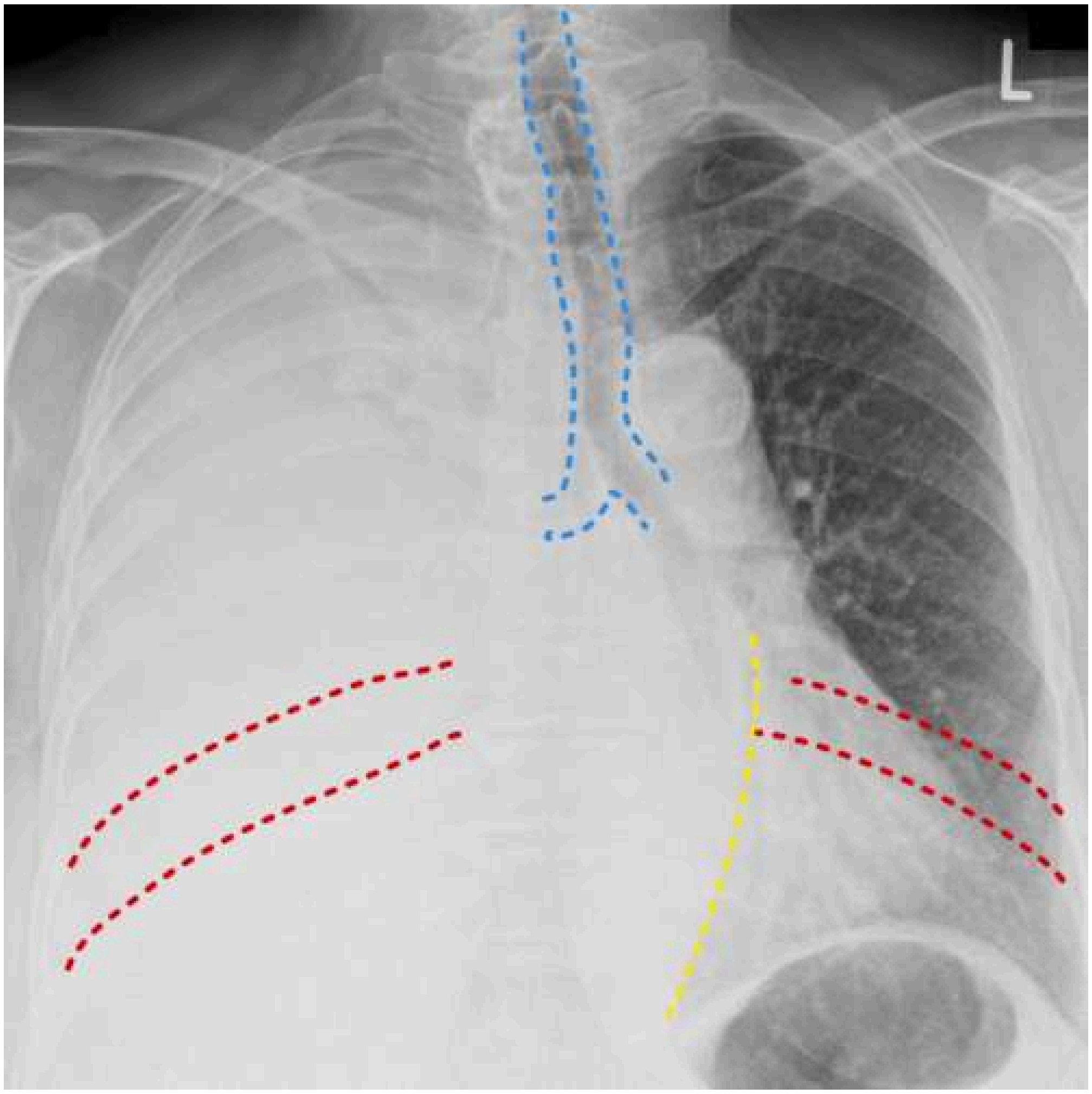

© Image used on license from Radiopaedia

Pleural effusion - note how the trachea (blue) is pushed away the side of the white-out. The other signs of a positive mass effect include leftward bowing of the azygo-oesophageal recess (yellow) and splaying of the ribs on the right (red)

For more information check out the link to the superb Radiology Masterclass website.

123

Next question

Textbooks

High-yield textbook

Extended textbook

Links

Wiki Radiography 13 4

Example of right upper lobe consolidation

Radiology Masterclass 42 6

Fantastic radiology teaching website

Suggest link Report broken link

Score: **17.3%**

1	✗
2	✗
3	✗
4	✗
5	✗
6	✗
7	✗
8	✗
9	✗
10	✗
11	✗
12	✓
13	✗
14	✗
15	✗
16	✗
17	✗
18	✗
19	✗
20	✗
21	✗
22	✗
23	✓
24	✗
25	✗
26	✗
27	✗
28	✗
29	✓
30	✗
31	✓
32	✗
33	✗
34	✗
35	✗

36	✓
37	✓
38	✗
39	✗
40	✗
41	✓
42	✗
43	✗
44	✗
45	✗
46	✗
47	✗
48	✗
49	✓
50	✗
51	✗
52	✓
53	✗
54	✗
55	✓
56	✗
57	✗
58	✓
59	✗
60	✓
61	✗
62	✗
63	✗
64	✗
65	✗
66	✗
67	✗
68	✗
69	✗
70	✗
71	✗

72	✗
73	✗
74	✗
75	✓
76	✗
77	✗
78	✗
79	✓
80	✗
81	✗
82	✓
83	✗
84	✗
85	✗
86	✗
87	✗
88	✗
89	✗
90	✗
91	✗
92	✗
93	✓
94	✗
95	✓
96	✗
97	✗
98	✗
99	✗
100	✗
101	✗
102	✗
103	✓
104	✗
105	✗
106	✓
107	✗

108	✕
109	✕
110	✕
111	-

All contents of this site are © 2024 Passmedicine Limited

A 77-year-old active smoker with a 40 pack year history presents with his second non-infective exacerbation of COPD in 3 months. He was diagnosed with COPD two years ago and had been relatively well controlled using salbutamol as required prior to these two admissions. Two days after his admission, he reports that he is close to his baseline and would like to go home. His repeat pulmonary function tests reveal a forced expiratory volume in 1 second of 46%.

On reviewing his peak flow diary you note a significant (> 20%) diurnal variation in his peak flow.

Which would be most useful in optimising his COPD control?

- No change to inhaler therapy, follow up in 3 months
- Add beclometasone inhaler alone
- Add salmeterol and fluticasone combination inhaler
- Add salmeterol inhaler alone
- Long term oxygen therapy

Submit answer

Reference ranges

Score: **16%**

1 ✗
2 ✗
3 ✗
4 ✗
5 ✗

6	✗
7	✗
8	✗
9	✗
10	✗
11	✗
12	✓
13	✗
14	✗
15	✗
16	✗
17	✗
18	✗
19	✗
20	✗
21	✗
22	✗
23	✓
24	✗
25	✗
26	✗
27	✗
28	✗
29	✓
30	✗
31	✓
32	✗
33	✗
34	✗
35	✗
36	✓
37	✓
38	✗
39	✗
40	✗
41	✓

42	✗
43	✗
44	✗
45	✗
46	✗
47	✗
48	✗
49	✓
50	✗
51	-
52	-
53	-
54	-
55	-
56	-
57	-
58	-
59	-
60	-
61	-
62	-
63	-
64	-
65	-
66	-
67	-
68	-
69	-
70	-
71	-
72	-
73	-
74	-
75	-
76	-
77	-
78	-
79	-
80	-

81 -
82 -
83 -
84 -
85 -
86 -
87 -
88 -
89 -
90 -
91 -
92 -
93 -
94 -
95 -
96 -
97 -
98 -
99 -
100 -
101 -
102 -
103 -
104 -

All contents of this site are © 2024 Passmedicine Limited

A 77-year-old active smoker with a 40 pack year history presents with his second non-infective exacerbation of COPD in 3 months. He was diagnosed with COPD two years ago and had been relatively well controlled using salbutamol as required prior to these two admissions. Two days after his admission, he reports that he is close to his baseline and would like to go home. His repeat pulmonary function tests reveal a forced expiratory volume in 1 second of 46%.

On reviewing his peak flow diary you note a significant (> 20%) diurnal variation in his peak flow.

Which would be most useful in optimising his COPD control?

- No change to inhaler therapy, follow up in 3 months — 1%
- Add beclometasone inhaler alone — 19%
- Add salmeterol and fluticasone combination inhaler — 74%
- Add salmeterol inhaler alone — 4%
- Long term oxygen therapy — 2%

COPD - still breathless despite using SABA/SAMA and **asthma/steroid responsive features** → add a LABA + ICS

Important for me Less important

As this patient has a feature suggestive of asthma/steroid responsiveness (significant diurnal variation) the next step in management is a long-acting beta agonist (e.g. salmeterol) + an inhaled corticosteroid. NICE now recommend the use of combined inhalers where possible.

Discuss (1) Improve

Next question

COPD: stable management

NICE updated its guidelines on the management of chronic obstructive pulmonary disease (COPD) in 2018.

General management

- >smoking cessation advice: including offering nicotine replacement therapy, varenicline or bupropion
- annual influenza vaccination
- one-off pneumococcal vaccination
- pulmonary rehabilitation to all people who view themselves as functionally disabled by COPD (usually Medical Research Council [MRC] grade 3 and above)

Bronchodilator therapy

- a short-acting beta2-agonist (SABA) or short-acting muscarinic antagonist (SAMA) is first-line treatment
- for patients who remain breathless or have exacerbations despite using short-acting bronchodilators the next step is determined by whether the patient has '*asthmatic features/features suggesting steroid responsiveness*'

There are a number of criteria NICE suggest to determine whether a patient has asthmatic/steroid responsive features:

- any previous, secure diagnosis of asthma or of atopy
- a higher blood eosinophil count - note that NICE recommend a full blood count for all patients as part of the work-up
- substantial variation in FEV1 over time (at least 400 ml)
- substantial diurnal variation in peak expiratory flow (at least 20%)

Interestingly NICE do not recommend formal reversibility testing as one of the criteria. In the guidelines they state that '*routine spirometric reversibility testing is not necessary as part of the diagnostic process or to plan initial therapy with bronchodilators or corticosteroids. It may be unhelpful or misleading...*'. They then go on to discuss why they have reached this conclusion. Please see the guidelines for more details.

No asthmatic features/features suggesting steroid responsiveness

- add a long-acting beta2-agonist (LABA) + long-acting muscarinic antagonist (LAMA)
    - if already taking a SAMA, discontinue and switch to a SABA

Asthmatic features/features suggesting steroid responsiveness

- LABA + inhaled corticosteroid (ICS)
- if patients remain breathless or have exacerbations offer triple therapy i.e. LAMA + LABA + ICS
    - if already taking a SAMA, discontinue and switch to a SABA

- NICE recommend the use of combined inhalers where possible

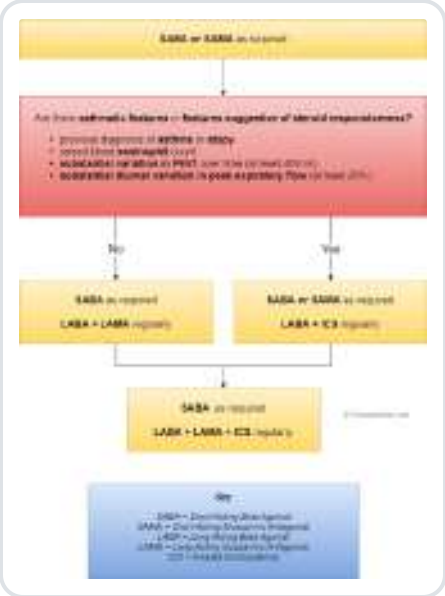

Oral theophylline

- NICE only recommends theophylline after trials of short and long-acting bronchodilators or to people who cannot used inhaled therapy
- the dose should be reduced if macrolide or fluoroquinolone antibiotics are co-prescribed

Oral prophylactic antibiotic therapy

- azithromycin prophylaxis is recommended in select patients
- patients should not smoke, have optimised standard treatments and continue to have exacerbations
- other prerequisites include a CT thorax (to exclude bronchiectasis) and sputum culture (to exclude atypical infections and tuberculosis)
- LFTs and an ECG to exclude QT prolongation should also be done as azithromycin can prolong the QT interval

Standby medication: NICE recommend offering a short course of oral corticosteroids and oral antibiotics to keep at home if: NICE

- have had an exacerbation within the last year
- understand how to take the medication, and are aware of associated risks and benefits
- know to when to seek help and when to ask for replacements once medication has been used

Mucolytics

- should be 'considered' in patients with a chronic productive cough and continued if symptoms improve

Phosphodiesterase-4 (PDE-4) inhibitors NICE

- oral PDE-4 inhibitors such as roflumilast reduce the risk of COPD exacerbations in patients with severe COPD and a history of frequent COPD exacerbations
- NICE recommend if:
  - the disease is severe, defined as a forced expiratory volume in 1 second (FEV1) after a bronchodilator of less than 50% of predicted normal, and

- the person has had 2 or more exacerbations in the previous 12 months despite triple inhaled therapy with a long-acting muscarinic antagonist, a long-acting beta-2 agonist and an inhaled corticosteroid

Cor pulmonale

- features include peripheral oedema, raised jugular venous pressure, systolic parasternal heave, loud P2
- use a loop diuretic for oedema, consider long-term oxygen therapy
- ACE-inhibitors, calcium channel blockers and alpha blockers are not recommended by NICE

Factors which may improve survival in patients with stable COPD

- smoking cessation - the single most important intervention in patients who are still smoking
- long term oxygen therapy in patients who fit criteria
- lung volume reduction surgery in selected patients

+ Q 123

Next question >

Textbooks

High-yield textbook

Extended textbook

Links

Global Initiative for Chronic Obstructive Lung Disease 14 32

GOLD criteria 2017

NICE 33 30

2018 COPD guidelines

NICE 15 10

Roflumilast NICE recommendations

NICE 65 18

2018 COPD management diagram

Suggest link Report broken link

Media

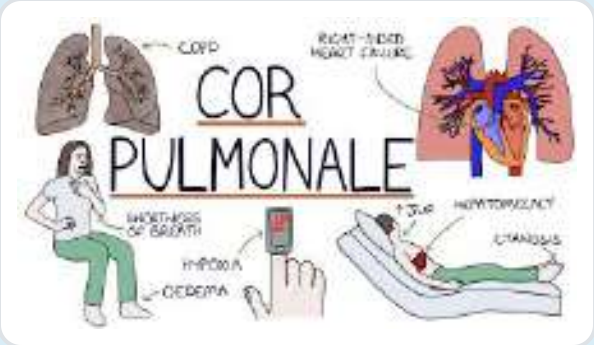

Cor pulmonale

Zero To Finals - YouTube 5 0

Chronic bronchitis

Osmosis - YouTube 3 0

Cor pulmonale

Osmosis - YouTube 1 0

Understanding COPD

Armando Hasudungan - YouTube

👍 0 👎 0

All about COPD (for Medical Students)

MedFlix - YouTube 👍 3 👎 1

Report broken media

Score: **17.3%**

1	✗
2	✗
3	✗
4	✗
5	✗
6	✗
7	✗
8	✗
9	✗
10	✗
11	✗
12	✓
13	✗
14	✗
15	✗
16	✗
17	✗
18	✗
19	✗
20	✗
21	✗

22	✗
23	✓
24	✗
25	✗
26	✗
27	✗
28	✗
29	✓
30	✗
31	✓
32	✗
33	✗
34	✗
35	✗
36	✓
37	✓
38	✗
39	✗
40	✗
41	✓
42	✗
43	✗
44	✗
45	✗
46	✗
47	✗
48	✗
49	✓
50	✗
51	✗
52	✓
53	✗
54	✗
55	✓
56	✗
57	✗

58	✓
59	✗
60	✓
61	✗
62	✗
63	✗
64	✗
65	✗
66	✗
67	✗
68	✗
69	✗
70	✗
71	✗
72	✗
73	✗
74	✗
75	✓
76	✗
77	✗
78	✗
79	✓
80	✗
81	✗
82	✓
83	✗
84	✗
85	✗
86	✗
87	✗
88	✗
89	✗
90	✗
91	✗
92	✗
93	✓

94	✗
95	✓
96	✗
97	✗
98	✗
99	✗
100	✗
101	✗
102	✗
103	✓
104	✗
105	✗
106	✓
107	✗
108	✗
109	✗
110	✗
111	-

All contents of this site are © 2024 Passmedicine Limited

A 46-year-old gentleman was referred by his GP to the respiratory clinic with deteriorating asthma control. He was diagnosed by his GP 2 years ago following complaints of feeling short of breath on exertion with wheeziness. Unfortunately, his symptoms deteriorated despite a trial of Clenil modulate 1000mcg BD, salmeterol 200mcg BD and montelukast 10mg OD. Upon further questioning, he stated that he had pins and needles in both hands as well as numbness of his fingertips for the last few weeks. His past medical history included hypertension, gout and sinusitis for which he was prescribed ramipril 5mg OD, allopurinol 100mg OD, salbutamol PRN and mometasone nasal spray 50mcg BD. He smoked 20 cigarettes per day and consumed 12 units of alcohol per week.

On examination, he appeared unwell. His heart rate was 98 bpm, respiratory rate 18/min, oxygen saturations 94% on air and blood pressure 146/82 mmHg. His heart sounds were normal with a normal JVP and examination of the chest revealed bilateral expiratory wheezes globally. Examination of the abdomen was normal. Examination of the peripheral nervous system demonstrated a peripheral neuropathy with a glove and stocking sensory loss of the upper limbs. Examination of the skin revealed the presence of purpura on his lower legs.

Initial investigations revealed the following results:

Hb	102 g/l
Platelets	342 * 10^9/l
WBC	12.1 * 10^9/l
	Neutrophils 82% count Lymphocytes 7% count Eosinophils 10% count Monocytes 1% count
ESR	42 mm/hr

Na^+	141 mmol/l
K^+	3.9 mmol/l
Urea	6.2 mmol/l
Creatinine	78 µmol/l

Chest x-ray: bilateral scattered pulmonary shadowing in lower zones
ECG: heart rate 97bpm, normal sinus rhythm, QRS interval 112ms, QTc interval 424ms

Which of the following tests is most likely to lead to the underlying diagnosis?

- Anti glomerular basement membrane antibodies
- p-ANCA antibodies
- ANA antibodies
- Anti Jo-1 antibodies
- c-ANCA antibodies

Submit answer

Reference ranges

Score: **16%**

1	✗
2	✗
3	✗
4	✗
5	✗
6	✗
7	✗
8	✗
9	✗
10	✗
11	✗
12	✓
13	✗
14	✗
15	✗
16	✗

17	✗
18	✗
19	✗
20	✗
21	✗
22	✗
23	✓
24	✗
25	✗
26	✗
27	✗
28	✗
29	✓
30	✗
31	✓
32	✗
33	✗
34	✗
35	✗
36	✓
37	✓
38	✗
39	✗
40	✗
41	✓
42	✗
43	✗
44	✗
45	✗
46	✗
47	✗
48	✗
49	✓
50	✗
51	-
52	-

```
-
-
-
-
-
-
-
-
-
-
-
-
-
-
-
-
-
-
-
-
-
-
-
-
-
-
-
-
-
-
-
-
-
-
-
-
-
-
-
-
```

93 -
94 -
95 -
96 -
97 -
98 -
99 -
100 -
101 -
102 -
103 -
104 -
105 -

All contents of this site are © 2024 Passmedicine Limited

Back to top

A 46-year-old gentleman was referred by his GP to the respiratory clinic with deteriorating asthma control. He was diagnosed by his GP 2 years ago following complaints of feeling short of breath on exertion with wheeziness. Unfortunately, his symptoms deteriorated despite a trial of Clenil modulate 1000mcg BD, salmeterol 200mcg BD and montelukast 10mg OD. Upon further questioning, he stated that he had pins and needles in both hands as well as numbness of his fingertips for the last few weeks. His past medical history included hypertension, gout and sinusitis for which he was prescribed ramipril 5mg OD, allopurinol 100mg OD, salbutamol PRN and mometasone nasal spray 50mcg BD. He smoked 20 cigarettes per day and consumed 12 units of alcohol per week.

On examination, he appeared unwell. His heart rate was 98 bpm, respiratory rate 18/min, oxygen saturations 94% on air and blood pressure 146/82 mmHg. His heart sounds were normal with a normal JVP and examination of the chest revealed bilateral expiratory wheezes globally. Examination of the abdomen was normal. Examination of the peripheral nervous system demonstrated a peripheral neuropathy with a glove and stocking sensory loss of the upper limbs. Examination of the skin revealed the presence of purpura on his lower legs.

Initial investigations revealed the following results:

Hb	102 g/l
Platelets	342 * 10^9/l
WBC	12.1 * 10^9/l
	Neutrophils 82% count Lymphocytes 7% count Eosinophils 10% count Monocytes 1% count
ESR	42 mm/hr

Na^+	141 mmol/l
K^+	3.9 mmol/l
Urea	6.2 mmol/l
Creatinine	78 µmol/l

Chest x-ray: bilateral scattered pulmonary shadowing in lower zones
ECG: heart rate 97bpm, normal sinus rhythm, QRS interval 112ms, QTc interval 424ms

Which of the following tests is most likely to lead to the underlying diagnosis?

Anti glomerular basement membrane antibodies	3%
p-ANCA antibodies	78%
ANA antibodies	2%
Anti Jo-1 antibodies	3%
c-ANCA antibodies	14%

Churg-Strauss syndrome - positive pANCA serology

Important for me Less important

This gentleman presents with a combination of worsening asthma in combination with sinusitis. He has pulmonary infiltrates on his chest x-ray, as well as polyneuropathy and an eosinophilia. The diagnosis is strongly suggestive of Churg-Strauss syndrome, and of the following options, p-ANCA antibodies are the most sensitive and specific to this condition.

Discuss (5) Improve

Next question

Eosinophilic granulomatosis with polyangiitis (Churg-Strauss syndrome)

Eosinophilic granulomatosis with polyangiitis (EGPA) is now the preferred term for **Churg-Strauss syndrome**. It is an ANCA associated small-medium vessel vasculitis.

Features

- asthma
- blood eosinophilia (e.g. > 10%)
- paranasal sinusitis
- mononeuritis multiplex
- pANCA positive in 60%

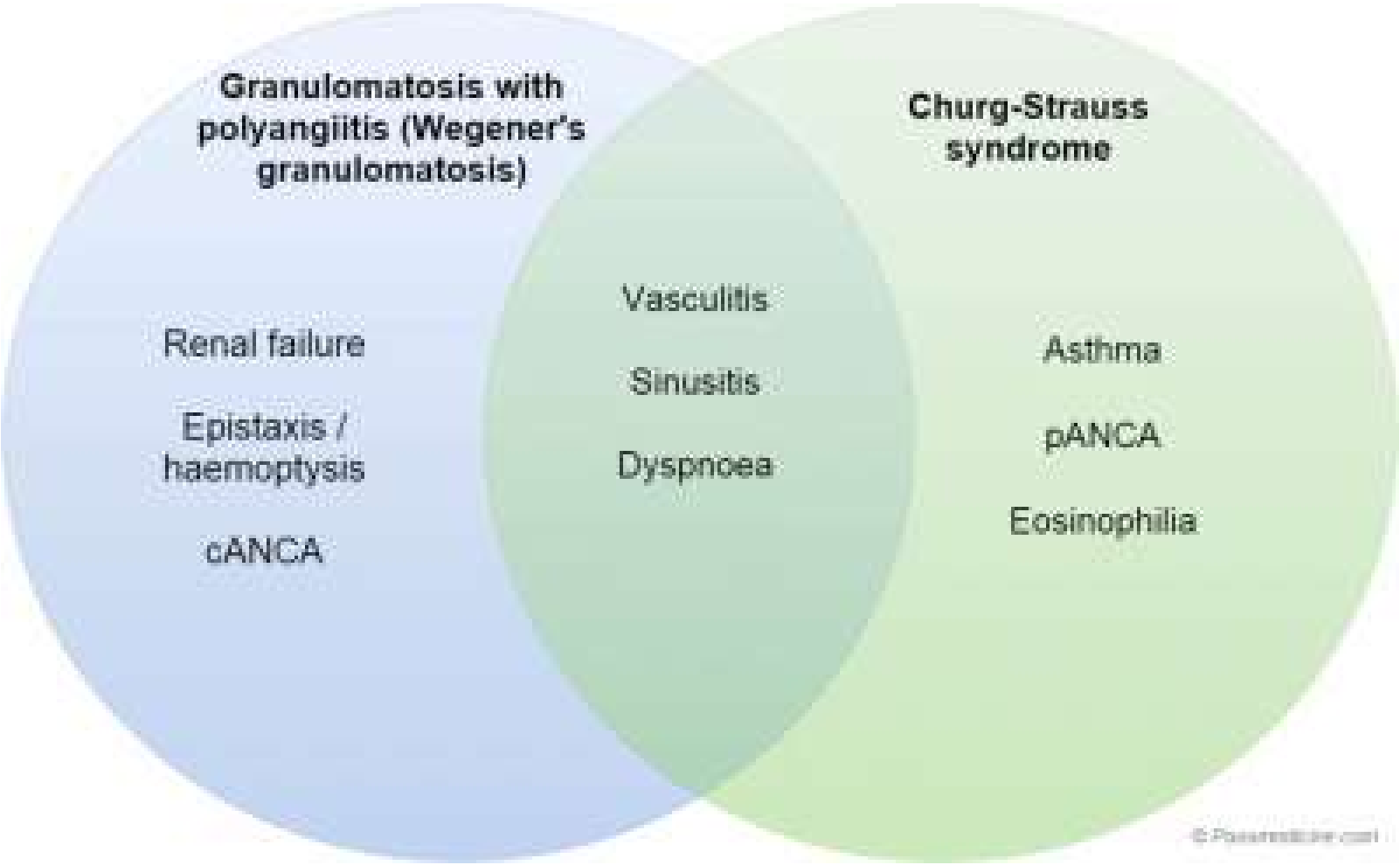

Comparison of granulomatosis with polyangiitis and Churg-Strauss syndrome

Leukotriene receptor antagonists may precipitate the disease.

123

Next question

Textbooks

High-yield textbook

Extended textbook

Media

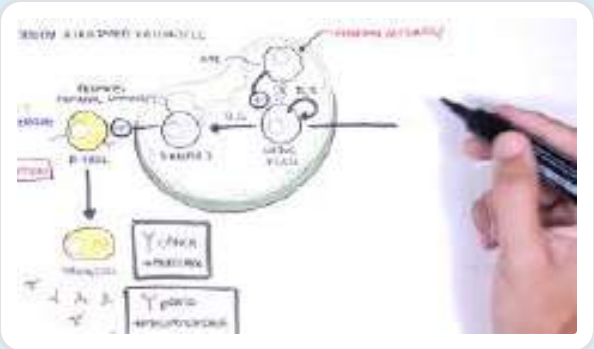

ANCA (Anti-Neutrophil Cytoplasmic Antibody) Associated Vasculitis - Causes, Pathophysiology, Types

Armando Hasudungan - YouTube

3 3

Report broken media

Score: **17.3%**

1	✗
2	✗
3	✗
4	✗
5	✗
6	✗
7	✗
8	✗
9	✗
10	✗
11	✗
12	✓
13	✗
14	✗
15	✗
16	✗
17	✗
18	✗
19	✗
20	✗
21	✗
22	✗
23	✓
24	✗
25	✗
26	✗
27	✗
28	✗

29	✓
30	✗
31	✓
32	✗
33	✗
34	✗
35	✗
36	✓
37	✓
38	✗
39	✗
40	✗
41	✓
42	✗
43	✗
44	✗
45	✗
46	✗
47	✗
48	✗
49	✓
50	✗
51	✗
52	✓
53	✗
54	✗
55	✓
56	✗
57	✗
58	✓
59	✗
60	✓
61	✗
62	✗
63	✗
64	✗

65	✗
66	✗
67	✗
68	✗
69	✗
70	✗
71	✗
72	✗
73	✗
74	✗
75	✓
76	✗
77	✗
78	✗
79	✓
80	✗
81	✗
82	✓
83	✗
84	✗
85	✗
86	✗
87	✗
88	✗
89	✗
90	✗
91	✗
92	✗
93	✓
94	✗
95	✓
96	✗
97	✗
98	✗
99	✗
100	✗

101	✗
102	✗
103	✓
104	✗
105	✗
106	✓
107	✗
108	✗
109	✗
110	✗
111	-

All contents of this site are © 2024 Passmedicine Limited

A 62-year-old gentleman is seen at the respiratory clinic after a mass lesion is identified by his GP on chest x-ray. He is a heavy smoker and has had a cough and weight loss for the past two months. On further questioning, he admits to feeling very weak and is having difficulty getting out of a chair. On examination, the consultant notices some proximal muscle wasting. Initial investigations reveal a blood pressure of 170/90mmHg and a low potassium. In addition to organising staging CT and bronchoscopy, he requests a 24-hour urinary cortisol test, which is raised.

Which of the following is the most likely underlying pathology?

- Squamous cell bronchial carcinoma
- Large cell bronchial carcinoma
- Carcinoid tumour
- Small cell bronchial carcinoma
- Bronchial adenocarcinoma

Submit answer

Reference ranges

Score: **16%**

1 ✗
2 ✗
3 ✗
4 ✗
5 ✗

6	✗
7	✗
8	✗
9	✗
10	✗
11	✗
12	✓
13	✗
14	✗
15	✗
16	✗
17	✗
18	✗
19	✗
20	✗
21	✗
22	✗
23	✓
24	✗
25	✗
26	✗
27	✗
28	✗
29	✓
30	✗
31	✓
32	✗
33	✗
34	✗
35	✗
36	✓
37	✓
38	✗
39	✗
40	✗
41	✓

42	✗
43	✗
44	✗
45	✗
46	✗
47	✗
48	✗
49	✓
50	✗
51	-
52	-
53	-
54	-
55	-
56	-
57	-
58	-
59	-
60	-
61	-
62	-
63	-
64	-
65	-
66	-
67	-
68	-
69	-
70	-
71	-
72	-
73	-
74	-
75	-
76	-
77	-
78	-
79	-
80	-

81 -
82 -
83 -
84 -
85 -
86 -
87 -
88 -
89 -
90 -
91 -
92 -
93 -
94 -
95 -
96 -
97 -
98 -
99 -
100 -
101 -
102 -
103 -
104 -
105 -
106 -

All contents of this site are © 2024 Passmedicine Limited
Back to top

A 62-year-old gentleman is seen at the respiratory clinic after a mass lesion is identified by his GP on chest x-ray. He is a heavy smoker and has had a cough and weight loss for the past two months. On further questioning, he admits to feeling very weak and is having difficulty getting out of a chair. On examination, the consultant notices some proximal muscle wasting. Initial investigations reveal a blood pressure of 170/90mmHg and a low potassium. In addition to organising staging CT and bronchoscopy, he requests a 24-hour urinary cortisol test, which is raised.

Which of the following is the most likely underlying pathology?

Squamous cell bronchial carcinoma	11%
Large cell bronchial carcinoma	1%
Carcinoid tumour	4%
Small cell bronchial carcinoma	82%
Bronchial adenocarcinoma	2%

The 24-hour urinary cortisol result here suggests a diagnosis of Cushing's syndrome. The co-existant presentation of lung cancer points to paraneoplastic Cushing's syndrome. The vast majority of paraneoplastic syndromes seen in lung cancer are caused by small cell bronchial carcinoma, a neuroendocrine tumour which can secrete a variety of hormones or antibodies. In paraneoplastic Cushing's syndrome, ectopic adrenocorticotrophic hormone (ACTH) production results in a syndrome characterised by muscle weakness, hypertension, hypokalaemia and oedema. The classical features of buffalo hump and moon face are often absent.

Pelosof, Lorraine C., and David E. Gerber. Paraneoplastic Syndromes: An Approach to Diagnosis and Treatment. Mayo Clinic Proceedings 85.9 (2010): 838854. PMC. Web. 24 Apr. 2015.

Discuss (1) | Improve

Next question

Lung cancer: small cell

Features

- usually central
- arise from APUD* cells
- associated with ectopic ADH, ACTH secretion
- ADH → hyponatraemia
- ACTH → Cushing's syndrome
- ACTH secretion can cause bilateral adrenal hyperplasia, the high levels of cortisol can lead to hypokalaemic alkalosis
- Lambert-Eaton syndrome: antibodies to voltage gated calcium channels causing myasthenic like syndrome

Management

- usually metastatic disease by time of diagnosis
- patients with very early stage disease (T1-2a, N0, M0) are now considered for surgery. NICE support this approach in their 2011 guidelines
- however, most patients with limited disease receive a combination of chemotherapy and radiotherapy
- patients with more extensive disease are offered palliative chemotherapy

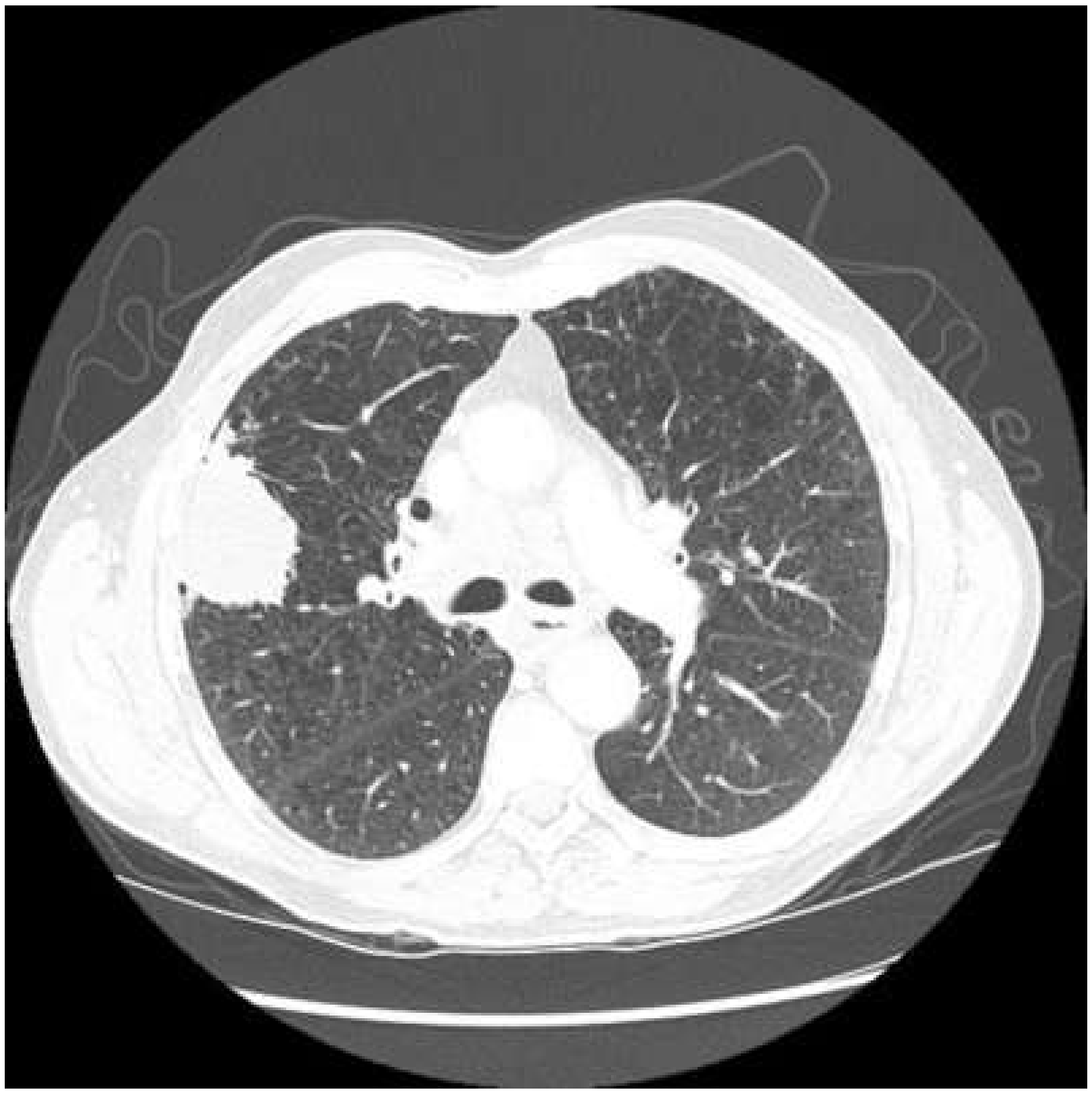

© Image used on license from Radiopaedia

CT scan showing small cell lung cancer with multiple pulmonary nodules and extensive mediastinal nodal metastases.

*an acronym for

- Amine - high amine content
- Precursor Uptake - high uptake of amine precursors
- Decarboxylase - high content of the enzyme decarboxylase

123

Next question

Textbooks

High-yield textbook

Extended textbook

Links

SIGN 3 5

2014 Lung cancer management guidelines

NICE 4 4

2011 Lung cancer guidelines

Suggest link

Report broken link

Media

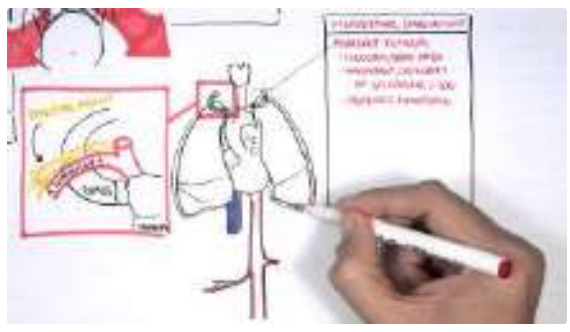

[Lung cancer]

Armando Hasudungan - YouTube 👍 1 👎 0

[Lung cancer]

MedFlix - YouTube 👍 1 👎 0

[Lung Cancer: An Overview]

Oncology for Medical Students - YouTube 👍 1 👎 0

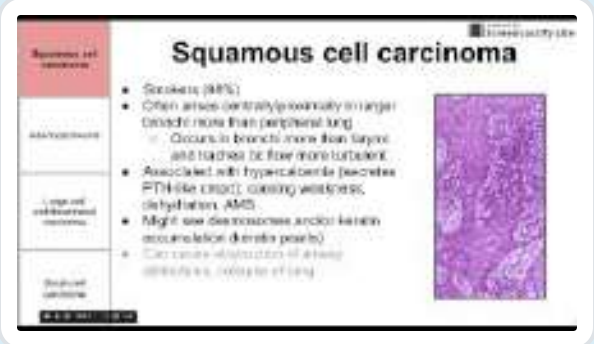

[Cancers of the lung]

MedLecturesMadeEasy - YouTube 👍 3 👎 2

Report broken media

Score: **17.3%**

1 ✗
2 ✗
3 ✗
4 ✗
5 ✗
6 ✗
7 ✗

8	✗
9	✗
10	✗
11	✗
12	✓
13	✗
14	✗
15	✗
16	✗
17	✗
18	✗
19	✗
20	✗
21	✗
22	✗
23	✓
24	✗
25	✗
26	✗
27	✗
28	✗
29	✓
30	✗
31	✓
32	✗
33	✗
34	✗
35	✗
36	✓
37	✓
38	✗
39	✗
40	✗
41	✓
42	✗
43	✗

44	✗
45	✗
46	✗
47	✗
48	✗
49	✓
50	✗
51	✗
52	✓
53	✗
54	✗
55	✓
56	✗
57	✗
58	✓
59	✗
60	✓
61	✗
62	✗
63	✗
64	✗
65	✗
66	✗
67	✗
68	✗
69	✗
70	✗
71	✗
72	✗
73	✗
74	✗
75	✓
76	✗
77	✗
78	✗
79	✓

80	✗
81	✗
82	✓
83	✗
84	✗
85	✗
86	✗
87	✗
88	✗
89	✗
90	✗
91	✗
92	✗
93	✓
94	✗
95	✓
96	✗
97	✗
98	✗
99	✗
100	✗
101	✗
102	✗
103	✓
104	✗
105	✗
106	✓
107	✗
108	✗
109	✗
110	✗
111	-

All contents of this site are © 2024 Passmedicine Limited

A 29-year-old man presents to his GP with shortness of breath. This has been occurring for the past 6 months and is sometimes accompanied by wheezing, particularly later on during the day. He does not have any past medical history and occasionally takes over-the-counter antihistamines for hay-fever. His only recent travel history is a holiday to Greece, where he found he was less short of breath and he was less wheezy. His only family history of note is his mother who died of a heart attack aged 65. He works as a car mechanic and smokes 5 roll-up cigarettes per day and drinks on average 5-6 units of alcohol per week.

Examination of the chest is normal with good air entry bilaterally and no added sounds. Heart sounds I and II are present with no obvious murmurs.

What is the most useful investigation in determining this man's diagnosis?

- Chest x-ray
- Peak expiratory flow rate measurements at both home and at work
- Pulmonary function testing
- Serum IgE measurement
- Skin prick testing

Submit answer

Reference ranges

Score: **16%**

1 ✕
2 ✕
3 ✕

4	✗
5	✗
6	✗
7	✗
8	✗
9	✗
10	✗
11	✗
12	✓
13	✗
14	✗
15	✗
16	✗
17	✗
18	✗
19	✗
20	✗
21	✗
22	✗
23	✓
24	✗
25	✗
26	✗
27	✗
28	✗
29	✓
30	✗
31	✓
32	✗
33	✗
34	✗
35	✗
36	✓
37	✓
38	✗
39	✗

40	✗
41	✓
42	✗
43	✗
44	✗
45	✗
46	✗
47	✗
48	✗
49	✓
50	✗
51	-
52	-
53	-
54	-
55	-
56	-
57	-
58	-
59	-
60	-
61	-
62	-
63	-
64	-
65	-
66	-
67	-
68	-
69	-
70	-
71	-
72	-
73	-
74	-
75	-
76	-
77	-
78	-

79 -
80 -
81 -
82 -
83 -
84 -
85 -
86 -
87 -
88 -
89 -
90 -
91 -
92 -
93 -
94 -
95 -
96 -
97 -
98 -
99 -
100 -
101 -
102 -
103 -
104 -
105 -
106 -
107 -

All contents of this site are © 2024 Passmedicine Limited
Back to top

A 29-year-old man presents to his GP with shortness of breath. This has been occurring for the past 6 months and is sometimes accompanied by wheezing, particularly later on during the day. He does not have any past medical history and occasionally takes over-the-counter antihistamines for hay-fever. His only recent travel history is a holiday to Greece, where he found he was less short of breath and he was less wheezy. His only family history of note is his mother who died of a heart attack aged 65. He works as a car mechanic and smokes 5 roll-up cigarettes per day and drinks on average 5-6 units of alcohol per week.

Examination of the chest is normal with good air entry bilaterally and no added sounds. Heart sounds I and II are present with no obvious murmurs.

What is the most useful investigation in determining this man's diagnosis?

Chest x-ray	1%
Peak expiratory flow rate measurements at both home and at work	87%
Pulmonary function testing	5%
Serum IgE measurement	5%
Skin prick testing	2%

The most likely diagnosis in this case is occupational asthma, as demonstrated by the timing of his breathlessness and wheeze as well as the improvement in symptoms when on holiday. The diagnosis of occupational asthma is best determined using peak expiratory flow rate measurements taken at home and work to determine the difference in the two - following this further investigation scan be performed to determine the allergen causing the occupational asthma.

Asthma: occupational

Patients may either present with concerns that chemicals at work are worsening their asthma or you may notice in the history that symptoms seem better at weekends / when away from work.

Exposure to the following chemicals is associated with occupational asthma:

- isocyanates - the most common cause
    - example occupations include spray painting and foam moulding using adhesives
- platinum salts
- soldering flux resin
- glutaraldehyde
- flour
- epoxy resins
- proteolytic enzymes

Serial measurements of peak expiratory flow are recommended at work and away from work.

Referral should be made to a respiratory specialist for patients with suspected occupational asthma.

+ Q 123

Next question

Textbooks

High-yield textbook

Extended textbook

Links

British Thoracic Society 9 3

2019 Asthma guidelines

Suggest link | Report broken link

Score: **17.3%**

1	✗
2	✗
3	✗
4	✗
5	✗
6	✗
7	✗
8	✗
9	✗
10	✗
11	✗
12	✓
13	✗
14	✗
15	✗
16	✗
17	✗
18	✗
19	✗
20	✗
21	✗
22	✗
23	✓
24	✗
25	✗
26	✗
27	✗
28	✗

29	✓
30	✗
31	✓
32	✗
33	✗
34	✗
35	✗
36	✓
37	✓
38	✗
39	✗
40	✗
41	✓
42	✗
43	✗
44	✗
45	✗
46	✗
47	✗
48	✗
49	✓
50	✗
51	✗
52	✓
53	✗
54	✗
55	✓
56	✗
57	✗
58	✓
59	✗
60	✓
61	✗
62	✗
63	✗
64	✗

65	✗
66	✗
67	✗
68	✗
69	✗
70	✗
71	✗
72	✗
73	✗
74	✗
75	✓
76	✗
77	✗
78	✗
79	✓
80	✗
81	✗
82	✓
83	✗
84	✗
85	✗
86	✗
87	✗
88	✗
89	✗
90	✗
91	✗
92	✗
93	✓
94	✗
95	✓
96	✗
97	✗
98	✗
99	✗
100	✗

101	✗
102	✗
103	✓
104	✗
105	✗
106	✓
107	✗
108	✗
109	✗
110	✗
111	-

All contents of this site are © 2024 Passmedicine Limited

A 55-year-old woman with poorly-controlled type 2 diabetes and a 50-pack-year smoking history presents to the Emergency Department with a three-day history of fever and productive cough. A chest radiograph shows right middle lobe pneumonia. She is prescribed a course of oral antibiotics and is discharged home.

She is reviewed in respiratory clinic two months later and has an ongoing dry cough.

What single investigation would be most appropriate to request during her consultation?

- Arterial blood gas measurement
- Pulmonary function tests
- Referral for CT thorax
- Repeat chest radiograph
- Sputum culture

Submit answer

Reference ranges

Score: **16%**

1 ✕
2 ✕
3 ✕
4 ✕
5 ✕
6 ✕

7	✗
8	✗
9	✗
10	✗
11	✗
12	✓
13	✗
14	✗
15	✗
16	✗
17	✗
18	✗
19	✗
20	✗
21	✗
22	✗
23	✓
24	✗
25	✗
26	✗
27	✗
28	✗
29	✓
30	✗
31	✓
32	✗
33	✗
34	✗
35	✗
36	✓
37	✓
38	✗
39	✗
40	✗
41	✓
42	✗

43	✗
44	✗
45	✗
46	✗
47	✗
48	✗
49	✓
50	✗
51	-
52	-
53	-
54	-
55	-
56	-
57	-
58	-
59	-
60	-
61	-
62	-
63	-
64	-
65	-
66	-
67	-
68	-
69	-
70	-
71	-
72	-
73	-
74	-
75	-
76	-
77	-
78	-
79	-
80	-
81	-

82 -
83 -
84 -
85 -
86 -
87 -
88 -
89 -
90 -
91 -
92 -
93 -
94 -
95 -
96 -
97 -
98 -
99 -
100 -
101 -
102 -
103 -
104 -
105 -
106 -
107 -
108 -

All contents of this site are © 2024 Passmedicine Limited
Back to top

A 55-year-old woman with poorly-controlled type 2 diabetes and a 50-pack-year smoking history presents to the Emergency Department with a three-day history of fever and productive cough. A chest radiograph shows right middle lobe pneumonia. She is prescribed a course of oral antibiotics and is discharged home.

She is reviewed in respiratory clinic two months later and has an ongoing dry cough.

What single investigation would be most appropriate to request during her consultation?

Arterial blood gas measurement	1%
Pulmonary function tests	10%
Referral for CT thorax	17%
Repeat chest radiograph	69%
Sputum culture	3%

All cases of pneumonia should have a repeat chest X-ray at 6 weeks after clinical resolution

Important for me Less important

This patient had lobar pneumonia and **a repeat chest radiograph should be arranged after about six weeks** for all patients with persistent symptoms, physical signs or at higher risk of malignancy such as smokers or older adults aged over 50 years old. Further investigation may be offered depending on their symptoms and radiology to rule out the presence of other conditions including malignancy. Although this patient does have a persistent cough, patients may take three to six months to feel back to normal and it would be most appropriate to request a chest radiograph first before any other radiological tests.

Arterial blood gas measurement is useful in patients with chronic lung disease to determine if they have chronic hypoxaemia. Such patients may be offered long-term oxygen therapy (LTOT) to improve survival. However, this patient does not have a diagnosis of chronic lung disease. Furthermore, if she continues smoking, it would not be appropriate to offer oxygen therapy as it is a fire hazard.

Pulmonary function tests such as spirometry should be offered to patients who smoke who have

symptoms such as breathlessness, chronic cough, significant sputum production, wheeze and frequent chest infections. However, it would not be as important as ensuring her pneumonia has resolved or that lung cancer is not missed.

A **CT thorax** would be appropriate in patients with persistent changes on a repeat chest radiograph, or those with a normal chest radiograph but persistent symptoms. However, a chest radiograph should be repeated before a CT due to the high radiation dose involved.

Sputum culture may be helpful if the patient remains productive or if her symptoms fail to resolve with initial antibiotic therapy as she may have an atypical organism causing her chest infection, such as *Pseudomonas*. However, given that her cough is now dry this is unlikely to be feasible. A repeat chest radiograph would be more helpful in determining the possible causes of her symptoms in the first instance.

Discuss (3) Improve

Next question

Pneumonia: assessment and management

Primary care setting

NICE recommends that patients should initially be assessed in primary care using the CRB65 criteria:

Criterion	Marker
C	Confusion (abbreviated mental test score <= 8/10)
R	Respiration rate >= 30/min
B	Blood pressure: systolic <= 90 mmHg and/or diastolic <= 60 mmHg
65	Aged >= 65 years

Patients are stratified for risk of death as follows:

- 0: low risk (less than 1% mortality risk)
    - NICE recommend that treatment at home should be considered (alongside clinical judgement)

- 1 or 2: intermediate risk (1-10% mortality risk)
    - NICE recommend that ' hospital assessment should be considered (particularly for people with a score of 2)'
- 3 or 4: high risk (more than 10% mortality risk)
    - NICE recommend urgent admission to hospital

NICE also mention point-of-care CRP test. This is currently not widely available but they make the following recommendation with reference to the use of antibiotic therapy:
- CRP < 20 mg/L - do not routinely offer antibiotic therapy
- CRP 20 - 100 mg/L - consider a delayed antibiotic prescription
- CRP > 100 mg/L - offer antibiotic therapy

Secondary care setting

Note that in hospital, once blood tests are available the CURB65, rather than the CRB65, can be used. This adds an extra criterion of urea > 7 mmol/L:

Criterion	Marker
C	Confusion (abbreviated mental test score <= 8/10)
U	urea > 7 mmol/L
R	Respiration rate >= 30/min
B	Blood pressure: systolic <= 90 mmHg and/or diastolic <= 60 mmHg
65	Aged >= 65 years

NICE recommend, in conjunction with clinical judgement:
- consider home-based care for patients with a CURB65 score of 0 or 1 - low risk (less than 3% mortality risk)
- consider hospital-based care for patients with a CURB65 score of 2 or more - intermediate risk (3-15% mortality risk)
- consider intensive care assessment for patients with a CURB65 score of 3 or more - high risk (more than 15% mortality risk)

Investigations
- chest x-ray

- in intermediate or high-risk patients NICE recommend blood and sputum cultures, pneumococcal and legionella urinary antigen tests
- CRP monitoring is recommend for admitted patients to help determine response to treatment

Management of low-severity community acquired pneumonia

- amoxicillin is first-line
- if penicillin allergic then use a macrolide or tetracycline
- NICE now recommend a 5 day course of antibiotics for patients with low severity community acquired pneumonia

Management of moderate and high-severity community acquired pneumonia

- dual antibiotic therapy is recommended with amoxicillin and a macrolide
- a 7-10 day course is recommended
- NICE recommend considering a beta-lactamase stable penicillin such as co-amoxiclav, ceftriaxone or piperacillin with tazobactam and a macrolide in high-severity community acquired pneumonia

Discharge criteria and advice post-discharge

NICE recommend that patients are not routinely discharged if in the past 24 hours they have had 2 or more of the following findings:

- temperature higher than 37.5°C
- respiratory rate 24 breaths per minute or more
- heart rate over 100 beats per minute
- systolic blood pressure 90 mmHg or less
- oxygen saturation under 90% on room air
- abnormal mental status
- inability to eat without assistance.

They also recommend delaying discharge if the temperature is higher than 37.5°C.

NICE recommend that the following information is given to patients with pneumonia in terms of how quickly their symptoms should symptoms should resolve:

Time	Progress
1 week	Fever should have resolved
4 weeks	Chest pain and sputum production should have substantially reduced

Time	Progress
6 weeks	Cough and breathlessness should have substantially reduced
3 months	Most symptoms should have resolved but fatigue may still be present
6 months	Most people will feel back to normal.

All cases of pneumonia should have a repeat chest X-ray at 6 weeks after clinical resolution to ensure that the consolidation has resolved and there is no underlying secondary abnormalities (e.g. a lung tumour).

+ Q 123

Next question >

B I A

Textbooks

High-yield textbook

Extended textbook

Links

NICE 16 11

2014 Pneumonia in adults: diagnosis and management

Clinical Knowledge Summaries 14 7

Community-acquired pneumonia

MDCalc

17 5

[CURB-65 scoring tool]

Suggest link | Report broken link

Media

Pneumonia

Osmosis - YouTube 4 0

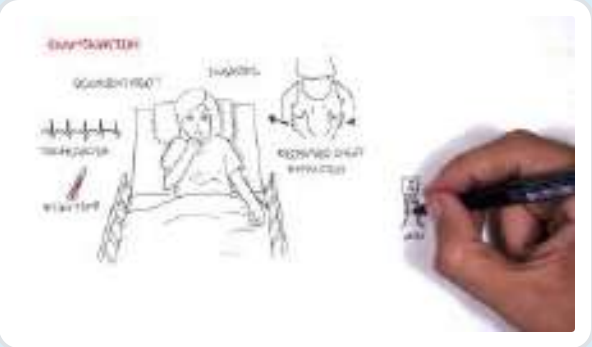

Community Acquired Pneumonia

Armando Hasudungan - YouTube 3 0

Report broken media

Score: **17.3%**

1 ✕
2 ✕
3 ✕
4 ✕
5 ✕
6 ✕
7 ✕
8 ✕
9 ✕
10 ✕
11 ✕

12 ✓
13 ✗
14 ✗
15 ✗
16 ✗
17 ✗
18 ✗
19 ✗
20 ✗
21 ✗
22 ✗
23 ✓
24 ✗
25 ✗
26 ✗
27 ✗
28 ✗
29 ✓
30 ✗
31 ✓
32 ✗
33 ✗
34 ✗
35 ✗
36 ✓
37 ✓
38 ✗
39 ✗
40 ✗
41 ✓
42 ✗
43 ✗
44 ✗
45 ✗
46 ✗
47 ✗

48	✗
49	✓
50	✗
51	✗
52	✓
53	✗
54	✗
55	✓
56	✗
57	✗
58	✓
59	✗
60	✓
61	✗
62	✗
63	✗
64	✗
65	✗
66	✗
67	✗
68	✗
69	✗
70	✗
71	✗
72	✗
73	✗
74	✗
75	✓
76	✗
77	✗
78	✗
79	✓
80	✗
81	✗
82	✓
83	✗

84	✗
85	✗
86	✗
87	✗
88	✗
89	✗
90	✗
91	✗
92	✗
93	✓
94	✗
95	✓
96	✗
97	✗
98	✗
99	✗
100	✗
101	✗
102	✗
103	✓
104	✗
105	✗
106	✓
107	✗
108	✗
109	✗
110	✗
111	-

All contents of this site are © 2024 Passmedicine Limited

A 45-year-old is referred to a respiratory clinic with 2 months of exertional shortness of breath. He has a past medical history of HIV. He is well controlled on Truvada. He has had an unprovoked pulmonary embolism three years ago and was treated with six months of warfarin. He smokes 15 cigarettes daily for the last 20 years. He recently completed his first mountaineering expedition and successfully reached the summit of Kilimanjaro.

On examination, there is a loud P2. The jugular venous pulse is raised and there is peripheral oedema. Chest auscultation is unremarkable and there are no murmurs.

A transthoracic echocardiogram is arranged, which demonstrates a mean pulmonary arterial pressure (PAPm) of 38 mmHg and mitral regurgitation with a regurgitant fraction of 14%.

An HRCT chest is normal. V/Q scanning demonstrates mismatched perfusion defects. The patient is referred for a right heart catheter, which confirms a PAPm of 38mmHg and also demonstrates a pulmonary arterial wedge pressure (PAWP) of 11 mmHg.

Given the likely diagnosis, what is the probable underlying aetiology?

- COPD
- Chronic thromboembolic disease
- HIV
- High altitude exposure
- Mitral regurgitation

Submit answer

Reference ranges

Score: **16%**

1	✗
2	✗
3	✗
4	✗
5	✗
6	✗
7	✗
8	✗
9	✗
10	✗
11	✗
12	✓
13	✗
14	✗
15	✗
16	✗
17	✗
18	✗
19	✗
20	✗
21	✗
22	✗
23	✓
24	✗
25	✗
26	✗
27	✗
28	✗
29	✓
30	✗
31	✓
32	✗
33	✗
34	✗

35	✗
36	✓
37	✓
38	✗
39	✗
40	✗
41	✓
42	✗
43	✗
44	✗
45	✗
46	✗
47	✗
48	✗
49	✓
50	✗
51	-
52	-
53	-
54	-
55	-
56	-
57	-
58	-
59	-
60	-
61	-
62	-
63	-
64	-
65	-
66	-
67	-
68	-
69	-
70	-
71	-
72	-

73	-
74	-
75	-
76	-
77	-
78	-
79	-
80	-
81	-
82	-
83	-
84	-
85	-
86	-
87	-
88	-
89	-
90	-
91	-
92	-
93	-
94	-
95	-
96	-
97	-
98	-
99	-
100	-
101	-
102	-
103	-
104	-
105	-
106	-
107	-
108	-
109	-

All contents of this site are © 2024 Passmedicine Limited

Back to top

A 45-year-old is referred to a respiratory clinic with 2 months of exertional shortness of breath. He has a past medical history of HIV. He is well controlled on Truvada. He has had an unprovoked pulmonary embolism three years ago and was treated with six months of warfarin. He smokes 15 cigarettes daily for the last 20 years. He recently completed his first mountaineering expedition and successfully reached the summit of Kilimanjaro.

On examination, there is a loud P2. The jugular venous pulse is raised and there is peripheral oedema. Chest auscultation is unremarkable and there are no murmurs.

A transthoracic echocardiogram is arranged, which demonstrates a mean pulmonary arterial pressure (PAPm) of 38 mmHg and mitral regurgitation with a regurgitant fraction of 14%.

An HRCT chest is normal. V/Q scanning demonstrates mismatched perfusion defects. The patient is referred for a right heart catheter, which confirms a PAPm of 38mmHg and also demonstrates a pulmonary arterial wedge pressure (PAWP) of 11 mmHg.

Given the likely diagnosis, what is the probable underlying aetiology?

COPD	7%
Chronic thromboembolic disease	58%
HIV	11%
High altitude exposure	16%
Mitral regurgitation	7%

Chronic pulmonary embolisms can lead to pulmonary hypertension

Important for me Less important

Chronic thromboembolic disease is the correct answer. The patient has pulmonary hypertension as evidenced by the clinical features and right heart catheter results (PAPm > =25mmHg). The patient has a history of pulmonary embolism and has been appropriately treated with warfarin for six months given his unprovoked VTE. However, the V/Q scan demonstrates mismatched perfusion defects suggesting chronic thromboembolic disease. This is therefore the most likely cause of pulmonary hypertension in this case.

COPD is incorrect. This is a cause of pulmonary hypertension. However, this is only seen in severe COPD. In a patient who has recently scaled a mountain and has a normal HRCT chest, COPD is unlikely.

HIV is incorrect. This is a cause of pulmonary hypertension. However, given he is well controlled on Truvada, this is slightly less likely in general. Additionally, it would not explain the mismatched perfusion defects on V/Q scanning and therefore it is a less likely cause than a chronic thromboembolic disease.

High altitude exposure is incorrect. He has only completed one mountaineering expedition. High altitude exposure can cause pulmonary hypertension but this is typically in people chronically exposed, living at high altitudes.

Mitral regurgitation (MR) is incorrect. The patient does not have clinically severe mitral regurgitation and the echocardiography findings are that of mild MR (regurgitant fraction < 30%). Therefore this is not the likely cause of pulmonary hypertension.

Discuss (9) Improve

Next question

Pulmonary hypertension: causes and classification

Pulmonary hypertension may be defined as a sustained elevation in mean pulmonary arterial pressure of greater than 20 mmHg at rest. It has recently been reclassified by the WHO:

Group 1: Pulmonary arterial hypertension (PAH)
- idiopathic*
- familial
- associated conditions: collagen vascular disease, congenital heart disease with systemic to pulmonary shunts, HIV**, drugs and toxins, sickle cell disease
- persistent pulmonary hypertension of the newborn

Group 2: Pulmonary hypertension with left heart disease
- left-sided atrial, ventricular or valvular disease such as left ventricular systolic and diastolic dysfunction, mitral stenosis and mitral regurgitation

Group 3: Pulmonary hypertension secondary to lung disease/hypoxia
- COPD
- interstitial lung disease

- sleep apnoea
- high altitude

Group 4: Pulmonary hypertension due to thromboembolic disease

Group 5: Miscellaneous conditions
- lymphangiomatosis e.g. secondary to carcinomatosis or sarcoidosis

*previously termed primary pulmonary hypertension
**the mechanism by which HIV infection produces pulmonary hypertension remains unknown

AI + Q 123

Next question >

Textbooks

High-yield textbook

Extended textbook

Links

Medcomic 2 1

Pulmonary hypertension

Suggest link Report broken link

Media

Pulmonary hypertension

Osmosis - YouTube 5 0

Report broken media

Score: **17.3%**

1	✗
2	✗
3	✗
4	✗
5	✗
6	✗
7	✗
8	✗
9	✗
10	✗
11	✗
12	✓
13	✗
14	✗
15	✗
16	✗
17	✗
18	✗
19	✗
20	✗
21	✗
22	✗
23	✓
24	✗
25	✗
26	✗
27	✗

28	✗
29	✓
30	✗
31	✓
32	✗
33	✗
34	✗
35	✗
36	✓
37	✓
38	✗
39	✗
40	✗
41	✓
42	✗
43	✗
44	✗
45	✗
46	✗
47	✗
48	✗
49	✓
50	✗
51	✗
52	✓
53	✗
54	✗
55	✓
56	✗
57	✗
58	✓
59	✗
60	✓
61	✗
62	✗
63	✗

64	✗
65	✗
66	✗
67	✗
68	✗
69	✗
70	✗
71	✗
72	✗
73	✗
74	✗
75	✓
76	✗
77	✗
78	✗
79	✓
80	✗
81	✗
82	✓
83	✗
84	✗
85	✗
86	✗
87	✗
88	✗
89	✗
90	✗
91	✗
92	✗
93	✓
94	✗
95	✓
96	✗
97	✗
98	✗
99	✗

100	✗
101	✗
102	✗
103	✓
104	✗
105	✗
106	✓
107	✗
108	✗
109	✗
110	✗
111	-

All contents of this site are © 2024 Passmedicine Limited

A 62-year-old man, with a 40-year heavy smoking history, presents to the emergency department. He's been troubled by a cough for the last five months associated with constant fatigue and weight loss. He reports coughing up blood on the morning of presentation.

On physical examination, the patient looks emaciated with notable finger clubbing. Auscultation reveals diminished air entry over the left lung with occasional wheezes. No murmurs are heard.

His vital signs are as follows:

- Temperature: 37.1°C.
- Blood pressure: 115/75 mmHg.
- Heart rate: 101 beats/min, regular.
- Respiratory rate: 22 breaths/min.
- Oxygen saturation: 94 % on room air.

Labs are ordered and the results are the following:

Hb	125 g/L	Male: (135-180)
Platelets	680 * 10^9/L	(150 - 400)
WBC	9.5 * 10^9/L	(4.0 - 11.0)
Calcium	2.75 mmol/L	(2.1-2.6)

The chest x-ray is shown:

© Image used on license from Radiopaedia

What is the most likely diagnosis?

- Lung metastases
- Sarcoidosis
- Small cell lung cancer
- Squamous cell lung cancer
- Tuberculosis

Submit answer

Reference ranges

Score: **16%**

1	✗
2	✗
3	✗
4	✗
5	✗
6	✗
7	✗
8	✗
9	✗
10	✗
11	✗
12	✓
13	✗
14	✗
15	✗
16	✗
17	✗
18	✗
19	✗
20	✗
21	✗
22	✗
23	✓
24	✗
25	✗
26	✗
27	✗
28	✗
29	✓
30	✗
31	✓
32	✗
33	✗
34	✗
35	✗

36	✓
37	✓
38	✗
39	✗
40	✗
41	✓
42	✗
43	✗
44	✗
45	✗
46	✗
47	✗
48	✗
49	✓
50	✗
51	-
52	-
53	-
54	-
55	-
56	-
57	-
58	-
59	-
60	-
61	-
62	-
63	-
64	-
65	-
66	-
67	-
68	-
69	-
70	-
71	-
72	-
73	-

74 -
75 -
76 -
77 -
78 -
79 -
80 -
81 -
82 -
83 -
84 -
85 -
86 -
87 -
88 -
89 -
90 -
91 -
92 -
93 -
94 -
95 -
96 -
97 -
98 -
99 -
100 -
101 -
102 -
103 -
104 -
105 -
106 -
107 -
108 -
109 -
110 -

All contents of this site are © 2024 Passmedicine Limited
Back to top

A 62-year-old man, with a 40-year heavy smoking history, presents to the emergency department. He's been troubled by a cough for the last five months associated with constant fatigue and weight loss. He reports coughing up blood on the morning of presentation.

On physical examination, the patient looks emaciated with notable finger clubbing. Auscultation reveals diminished air entry over the left lung with occasional wheezes. No murmurs are heard.

His vital signs are as follows:

- Temperature: 37.1°C.
- Blood pressure: 115/75 mmHg.
- Heart rate: 101 beats/min, regular.
- Respiratory rate: 22 breaths/min.
- Oxygen saturation: 94 % on room air.

Labs are ordered and the results are the following:

Hb	125 g/L	Male: (135-180)
Platelets	680 * 10^9/L	(150 - 400)
WBC	9.5 * 10^9/L	(4.0 - 11.0)
Calcium	2.75 mmol/L	(2.1-2.6)

The chest x-ray is shown:

© Image used on license from Radiopaedia

What is the most likely diagnosis?

Lung metastases	1%
Sarcoidosis	5%
Small cell lung cancer	21%
Squamous cell lung cancer	72%
Tuberculosis	1%

Squamous cell lung cancer is the correct answer.

The patient's chest x-ray reveals a concerning mass in the left lung's hilar region. Considering the patient's extensive history of smoking coupled with respiratory symptoms, including haemoptysis, thrombocytosis, and the presence of hypercalcemia, a primary lung malignancy is the leading diagnostic consideration. While both small cell and squamous cell lung cancers could be potential culprits, hypercalcemia, which may be attributed to paraneoplastic secretion of parathyroid hormone-related protein, is more commonly associated with squamous cell lung cancer.

Lung metastases is not correct. While the x-ray findings and symptoms might suggest some form of lung disease, the patient's significant smoking history combined with hypercalcemia lean more

towards a primary lung malignancy rather than metastatic disease.

Sarcoidosis is a viable differential diagnosis. The hypercalcemia and thrombocytosis associated with sarcoidosis make it a potential consideration. However, sarcoidosis typically presents with bilateral hilar lymphadenopathy. The unilateral presentation in this case, combined with the presence of haemoptysis, makes sarcoidosis less likely.

Small cell lung cancer is less likely. Although the patient's symptoms could be consistent with small cell lung cancer, the presence of hypercalcemia makes squamous cell lung cancer more likely.

Tuberculosis seems improbable in this case. While TB can indeed cause haemoptysis, chronic cough, weight loss, and hilar lymphadenopathy on imaging, other typical symptoms such as fever and night sweats are absent. The combination of a hilar mass and thrombocytosis with the patient's smoking history places lung cancer higher on the differential list.

Discuss (1) | Improve

Next question

Lung cancer: investigation

Chest x-ray

- this is often the first investigation done in patients with suspected lung cancer
- in around 10% of patients subsequently diagnosed with lung cancer the chest x-ray was reported as normal

CT

- is the investigation of choice to investigate suspected lung cancer

Bronchoscopy

- this allows a biopsy to be taken to obtain a histological diagnosis sometimes aided by endobronchial ultrasound

PET scanning

- is typically done in non-small cell lung cancer to establish eligibility for curative treatment
- uses 18-fluorodeoxygenase which is preferentially taken up by neoplastic tissue
- has been shown to improve diagnostic sensitivity of both local and distant metastasis spread in non-small cell lung cancer

Bloods

- raised platelets may be seen

AI + Q 123

Next question >

Textbooks

High-yield textbook

Extended textbook

Links

Royal College of Physicians 2 3

2012 PET/CT in oncology review

Radiopaedia 3 1

Lung cancer review

Suggest link Report broken link

Media

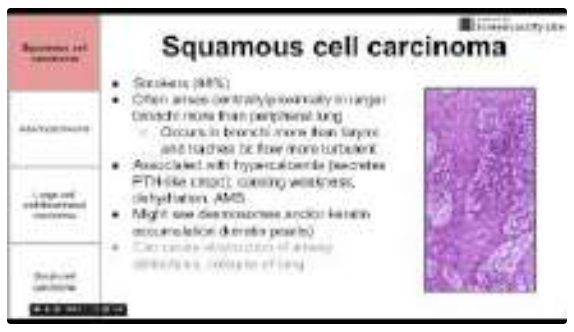

[Cancers of the lung]

MedLecturesMadeEasy - YouTube 5 0

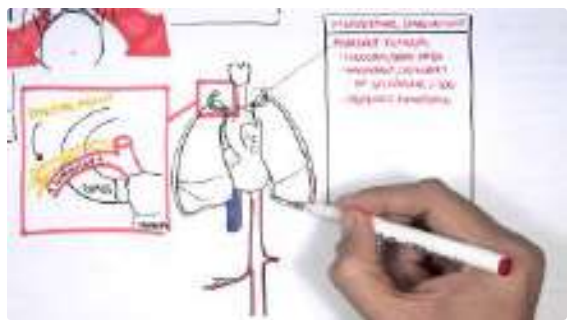

[Lung cancer]

Armando Hasudungan - YouTube 1 0

[Lung cancer]

MedFlix - YouTube 2 1

[Lung Cancer: An Overview]

Oncology for Medical Students - YouTube 1 1

Report broken media

Score: **17.3%**

1 ✗
2 ✗

3	✗
4	✗
5	✗
6	✗
7	✗
8	✗
9	✗
10	✗
11	✗
12	✓
13	✗
14	✗
15	✗
16	✗
17	✗
18	✗
19	✗
20	✗
21	✗
22	✗
23	✓
24	✗
25	✗
26	✗
27	✗
28	✗
29	✓
30	✗
31	✓
32	✗
33	✗
34	✗
35	✗
36	✓
37	✓
38	✗

39	✗
40	✗
41	✓
42	✗
43	✗
44	✗
45	✗
46	✗
47	✗
48	✗
49	✓
50	✗
51	✗
52	✓
53	✗
54	✗
55	✓
56	✗
57	✗
58	✓
59	✗
60	✓
61	✗
62	✗
63	✗
64	✗
65	✗
66	✗
67	✗
68	✗
69	✗
70	✗
71	✗
72	✗
73	✗
74	✗

75	✓
76	✗
77	✗
78	✗
79	✓
80	✗
81	✗
82	✓
83	✗
84	✗
85	✗
86	✗
87	✗
88	✗
89	✗
90	✗
91	✗
92	✗
93	✓
94	✗
95	✓
96	✗
97	✗
98	✗
99	✗
100	✗
101	✗
102	✗
103	✓
104	✗
105	✗
106	✓
107	✗
108	✗
109	✗
110	✗

111 -

All contents of this site are © 2024 Passmedicine Limited

A 30-year-old man presents to the emergency department with a four-day history of subjective fevers, shortness of breath, non-productive cough and malaise.

On arrival to the emergency department, his observations revealed a temperature of 38.5ºC, heart rate 120/min, blood pressure 90/60 mmHg, respiratory rate 35/min and oxygen saturations of 80% on room air. An arterial blood gas revealed severe type 1 respiratory failure and the patient was intubated and placed on mechanical ventilation.

A post-intubation chest x-ray revealed bilateral pulmonary infiltrates and within the limits of a portable chest x-ray, a normal sized cardiac silhouette.

Intravenous 1g ceftriaxone, 500mg azithromycin and 200mg hydrocortisone were given in the emergency department for severe community acquired pneumonia prior to transfer to the intensive care unit (ICU).

The patient remained on invasive mechanical ventilation for the first 24 hours. During this time, he underwent computed tomography pulmonary angiography (CTPA) and bronchoalveolar lavage.

He made good progress and was extubated to high flow nasal cannulae after 24 hours. He is haemodynamically stable. He is stepped down to the high dependency unit (HDU), where you review the patient.

You speak with the patient's wife to obtain a collateral history. The patient has no known past medical, surgical, drug or family history of note. He works as a full-time chef and there have been no known sick contacts. He drinks 1-2 cans of standard strength beer per night and occasionally binge drinks at the weekends. He recently started smoking cigarettes to cope with increased stress at work and there is no history of illicit drug use. There has been no recent travel history.

On examination in the HDU, the temperature was 37.5ºC, heart rate 90/min, blood pressure 100/60 mmHg and respiratory rate 26/min. He is on high flow oxygen via nasal cannulae, with a flow rate of 30 litres per minute, the fraction of inspired oxygen is 30% and has oxygen saturations of 95%. There are fine inspiratory crepitations audible in the lower posterior chest bilaterally which do not change with coughing. The jugular venous pressure was not elevated and there was no pedal oedema.

Current medications are: intravenous ceftriaxone, azithromycin and as required paracetamol

You review the latest available results for this patient:

WBC	$11 * 10^9$/l	Urea	7 mmol/l
Neuts	$8.5 * 10^9$/l	Creatinine	80 μmol/l
Lymphs	$1.5 * 10^9$/l	CRP	80 mg/l
Eosin	$1.0 * 10^9$/l		

Bronchoalveolar lavage	**Result**
Neutrophils	5%
Lymphocytes	10%
Eosinophils	30%
Respiratory viruses PCR	Negative
Mycoplasma *pneumoniae* PCR	Negative
Microscopy, culture and sensitivities	Nil growth

Imaging	**Report**
CT pulmonary angiogram	No pulmonary embolism. Bilateral patchy areas of ground-glass opacities and small bilateral pleural effusions

Which of the following would be the most appropriate ongoing management for this patient?

- Continue intravenous ceftriaxone and azithromycin
- Cease intravenous ceftriaxone, azithromycin and observe
- Cease intravenous ceftriaxone and azithromycin. Commence intravenous furosemide 40mg twice daily
- Continue intravenous ceftriaxone, azithromycin and commence intravenous hydrocortisone

Cease intravenous ceftriaxone, azithromycin and commence intravenous hydrocortisone

Submit answer

Reference ranges

Score: **0%**

1 -

All contents of this site are © 2024 Passmedicine Limited

A 30-year-old man presents to the emergency department with a four-day history of subjective fevers, shortness of breath, non-productive cough and malaise.

On arrival to the emergency department, his observations revealed a temperature of 38.5ºC, heart rate 120/min, blood pressure 90/60 mmHg, respiratory rate 35/min and oxygen saturations of 80% on room air. An arterial blood gas revealed severe type 1 respiratory failure and the patient was intubated and placed on mechanical ventilation.

A post-intubation chest x-ray revealed bilateral pulmonary infiltrates and within the limits of a portable chest x-ray, a normal sized cardiac silhouette.

Intravenous 1g ceftriaxone, 500mg azithromycin and 200mg hydrocortisone were given in the emergency department for severe community acquired pneumonia prior to transfer to the intensive care unit (ICU).

The patient remained on invasive mechanical ventilation for the first 24 hours. During this time, he underwent computed tomography pulmonary angiography (CTPA) and bronchoalveolar lavage.

He made good progress and was extubated to high flow nasal cannulae after 24 hours. He is haemodynamically stable. He is stepped down to the high dependency unit (HDU), where you review the patient.

You speak with the patient's wife to obtain a collateral history. The patient has no known past medical, surgical, drug or family history of note. He works as a full-time chef and there have been no known sick contacts. He drinks 1-2 cans of standard strength beer per night and occasionally binge drinks at the weekends. He recently started smoking cigarettes to cope with increased stress at work and there is no history of illicit drug use. There has been no recent travel history.

On examination in the HDU, the temperature was 37.5ºC, heart rate 90/min, blood pressure 100/60 mmHg and respiratory rate 26/min. He is on high flow oxygen via nasal cannulae, with a flow rate of 30 litres per minute, the fraction of inspired oxygen is 30% and has oxygen saturations of 95%. There are fine inspiratory crepitations audible in the lower posterior chest bilaterally which do not change with coughing. The jugular venous pressure was not elevated and there was no pedal oedema.

Current medications are: intravenous ceftriaxone, azithromycin and as required paracetamol

You review the latest available results for this patient:

WBC	$11 * 10^9$/l	Urea	7 mmol/l
Neuts	$8.5 * 10^9$/l	Creatinine	80 µmol/l
Lymphs	$1.5 * 10^9$/l	CRP	80 mg/l
Eosin	$1.0 * 10^9$/l		

Bronchoalveolar lavage	**Result**
Neutrophils	5%
Lymphocytes	10%
Eosinophils	30%
Respiratory viruses PCR	Negative
Mycoplasma *pneumoniae* PCR	Negative
Microscopy, culture and sensitivities	Nil growth

Imaging	**Report**
CT pulmonary angiogram	No pulmonary embolism. Bilateral patchy areas of ground-glass opacities and small bilateral pleural effusions

Which of the following would be the most appropriate ongoing management for this patient?

- Continue intravenous ceftriaxone and azithromycin 6%
- Cease intravenous ceftriaxone, azithromycin and observe 5%
- Cease intravenous ceftriaxone and azithromycin. Commence intravenous furosemide 40mg twice daily 4%
- Continue intravenous ceftriaxone, azithromycin and commence intravenous hydrocortisone 37%
- Cease intravenous ceftriaxone, azithromycin and commence intravenous hydrocortisone 49%

Acute eosinophilic pneumonia is highly responsive to steroids

Important for me Less important

This man presents with clinical and laboratory features consistent with acute eosinophilic pneumonia, which is highly responsive to steroids.

Antibiotics can be ceased in this case for a number of reasons:

- There is no evidence of consolidation on the CTPA
- With bacterial pneumonia, you normally expect a neutrophil pleocytosis on the bronchoalveolar lavage fluid analysis

- Patients with bacterial pneumonia requiring intubation and ventilation rarely improve as rapidly as described in this case, which should make you question the diagnosis community acquired pneumonia.

The modified Philit criteria are used to diagnose acute eosinophilic pneumonia

- acute respiratory illness of less than or equal to 1-month duration
- pulmonary infiltrates on chest radiography or computed tomography (CT)
- pulmonary eosinophilia as demonstrated by more than 25% eosinophils in BAL fluid (can be accompanied by variably increased percentages of lymphocytes and neutrophils) or eosinophilic pneumonia on lung biopsy (bronchoscopic or surgical), and
- the absence of other specific pulmonary eosinophilic diseases e.g. eosinophilic granulomatosis with polyangiitis (previously known as Churg-Strauss syndrome)

Acute eosinophilic pneumonia can be caused by inhalation of chemicals, with tobacco being most frequently associated with developing the condition, especially those who have recently started smoking, as in this case.

There can be a spectrum of presentations, from mild symptoms that resolve spontaneously, to a clinical picture mimics acute respiratory distress syndrome (ARDS) and can be misdiagnosed as community acquired pneumonia.

The BAL is a key investigation. A marked eosinophilia (>25%) which may be accompanied by elevated neutrophils and lymphocytes, suggests an acute eosinophilic pneumonia. Whereas in ARDS, the BAL analysis is expected to show a neutrophilia.

Acute eosinophilic pneumonia responds within days with appropriate treatment but it can be fatal if not identified.

This patient received 200mg intravenous hydrocortisone in the emergency, most likely because the

suspicion was severe community acquired pneumonia and you should be aware that there is a growing evidence base for the use of steroids for severe community acquired pneumonia. The hydrocortisone, albeit inadvertently, may have contributed to this patient's rapid improvement and extubation.

There is no consensus on the dose and duration of corticosteroid therapy for such patients. Some articles suggest methylprednisolone for those critically unwell, with a transition to oral prednisolone for up to 4 weeks once stabilised.

Option 1 - incorrect as this would treat bacterial pneumonia and no an acute eosinophilic pneumonia

Option 2 - stopping antibiotics is a correct management step but observing only would likely lead to this patient relapsing after only having one dose of corticosteroids

Option 3 - stopping antibiotics is a correct management step but there is no evidence of heart failure/fluid overload on examination. Acute eosinophilic pneumonia is frequently associated with pleural effusions, which may be unilateral or bilateral.

Option 4 - there is no indication for ongoing antibiotics

Option 5 - the correct answer

Discuss (10) | Improve

Next question

Pulmonary eosinophilia

Pulmonary eosinophilia describes a situation where there are increased numbers of eosinophils in the lung airways and parenchyma. This is generally associated with a blood eosinophilia.

Causes of pulmonary eosinophilia
- Churg-Strauss syndrome
- allergic bronchopulmonary aspergillosis (ABPA)
- Loffler's syndrome
- eosinophilic pneumonia
- hypereosinophilic syndrome
- tropical pulmonary eosinophilia
- drugs: nitrofurantoin, sulphonamides
- less common: Wegener's granulomatosis

Loffler's syndrome

- transient CXR shadowing and blood eosinophilia
- thought to be due to parasites such as *Ascaris lumbricoides* causing an alveolar reaction
- presents with a fever, cough and night sweats which often last for less than 2 weeks.
- generally a self-limiting disease

Acute eosinophilic pneumonia

- highly responsive to steroids

Tropical pulmonary eosinophilia

- associated with *Wuchereria bancrofti* infection

AI + Q 123

Next question >

Textbooks

High-yield textbook

Extended textbook

Score: **8.7%**

1 ✓
2 ✗
3 ✗
4 ✗

5	✗
6	✗
7	✗
8	✗
9	✗
10	✗
11	✗
12	✗
13	✗
14	✗
15	✓
16	✗
17	✗
18	✗
19	✗
20	✗
21	✗
22	✗
23	✗

All contents of this site are © 2024 Passmedicine Limited

Back to top

A 59-year-old man is seen in the emergency department with abdominal pain. He is a type 2 diabetic with a body mass index of $40kg/m^2$ and takes regular metformin and glibenclamide. He has previous episodes of pancreatitis and he says the pain is central and radiating to his back like on previous occasions. He has never smoked and worked as a loans manager for 38 years before taking early retirement.

On examination, he has a clear chest and respiratory rate is 15/min. His abdomen has guarding in the epigastric areas but bowel sounds are present. The surgical registrar asks you to perform an arterial blood gas and the results are as below.

pH	7.38
pCO2	7.8 kPa
pO2	8.4 kPa
HCO3	31 mmol/L
Base excess	+4.2
Glucose	5.3 mmol/L
Lactate	2.50mmol/L

Please explain what the likely cause of these findings are?

- Obstructive sleep apnoea (OSA)
- Chronic obstructive pulmonary disease (COPD)
- Alpha-1-antitrypsin deficiency
- Lactic acidosis
- Sepsis

Submit answer

Reference ranges

Score: **0%**

1 -
2 -

All contents of this site are © 2024 Passmedicine Limited

Back to top

A 59-year-old man is seen in the emergency department with abdominal pain. He is a type 2 diabetic with a body mass index of 40kg/m^2 and takes regular metformin and glibenclamide. He has previous episodes of pancreatitis and he says the pain is central and radiating to his back like on previous occasions. He has never smoked and worked as a loans manager for 38 years before taking early retirement.

On examination, he has a clear chest and respiratory rate is 15/min. His abdomen has guarding in the epigastric areas but bowel sounds are present. The surgical registrar asks you to perform an arterial blood gas and the results are as below.

pH	7.38
pCO2	7.8 kPa
pO2	8.4 kPa
HCO3	31 mmol/L
Base excess	+4.2
Glucose	5.3 mmol/L
Lactate	2.50mmol/L

Please explain what the likely cause of these findings are?

- Obstructive sleep apnoea (OSA) 58%
- Chronic obstructive pulmonary disease (COPD) 7%
- Alpha-1-antitrypsin deficiency 18%
- Lactic acidosis 12%
- Sepsis 5%

Untreated OSA -> compensated respiratory acidosis

Important for me Less important

This gentleman has a raised CO2 but a normal pH therefore this is a compensated respiratory acidosis. His lactate is raised but there is no acidosis so this is not lactic acidosis. COPD patients by definition almost always have some smoking history. Furthermore, he has no lung or liver pathology so alpha-1-antitrypsin deficiency is also unlikely. Patients who are obese often have lots of soft tissue in the neck that occlude the airway when asleep and the tone falls. Therefore, the carbon dioxide rises during sleep and they have daytime somnolence and headaches. Over long periods of time, the carbon dioxide can become compensated by renal retention of bicarbonate and in an analogous mechanism to COPD, patients with chronic OSA can become carbon dioxide retainers with normal pH. This gentleman would probably benefit from home CPAP after this result is repeated 6 weeks after discharge from hospital.

Discuss (16) | Improve

Next question ›

Obstructive sleep apnoea/hypopnoea syndrome

Predisposing factors

- obesity
- macroglossia: acromegaly, hypothyroidism, amyloidosis
- large tonsils
- Marfan's syndrome

The partner often complains of excessive snoring and may report periods of apnoea.

Consequence

- daytime somnolence
- compensated respiratory acidosis
- hypertension

Assessment of sleepiness

- Epworth Sleepiness Scale - questionnaire completed by patient +/- partner
- Multiple Sleep Latency Test (MSLT) - measures the time to fall asleep in a dark room (using EEG criteria)

Diagnostic tests

- sleep studies (polysomnography) - ranging from monitoring of pulse oximetry at night to full polysomnography where a wide variety of physiological factors are measured including EEG, respiratory airflow, thoraco-abdominal movement, snoring and pulse oximetry

Management

- weight loss
- continuous positive airway pressure (CPAP) is first line for moderate or severe OSAHS
- intra-oral devices (e.g. mandibular advancement) may be used if CPAP is not tolerated or for patients with mild OSAHS where there is no daytime sleepiness
- the DVLA should be informed if OSAHS is causing excessive daytime sleepiness
- limited evidence to support use of pharmacological agents

123

Next question

Textbooks

High-yield textbook

Extended textbook

Links

Clinical Knowledge Summaries 4 4

Obstructive sleep apnoea guidelines

NICE 8 5

2021 Obstructive sleep apnoea/hypopnoea syndrome and obesity hypoventilation syndrome guidelines

Suggest link Report broken link

Media

[Sleep apnea]

Osmosis - YouTube 3 0

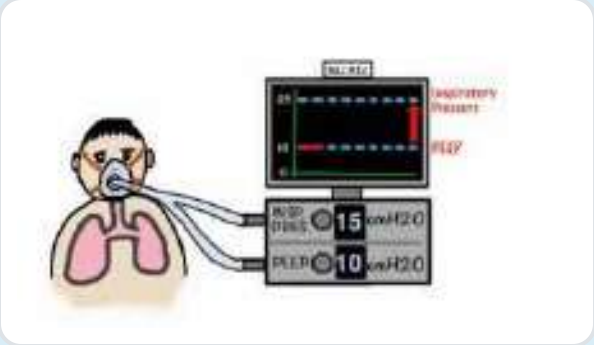

[CPAP and Non-Invasive Ventilation in 5 minutes]

Nick Smith - YouTube 2 0

[Obstructive Sleep Apnoea]

Zero To Finals - YouTube 1 0

[Understanding Obstructive Sleep Apnea Syndrome]

Rhesus Medicine - YouTube 0 0

Report broken media

Score: **8.7%**

1 ✓
2 ✗
3 ✗
4 ✗

5	✗
6	✗
7	✗
8	✗
9	✗
10	✗
11	✗
12	✗
13	✗
14	✗
15	✓
16	✗
17	✗
18	✗
19	✗
20	✗
21	✗
22	✗
23	✗

All contents of this site are © 2024 Passmedicine Limited

Back to top

A 31-year-old male presented to the emergency department with a 1-day history of dyspnoea associated with a dry cough and palpitations.

On examination, his temperature is 37.3ºC. He has a respiratory rate of 28 breaths per minute, with an oxygen saturation of 94% on room air. His blood pressure is 125/80 mmHg with a heart rate of 100bpm. On auscultation, there is reduced air entry in the right lower zone and a chest radiograph shows a right pneumothorax. A thoracostomy tube is placed on the right side immediately.

During the morning ward round, 4 days later, it is noticed that whilst checking the chest drain there is an air leak of 50cc. A repeat chest radiograph shows the right pneumothorax is still present.

What is the next most appropriate step in this patient's management?

- Apply supplemental oxygen therapy
- Change the thoracostomy tube to a large bore catheter
- Thoracic surgery consultation
- Apply suction at -20 cmH2O using a high pressure-low volume system
- Observe for a further 48 hours

Submit answer

Reference ranges

Score: **0%**

1 -
2 -

3	-

All contents of this site are © 2024 Passmedicine Limited

A 31-year-old male presented to the emergency department with a 1-day history of dyspnoea associated with a dry cough and palpitations.

On examination, his temperature is 37.3ºC. He has a respiratory rate of 28 breaths per minute, with an oxygen saturation of 94% on room air. His blood pressure is 125/80 mmHg with a heart rate of 100bpm. On auscultation, there is reduced air entry in the right lower zone and a chest radiograph shows a right pneumothorax. A thoracostomy tube is placed on the right side immediately.

During the morning ward round, 4 days later, it is noticed that whilst checking the chest drain there is an air leak of 50cc. A repeat chest radiograph shows the right pneumothorax is still present.

What is the next most appropriate step in this patient's management?

Apply supplemental oxygen therapy	6%
Change the thoracostomy tube to a large bore catheter	9%
Thoracic surgery consultation	64%
Apply suction at -20 cmH2O using a high pressure-low volume system	17%
Observe for a further 48 hours	5%

When draining a pneumothorax, if after 3-5 days there is persistent air leak (e.g. bubbling chest drain) or failure of the lung to re-expand, a thoracic surgical opinion should be sought

Important for me Less important

All patients with a primary spontaneous pneumothorax (PSP) should receive resuscitation with a focus on airway stabilisation (if indicated) as well as supplemental oxygen to treat hypoxaemia (if present) and to facilitate absorption of air from the pleural space. Subsequent management is directed at deciding whether air needs to be removed from the pleural space. If so, then options include observation with or without supplemental oxygen, needle aspiration of intrapleural air, and chest tube or catheter thoracostomy.

An air leak is considered prolonged if it continues over the next three to seven days. One should check that the leak is not coming from the drainage chamber, from the tubing, or from around the

chest tube at the skin entry site; this is classically done by clamping the tube at different locations to isolate the site of the leak. A thoracic surgery consultation is necessary for patients with a persistent air leak. These patients require a more aggressive approach for closure since the longer an air leak persists, the less likely it is that the leak will close spontaneously requiring a definitive intervention (e.g. pleurectomy, blebectomy and/or pleurodesis).

Applying supplemental oxygen is of no benefit here as the patient is currently saturating well.

Observation for a further 48 hours is not indicated in patients with a persistent air leak.

Applying suction will not be the right answer here as the thoracostomy tube is already on suction once inserted.

Changing the tube will not be of benefit as it has been inserted 4 days ago with a persistent air leak and without any changes in the chest radiograph or clinical examination.

Discuss (3) | Improve

Next question

Pneumothorax: management

The British Thoracic Society (BTS) published updated guidelines for the management of spontaneous pneumothorax in 2023.

The updated guidelines put less emphasis on the size of the pneumothorax and more emphasis on whether the patient is symptomatic and the presence of high-risk characteristics.

Decision algorithm

The first step is assessing whether the patient is symptomatic

- the BTS define minimal symptoms as '*no significant pain or breathlessness and no physiological compromise*'
- no or minimal symptoms → conservative care, regardless of pneumothorax size
- symptomatic → assess for high-risk characteristics

If a pneumothorax is symptomatic, the next step is assessment for high-risk characteristics

- high-risk characteristics are defined as follows:
  - haemodynamic compromise (suggesting a tension pneumothorax)
  - significant hypoxia

- bilateral pneumothorax
- underlying lung disease
- ≥ 50 years of age with significant smoking history
- haemothorax

- if no high-risk characteristics are present, and it is safe to intervene, then there is a choice of intervention:
    - conservative care
    - ambulatory device
    - needle aspiration
- if high-risk characteristics are present, and it is safe to intervene → chest drain

How is safety or intervention determined?

- before a needle aspiration/chest drain insertion, the safety of intervention should be assessed
- this depends on the clinical context, but is usually:
    - 2cm laterally or apically on chest x-ray, or
    - any size on CT scan which can be safely accessed with radiological support

Management options

Conservative care

- patients with a primary spontaneous pneumothorax that is managed conservatively should be reviewed every 2-4 days as an outpatient
- patients with a secondary spontaneous pneumothorax that is managed conservatively should be monitored as an inpatient
- if stable, follow-up in the outpatients department in 2-4 weeks

Ambulatory care

- an example of an ambulatory device is the Rocketµ Pleural Vent„
- it includes an 8FG catheter mounted on an 18G needle and a pigtail catheter to minimize the risk of occlusion
- ambulatory devices typically have a one-way valve and vent to prevent air and fluid return to the pleural space while allowing for controlled escape of air and drainage of fluid

- many devices also have an indication diaphragm that signals when the catheter tip enters the pleural space and continues to fluctuate with respiration, aiding in the assessment of pneumothorax resolution

Needle aspiration

- a chest drain should be inserted if needle aspiration of a pneumothorax is unsuccessful
- if resolved, discharge and follow-up in the outpatients department in 2-4 weeks

Chest drain insertion

- daily review as an inpatient
- remove drain when resolved
- discharge and follow-up in the outpatients department in 2-4 weeks

Persistentent / recurrent pneumothorax

If a patient has a persistent air leak or insufficient lung reexpansion despite chest drain insertion, or the patient has recurrent pneumothoraces, then video-assisted thoracoscopic surgery (VATS) should be considered to allow for mechanical/chemical pleurodesis +/- bullectomy.

Discharge advice

Smoking

- patients should be advised to avoid smoking to reduce the risk of further episodes - the lifetime risk of developing a pneumothorax in healthy smoking men is around 10% compared with around 0.1% in non-smoking men

Fitness to fly

- absolute contraindication, the CAA suggest patients may travel 2 weeks after successful drainage if there is no residual air. The British Thoracic Society used to recommend not travelling by air for a period of 6 weeks but this has now been changed to 1 week post check x-ray

Scuba diving

- the BTS guidelines state: '*Diving should be permanently avoided unless the patient has undergone bilateral surgical pleurectomy and has normal lung function and chest CT scan postoperatively.*'

Image gallery

123

Next question

Textbooks

High-yield textbook

Extended textbook

Links

British Thoracic Society 2 1

2023 Pleural disease guidelines

Suggest link Report broken link

Media

How to identify pneumothorax on a chest X-ray

Medmastery - YouTube 👍 30 👎 1

Pneumothorax

Zero To Finals - YouTube 👍 9 👎 1

Pneumothorax

Osmosis - YouTube 👍 6 👎 1

Needle Aspiration of Pneumothorax

NEJM - YouTube 👍 10 👎 6

Report broken media

Score: **8.7%**

1 ✓
2 ✗
3 ✗

4	✗
5	✗
6	✗
7	✗
8	✗
9	✗
10	✗
11	✗
12	✗
13	✗
14	✗
15	✓
16	✗
17	✗
18	✗
19	✗
20	✗
21	✗
22	✗
23	✗

All contents of this site are © 2024 Passmedicine Limited

Back to top

A 66-year-old gentleman with a diagnosis of chronic obstructive pulmonary disease (COPD) is reviewed in clinic. He complains of persistent breathlessness on exertion. There is no significant history of cough.

Pulmonary function testing reveals:

SpO2	90%
FVC	2.8L
FEV1	1.47 (40% predicted)
FEV1/FVC ratio	53%

Looking back at his notes you note that significant (> 20%) diurnal variation has been noted in his peak flows.

The patient is currently prescribed a short-acting beta-2 agonist along with a combination inhaler containing a long-acting beta-2 agonist and corticosteroid.

What is the most appropriate additional medication?

- Inhaled tiotropium
- Oral modified-release aminophylline
- Short-acting muscarinic agonist
- Oral prednisolone
- Oral roflumilast

Submit answer

Reference ranges

Score: **0%**

1 -
2 -
3 -
4 -

All contents of this site are © 2024 Passmedicine Limited

A 66-year-old gentleman with a diagnosis of chronic obstructive pulmonary disease (COPD) is reviewed in clinic. He complains of persistent breathlessness on exertion. There is no significant history of cough.

Pulmonary function testing reveals:

SpO2	90%
FVC	2.8L
FEV1	1.47 (40% predicted)
FEV1/FVC ratio	53%

Looking back at his notes you note that significant (> 20%) diurnal variation has been noted in his peak flows.

The patient is currently prescribed a short-acting beta-2 agonist along with a combination inhaler containing a long-acting beta-2 agonist and corticosteroid.

What is the most appropriate additional medication?

- Inhaled tiotropium 51%
- Oral modified-release aminophylline 5%
- Short-acting muscarinic agonist 10%
- Oral prednisolone 10%
- Oral roflumilast 24%

COPD - still breathless despite using SABA/SAMA and a LABA + ICS → add a LAMA

Important for me Less important

The correct answer in this case is **inhaled tiotropium**. Tiotropium is a long-acting muscarinic antagonist (LAMA) that is commonly used as an additional bronchodilator in the management of COPD. According to the National Institute for Health and Care Excellence (NICE) guidelines, adding

a LAMA such as tiotropium is recommended when patients with COPD continue to experience breathlessness or exacerbations despite treatment with a long-acting beta-2 agonist (LABA) and inhaled corticosteroid (ICS).

Oral modified-release aminophylline is not the most appropriate choice because it is a methylxanthine bronchodilator that has a narrow therapeutic index and requires regular monitoring of serum levels. It is generally reserved for cases where other treatments have failed or are contraindicated.

Short-acting muscarinic agonist would be an incorrect choice because these medications are not used in the treatment of COPD. In fact, short-acting muscarinic antagonists (SAMA), such as ipratropium, may be used as bronchodilators in COPD but are not the most appropriate option here given that the patient already has LABA/ICS therapy and adding a LAMA like tiotropium would provide better symptom control.

Oral prednisolone would not be the best option in this scenario, as it is typically used for acute exacerbations of COPD rather than as part of routine maintenance therapy. Long-term oral corticosteroid use has significant side effects and should be avoided unless absolutely necessary.

Finally, **oral roflumilast** could be considered for patients with severe COPD who have chronic bronchitis symptoms and frequent exacerbations, but it is not the first choice for managing persistent breathlessness in this patient. Adding a LAMA like tiotropium would be more appropriate according to the NICE guidelines.

In summary, the most appropriate additional medication for this patient with COPD and persistent breathlessness despite LABA/ICS therapy is inhaled tiotropium.

Discuss (2) | Improve

Next question >

COPD: stable management

NICE updated its guidelines on the management of chronic obstructive pulmonary disease (COPD) in 2018.

General management

- >smoking cessation advice: including offering nicotine replacement therapy, varenicline or bupropion
- annual influenza vaccination
- one-off pneumococcal vaccination

- pulmonary rehabilitation to all people who view themselves as functionally disabled by COPD (usually Medical Research Council [MRC] grade 3 and above)

Bronchodilator therapy

- a short-acting beta2-agonist (SABA) or short-acting muscarinic antagonist (SAMA) is first-line treatment
- for patients who remain breathless or have exacerbations despite using short-acting bronchodilators the next step is determined by whether the patient has '*asthmatic features/features suggesting steroid responsiveness*'

There are a number of criteria NICE suggest to determine whether a patient has asthmatic/steroid responsive features:

- any previous, secure diagnosis of asthma or of atopy
- a higher blood eosinophil count - note that NICE recommend a full blood count for all patients as part of the work-up
- substantial variation in FEV1 over time (at least 400 ml)
- substantial diurnal variation in peak expiratory flow (at least 20%)

Interestingly NICE do not recommend formal reversibility testing as one of the criteria. In the guidelines they state that '*routine spirometric reversibility testing is not necessary as part of the diagnostic process or to plan initial therapy with bronchodilators or corticosteroids. It may be unhelpful or misleading...*'. They then go on to discuss why they have reached this conclusion. Please see the guidelines for more details.

No asthmatic features/features suggesting steroid responsiveness

- add a long-acting beta2-agonist (LABA) + long-acting muscarinic antagonist (LAMA)
    - if already taking a SAMA, discontinue and switch to a SABA

Asthmatic features/features suggesting steroid responsiveness

- LABA + inhaled corticosteroid (ICS)
- if patients remain breathless or have exacerbations offer triple therapy i.e. LAMA + LABA + ICS
    - if already taking a SAMA, discontinue and switch to a SABA
- NICE recommend the use of combined inhalers where possible

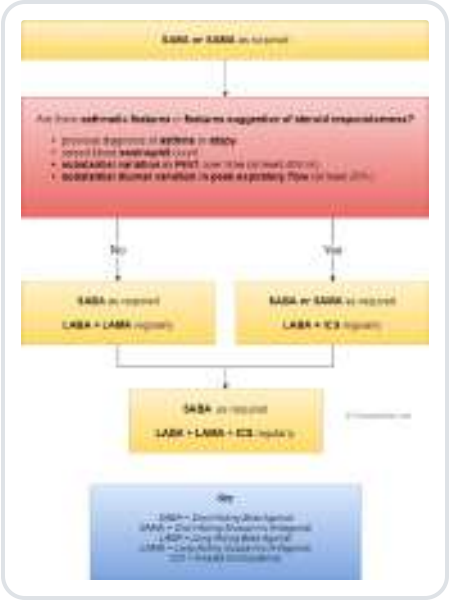

Oral theophylline

- NICE only recommends theophylline after trials of short and long-acting bronchodilators or to people who cannot used inhaled therapy
- the dose should be reduced if macrolide or fluoroquinolone antibiotics are co-prescribed

Oral prophylactic antibiotic therapy

- azithromycin prophylaxis is recommended in select patients
- patients should not smoke, have optimised standard treatments and continue to have exacerbations
- other prerequisites include a CT thorax (to exclude bronchiectasis) and sputum culture (to exclude atypical infections and tuberculosis)
- LFTs and an ECG to exclude QT prolongation should also be done as azithromycin can prolong the QT interval

Standby medication: NICE recommend offering a short course of oral corticosteroids and oral antibiotics to keep at home if: NICE

- have had an exacerbation within the last year
- understand how to take the medication, and are aware of associated risks and benefits
- know to when to seek help and when to ask for replacements once medication has been used

Mucolytics

- should be 'considered' in patients with a chronic productive cough and continued if symptoms improve

Phosphodiesterase-4 (PDE-4) inhibitors NICE

- oral PDE-4 inhibitors such as roflumilast reduce the risk of COPD exacerbations in patients with severe COPD and a history of frequent COPD exacerbations
- NICE recommend if:
    - the disease is severe, defined as a forced expiratory volume in 1 second (FEV1) after a bronchodilator of less than 50% of predicted normal, and
    - the person has had 2 or more exacerbations in the previous 12 months despite triple inhaled therapy with a long-acting muscarinic antagonist, a long-acting beta-2 agonist and an inhaled corticosteroid

Cor pulmonale

- features include peripheral oedema, raised jugular venous pressure, systolic parasternal heave, loud P2
- use a loop diuretic for oedema, consider long-term oxygen therapy
- ACE-inhibitors, calcium channel blockers and alpha blockers are not recommended by NICE

Factors which may improve survival in patients with stable COPD

- smoking cessation - the single most important intervention in patients who are still smoking
- long term oxygen therapy in patients who fit criteria
- lung volume reduction surgery in selected patients

123

Next question

Textbooks

High-yield textbook

Extended textbook

Links

Global Initiative for Chronic Obstructive Lung Disease 14 32

GOLD criteria 2017

NICE 33 30

2018 COPD guidelines

NICE

15 10

[Roflumilast NICE recommendations]

NICE 65 18

[2018 COPD management diagram]

Suggest link Report broken link

Media

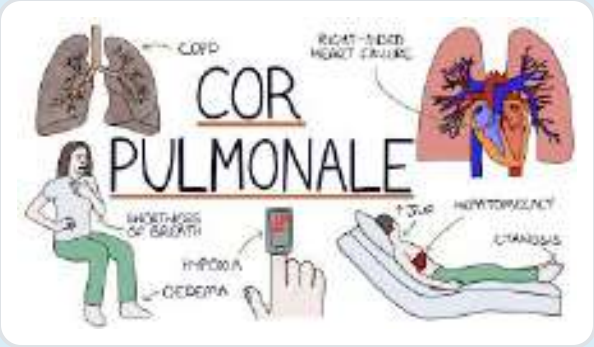

Cor pulmonale

Zero To Finals - YouTube 5 0

Chronic bronchitis

Osmosis - YouTube 3 0

Cor pulmonale

Osmosis - YouTube 1 0

Understanding COPD

Armando Hasudungan - YouTube 0 0

All about COPD (for Medical Students)

MedFlix - YouTube 👍 3 👎 1

Report broken media

Score: **8.7%**

1	✓
2	✗
3	✗
4	✗
5	✗
6	✗
7	✗
8	✗
9	✗
10	✗
11	✗
12	✗
13	✗
14	✗
15	✓
16	✗
17	✗
18	✗
19	✗
20	✗
21	✗
22	✗
23	✗

All contents of this site are © 2024 Passmedicine Limited

PassMedicine

A 25-year-old woman presents with a 2 month history of increasing shortness of breath and feeling that he chest is tight. This has built up gradually with no obvious cause and it has reached the point where she struggles to breathe when climbing a flight of stairs. She has occasional episodes of sweating profusely at night with her having to change pillows during the night,

She has a dry cough and a past medical history only significant for recurrent UTIs. She takes the combined oral contraceptive pill and prophylactic nitrofurantoin. She does not smoke, keeps a pet dog and was abroad in the USA 6 months ago.

On examination, her saturations are 94% in air and she is tachypnoeic as she walks down the corridor. Her chest has a mixture of crepitations and wheeze. There is no JVP and no murmurs. She has some red scaly areas across the back of her hands. There is no clubbing and her current peak flow is 320.

Hb	140 g/l	Na^+	139 mmol/l
Platelets	397 * 10^9/l	K^+	3.9 mmol/l
WBC	6.2 * 10^9/l	Urea	5.6 mmol/l
Neuts	3.4 * 10^9/l	Creatinine	89 µmol/l
Lymphs	0.3 * 10^9/l	CRP	32 mg/l
Eosin	1.5 * 10^9/l		

Chest x-ray	bilateral patchy shadows in the mid zones
High resolution CT scan	bilateral patchy areas of ground-glass opacity and interlobular septal thickening
Bronchoalveolar lavage	raised leucocytes with eosinophil predominance

What is the likely diagnosis?

- Eosinophilic polyangiitis with granulomatosis
- Eosinophilic asthma
- Pulmonary eosinophilia
- Idiopathic pulmonary fibrosis

Bronchiectasis

Submit answer

Reference ranges

Score: **0%**

1 -
2 -
3 -
4 -
5 -

All contents of this site are © 2024 Passmedicine Limited

Back to top

A 25-year-old woman presents with a 2 month history of increasing shortness of breath and feeling that he chest is tight. This has built up gradually with no obvious cause and it has reached the point where she struggles to breathe when climbing a flight of stairs. She has occasional episodes of sweating profusely at night with her having to change pillows during the night,

She has a dry cough and a past medical history only significant for recurrent UTIs. She takes the combined oral contraceptive pill and prophylactic nitrofurantoin. She does not smoke, keeps a pet dog and was abroad in the USA 6 months ago.

On examination, her saturations are 94% in air and she is tachypnoeic as she walks down the corridor. Her chest has a mixture of crepitations and wheeze. There is no JVP and no murmurs. She has some red scaly areas across the back of her hands. There is no clubbing and her current peak flow is 320.

Hb	140 g/l	Na^+	139 mmol/l
Platelets	$397 * 10^9/l$	K^+	3.9 mmol/l
WBC	$6.2 * 10^9/l$	Urea	5.6 mmol/l
Neuts	$3.4 * 10^9/l$	Creatinine	89 µmol/l
Lymphs	$0.3 * 10^9/l$	CRP	32 mg/l
Eosin	$1.5 * 10^9/l$		

Chest x-ray	bilateral patchy shadows in the mid zones
High resolution CT scan	bilateral patchy areas of ground-glass opacity and interlobular septal thickening
Bronchoalveolar lavage	raised leucocytes with eosinophil predominance

What is the likely diagnosis?

- Eosinophilic polyangiitis with granulomatosis 24%
- Eosinophilic asthma 11%
- Pulmonary eosinophilia 58%
- Idiopathic pulmonary fibrosis 6%

Bronchiectasis 1%

Nitrofurantoin causes a pulmonary eosinophilia

Important for me Less important

This lady has a reduced peak flow, shortness of breath and wheeze. This immediately excludes pulmonary fibrosis which is a restrictive airway disease and peak flow is relatively preserved. Asthma would not have ground glass changes. Bronchiectasis would have dilated airspaces on CT that are not seen here. Eosinophilic polyangiitis with granulomatosis will have renal involvement also. Nitrofurantoin is a recognised cause of pulmonary eosinophilia and should be stopped.

Discuss (14) Improve

Next question

Pulmonary eosinophilia

Pulmonary eosinophilia describes a situation where there are increased numbers of eosinophils in the lung airways and parenchyma. This is generally associated with a blood eosinophilia.

Causes of pulmonary eosinophilia

- Churg-Strauss syndrome
- allergic bronchopulmonary aspergillosis (ABPA)
- Loffler's syndrome
- eosinophilic pneumonia
- hypereosinophilic syndrome
- tropical pulmonary eosinophilia
- drugs: nitrofurantoin, sulphonamides
- less common: Wegener's granulomatosis

Loffler's syndrome

- transient CXR shadowing and blood eosinophilia
- thought to be due to parasites such as *Ascaris lumbricoides* causing an alveolar reaction
- presents with a fever, cough and night sweats which often last for less than 2 weeks.
- generally a self-limiting disease

Acute eosinophilic pneumonia

- highly responsive to steroids

Tropical pulmonary eosinophilia

- associated with *Wuchereria bancrofti* infection

+ Q 123

Next question

Textbooks

High-yield textbook

Extended textbook

Score: **8.7%**

1	✓
2	✗
3	✗
4	✗
5	✗
6	✗
7	✗
8	✗
9	✗
10	✗
11	✗
12	✗

13	✗
14	✗
15	✓
16	✗
17	✗
18	✗
19	✗
20	✗
21	✗
22	✗
23	✗

All contents of this site are © 2024 Passmedicine Limited

A 64-year-old woman was brought in by ambulance following an out-of-hospital cardiac arrest. Return of spontaneous circulation was achieved with 2 cycles of resuscitation. She has spent the following 3 days in the intensive care unit, intubated and ventilated.

On the morning round, it is noted that she is requiring a higher fraction of inspired oxygen to maintain normal saturations and is bringing up copious amounts of secretions. A sample of sputum is sent for microscopy, culture, and sensitivity (MC&S). These results are shown below:

Sputum MC&S	*Bacteroides fragilis*

What is the most likely explanation for these results?

- Aspiration pneumonia
- Contaminated sample
- Hospital-acquired pneumonia
- Seeding of bacteraemia
- Ventilator-associated pneumonia

Submit answer

Reference ranges

5 -
6 -

All contents of this site are © 2024 Passmedicine Limited

A 64-year-old woman was brought in by ambulance following an out-of-hospital cardiac arrest. Return of spontaneous circulation was achieved with 2 cycles of resuscitation. She has spent the following 3 days in the intensive care unit, intubated and ventilated.

On the morning round, it is noted that she is requiring a higher fraction of inspired oxygen to maintain normal saturations and is bringing up copious amounts of secretions. A sample of sputum is sent for microscopy, culture, and sensitivity (MC&S). These results are shown below:

Sputum MC&S	*Bacteroides fragilis*

What is the most likely explanation for these results?

- Aspiration pneumonia 48%
- Contaminated sample 4%
- Hospital-acquired pneumonia 2%
- Seeding of bacteraemia 3%
- Ventilator-associated pneumonia 42%

Anaerobic bacteria in sputum culture suggest aspiration pneumonia

Important for me Less important

This woman is suffering from **aspiration pneumonia**, likely secondary to her cardiac arrest. Not only does this fit the clinical history, but the anaerobic growth (*Bacteroides fragilis*) on MC&S provides further evidence that this is the case. This is therefore the most likely answer.

A **contaminated sample** may be suspected if the MC&S grows a bacteria that does not fit the clinical picture, however, *Bacteroides fragilis* is rarely a contaminant and its presence is consistent with the clinical picture here. The most common contaminants are coagulase-negative staphylococci species in blood cultures.

A **hospital-acquired pneumonia** could explain this clinical picture however the distinguishing feature is the sputum MC&S. *Bacteroides fragilis* is an anaerobe associated with aspiration

pneumonia, making hospital-acquired pneumonia less likely.

Secondary seeding of a *Bacteroides fragilis* bacteraemia is less likely than aspiration in this instance given the clinical history of cardiac arrest and no mention of further systemic features on infection. Further blood cultures to investigate this possibility would be a reasonable further step to take.

As with hospital-acquired pneumonia, **ventilator-associated pneumonia** is less likely than aspiration pneumonia here due to the species grown. *Bacteroides fragilis* is an anaerobe associated with aspiration pneumonia.

Discuss (2) | Improve

Next question >

Aspiration pneumonia

Aspiration pneumonia is a pneumonia that develops as a result of foreign materials gaining entry to the bronchial tree, usually oral or gastric contents such as food and saliva. Depending on the acidity of the aspirate a chemical pneumonitis can develop, as well as bacterial pathogens adding to the inflammation.

Aspiration pneumonia often results from an incompetent swallowing mechanism, such as those that occur in neurological disease or injury such as stroke, multiple sclerosis and intoxication. Iatrogenic causes, such as intubation, can also result in aspiration pneumonia developing. Risk factors for the development of aspiration pneumonia include:
- Poor dental hygiene
- Swallowing difficulties
- Prolonged hospitalization or surgical procedures
- Impaired consciousness
- Impaired mucociliary clearance

The right middle and lower lung lobes are the most common sites affected, due to the larger calibre and more vertical orientation of the right main bronchus.

The bacteria implicated in aspiration pneumonia may be aerobic or anaerobic. Examples of aerobic bacteria include:
- *Streptococcus pneumoniae*
- *Staphylococcus aureus*
- *Haemophilus influenzae*

- *Pseudomonas aeruginosa*
- Klebsiella: often seen in aspiration lobar pneumonia in alcoholics

Examples of anaerobic bacteria include:

- *Bacteroides*
- *Prevotella*
- *Fusobacterium*
- *Peptostreptococcus*

AI + Q 123

Next question

Textbooks

High-yield textbook

Extended textbook

Score: **8.7%**

1	✓
2	✗
3	✗
4	✗
5	✗
6	✗
7	✗
8	✗

9	✗
10	✗
11	✗
12	✗
13	✗
14	✗
15	✓
16	✗
17	✗
18	✗
19	✗
20	✗
21	✗
22	✗
23	✗

All contents of this site are © 2024 Passmedicine Limited

Back to top

A 71-year-old retired bus driver is referred to the respiratory fast-track clinic. He saw his GP after 2 months of right-sided chest pain and cough. He received a course of amoxicillin with some improvement in the cough and chest pain but has since started getting short of breath when just walking around the house. He is an ex-smoker of 30 pack-years.

On assessment, he has dullness to percussion and reduced air entry on the right lung base. His saturations are 96% on air. Chest x-ray confirms a right pleural effusion. Pleural ultrasound shows a moderate sized simple effusion. A pleural aspirate is performed:

Appearance	Serosanguineous
pH	7.32
Protein	45 g/l
LDH	450 IU/l
Glucose	4.0mmol/l
Gram stain	No organisms or malignant cells seen
Culture	No growth

Given the clinical scenario and results so far, what is the next best step for investigation of this patient?

- Surgical VATS for pleural biopsy
- CT thorax with contrast
- Further course of antibiotics
- Intercostal drain
- Observe and repeat chest x-ray and pleural ultrasound in 4 weeks

Submit answer

Reference ranges

Score: **0%**

1	-
2	-
3	-
4	-
5	-
6	-
7	-

All contents of this site are © 2024 Passmedicine Limited

A 71-year-old retired bus driver is referred to the respiratory fast-track clinic. He saw his GP after 2 months of right-sided chest pain and cough. He received a course of amoxicillin with some improvement in the cough and chest pain but has since started getting short of breath when just walking around the house. He is an ex-smoker of 30 pack-years.

On assessment, he has dullness to percussion and reduced air entry on the right lung base. His saturations are 96% on air. Chest x-ray confirms a right pleural effusion. Pleural ultrasound shows a moderate sized simple effusion. A pleural aspirate is performed:

Appearance	Serosanguineous
pH	7.32
Protein	45 g/l
LDH	450 IU/l
Glucose	4.0mmol/l
Gram stain	No organisms or malignant cells seen
Culture	No growth

Given the clinical scenario and results so far, what is the next best step for investigation of this patient?

- Surgical VATS for pleural biopsy 14%
- CT thorax with contrast 46%
- Further course of antibiotics 4%
- Intercostal drain 22%
- Observe and repeat chest x-ray and pleural ultrasound in 4 weeks 13%

This patient has been investigated according to the algorithm supplied in the British Thoracic Society guidelines 2010: Investigation of a unilateral pleural effusion in adults. He has a unilateral pleural effusion that is an exudate. Investigations have yielded neither a diagnosis nor an indication for chest drain(purulent fluid, pH<7.2, organisms on Gram stain or culture). There is no

clear evidence of infection and malignancy needs to be excluded. The next step in the algorithm is CT with contrast. Pleural biopsy may be required after that.

Discuss (9) Improve

Next question

Pleural effusion: investigation and management

The British Thoracic Society (BTS) produced guidelines in 2010 covering the investigation of patients with a pleural effusion.

Imaging
- posterioranterior (PA) chest x-rays should be performed in all patients
- ultrasound is recommended: it increases the likelihood of successful pleural aspiration and is sensitive for detecting pleural fluid septations
- contrast CT is now increasingly performed to investigate the underlying cause, particularly for exudative effusions

Pleural aspiration
- as above, ultrasound is recommended to reduce the complication rate
- a 21G needle and 50ml syringe should be used
- fluid should be sent for pH, protein, lactate dehydrogenase (LDH), cytology and microbiology

Light's criteria was developed in 1972 to help distinguish between a transudate and an exudate. The BTS recommend using the criteria for borderline cases:
- exudates have a protein level of >30 g/L, transudates have a protein level of <30 g/L
- if the protein level is between 25-35 g/L, Light's criteria should be applied. An exudate is likely if at least one of the following criteria are met:
  - pleural fluid protein divided by serum protein >0.5
  - pleural fluid LDH divided by serum LDH >0.6
  - pleural fluid LDH more than two-thirds the upper limits of normal serum LDH

Other characteristic pleural fluid findings:

- low glucose: rheumatoid arthritis, tuberculosis
- raised amylase: pancreatitis, oesophageal perforation
- heavy blood staining: mesothelioma, pulmonary embolism, tuberculosis

Pleural infection

All patients with a pleural effusion in association with sepsis or a pneumonic illness require diagnostic pleural fluid sampling

- if the fluid is purulent or turbid/cloudy a chest tube should be placed to allow drainage
- if the fluid is clear but the **pH is less than 7.2 in patients with suspected pleural infection a chest tube should be placed**

Management of recurrent pleural effusion

Options for managing patients with recurrent pleural effusions include:

- recurrent aspiration
- pleurodesis
- indwelling pleural catheter
- drug management to alleviate symptoms e.g. opioids to relieve dyspnoea

123

Next question

Textbooks

High-yield textbook

Extended textbook

Links

British Thoracic Society

2023 Pleural disease guidelines

17 14

Royal College of Physicians

2012 Pleural infection review

13 7

Suggest link

Report broken link

Media

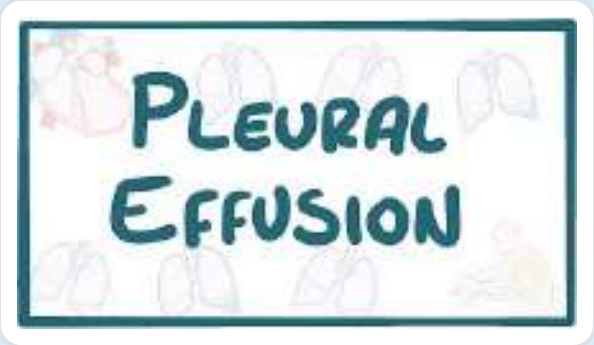

Pleural effusion

Osmosis - YouTube 8 1

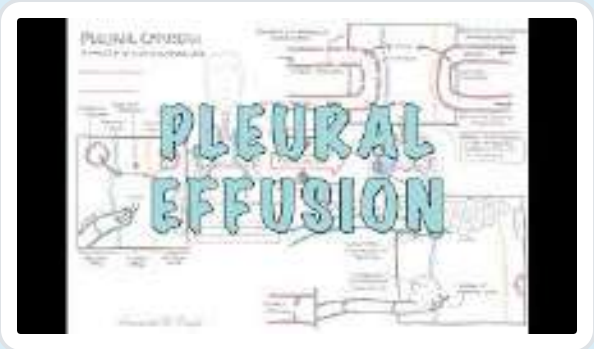

Pleural effusion

Armando Hasudungan - YouTube 6 1

Report broken media

Score: **8.7%**

1 ✓

2	✗
3	✗
4	✗
5	✗
6	✗
7	✗
8	✗
9	✗
10	✗
11	✗
12	✗
13	✗
14	✗
15	✓
16	✗
17	✗
18	✗
19	✗
20	✗
21	✗
22	✗
23	✗

All contents of this site are © 2024 Passmedicine Limited

A 45 year old patient undergoing R-CHOP (Rituximab, Cyclophosphamide, Doxyrubicin, Vincristine and Prednisolone) chemotherapy for Non-Hodgkins Lymphoma presents with a progressive cough, rigors and fevers up to 39.4 degrees on his home thermometer. His GP had tried 2 courses of antibiotics that had no beneficial effect on his symptoms. He attended to the Medical Assessment Unit after a particularly bad episode of coughing having experienced blood stained sputum.

Investigations are as follows

Hb	10.4 g/dl
Platelets	460 * 10^9/l
WBC	16.4 * 10^9/l
Neutrophils	13.5 * 10^9/l
Lymphocytes	2.7 * 10^9/l

Na^+	134 mmol/l
K^+	4.2 mmol/l
Urea	7.4 mmol/l
Creatinine	106 µmol/l

Chest X-Ray
- Cavitating lesion in the right upper zone.
- No evidence of pleural effusion
- No other focal consolidation

CT Thorax
- Cavitating lesion with halo sign

Broncho-alveolar lavage induced sputum
- Hyphae seen on silver staining

What is the most likely diagnosis?

- Invasive Aspergillosis
- Allergic Bronchopulmonary Aspergillosis
- Aspergilloma
- Tuberculosis
- Post atypical pneumonia lung abscess

Submit answer

Reference ranges

Score: **0%**

1 -
2 -
3 -
4 -
5 -
6 -
7 -
8 -

All contents of this site are © 2024 Passmedicine Limited

Back to top

A 45 year old patient undergoing R-CHOP (Rituximab, Cyclophosphamide, Doxyrubicin, Vincristine and Prednisolone) chemotherapy for Non-Hodgkins Lymphoma presents with a progressive cough, rigors and fevers up to 39.4 degrees on his home thermometer. His GP had tried 2 courses of antibiotics that had no beneficial effect on his symptoms. He attended to the Medical Assessment Unit after a particularly bad episode of coughing having experienced blood stained sputum.

Investigations are as follows

Hb	10.4 g/dl
Platelets	460 * 10^9/l
WBC	16.4 * 10^9/l
Neutrophils	13.5 * 10^9/l
Lymphocytes	2.7 * 10^9/l

Na^+	134 mmol/l
K^+	4.2 mmol/l
Urea	7.4 mmol/l
Creatinine	106 µmol/l

Chest X-Ray

- Cavitating lesion in the right upper zone.
- No evidence of pleural effusion
- No other focal consolidation

CT Thorax

- Cavitating lesion with halo sign

Broncho-alveolar lavage induced sputum

- Hyphae seen on silver staining

What is the most likely diagnosis?

- Invasive Aspergillosis 34%
- Allergic Bronchopulmonary Aspergillosis 5%
- Aspergilloma 57%
- Tuberculosis 2%
- Post atypical pneumonia lung abscess 2%

This patient is likely to have had a prolonged period of neutropenia post chemotherapy that has left him at risk from fungal infections. Fungal infections are the preserve of the immunosuppressed. They should be part of a differential diagnosis of patients undergoing chemotherapy, stem cell transplant, patients on immunosuppressive medications for autoimmune conditions and those that are HIV positive.

The patient above describes symptoms of active infection and also has the worrying symptom of haemoptysis. Investigations have revealed the classical signs on CT scanning the 'halo sign' and hyphae have been seen on silver staining. Specific blood tests for aspergillous can be done in some centres although the reliability of these are variable. The mortality for invasive aspergillosis vary from 40-90% in the literature. As such it is important to identify it and treat quickly. Fluconazole is of no benefit in these patients. The first line treatment is voriconazole which should be started intravenously before oral dosing is considered. This is due to oral voriconazole taking at least 10 days to get to therapeutic levels. If voriconazole is not tolerated, then lipsomal amphotericin should be used.

Of the other options listed above, aspergilloma may be asymptomatic and only be noted incidentally when scanning for other conditions is undertaken. It can form in cavities left behind from treated TB. Allergic bronchopulmonary Aspergillosis (ABPA) presents commonly in patients with asthma or cystic fibrosis. Typically ABPA presents like poorly controlled asthma, with wheeze and exercise intolerance. It can progress to a bronchecstasis type illness with or without chronic sputum production.

Discuss (9) Improve

Next question

Allergic bronchopulmonary aspergillosis

Allergic bronchopulmonary aspergillosis results from an allergy to *Aspergillus spores*. In the exam questions often give a history of bronchiectasis and eosinophilia.

Features

- bronchoconstriction: wheeze, cough, dyspnoea. Patients may have a previous label of asthma
- bronchiectasis (proximal)

Investigations

- eosinophilia
- flitting CXR changes
- positive radioallergosorbent (RAST) test to Aspergillus
- positive IgG precipitins (not as positive as in aspergilloma)
- raised IgE

Management

- oral glucocorticoids
- itraconazole is sometimes introduced as a second-line agent

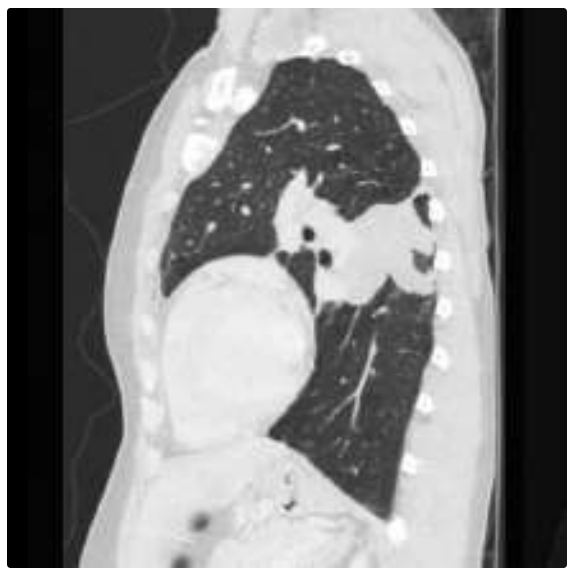

123

Next question

Textbooks

High-yield textbook

Extended textbook

Score: **8.7%**

1	✓
2	✗
3	✗
4	✗
5	✗
6	✗
7	✗
8	✗
9	✗
10	✗
11	✗
12	✗
13	✗
14	✗
15	✓
16	✗
17	✗
18	✗
19	✗
20	✗
21	✗
22	✗
23	✗

All contents of this site are © 2024 Passmedicine Limited

Back to top

A 55-year-old man presents to the emergency department with a 2-day history of haemoptysis. In the past 3-4 weeks he also reports worsening shortness of breath with mild central chest pain. His past medical history includes hypertension for which he takes amlodipine 5mg daily.

On examination, his saturations are 90% on air. His heart rate is 72/min and regular with a blood pressure of 115/85mmHg. There is reduced air entry at the right base. During the examination, he coughs up approximately 100mls of fresh blood.

Imaging of his chest is requested, as shown below.

© Image used on license from Radiopaedia

What is the most likely diagnosis?

- Eosinophilic granulomatosis with polyangiitis
- Granulomatosis with polyangiitis
- Pulmonary embolism
- Rheumatoid arthritis
- Sarcoidosis

Submit answer

Reference ranges

Score: **0%**

1	-
2	-
3	-
4	-
5	-
6	-
7	-
8	-
9	-

All contents of this site are © 2024 Passmedicine Limited

A 55-year-old man presents to the emergency department with a 2-day history of haemoptysis. In the past 3-4 weeks he also reports worsening shortness of breath with mild central chest pain. His past medical history includes hypertension for which he takes amlodipine 5mg daily.

On examination, his saturations are 90% on air. His heart rate is 72/min and regular with a blood pressure of 115/85mmHg. There is reduced air entry at the right base. During the examination, he coughs up approximately 100mls of fresh blood.

Imaging of his chest is requested, as shown below.

© Image used on license from Radiopaedia

What is the most likely diagnosis?

- Eosinophilic granulomatosis with polyangiitis 9%
- Granulomatosis with polyangiitis 62%
- Pulmonary embolism 14%
- Rheumatoid arthritis 3%
- Sarcoidosis 12%

This patient's chest x-ray and CT scan show multiple small nodules throughout the lung fields. Additionally, on the CT scan, there are a few well-defined regions of airspace opacification (as demonstrated by the grey-coloured, round lung markings) which can represent consolidation or pulmonary haemorrhage. In keeping with the history of haemoptysis and shortness of breath, pulmonary haemorrhage is a likely cause of this finding. Further inspection of the chest x-ray

shows blunting of the right costophrenic angle demonstrating a likely pleural effusion. Granulomatosis with polyangiitis (GPA) is a type of small vessel vasculitis that is responsible for causing respiratory symptoms such as sinusitis, nasal crusting, shortness of breath and pulmonary haemorrhage. The disease can also cause multiple nodules (with or without cavitation) to arise in the lung parenchyma similarly to that seen in this patient. Pleural effusions are seen in up to 20% of chest x-rays of GPA patients. The disease can initially manifest around middle-age.

Eosinophilic granulomatosis with polyangiitis also causes respiratory symptoms. Pulmonary nodules and pleural effusions may also be seen on imaging, however, pulmonary haemorrhage is not a typical symptom. Instead, wheeze and sinusitis tend to feature.

Pulmonary emboli are capable of causing shortness of breath, hypoxia and haemoptysis (as seen in this patient). They are diagnosed using a CT pulmonary angiogram to assess for filling defects in the pulmonary arteries. Normally, chest x-ray appearances are completely normal. However, in some cases (and also on CT imaging), there is evidence of pulmonary infarction. Pulmonary infarctions create wedge-shaped opacifications without the presence of air bronchograms. Instead, this patient's imaging shows multiple lung nodules, pleural effusion and airspace opacification suggestive of pulmonary haemorrhage.

Rheumatoid arthritis has multiple respiratory features including lower zone fibrosis, pulmonary nodules, pleural effusions and bronchiolitis obliterans. However, rheumatoid arthritis does not cause haemoptysis, making it the incorrect answer.

Sarcoidosis causes a range of pulmonary features from hilar lymphadenopathy to diffuse pulmonary infiltrates and fibrosis. The disease is most common in young Afro-Caribbean women and although shortness of breath and a dry cough are common symptoms, haemoptysis is not seen.

Discuss (6) | Improve

Next question

Granulomatosis with polyangiitis

Granulomatosis with polyangiitis is now the preferred term for Wegener's granulomatosis. It is an autoimmune condition associated with a necrotizing granulomatous vasculitis, affecting both the upper and lower respiratory tract as well as the kidneys.

Features

- upper respiratory tract: epistaxis, sinusitis, nasal crusting
- lower respiratory tract: dyspnoea, haemoptysis

- rapidly progressive glomerulonephritis ('pauci-immune', 80% of patients)
- saddle-shape nose deformity
- also: vasculitic rash, eye involvement (e.g. proptosis), cranial nerve lesions

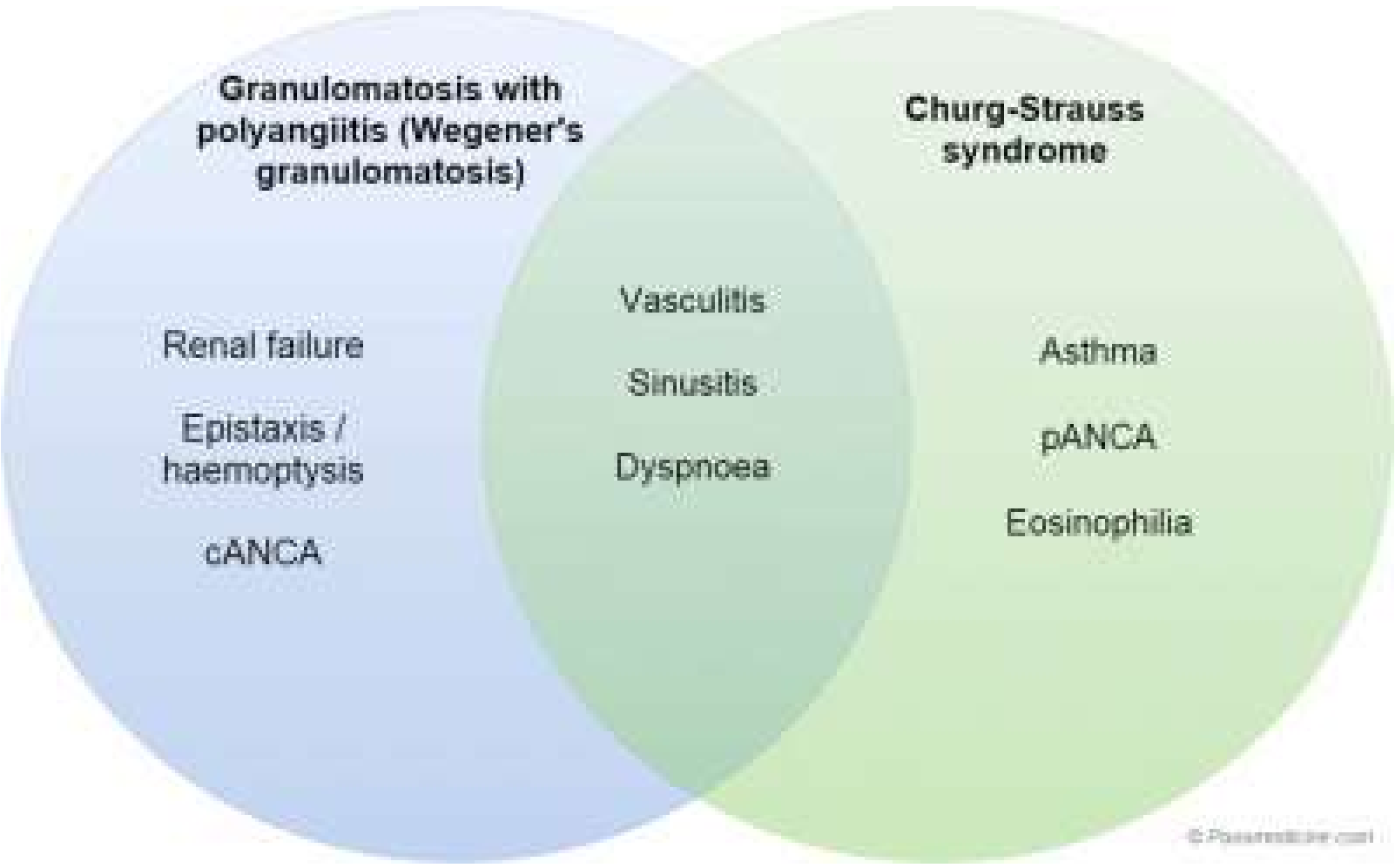

Comparison of granulomatosis with polyangiitis and Churg-Strauss syndrome

Investigations

- cANCA positive in > 90%, pANCA positive in 25%
- chest x-ray: wide variety of presentations, including cavitating lesions
- renal biopsy: epithelial crescents in Bowman's capsule

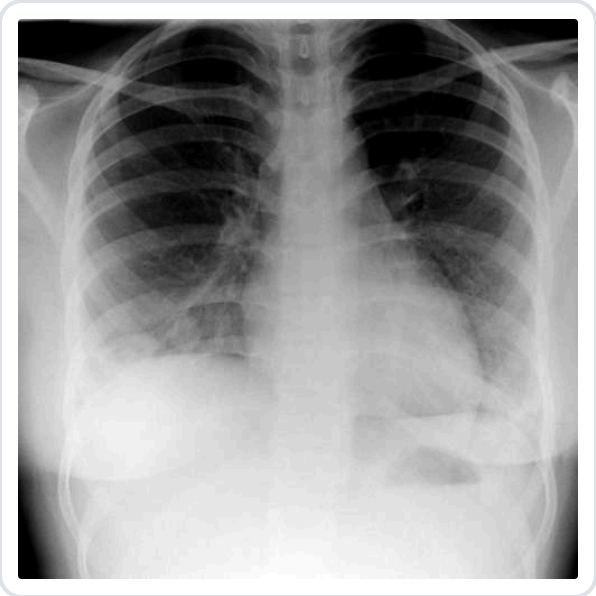

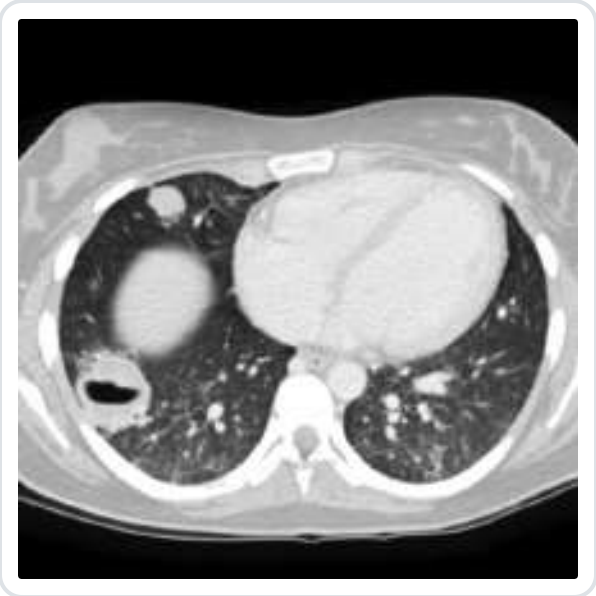

Management

- steroids
- cyclophosphamide (90% response)
- plasma exchange
- median survival = 8-9 years

123

Next question

Textbooks

High-yield textbook

Extended textbook

Media

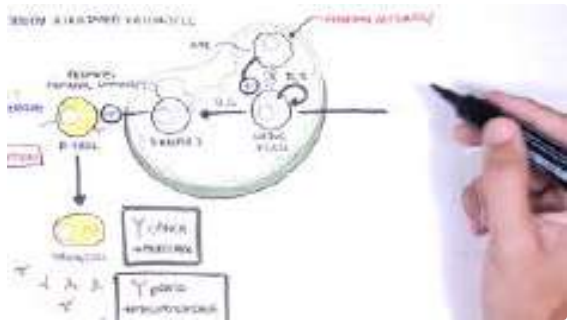

[ANCA (Anti-Neutrophil Cytoplasmic Antibody) Associated Vasculitis - Causes, Pathophysiology, Types]

Armando Hasudungan - YouTube

5 1

Granulomatosis with polyangiitis

Armando Hasudungan - YouTube

5 2

Report broken media

Score: **8.7%**

1 ✓

2 ✗

3 ✗

4	✗
5	✗
6	✗
7	✗
8	✗
9	✗
10	✗
11	✗
12	✗
13	✗
14	✗
15	✓
16	✗
17	✗
18	✗
19	✗
20	✗
21	✗
22	✗
23	✗

All contents of this site are © 2024 Passmedicine Limited

A 59-year-old man is admitted with fever, chest pain, and breathlessness. Chest x-ray confirms a large right-sided pleural effusion.

Thoracic ultrasound confirms a large volume pleural effusion and a suitable site is marked. A chest drain is inserted without complication and the drain yields frank pus. Post-procedure, the patient is well and observations are unchanged.

Twenty-four hours later, the effusion is much improved on x-ray and minimal fluid is draining. This remains mildly purulent but non-bloody. However, you note bubbling in the underwater seal. On review of the chart, this has been the case since insertion. The patient is much improved and the drain is still swinging.

What is the most likely diagnosis?

- Bronchopleural fistula
- Iatrogenic diaphragmatic injury
- Iatrogenic lung injury
- Infection with gas-producing organism
- Re-expansion pulmonary oedema

Submit answer

Reference ranges

Score: **0%**

1 -
2 -

3 -
4 -
5 -
6 -
7 -
8 -
9 -
10 -

All contents of this site are © 2024 Passmedicine Limited

A 59-year-old man is admitted with fever, chest pain, and breathlessness. Chest x-ray confirms a large right-sided pleural effusion.

Thoracic ultrasound confirms a large volume pleural effusion and a suitable site is marked. A chest drain is inserted without complication and the drain yields frank pus. Post-procedure, the patient is well and observations are unchanged.

Twenty-four hours later, the effusion is much improved on x-ray and minimal fluid is draining. This remains mildly purulent but non-bloody. However, you note bubbling in the underwater seal. On review of the chart, this has been the case since insertion. The patient is much improved and the drain is still swinging.

What is the most likely diagnosis?

- Bronchopleural fistula 65%
- Iatrogenic diaphragmatic injury 1%
- Iatrogenic lung injury 15%
- Infection with gas-producing organism 11%
- Re-expansion pulmonary oedema 7%

Bubbling of a chest drain inserted to drain an empyema may indicates that a bronchopleural fistula has occurred

Important for me Less important

The correct answer is **bronchopleural fistula**. This refers to abnormal communication between the pleural space and the bronchi. Complicated infection such as empyema is a well-recognised cause. Unexpected bubbling when a chest drain is inserted for empyema should raise the suspicion of this complication.

Iatrogenic diaphragmatic injury is incorrect. This is a very rare complication of chest drain insertion, made less likely by the use of ultrasound guidance and the large volume of fluid. It also would not lead to bubbling in the drain as there would be no leakage of air.

Iatrogenic lung injury is incorrect. While this could lead to bubbling of the drain, it is an unusual complication of chest drain insertion that is even less likely given the use of ultrasound guidance and the large volume of fluid here. We are also told that the procedure has gone ahead without complication. In the case of lung injury, we would expect increased pain and breathlessness during the procedure.

Infection with gas-producing organism is incorrect. An empyema may contain a variety of organisms but it is very rare to see gas in the fluid as a result of the infection alone. In the case described, there is also minimal fluid after 24 hours but ongoing bubbling, suggesting ongoing leakage of air into the pleural space. This suggests a structural problem such as a bronchopleural fistula.

Re-expansion pulmonary oedema is incorrect. This tends to present at the time of chest drain insertion with increased breathlessness, cough, and often chest pain. In the case described, the patient is well post-procedure with none of these features. It also would not cause bubbling in the drain.

Discuss (5) Improve

Next question

Chest drain

A chest drain is a tube inserted into the pleural cavity which creates a one-way valve, allowing movement of air or liquid out of the cavity.

Chest drain insertion is indicated in cases of:

- Pleural effusion
- Pneumothorax not suitable for conservative management or aspiration
- Empyema
- Haemothorax
- Haemopneumothorax
- Chylothorax
- In some cases of penetrating chest wall injury in ventilated patients

Insertion of a chest drain is relatively contraindicated in patients with any of the following:

- INR > 1.3
- Platelet count < 75
- Pulmonary bullae
- Pleural adhesions

Please note, all of the above represent only relative contraindications, addressing respiratory compromise in an emergency situation should always be on an individual case basis.

Once patient consent has been obtained and patient imaging assessed, the patient should be positioned in a supine position or at a 45º angle. The patient's forearm may be positioned behind the patient's head to allow easy access to the axilla. Identify the 5th intercostal space in the midaxillary line. Alternatively, positioning may be determined by ultrasound guidance, British Thoracic Society Guidance 'strongly recommend' use of ultrasound guidance in all cases of fluid within the pleura. The area should be anaesthetised using local anaesthetic injection (lidocaine, up to 3mg/kg). The drainage tube should then be inserted using a Seldinger technique. The drain tubing should then be secured using either a straight stitch or with an adhesive dressing.

Positioning can be confirmed by aspiration of fluid from the drainage tubing, by 'swinging' of the fluid within the drain tubing when the patient inspires and on chest x-ray.

Complications that may occur and which the patient should be advised of in the process of obtaining consent:

- Failure of insertion - the drain may be abutting the apical pleura, in which case it should be pulled back, or may be subcutaneous or in rare cases could enter the abdominal cavity. In both latter cases, the drain should be removed and re-sited.
- Bleeding - around the site of the drain or into the pleural space
- Infection
- Penetration of the lung
- Re-expansion pulmonary oedema

Re-expansion pulmonary oedema may be preceded by the onset of a cough and/or shortness of breath. In the event of concerns regarding re-expansion pulmonary oedema, the chest drain should be clamped and an urgent chest x-ray should be obtained. To avoid re-expansion pulmonary oedema, it is recommended that the drain tubing should be clamped regularly in the event of rapid fluid output i.e. drain output should not exceed 1L of fluid over a short period of time (less than 6 hours).

Removal of the chest drain is dependent upon the indication for insertion:

- In cases of fluid drainage from the pleural cavity, the drain should be removed when there has been no output for > 24 hours and imaging shows resolution of the fluid collection.
- In cases of pneumothorax, the drain should be removed when it is no longer bubbling spontaneously or when the patient coughs and ideally when imaging shows resolution of the pneumothorax.
- Drains inserted in cases of penetrating chest injury should be reviewed by the specialist to confirm an appropriate time for removal.

123

Next question

Textbooks

High-yield textbook

Extended textbook

Score: **8.7%**

1	✓
2	✗
3	✗
4	✗
5	✗
6	✗
7	✗
8	✗
9	✗
10	✗
11	✗
12	✗
13	✗
14	✗
15	✓

16 ✕
17 ✕
18 ✕
19 ✕
20 ✕
21 ✕
22 ✕
23 ✕

All contents of this site are © 2024 Passmedicine Limited

A 25-year-old man is reviewed prior to discharge. He was admitted to hospital one day ago with a small pneumothorax. As it was <1cm in size he was treated with high flow oxygen and he admitted for observations over 24 hours. His symptoms have resolved and a repeat chest x-Ray shows complete resolution of the pneumothorax. What advice should he be given before discharge?

- He should not dive for a year
- He should never dive unless he undergoes pleurodesis
- He should not drive for four weeks
- He should have no contact sport for four weeks
- He should not fly for four weeks

Submit answer

Reference ranges

Score: **0%**

1 -
2 -
3 -
4 -
5 -
6 -
7 -
8 -
9 -
10 -

11	-

All contents of this site are © 2024 Passmedicine Limited

A 25-year-old man is reviewed prior to discharge. He was admitted to hospital one day ago with a small pneumothorax. As it was <1cm in size he was treated with high flow oxygen and he admitted for observations over 24 hours. His symptoms have resolved and a repeat chest x-Ray shows complete resolution of the pneumothorax. What advice should he be given before discharge?

He should not dive for a year	4%
He should never dive unless he undergoes pleurodesis	72%
He should not drive for four weeks	2%
He should have no contact sport for four weeks	5%
He should not fly for four weeks	17%

'The correct answer is that he should be advised to never dive unless he undergoes pleurodesis. The British Thoracic Society (BTS) advises that a patient who has developed a pneumothorax should never dive again unless the undergo a pleurodesis procedure and are investigated following the procedure to ensure its success. He should also be advised not to fly, but this restriction is generally only for two weeks. There are no restrictions on driving or contact sport with pneumothorax.

Discuss (6) Improve

Next question

Pneumothorax: management

The British Thoracic Society (BTS) published updated guidelines for the management of spontaneous pneumothorax in 2023.

The updated guidelines put less emphasis on the size of the pneumothorax and more emphasis on whether the patient is symptomatic and the presence of high-risk characteristics.

Decision algorithm

The first step is assessing whether the patient is symptomatic

- the BTS define minimal symptoms as '*no significant pain or breathlessness and no physiological compromise*'
- no or minimal symptoms → conservative care, regardless of pneumothorax size
- symptomatic → assess for high-risk characteristics

If a pneumothorax is symptomatic, the next step is assessment for high-risk characteristics

- high-risk characteristics are defined as follows:
  - haemodynamic compromise (suggesting a tension pneumothorax)
  - significant hypoxia
  - bilateral pneumothorax
  - underlying lung disease
  - ≥ 50 years of age with significant smoking history
  - haemothorax
- if no high-risk characteristics are present, and it is safe to intervene, then there is a choice of intervention:
  - conservative care
  - ambulatory device
  - needle aspiration
- if high-risk characteristics are present, and it is safe to intervene → chest drain

How is safety or intervention determined?

- before a needle aspiration/chest drain insertion, the safety of intervention should be assessed
- this depends on the clinical context, but is usually:
  - 2cm laterally or apically on chest x-ray, or
  - any size on CT scan which can be safely accessed with radiological support

Management options

Conservative care

- patients with a primary spontaneous pneumothorax that is managed conservatively should be reviewed every 2-4 days as an outpatient
- patients with a secondary spontaneous pneumothorax that is managed conservatively should be monitored as an inpatient
- if stable, follow-up in the outpatients department in 2-4 weeks

Ambulatory care

- an example of an ambulatory device is the Rocketµ Pleural Vent„
- it includes an 8FG catheter mounted on an 18G needle and a pigtail catheter to minimize the risk of occlusion
- ambulatory devices typically have a one-way valve and vent to prevent air and fluid return to the pleural space while allowing for controlled escape of air and drainage of fluid
- many devices also have an indication diaphragm that signals when the catheter tip enters the pleural space and continues to fluctuate with respiration, aiding in the assessment of pneumothorax resolution

Needle aspiration

- a chest drain should be inserted if needle aspiration of a pneumothorax is unsuccessful
- if resolved, discharge and follow-up in the outpatients department in 2-4 weeks

Chest drain insertion

- daily review as an inpatient
- remove drain when resolved
- discharge and follow-up in the outpatients department in 2-4 weeks

Persistentent / recurrent pneumothorax

If a patient has a persistent air leak or insufficient lung reexpansion despite chest drain insertion, or the patient has recurrent pneumothoraces, then video-assisted thoracoscopic surgery (VATS) should be considered to allow for mechanical/chemical pleurodesis +/- bullectomy.

Discharge advice

Smoking

- patients should be advised to avoid smoking to reduce the risk of further episodes - the lifetime risk of developing a pneumothorax in healthy smoking men is around 10% compared with around 0.1% in non-smoking men

Fitness to fly

- absolute contraindication, the CAA suggest patients may travel 2 weeks after successful drainage if there is no residual air. The British Thoracic Society used to recommend not travelling by air for a period of 6 weeks but this has now been changed to 1 week post check x-ray

Scuba diving

- the BTS guidelines state: '*Diving should be permanently avoided unless the patient has undergone bilateral surgical pleurectomy and has normal lung function and chest CT scan postoperatively.*'

Image gallery

+ Q 123

Next question >

B I A T↕

Textbooks

High-yield textbook

Extended textbook

Links

British Thoracic Society 2 1

[2023 Pleural disease guidelines]

Suggest link | Report broken link

Media

How to identify pneumothorax on a chest X-ray

Medmastery - YouTube 30 1

Pneumothorax

Zero To Finals - YouTube 9 1

Pneumothorax

Osmosis - YouTube 6 1

Needle Aspiration of Pneumothorax

NEJM - YouTube 10 6

Report broken media

Score: **8.7%**

1	✓
2	✗
3	✗
4	✗
5	✗
6	✗
7	✗
8	✗
9	✗
10	✗
11	✗
12	✗
13	✗
14	✗
15	✓
16	✗
17	✗
18	✗
19	✗
20	✗
21	✗
22	✗
23	✗

All contents of this site are © 2024 Passmedicine Limited

Back to top

A 35-year-old man who lives in long-term residential care presents with drowsiness and increased respiratory effort. There is new consolidation on his chest x-ray and he is diagnosed with pneumonia. His care workers reported that he had some vomiting episodes 5 days previously.

A sputum sample is analysed in the microbiology laboratory. On microscopy of the sample, a mixture of Gram-positive cocci and Gram-negative rods is visible. At 48 hours there is growth on both the blood agar plate and the anaerobic agar plate.

What finding on sputum culture would provide evidence that his pneumonia is due to aspiration?

- Bacteria which are sensitive to metronidazole
- Bacteria which are sensitive to optochin
- Bacteria which are sensitive to penicillin
- Catalase negative organisms
- Growth of Gram negative cocci

Submit answer

Reference ranges

Score: **0%**

1 -
2 -
3 -
4 -
5 -
6 -

7	-
8	-
9	-
10	-
11	-
12	-

All contents of this site are © 2024 Passmedicine Limited

Back to top

A 35-year-old man who lives in long-term residential care presents with drowsiness and increased respiratory effort. There is new consolidation on his chest x-ray and he is diagnosed with pneumonia. His care workers reported that he had some vomiting episodes 5 days previously.

A sputum sample is analysed in the microbiology laboratory. On microscopy of the sample, a mixture of Gram-positive cocci and Gram-negative rods is visible. At 48 hours there is growth on both the blood agar plate and the anaerobic agar plate.

What finding on sputum culture would provide evidence that his pneumonia is due to aspiration?

- Bacteria which are sensitive to metronidazole 62%
- Bacteria which are sensitive to optochin 6%
- Bacteria which are sensitive to penicillin 3%
- Catalase negative organisms 11%
- Growth of Gram negative cocci 18%

Anaerobic bacteria in sputum culture suggest aspiration pneumonia

Important for me Less important

Anaerobic bacteria often contribute to aspiration pneumonia as these bacteria are part of the microflora of the mouth and digestive tract, and may enter the respiratory system via aspiration of oral or gastrointestinal fluids. They are commonly found to cause infection alongside other aerobic bacteria. It is important to consider whether a patient's pneumonia may be due to aspiration, as not all the commonly used antibiotic options for community-acquired pneumonia will treat anaerobic infections.

Most **anaerobic bacteria** are sensitive to metronidazole, and conversely, metronidazole does not have any activity against non-anaerobes. Therefore the presence of metronidazole-sensitive organisms suggests that there are anaerobes present, which are often found in aspiration pneumonia.

Optochin is used as a test to differentiate *Streptococcus pneumoniae* from other alpha-haemolytic Streptococci. *Strep pneumoniae* is a common cause of community-acquired pneumonia and would

not suggest aspiration pneumonia.

Most **anaerobic bacteria** are not sensitive to penicillin (with a few exceptions). A penicillin-sensitive organism grown from sputum would be most likely to be a typical organism such as *Strep pneumoniae*.

The **catalase test** is used to differentiate Gram-positive cocci into *Staphylococci* or *Streptococci*. Streptococci are catalase negative.

The most important **Gram-negative cocci** are *Neisseria* and *Moraxella*. *Moraxella catarrhalis* can cause respiratory tract infections but is not associated with aspiration pneumonia.

Discuss Improve

Next question

Aspiration pneumonia

Aspiration pneumonia is a pneumonia that develops as a result of foreign materials gaining entry to the bronchial tree, usually oral or gastric contents such as food and saliva. Depending on the acidity of the aspirate a chemical pneumonitis can develop, as well as bacterial pathogens adding to the inflammation.

Aspiration pneumonia often results from an incompetent swallowing mechanism, such as those that occur in neurological disease or injury such as stroke, multiple sclerosis and intoxication. Iatrogenic causes, such as intubation, can also result in aspiration pneumonia developing. Risk factors for the development of aspiration pneumonia include:

- Poor dental hygiene
- Swallowing difficulties
- Prolonged hospitalization or surgical procedures
- Impaired consciousness
- Impaired mucociliary clearance

The right middle and lower lung lobes are the most common sites affected, due to the larger calibre and more vertical orientation of the right main bronchus.

The bacteria implicated in aspiration pneumonia may be aerobic or anaerobic. Examples of aerobic bacteria include:

- *Streptococcus pneumoniae*
- *Staphylococcus aureus*

- *Haemophilus influenzae*
- *Pseudomonas aeruginosa*
- Klebsiella: often seen in aspiration lobar pneumonia in alcoholics

Examples of anaerobic bacteria include:

- *Bacteroides*
- *Prevotella*
- *Fusobacterium*
- *Peptostreptococcus*

+ Q 123

Next question >

Textbooks

High-yield textbook

Extended textbook

Score: **8.7%**

1 ✓
2 ✗
3 ✗
4 ✗
5 ✗
6 ✗
7 ✗

8	✗
9	✗
10	✗
11	✗
12	✗
13	✗
14	✗
15	✓
16	✗
17	✗
18	✗
19	✗
20	✗
21	✗
22	✗
23	✗

All contents of this site are © 2024 Passmedicine Limited

Back to top

A 65-year-old gentleman who is visiting is family and usually resides in Chile attends the emergent department with shortness of breath of two days worsening.

Through translation by a relative, you understand that he is retired and formerly worked on coal extraction and in silica extraction but retired a few years ago due to health issues.

He usually has problems with feeling short of breath and can just about manage a flight of stairs but he has worsened and is now short of breath at rest. He has a cough which is productive of black sputum but he reports this is normal for him. He has lost 5 stone in weight over the last year.

He has a history of rheumatoid arthritis, ischaemic heart disease and hypertension. He is a smoker of 10 pack years and does not recall any exposure to tuberculosis or foreign pets.

On examination, he is in respiratory distress with use of the accessory muscles. No JVP can be seen and there are crepitations throughout the mid and upper zones. He looks drowsy and has peripheral cyanosis. There is clubbing and he is a febrile. He is saturating at 92% on 10 litres of oxygen via a face mask. There are no murmurs or signs of endocarditis.

ABG now pH	7.31
PaO2	7.92 kPa
PaCO2	6.44 kPa
HCO3	21 mmol/l
Chest X-Ray	upper zone reticulonodular changes with large cavity on right apex
High resolution CT	ground glass opacities in upper zones with a modular appearance and centroacinar emphysema in the lower zone

Hb	110 g/l	Na^+	139 mmol/l
Platelets	310* 10^9/l	K^+	4.5 mmol/l
WBC	12.3 * 10^9/l	Urea	9.9 mmol/l
Neuts	11.9 * 10^9/l	Creatinine	178 µmol/l
Lymphs	0.2 * 10^9/l	CRP	156 mg/l
c-ANCA	pending	p-ANCA	pending
Rheumatoid factor	pending		

What is the likely diagnosis?

- Silicotuberculosis
- Idiopathic pulmonary fibrosis
- Granulomatosis with polyangiitis
- Caplan Syndrome
- *pneumocystis jirovecii*

Submit answer

Reference ranges

Score: **0%**

1 -
2 -
3 -
4 -
5 -
6 -
7 -
8 -
9 -
10 -
11 -
12 -
13 -

All contents of this site are © 2024 Passmedicine Limited

Back to top

A 65-year-old gentleman who is visiting is family and usually resides in Chile attends the emergent department with shortness of breath of two days worsening.

Through translation by a relative, you understand that he is retired and formerly worked on coal extraction and in silica extraction but retired a few years ago due to health issues.

He usually has problems with feeling short of breath and can just about manage a flight of stairs but he has worsened and is now short of breath at rest. He has a cough which is productive of black sputum but he reports this is normal for him. He has lost 5 stone in weight over the last year.

He has a history of rheumatoid arthritis, ischaemic heart disease and hypertension. He is a smoker of 10 pack years and does not recall any exposure to tuberculosis or foreign pets.

On examination, he is in respiratory distress with use of the accessory muscles. No JVP can be seen and there are crepitations throughout the mid and upper zones. He looks drowsy and has peripheral cyanosis. There is clubbing and he is a febrile. He is saturating at 92% on 10 litres of oxygen via a face mask. There are no murmurs or signs of endocarditis.

ABG now pH	7.31
PaO2	7.92 kPa
PaCO2	6.44 kPa
HCO3	21 mmol/l
Chest X-Ray	upper zone reticulonodular changes with large cavity on right apex
High resolution CT	ground glass opacities in upper zones with a modular appearance and centroacinar emphysema in the lower zone

Hb	110 g/l	Na^+	139 mmol/l
Platelets	310* 10^9/l	K^+	4.5 mmol/l
WBC	12.3 * 10^9/l	Urea	9.9 mmol/l
Neuts	11.9 * 10^9/l	Creatinine	178 µmol/l
Lymphs	0.2 * 10^9/l	CRP	156 mg/l
c-ANCA	pending	p-ANCA	pending
Rheumatoid factor	pending		

What is the likely diagnosis?

Silicotuberculosis	54%
Idiopathic pulmonary fibrosis	4%
Granulomatosis with polyangiitis	6%
Caplan Syndrome	35%
pneumocystis jirovecii	2%

Rheumatoid arthritis causes a severe form of coal workers pneumoconiosis called Caplan's syndrome

Important for me Less important

A complex background in a gentleman with severe respiratory failure. He has a background lung disease with smoking and possible coal and silica exposure. He is also immunosuppressed and so is at risk of PCP.

The key features are melanoptysis the coughing up of black sputum which is pathognomonic of coal workers pneumoconiosis. This disease is typically leads to the severe progressive massive fibrosis in those with rheumatoid arthritis which is named eponymously as Caplan's syndrome.

Discuss (16) Improve

Next question

Rheumatoid arthritis: respiratory manifestations

A variety of respiratory problems may be seen in patients with rheumatoid arthritis:

- pulmonary fibrosis
- pleural effusion
- pulmonary nodules
- bronchiolitis obliterans
    - progressive dyspnoea
    - obstructive pattern on spirometry
    - centrilobular nodules, bronchial wall thickening is seen on CT
- complications of drug therapy e.g. methotrexate pneumonitis

- pleurisy
- Caplan's syndrome
  - massive fibrotic nodules with occupational coal dust exposure
- infection (possibly atypical) secondary to immunosuppression

123

Next question

Textbooks

High-yield textbook

Extended textbook

Score: **8.7%**

1	✓
2	✗
3	✗
4	✗
5	✗
6	✗
7	✗

8	✗
9	✗
10	✗
11	✗
12	✗
13	✗
14	✗
15	✓
16	✗
17	✗
18	✗
19	✗
20	✗
21	✗
22	✗
23	✗

All contents of this site are © 2024 Passmedicine Limited

Back to top

A 32-year-old woman presents to the emergency department with shortness of breath. This has been worsening over the past 24 hours and was preceded by coryzal symptoms. She has a past medical history of asthma for which she takes regular montelukast and a Seretideµ inhaler.

On examination, she is alert but unable to speak in full sentences. Her temperature is 37.1ºC, oxygen saturation 92% on air, heart rate 83 beats per minute, respiratory rate 32 breaths per minute and blood pressure 130/83 mmHg. Auscultation of the chest reveals bilateral wheeze and poor air entry in the bases.

Her initial arterial blood gas on room air shows the following:

pH	7.46 (7.35-7.45)
PaO_2	7.5 kPa (10-13 kPa)
$PaCo_2$	3.1 kPa (4.7-6.0 kPa)
Lac	2.0 (<2.0)
HCo_3	24 (22-26)
BE	+3 (-2-2)

You initiate management with high flow oxygen, back-to-back salbutamol nebulisers, an ipratropium bromide nebuliser, intravenous hydrocortisone and intravenous magnesium sulphate.

On reassessment, in the subsequent hour, she appears more comfortable with a temperature of 37.3ºC, oxygen saturation 100% on high flow oxygen, heart rate 92 beats per minute, respiratory rate of 24 breaths per minute and blood pressure 126/78mmHg.

You repeat an arterial blood gas:

pH	7.34 (7.35-7.45)
PaO_2	43 kPa (10-13 kPa)
$PaCo_2$	3.2 kPa (4.7-6.0 kPa)
Lac	6.4 (<2.0)
HCo_3	19 (22-26)
BE	-5 (-2-2)

What is the most likely cause for the hyperlactatemia seen on the subsequent arterial blood gas?

- Sepsis
- Magnesium sulfate
- Salbutamol
- Pulmonary embolism
- Stress response

Submit answer

Reference ranges

Score: **0%**

1	-
2	-
3	-
4	-
5	-
6	-
7	-
8	-
9	-
10	-
11	-
12	-
13	-
14	-

All contents of this site are © 2024 Passmedicine Limited

A 32-year-old woman presents to the emergency department with shortness of breath. This has been worsening over the past 24 hours and was preceded by coryzal symptoms. She has a past medical history of asthma for which she takes regular montelukast and a Seretideµ inhaler.

On examination, she is alert but unable to speak in full sentences. Her temperature is 37.1ºC, oxygen saturation 92% on air, heart rate 83 beats per minute, respiratory rate 32 breaths per minute and blood pressure 130/83 mmHg. Auscultation of the chest reveals bilateral wheeze and poor air entry in the bases.

Her initial arterial blood gas on room air shows the following:

pH	7.46 (7.35-7.45)
PaO_2	7.5 kPa (10-13 kPa)
$PaCo_2$	3.1 kPa (4.7-6.0 kPa)
Lac	2.0 (<2.0)
HCo_3	24 (22-26)
BE	+3 (-2-2)

You initiate management with high flow oxygen, back-to-back salbutamol nebulisers, an ipratropium bromide nebuliser, intravenous hydrocortisone and intravenous magnesium sulphate.

On reassessment, in the subsequent hour, she appears more comfortable with a temperature of 37.3ºC, oxygen saturation 100% on high flow oxygen, heart rate 92 beats per minute, respiratory rate of 24 breaths per minute and blood pressure 126/78mmHg.

You repeat an arterial blood gas:

pH	7.34 (7.35-7.45)
PaO_2	43 kPa (10-13 kPa)
$PaCo_2$	3.2 kPa (4.7-6.0 kPa)
Lac	6.4 (<2.0)
HCo_3	19 (22-26)
BE	-5 (-2-2)

What is the most likely cause for the hyperlactatemia seen on the subsequent arterial blood gas?

Sepsis	10%
Magnesium sulfate	22%
Salbutamol	36%
Pulmonary embolism	3%
Stress response	30%

Excessive salbutamol use in acute asthma can lead to hyperlactatemia

Important for me Less important

Salbutamol is a cause of type B lactic acidosis (that is not caused by tissue hypoperfusion or hypoxia resulting in anaerobic metabolism). This should be kept in mind along with the clinical picture - in this case, the patient was orientated and not clinically toxic, hypoxic or hypotensive.

Magnesium sulfate is not reported to cause lactic acidosis.

The clinical picture is not in keeping with sepsis nor a pulmonary embolism. The symptoms, examination findings, observations and response to treatment are in keeping with a life-threatening attack of asthma.

There is evidence that high levels of lactatemia in acute asthma are due to the effects of β-adrenergic agonists rather than a physiological response to the stress.

Discuss (4) Improve

Next question

Drugs used in respiratory medicine

Drug	Mechanism of action	Notes
Salbutamol	Beta receptor agonist	• Short-acting inhaled bronchodilator. Relaxes bronchial smooth muscle through effects on

Drug	Mechanism of action	Notes
		beta 2 receptors • Used in asthma and chronic obstructive pulmonary disease (COPD). • Salmeterol has similar effects but is long-acting
Corticosteroids	Anti-inflammatory	• Inhaled corticosteroids are used as maintenance therapy • Oral or intravenous corticosteroids are used following an acute exacerbation of asthma or COPD
Ipratropium	Blocks the muscarinic acetylcholine receptors	• Short-acting inhaled bronchodilator. Relaxes bronchial smooth muscle • Used primarily in COPD • Tiotropium has similar effects but is long-acting
Methylxanthines (e.g. theophylline)	Non-specific inhibitor of phosphodiesterase resulting in an increase in cAMP	• Given orally or intravenously • Has a narrow therapeutic index
Monteleukast, zafirlukast	Blocks leukotriene receptors	• Usually taken orally • Useful in aspirin-induced asthma

+ Q 123

Next question >

Textbooks

High-yield textbook

Extended textbook

Score: **8.7%**

1	✓
2	✗
3	✗
4	✗
5	✗
6	✗
7	✗
8	✗
9	✗
10	✗
11	✗
12	✗
13	✗
14	✗
15	✓
16	✗
17	✗
18	✗
19	✗
20	✗
21	✗
22	✗
23	✗

All contents of this site are © 2024 Passmedicine Limited

Back to top

A 32-year-old businessman presented with a 1-week history of a productive cough of yellow sputum, mild wheeze, and mild dyspnoea. He has a 2 pack year history of smoking but has been otherwise well. On examination, his blood pressure is 120/90 mmHg, heart rate is 80 beats/minute, oxygen saturation 98% on room air. On auscultation, there is a mild wheeze but his chest is otherwise clear.

Hb	140 g/l
Platelets	350 * 10^9/l
WBC	13 * 10^9/l

Chest x-ray is clear.

How should he be managed?

- Amoxicillin
- Amoxicillin with clavulanic acid
- Amoxicillin and doxycycline
- Cough medicine and adequate hydration
- Adequate hydration

Submit answer

Reference ranges

2	-
3	-
4	-
5	-
6	-
7	-
8	-
9	-
10	-
11	-
12	-
13	-
14	-
15	-

All contents of this site are © 2024 Passmedicine Limited

A 32-year-old businessman presented with a 1-week history of a productive cough of yellow sputum, mild wheeze, and mild dyspnoea. He has a 2 pack year history of smoking but has been otherwise well. On examination, his blood pressure is 120/90 mmHg, heart rate is 80 beats/minute, oxygen saturation 98% on room air. On auscultation, there is a mild wheeze but his chest is otherwise clear.

Hb	140 g/l
Platelets	350 * 10^9/l
WBC	13 * 10^9/l

Chest x-ray is clear.

How should he be managed?

- Amoxicillin 41%
- Amoxicillin with clavulanic acid 15%
- Amoxicillin and doxycycline 6%
- Cough medicine and adequate hydration 20%
- Adequate hydration 18%

The clinical scenario is of acute bronchitis in an otherwise well man. This is usually a self-limiting condition which resolves without antibiotics within 3 weeks and therefore the best management strategy is adequate analgesia and hydration. Cough medicines are not routinely recommended by NICE as they suppress natural mechanisms to keep the airways clear.

In someone who has a chronic chest condition, antibiotics may be prescribed but a delayed prescription strategy should be considered.

Finally, it is important to always remember to provide smoking cessation advice.

Discuss (11) Improve

Respiratory tract infections: NICE guidelines

NICE issued guidance in 2008 on the management of respiratory tract infection, focusing on the prescribing of antibiotics for self-limiting respiratory tract infections in adults and children in primary care

A no antibiotic prescribing or delayed antibiotic prescribing approach is generally recommended for patients with acute otitis media, acute sore throat/acute pharyngitis/acute tonsillitis, common cold, acute rhinosinusitis or acute cough/acute bronchitis.

However, an immediate antibiotic prescribing approach may be considered for:
- children younger than 2 years with bilateral acute otitis media
- children with otorrhoea who have acute otitis media
- patients with acute sore throat/acute pharyngitis/acute tonsillitis when 3 or more Centor criteria are present

The Centor criteria* are as follows:
- presence of tonsillar exudate
- tender anterior cervical lymphadenopathy or lymphadenitis
- history of fever
- absence of cough

If the patient is deemed at risk of developing complications, an immediate antibiotic prescribing policy is recommended
- are systemically very unwell
- have symptoms and signs suggestive of serious illness and/or complications (particularly pneumonia, mastoiditis, peritonsillar abscess, peritonsillar cellulitis, intraorbital or intracranial complications)
- are at high risk of serious complications because of pre-existing comorbidity. This includes patients with significant heart, lung, renal, liver or neuromuscular disease, immunosuppression, cystic fibrosis, and young children who were born prematurely
- are older than 65 years with acute cough and two or more of the following, or older than 80 years with acute cough and one or more of the following:
- - hospitalisation in previous year
- - type 1 or type 2 diabetes
- - history of congestive heart failure
- - current use of oral glucocorticoids

The guidelines also suggest that patients should be advised how long respiratory tract infections may last:

- acute otitis media: 4 days
- acute sore throat/acute pharyngitis/acute tonsillitis: 1 week
- common cold: 1 1/2 weeks
- acute rhinosinusitis: 2 1/2 weeks
- acute cough/acute bronchitis: 3 weeks

*if 3 or more of the criteria are present there is a 40-60% chance the sore throat is caused by Group A beta-haemolytic *Streptococcus*

123

Next question

Textbooks

High-yield textbook

Extended textbook

Links

NICE

2008 Respiratory tract infection guidelines

7 6

Suggest link

Report broken link

Score: **8.7%**

1	✓
2	✗
3	✗
4	✗
5	✗
6	✗
7	✗
8	✗
9	✗
10	✗
11	✗
12	✗
13	✗
14	✗
15	✓
16	✗
17	✗
18	✗
19	✗
20	✗
21	✗
22	✗
23	✗

All contents of this site are © 2024 Passmedicine Limited

Back to top

A 68-year-old woman presents to the emergency department with shortness of breath. A CT pulmonary angiogram is undertaken, which excludes a pulmonary embolism. However, it demonstrates a 4.5mm solid nodule in the right midzone.

What is the appropriate management of this lesion?

- Biopsy immediately
- CT PET immediately
- MRI chest in 3 months
- No further investigation required
- Traditional CT chest in 12 months

Submit answer

Reference ranges

Score: **0%**

1 -
2 -
3 -
4 -
5 -
6 -
7 -
8 -
9 -
10 -

11	-
12	-
13	-
14	-
15	-
16	-

All contents of this site are © 2024 Passmedicine Limited

A 68-year-old woman presents to the emergency department with shortness of breath. A CT pulmonary angiogram is undertaken, which excludes a pulmonary embolism. However, it demonstrates a 4.5mm solid nodule in the right midzone.

What is the appropriate management of this lesion?

Biopsy immediately	11%
CT PET immediately	10%
MRI chest in 3 months	3%
No further investigation required	52%
Traditional CT chest in 12 months	24%

Solitary, solid and non-calcified lung nodules of less than 5mm in size do not warrant further investigations or monitoring

Important for me   Less important

No further investigation required is the right answer. Solitary, solid and non-calcified lung nodules of less than 5mm in size do not warrant further investigations or monitoring.

Biopsy immediately is incorrect. If a lesion is determined to be sufficiently sinister to require a biopsy to exclude malignancy, a PET scan should be undertaken prior to biopsy. If the PET scan is positive the patient should proceed to biopsy.

CT PET immediately is incorrect. This is the investigation undertaken if a nodule is > 8mm and high risk. High-risk features include older age, female sex, family history of lung cancer, emphysema, spiculation and larger nodule size.

MRI chest in 3 months is incorrect. MRI scanning is not typically used in the investigation and monitoring of lung nodules.

Traditional CT chest in 12 months is incorrect. Undertaking a repeat CT in 3 rather than 12 months would be an appropriate option if the nodule was 5-6mm, or =>8mm and low-risk.

Discuss (2) Improve

Next question

Solitary lung nodule

BTS guidelines for lung nodules:

- Nodule <5mm, or clear benign features, or unsuitable for treatment: can be discharged
- Nodule =>8mm and high risk*: then CT-PET, and if CT-PET shows high uptake then biopsy
- Nodule 5-6mm, or =>8mm and low-risk*: then CT surveillance
- CT surveillance: if 5-6mm then at 1 year, if =>6 then in three months

*To determine the risk of malignancy following CT the BTS uses the Brock model

123

Next question

Textbooks

High-yield textbook

Extended textbook

Score: **8.7%**

1 ✓

2	✗
3	✗
4	✗
5	✗
6	✗
7	✗
8	✗
9	✗
10	✗
11	✗
12	✗
13	✗
14	✗
15	✓
16	✗
17	✗
18	✗
19	✗
20	✗
21	✗
22	✗
23	✗

All contents of this site are © 2024 Passmedicine Limited

Back to top

A 63-year-old man presents to his general practitioner complaining of frequent wheezy exacerbations. He has a past medical history of chronic obstructive pulmonary disease. There is no history of asthma or atopy. He takes salbutamol as required. He is an ex-smoker with 35 pack-year history. He does not drink alcohol.

On examination, he is comfortable at rest. There is a mild expiratory wheeze audible in the midzones. The jugular venous pulse is not raised and there is no peripheral oedema.

Blood tests:

Hb	138 g/L	Male: (135-180) Female: (115 - 160)
Platelets	189 * 10^9/L	(150 - 400)
WBC	4.8 * 10^9/L	(4.0 - 11.0)
Neuts	3.1 * 10^9/L	(2.0 - 7.0)
Lymphs	1.5 * 10^9/L	(1.0 - 3.5)
Mono	0.2 * 10^9/L	(0.2 - 0.8)
Eosin	0.0 * 10^9/L	(0.0 - 0.4)
Na^+	138 mmol/L	(135 - 145)
K^+	4.2 mmol/L	(3.5 - 5.0)
Urea	5.2 mmol/L	(2.0 - 7.0)
Creatinine	93 µmol/L	(55 - 120)

Previous investigations did not demonstrate substantial variation in FEV1 over time or substantial diurnal variation in peak expiratory flow.

What is the most appropriate addition to his medication regimen?

- Long acting beta agonist (LABA)
- Long acting beta agonist (LABA) + long acting muscarinic antagonist (LAMA)
- Long acting beta agonist (LABA) and inhaled corticosteroid (ICS)

Long acting muscarinic antagonist (LAMA)

LABA + LAMA + ICS

Submit answer

Reference ranges

Score: **0%**

1 -
2 -
3 -
4 -
5 -
6 -
7 -
8 -
9 -
10 -
11 -
12 -
13 -
14 -
15 -
16 -
17 -

All contents of this site are © 2024 Passmedicine Limited

A 63-year-old man presents to his general practitioner complaining of frequent wheezy exacerbations. He has a past medical history of chronic obstructive pulmonary disease. There is no history of asthma or atopy. He takes salbutamol as required. He is an ex-smoker with 35 pack-year history. He does not drink alcohol.

On examination, he is comfortable at rest. There is a mild expiratory wheeze audible in the midzones. The jugular venous pulse is not raised and there is no peripheral oedema.

Blood tests:

Hb	138 g/L	Male: (135-180) Female: (115 - 160)
Platelets	189 * 10^9/L	(150 - 400)
WBC	4.8 * 10^9/L	(4.0 - 11.0)
Neuts	3.1 * 10^9/L	(2.0 - 7.0)
Lymphs	1.5 * 10^9/L	(1.0 - 3.5)
Mono	0.2 * 10^9/L	(0.2 - 0.8)
Eosin	0.0 * 10^9/L	(0.0 - 0.4)
Na^+	138 mmol/L	(135 - 145)
K^+	4.2 mmol/L	(3.5 - 5.0)
Urea	5.2 mmol/L	(2.0 - 7.0)
Creatinine	93 µmol/L	(55 - 120)

Previous investigations did not demonstrate substantial variation in FEV1 over time or substantial diurnal variation in peak expiratory flow.

What is the most appropriate addition to his medication regimen?

- Long acting beta agonist (LABA) 13%
- Long acting beta agonist (LABA) + long acting muscarinic antagonist (LAMA) 60%
- Long acting beta agonist (LABA) and inhaled corticosteroid (ICS) 14%

Long acting muscarinic antagonist (LAMA) 11%

LABA + LAMA + ICS 2%

COPD - still breathless despite using SABA/SAMA and **no** asthma/steroid responsive features → add a LABA + LAMA

Important for me Less important

Long-acting beta2-agonist (LABA) + long-acting muscarinic antagonist (LAMA) is the correct answer. This patient has poorly controlled COPD. He has no features to suggest steroid responsiveness and therefore the next step should be the addition of a LABA+LAMA. He does not warrant inhaled corticosteroids on this basis.

Long-acting beta2-agonist (LABA) is incorrect. The patient needs a combination of LABA/LAMA.

Long-acting muscarinic antagonist (LAMA) is incorrect. The patient needs a combination of a LABA/LAMA.

LABA + LAMA + ICS is incorrect. This combination would be warranted in those patients with steroid-responsive features that fail a LABA + ICS combination.

Long-acting beta2-agonist (LABA) and inhaled corticosteroid (ICS) is incorrect. This would be a suitable choice if the patient had features of steroid-responsiveness.

Discuss (4) Improve

Next question

COPD: stable management

NICE updated its guidelines on the management of chronic obstructive pulmonary disease (COPD) in 2018.

General management

- >smoking cessation advice: including offering nicotine replacement therapy, varenicline or bupropion
- annual influenza vaccination
- one-off pneumococcal vaccination

- pulmonary rehabilitation to all people who view themselves as functionally disabled by COPD (usually Medical Research Council [MRC] grade 3 and above)

Bronchodilator therapy

- a short-acting beta2-agonist (SABA) or short-acting muscarinic antagonist (SAMA) is first-line treatment
- for patients who remain breathless or have exacerbations despite using short-acting bronchodilators the next step is determined by whether the patient has '*asthmatic features/features suggesting steroid responsiveness*'

There are a number of criteria NICE suggest to determine whether a patient has asthmatic/steroid responsive features:

- any previous, secure diagnosis of asthma or of atopy
- a higher blood eosinophil count - note that NICE recommend a full blood count for all patients as part of the work-up
- substantial variation in FEV1 over time (at least 400 ml)
- substantial diurnal variation in peak expiratory flow (at least 20%)

Interestingly NICE do not recommend formal reversibility testing as one of the criteria. In the guidelines they state that *'routine spirometric reversibility testing is not necessary as part of the diagnostic process or to plan initial therapy with bronchodilators or corticosteroids. It may be unhelpful or misleading...*'. They then go on to discuss why they have reached this conclusion. Please see the guidelines for more details.

No asthmatic features/features suggesting steroid responsiveness

- add a long-acting beta2-agonist (LABA) + long-acting muscarinic antagonist (LAMA)
  - if already taking a SAMA, discontinue and switch to a SABA

Asthmatic features/features suggesting steroid responsiveness

- LABA + inhaled corticosteroid (ICS)
- if patients remain breathless or have exacerbations offer triple therapy i.e. LAMA + LABA + ICS
  - if already taking a SAMA, discontinue and switch to a SABA
- NICE recommend the use of combined inhalers where possible

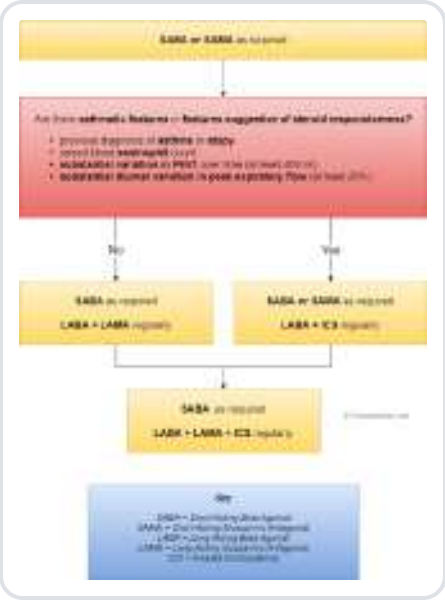

Oral theophylline

- NICE only recommends theophylline after trials of short and long-acting bronchodilators or to people who cannot used inhaled therapy
- the dose should be reduced if macrolide or fluoroquinolone antibiotics are co-prescribed

Oral prophylactic antibiotic therapy

- azithromycin prophylaxis is recommended in select patients
- patients should not smoke, have optimised standard treatments and continue to have exacerbations
- other prerequisites include a CT thorax (to exclude bronchiectasis) and sputum culture (to exclude atypical infections and tuberculosis)
- LFTs and an ECG to exclude QT prolongation should also be done as azithromycin can prolong the QT interval

Standby medication: NICE recommend offering a short course of oral corticosteroids and oral antibiotics to keep at home if: NICE

- have had an exacerbation within the last year
- understand how to take the medication, and are aware of associated risks and benefits
- know to when to seek help and when to ask for replacements once medication has been used

Mucolytics

- should be 'considered' in patients with a chronic productive cough and continued if symptoms improve

Phosphodiesterase-4 (PDE-4) inhibitors NICE

- oral PDE-4 inhibitors such as roflumilast reduce the risk of COPD exacerbations in patients with severe COPD and a history of frequent COPD exacerbations
- NICE recommend if:
    - the disease is severe, defined as a forced expiratory volume in 1 second (FEV1) after a bronchodilator of less than 50% of predicted normal, and
    - the person has had 2 or more exacerbations in the previous 12 months despite triple inhaled therapy with a long-acting muscarinic antagonist, a long-acting beta-2 agonist and an inhaled corticosteroid

Cor pulmonale

- features include peripheral oedema, raised jugular venous pressure, systolic parasternal heave, loud P2
- use a loop diuretic for oedema, consider long-term oxygen therapy
- ACE-inhibitors, calcium channel blockers and alpha blockers are not recommended by NICE

Factors which may improve survival in patients with stable COPD

- smoking cessation - the single most important intervention in patients who are still smoking
- long term oxygen therapy in patients who fit criteria
- lung volume reduction surgery in selected patients

123

Next question

Textbooks

High-yield textbook

Extended textbook

Links

Global Initiative for Chronic Obstructive Lung Disease 14 32

GOLD criteria 2017

NICE 33 30

2018 COPD guidelines

NICE

15 10

[Roflumilast NICE recommendations]

NICE 65 18

[2018 COPD management diagram]

Suggest link Report broken link

Media

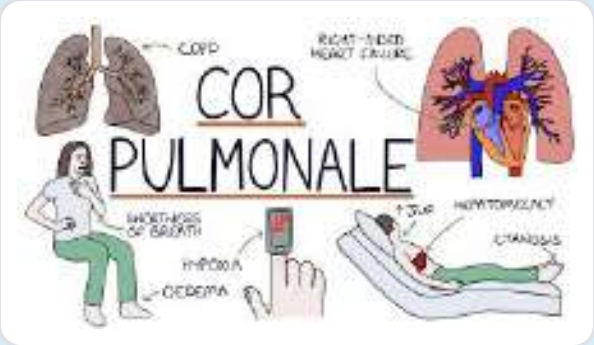

Cor pulmonale

Zero To Finals - YouTube 5 0

Chronic bronchitis

Osmosis - YouTube 3 0

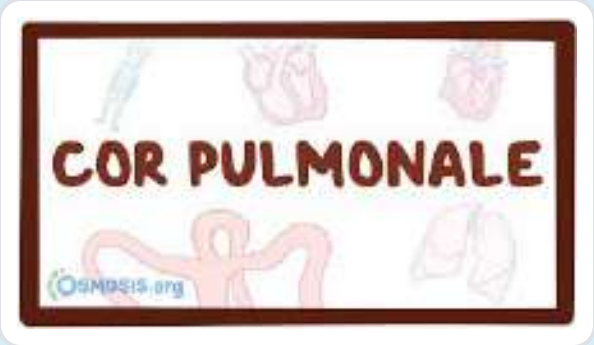

Cor pulmonale

Osmosis - YouTube 1 0

Understanding COPD

Armando Hasudungan - YouTube 0 0

[All about COPD (for Medical Students)]

MedFlix - YouTube 👍 3 👎 1

Report broken media

Score: **8.7%**

1	✓
2	✗
3	✗
4	✗
5	✗
6	✗
7	✗
8	✗
9	✗
10	✗
11	✗
12	✗
13	✗
14	✗
15	✓
16	✗
17	✗
18	✗
19	✗
20	✗
21	✗
22	✗
23	✗

All contents of this site are © 2024 Passmedicine Limited

A 55-year-old HIV-positive American woman develops fever, cough and fatigue after returning from her Thanksgiving holiday. Her chest radiograph is normal. Her symptoms persist despite treatment with oral co-amoxiclav. She undergoes a bronchoscopy and her bronchial washings grow *Histoplasma capsulatum*.

What single treatment is most likely to resolve her symptoms?

- Amphotericin
- Caspofungin
- Fluconazole
- Ivermectin
- Oral prednisolone

Submit answer

Reference ranges

10 -
11 -
12 -
13 -
14 -
15 -
16 -
17 -
18 -

All contents of this site are © 2024 Passmedicine Limited

A 55-year-old HIV-positive American woman develops fever, cough and fatigue after returning from her Thanksgiving holiday. Her chest radiograph is normal. Her symptoms persist despite treatment with oral co-amoxiclav. She undergoes a bronchoscopy and her bronchial washings grow *Histoplasma capsulatum*.

What single treatment is most likely to resolve her symptoms?

Amphotericin	57%
Caspofungin	10%
Fluconazole	17%
Ivermectin	11%
Oral prednisolone	5%

Amphotericin or itraconazole are the pharmacological agents of choice for histoplasmosis

Important for me Less important

Histoplasma capsulatum is a rare fungus that can be found in the United States of America that can cause respiratory symptoms in immunocompromised patients. It should be treated with **amphotericin** or itraconazole.

Caspofungin is also an antifungal drug, but it is more appropriate to treat patients with *Aspergillus* infections.

Fluconazole is also an antifungal drug, but it is more appropriate to treat patients with *Candida* infections.

Ivermectin is an anti-parasitic drug, but it is more appropriate to treat other infections such as *Strongyloides* and Norwegian scabies.

Oral prednisolone is used to treat many respiratory diseases including acute asthma. However, it is not appropriate for the initial treatment of a fungal infection such as *Histoplasma* and appropriate anti-fungal medication should be prescribed first.

Discuss (1) | Improve

Next question

Histoplasmosis

Histoplasmosis is due to the fungus *Histoplasma capsulatum*. It is most commonly encountered in the Mississippi and Ohio River valleys.

Features

- URTI symptoms
- retrosternal pain

Management

- amphotericin or itraconazole are the pharmacological agents of choice for histoplasmosis

123

Next question

Textbooks

High-yield textbook

Extended textbook

Score: **8.7%**

1	✓
2	✗
3	✗
4	✗
5	✗
6	✗
7	✗
8	✗
9	✗
10	✗
11	✗
12	✗
13	✗
14	✗
15	✓
16	✗
17	✗
18	✗
19	✗
20	✗
21	✗
22	✗
23	✗

All contents of this site are © 2024 Passmedicine Limited

Back to top

A 63-year-old man was admitted two hours ago with an infective exacerbation of COPD. He had become rapidly unwell following one day of a productive cough, developing worsening fever, shortness of breath and chest tightness. Arterial blood gas demonstrated that he was acidotic in type two respiratory failure despite treatment with back-to-back nebulisers, IV hydrocortisone and IV antibiotics. He was started on non-invasive ventilation (NIV) with IPAP of 10cmH_2O and EPAP of 4cmH_2O. This has been increased to IPAP of 16cmH_2O. During a review of this patient, the nurses ask what should be done about his nebulisers, prescribed 3 hourly, during NIV treatment.

How should he be treated with nebulisers whilst having NIV?

- Add nebulisers into NIV mask
- Take off mask to administer nebulisers
- Hold nebulisers whilst on NIV
- Give IV salbutamol instead of nebulised
- Stop NIV whilst on 2 hourly nebulisers

Submit answer

Reference ranges

Score: **0%**

1 -
2 -
3 -
4 -
5 -
6 -

7 -
8 -
9 -
10 -
11 -
12 -
13 -
14 -
15 -
16 -
17 -
18 -
19 -

All contents of this site are © 2024 Passmedicine Limited

A 63-year-old man was admitted two hours ago with an infective exacerbation of COPD. He had become rapidly unwell following one day of a productive cough, developing worsening fever, shortness of breath and chest tightness. Arterial blood gas demonstrated that he was acidotic in type two respiratory failure despite treatment with back-to-back nebulisers, IV hydrocortisone and IV antibiotics. He was started on non-invasive ventilation (NIV) with IPAP of 10cmH_2O and EPAP of 4cmH_2O. This has been increased to IPAP of 16cmH_2O. During a review of this patient, the nurses ask what should be done about his nebulisers, prescribed 3 hourly, during NIV treatment.

How should he be treated with nebulisers whilst having NIV?

- Add nebulisers into NIV mask 56%
- Take off mask to administer nebulisers 24%
- Hold nebulisers whilst on NIV 13%
- Give IV salbutamol instead of nebulised 4%
- Stop NIV whilst on 2 hourly nebulisers 3%

The correct answer is to take off the mask to administer nebulisers. This is a patient with a severe exacerbation of COPD with type two respiratory failure with acidosis not responding to medical therapy and needing NIV. Whilst it is possible to give nebulisers into some NIV masks it is preferable to administer nebulisers off NIV as a far greater proportion of the drug reaches the airways, necessary for bronchodilation. Giving nebulised medication into ongoing NIV is not recommended by the BTS as the pressures reduce the effective dose reaching the airways. Stopping nebulisers or NIV are both inappropriate as both are necessary.

Source:
'The Use of Non-Invasive Ventilation in the management of patients with chronic obstructive pulmonary disease admitted to hospital with acute type II respiratory failure. British Thoracic Society, October 2008'.

Discuss (7) | Improve

Next question

Acute exacerbation of COPD

Acute exacerbations of COPD are one of the most common reasons why people present to hospital in developed countries.

The most common infective causes of COPD exacerbations are:

- bacteria
  - *Haemophilus influenzae* (most common cause)
  - *Streptococcus pneumoniae*
  - *Moraxella catarrhalis*
- respiratory viruses
  - account for around 30% of exacerbations
  - human rhinovirus is the most important pathogen

Features

- increase in dyspnoea, cough, wheeze
- there may be an increase in sputum suggestive of an infective cause
- patients may be hypoxic and in some cases have acute confusion

NICE guidelines from 2010 recommend the following:

- increase the frequency of bronchodilator use and consider giving via a nebuliser
- give prednisolone 30 mg daily for 5 days
- it is common practice for all patients with an exacerbation of COPD to receive antibiotics. NICE do not support this approach. They recommend giving oral antibiotics 'if sputum is purulent or there are clinical signs of pneumonia'
- the BNF recommends one of the following oral antibiotics first-line: amoxicillin or clarithromycin or doxycycline.

Admission is recommended if any of the following criteria are met

- severe breathlessness
- acute confusion or impaired consciousness
- cyanosis
- oxygen saturation less than 90% on pulse oximetry.
- social reasons e.g. inability to cope at home (or living alone)
- significant comorbidity (such as cardiac disease or insulin-dependent diabetes)

Severe exacerbations requiring secondary care

Oxygen therapy

- COPD patients are at risk of hypercapnia - therefore an initial oxygen saturation target of 88-92% should be used
- prior to the availability of blood gases, use a 28% Venturi mask at 4 l/min and aim for an oxygen saturation of 88-92% for patients with risk factors for hypercapnia but no prior history of respiratory acidosis
- adjust target range to 94-98% if the pCO_2 is normal

Nebulised bronchodilator

- beta adrenergic agonist: e.g. salbutamol
- muscarinic antagonists: e.g. ipratropium

Steroid therapy as above

- IV hydrocortisone may sometimes be considered instead of oral prednisolone

IV theophylline

- may be considered for patients not responding to nebulised bronchodilators

Patients with COPD are prone to develop type 2 respiratory failure. If this develops then non-invasive ventilation may be used

- typically used for COPD with respiratory acidosis pH 7.25-7.35
    - the BTS guidelines state that NIV can be used in patients who are more acidotic (i.e. pH < 7.25) but that a greater degree of monitoring is required (e.g. HDU) and a lower threshold for intubation and ventilation should be used
- bilevel positive airway pressure (BiPaP) is typically used with initial settings:
    - Expiratory Positive Airway Pressure (EPAP): 4-5 cm H_2O
    - Inspiratory Positive Airway Pressure (IPAP): RCP advocate 10 cm H20 whilst BTS suggest 12-15 cm H_2O

123

Next question

Textbooks

High-yield textbook

Extended textbook

Links

Clinical Knowledge Summaries 28 25

Acute exacerbation of COPD guidelines

NICE 22 10

2018 COPD guidelines

Suggest link Report broken link

Media

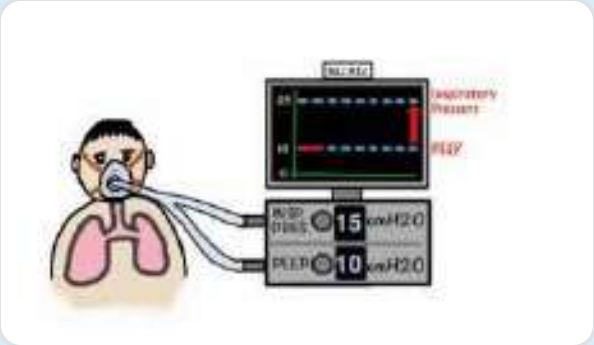

CPAP and Non-Invasive Ventilation in 5 minutes

Nick Smith - YouTube 6 2

Report broken media

Score: **8.7%**

1 ✓
2 ✗
3 ✗
4 ✗
5 ✗

6	✗
7	✗
8	✗
9	✗
10	✗
11	✗
12	✗
13	✗
14	✗
15	✓
16	✗
17	✗
18	✗
19	✗
20	✗
21	✗
22	✗
23	✗

All contents of this site are © 2024 Passmedicine Limited

Back to top

An 81-year-old man is admitted to the geriatric ward with confusion.

His past medical history is significant for hypertension, hyperlipidaemia, and a TIA 3 years ago. There is no history of any cognitive impairment. He has never smoked and consumes minimal alcohol.

Urine sent for culture and sensitivity is positive for *Escherichia coli*, so the patient is treated for a presumed delirium triggered by a UTI.

As part of the delirium workup, a routine chest x-ray is also performed. The chest x-ray is reported as follows:

> There is a 3 cm right-sided apical pneumothorax.

On review, the patient does not complain of any shortness of breath or chest pain. His observations are shown below:

- Heart rate: 66 bpm
- Respiratory rate: 18 breaths/minute
- Oxygen saturation: 98%
- Temperature: 37.0°C
- Blood pressure: 124/76 mmHg

What is the most appropriate management?

- Ambulatory device insertion
- Chest drain insertion
- Conservative management
- Needle aspiration
- Pleurodesis

Submit answer

Reference ranges

Score: **0%**

1	-
2	-
3	-
4	-
5	-
6	-
7	-
8	-
9	-
10	-
11	-
12	-
13	-
14	-
15	-
16	-
17	-
18	-
19	-
20	-

All contents of this site are © 2024 Passmedicine Limited

Back to top

An 81-year-old man is admitted to the geriatric ward with confusion.

His past medical history is significant for hypertension, hyperlipidaemia, and a TIA 3 years ago. There is no history of any cognitive impairment. He has never smoked and consumes minimal alcohol.

Urine sent for culture and sensitivity is positive for *Escherichia coli*, so the patient is treated for a presumed delirium triggered by a UTI.

As part of the delirium workup, a routine chest x-ray is also performed. The chest x-ray is reported as follows:

> There is a 3 cm right-sided apical pneumothorax.

On review, the patient does not complain of any shortness of breath or chest pain. His observations are shown below:

- Heart rate: 66 bpm
- Respiratory rate: 18 breaths/minute
- Oxygen saturation: 98%
- Temperature: 37.0ºC
- Blood pressure: 124/76 mmHg

What is the most appropriate management?

Ambulatory device insertion	3%
Chest drain insertion	14%
Conservative management	62%
Needle aspiration	21%
Pleurodesis	0%

Minimally symptomatic pneumothorax, regardless of size, can be treated with conservative treatment / regular follow-up

Important for me Less important

Conservative management is correct. This patient has an asymptomatic pneumothorax of 3 cm. Since the 2023 BTS guidelines update the determinants of the management strategy have changed, and the focus is no longer on the size of the pneumothorax but on the level of symptoms experienced by the patient. It is recommended that any asymptomatic pneumothorax, regardless of size, be managed conservatively.

Ambulatory device insertion is incorrect. This would be an option if the patient was symptomatic from their pneumothorax and did not have any of the 'high risk' characteristics (these include haemodynamic compromise, hypoxia, pre-existing lung disease, bilateral pneumothoraces, age over 50 years with a significant smoking history, or haemopneumothorax). The patient in this case is asymptomatic, so conservative management is the correct answer.

Chest drain insertion is incorrect. A chest drain would be indicated if the patient was symptomatic from their pneumothorax and also had any of the 'high risk' characteristics mentioned above or if a symptomatic patient without 'high risk' features underwent unsuccessful needle aspiration. The patient in this question has neither symptoms nor any of the 'high risk' characteristics; this answer is therefore incorrect.

Needle aspiration is incorrect. Needle aspiration would be indicated if the patient was symptomatic from their pneumothorax and had none of the 'high-risk' features mentioned above. This patient is asymptomatic, so this answer is incorrect.

Pleurodesis is incorrect. This procedure prevents recurrent pneumothoraces. This patient does not report having had a previous pneumothorax; thus this answer is incorrect.

Discuss (1) Improve

Next question

Pneumothorax: management

The British Thoracic Society (BTS) published updated guidelines for the management of spontaneous pneumothorax in 2023.

The updated guidelines put less emphasis on the size of the pneumothorax and more emphasis on

whether the patient is symptomatic and the presence of high-risk characteristics.

Decision algorithm

The first step is assessing whether the patient is symptomatic
- the BTS define minimal symptoms as '*no significant pain or breathlessness and no physiological compromise*'
- no or minimal symptoms → conservative care, regardless of pneumothorax size
- symptomatic → assess for high-risk characteristics

If a pneumothorax is symptomatic, the next step is assessment for high-risk characteristics
- high-risk characteristics are defined as follows:
  - haemodynamic compromise (suggesting a tension pneumothorax)
  - significant hypoxia
  - bilateral pneumothorax
  - underlying lung disease
  - ≥ 50 years of age with significant smoking history
  - haemothorax
- if no high-risk characteristics are present, and it is safe to intervene, then there is a choice of intervention:
  - conservative care
  - ambulatory device
  - needle aspiration
- if high-risk characteristics are present, and it is safe to intervene → chest drain

How is safety or intervention determined?
- before a needle aspiration/chest drain insertion, the safety of intervention should be assessed
- this depends on the clinical context, but is usually:
  - 2cm laterally or apically on chest x-ray, or
  - any size on CT scan which can be safely accessed with radiological support

Management options

Conservative care

- patients with a primary spontaneous pneumothorax that is managed conservatively should be reviewed every 2-4 days as an outpatient
- patients with a secondary spontaneous pneumothorax that is managed conservatively should be monitored as an inpatient
- if stable, follow-up in the outpatients department in 2-4 weeks

Ambulatory care

- an example of an ambulatory device is the Rocketµ Pleural Vent„
- it includes an 8FG catheter mounted on an 18G needle and a pigtail catheter to minimize the risk of occlusion
- ambulatory devices typically have a one-way valve and vent to prevent air and fluid return to the pleural space while allowing for controlled escape of air and drainage of fluid
- many devices also have an indication diaphragm that signals when the catheter tip enters the pleural space and continues to fluctuate with respiration, aiding in the assessment of pneumothorax resolution

Needle aspiration

- a chest drain should be inserted if needle aspiration of a pneumothorax is unsuccessful
- if resolved, discharge and follow-up in the outpatients department in 2-4 weeks

Chest drain insertion

- daily review as an inpatient
- remove drain when resolved
- discharge and follow-up in the outpatients department in 2-4 weeks

Persistentent / recurrent pneumothorax

If a patient has a persistent air leak or insufficient lung reexpansion despite chest drain insertion, or the patient has recurrent pneumothoraces, then video-assisted thoracoscopic surgery (VATS) should be considered to allow for mechanical/chemical pleurodesis +/- bullectomy.

Discharge advice

Smoking

- patients should be advised to avoid smoking to reduce the risk of further episodes - the lifetime risk of developing a pneumothorax in healthy smoking men is around 10% compared with around 0.1% in non-smoking men

Fitness to fly

- absolute contraindication, the CAA suggest patients may travel 2 weeks after successful drainage if there is no residual air. The British Thoracic Society used to recommend not travelling by air for a period of 6 weeks but this has now been changed to 1 week post check x-ray

Scuba diving

- the BTS guidelines state: '*Diving should be permanently avoided unless the patient has undergone bilateral surgical pleurectomy and has normal lung function and chest CT scan postoperatively.*'

Image gallery

123

Next question >

Textbooks

High-yield textbook

Extended textbook

Links

British Thoracic Society 2 1

2023 Pleural disease guidelines

Suggest link Report broken link

Media

How to identify pneumothorax on a chest X-ray

Medmastery - YouTube 30 1

Pneumothorax

Zero To Finals - YouTube 9 1

Pneumothorax

Osmosis - YouTube 6 1

Needle Aspiration of Pneumothorax

NEJM - YouTube 10 6

Report broken media

Score: **8.7%**

1	✓
2	✗
3	✗
4	✗
5	✗
6	✗
7	✗
8	✗
9	✗
10	✗
11	✗
12	✗
13	✗
14	✗
15	✓
16	✗
17	✗
18	✗
19	✗
20	✗
21	✗
22	✗
23	✗

All contents of this site are © 2024 Passmedicine Limited

Back to top

PassMedicine

A 78-year-old female presents to the Emergency Department with confusion, nausea and vomiting. She has been generally unwell with fatigue, weakness and fevers for 4 weeks. On examination her respiratory rate is 26/min, oxygen saturations are 98% on 4 litres of oxygen, blood pressure 100/65 mmHg, pulse 120/min and temperature is 36.3°C. Her airway is patent and crepitations are present at both bases. There are crusting lesions beneath both nostrils, the pulse is thready and regular, heart sounds are normal and her abdomen is soft non-tender. Electrocardiogram shows a sinus tachycardia and urine dip showed 3+ blood and protein. Arterial blood gas on 4 litres of oxygen is as follows:

pH	7.35
pO2	7.79 kPa
pCO2	3.52 kPa
Bicarbonate	17 mmol/l
Base Excess	-6.9 mmol/l
Lactate	4.5 mmol/l

Venous blood analysis is as follows:

Hb	119 g/l	Na^+	129 mmol/l
Platelets	$511 * 10^9/l$	K^+	6.2 mmol/l
WBC	$19.1 * 10^9/l$	Urea	42.1 mmol/l
Neuts	$17.2 * 10^9/l$	Creatinine	497 µmol/l
Lymphs	$1.8 * 10^9/l$	CRP	241 mg/l
Eosin	$0.04 * 10^9/l$		

The patient was resuscitated with fluids and antibiotics although the full septic screen was negative and renal function remained poor. ANA and cANCA pattern were positive with PR3 antibodies found and the renal team were involved. What is the most likely underlying diagnosis?

- Lymphoma
- Churg-Strauss syndrome

- Granulomatosis with polyangiitis
- Acute myeloid leukaemia
- Goodpasture's syndrome

Submit answer

Reference ranges

Score: **0%**

1	-
2	-
3	-
4	-
5	-
6	-
7	-
8	-
9	-
10	-
11	-
12	-
13	-
14	-
15	-
16	-
17	-
18	-
19	-
20	-
21	-

All contents of this site are © 2024 Passmedicine Limited

A 78-year-old female presents to the Emergency Department with confusion, nausea and vomiting. She has been generally unwell with fatigue, weakness and fevers for 4 weeks. On examination her respiratory rate is 26/min, oxygen saturations are 98% on 4 litres of oxygen, blood pressure 100/65 mmHg, pulse 120/min and temperature is 36.3ºC. Her airway is patent and crepitations are present at both bases. There are crusting lesions beneath both nostrils, the pulse is thready and regular, heart sounds are normal and her abdomen is soft non-tender. Electrocardiogram shows a sinus tachycardia and urine dip showed 3+ blood and protein. Arterial blood gas on 4 litres of oxygen is as follows:

pH	7.35
pO2	7.79 kPa
pCO2	3.52 kPa
Bicarbonate	17 mmol/l
Base Excess	-6.9 mmol/l
Lactate	4.5 mmol/l

Venous blood analysis is as follows:

Hb	119 g/l	Na^+	129 mmol/l
Platelets	511 * 10^9/l	K^+	6.2 mmol/l
WBC	19.1 * 10^9/l	Urea	42.1 mmol/l
Neuts	17.2 * 10^9/l	Creatinine	497 µmol/l
Lymphs	1.8 * 10^9/l	CRP	241 mg/l
Eosin	0.04 * 10^9/l		

The patient was resuscitated with fluids and antibiotics although the full septic screen was negative and renal function remained poor. ANA and cANCA pattern were positive with PR3 antibodies found and the renal team were involved. What is the most likely underlying diagnosis?

Lymphoma 0%

Churg-Strauss syndrome 5%

Granulomatosis with polyangiitis 91%

Acute myeloid leukaemia 0%

Goodpasture's syndrome 3%

Consider granulomatosis with polyangiitis when a patient presents with ENT, respiratory and kidney involvement

Important for me Less important

This patient presents with systemic inflammatory response syndrome (SIRS) as evidence by her tachycardia, tachypnoea and leucocytosis. The most common cause, in this case, would be sepsis, however, history, examination and investigations have not demonstrated a source. The raised lactate suggests end organ hypo-perfusion. Routine biochemistry demonstrates severe renal impairment which must be assumed to represent stage 3 acute kidney injury (AKI) without previous values for comparison. Arterial blood gas demonstrates a compensated metabolic acidosis consistent with acute kidney injury, sepsis or SIRS.

With a negative septic screen we must consider alternative causes of SIRS and in the context of stage 3 AKI and heavy blood and protein on the urine dip, intrinsic renal pathology must be suspected. Granulomatosis with polyangiitis (previously known as Wegener's Granulomatosis) typically presents with non-specific symptoms, an unwell patient and AKI with active urinary sediment. Nasal crusting due to granulomas and a collapsed nasal septum may also be found. The diagnosis is also suggestive by a positive cANCA with PR3 antibodies although renal biopsy is required to confirm the diagnosis.

Discuss (6) Improve

Next question

Granulomatosis with polyangiitis

Granulomatosis with polyangiitis is now the preferred term for Wegener's granulomatosis. It is an autoimmune condition associated with a necrotizing granulomatous vasculitis, affecting both the upper and lower respiratory tract as well as the kidneys.

Features

- upper respiratory tract: epistaxis, sinusitis, nasal crusting
- lower respiratory tract: dyspnoea, haemoptysis

- rapidly progressive glomerulonephritis ('pauci-immune', 80% of patients)
- saddle-shape nose deformity
- also: vasculitic rash, eye involvement (e.g. proptosis), cranial nerve lesions

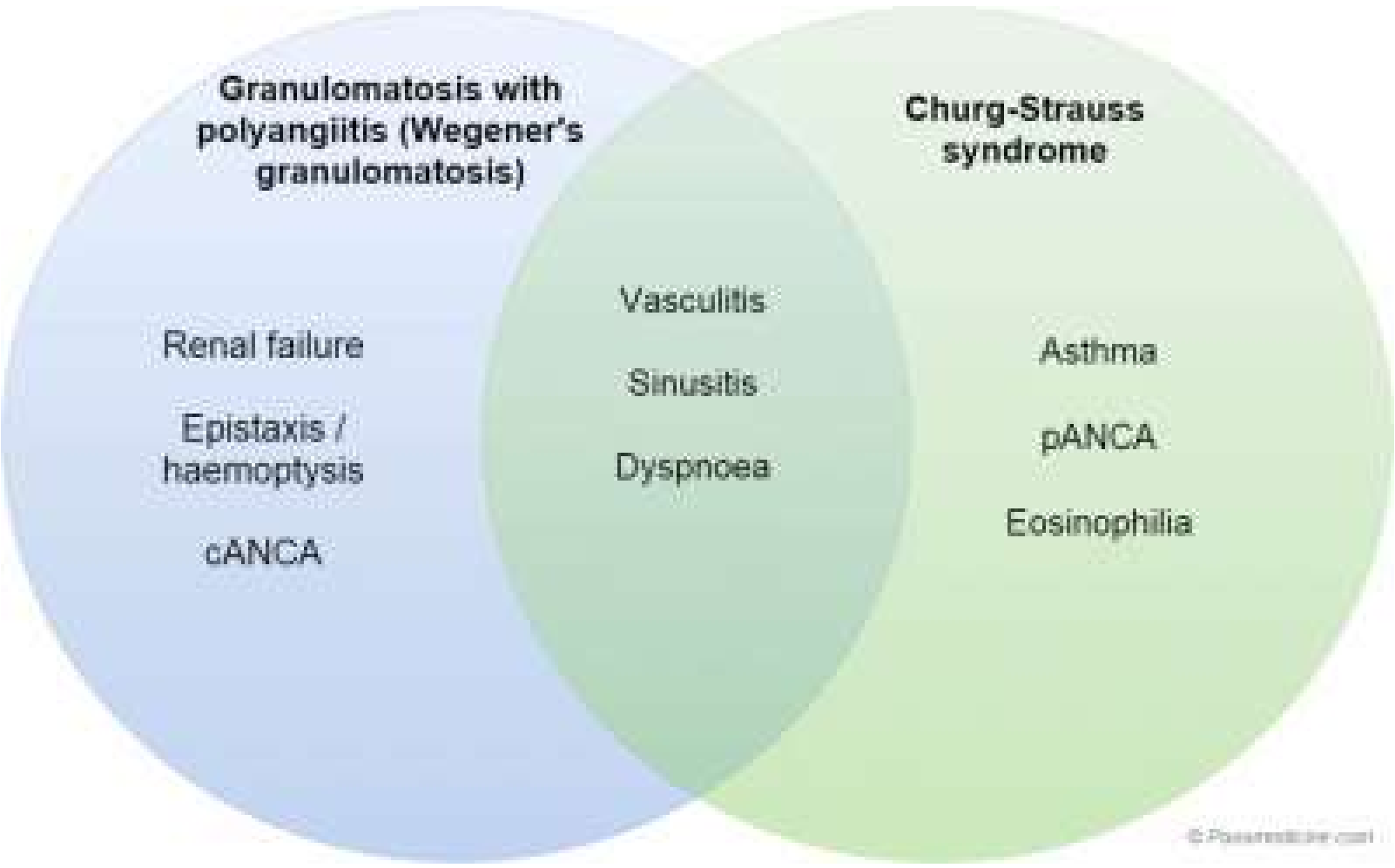

Comparison of granulomatosis with polyangiitis and Churg-Strauss syndrome

Investigations

- cANCA positive in > 90%, pANCA positive in 25%
- chest x-ray: wide variety of presentations, including cavitating lesions
- renal biopsy: epithelial crescents in Bowman's capsule

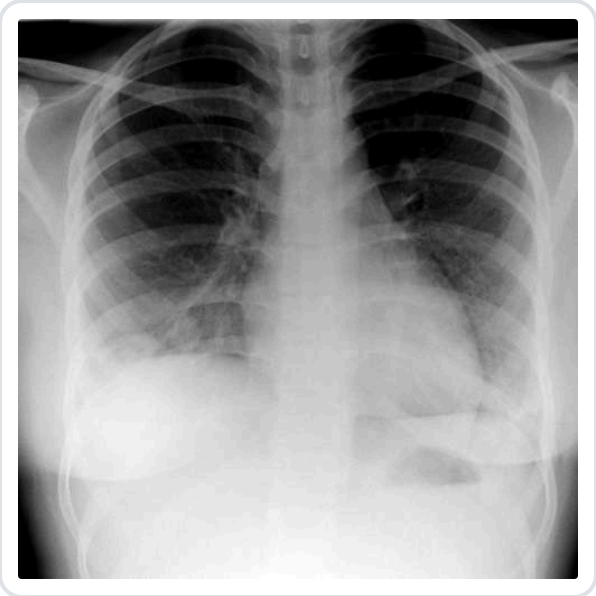

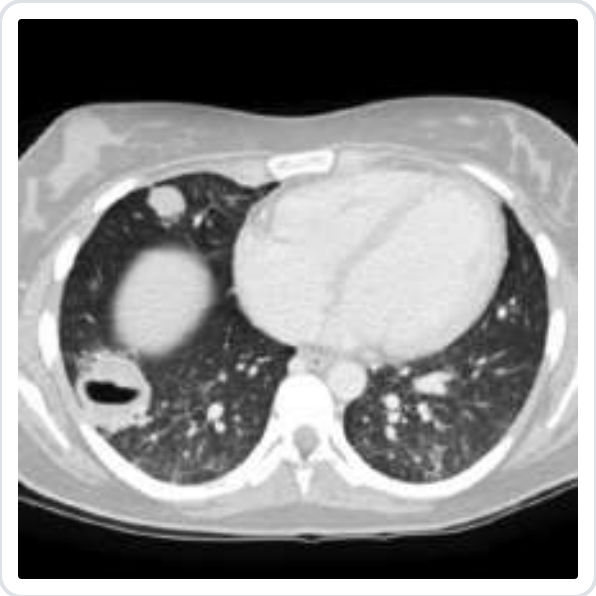

Management

- steroids
- cyclophosphamide (90% response)
- plasma exchange
- median survival = 8-9 years

123

Next question

Textbooks

High-yield textbook

Extended textbook

Media

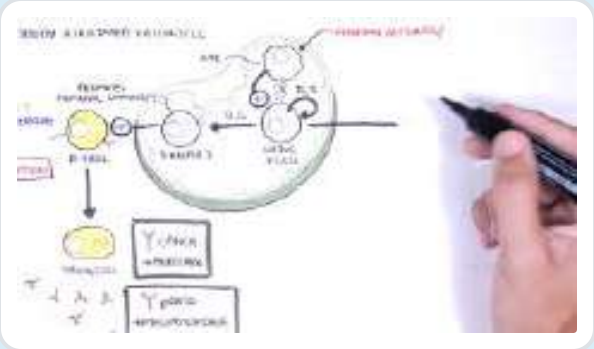

ANCA (Anti-Neutrophil Cytoplasmic Antibody) Associated Vasculitis - Causes, Pathophysiology, Types

Armando Hasudungan - YouTube 5 1

Granulomatosis with polyangiitis

Armando Hasudungan - YouTube 5 2

Report broken media

Score: **8.7%**

1 ✓
2 ✗
3 ✗

4	✗
5	✗
6	✗
7	✗
8	✗
9	✗
10	✗
11	✗
12	✗
13	✗
14	✗
15	✓
16	✗
17	✗
18	✗
19	✗
20	✗
21	✗
22	✗
23	✗

All contents of this site are © 2024 Passmedicine Limited

A 72-year-old man is admitted to hospital for an elective knee replacement. The surgery is completed successfully and induction, maintenance and emergence of anaesthesia proceeds without any problem. Several hours after the operation however, the patient's saturations start to drop, reaching a level of 91% when the patient is started on oxygen via face mask. He also starts coughing up small mucous plugs.

His background history includes mild COPD that is treated with tiotropium and hypertension which is treated with ramipril and amlodipine. There is no relevant family history and he has smoked 15 cigarettes a day for 30 years.

What is the most likely diagnosis?

- Basal atelectasis
- *Pneumococcus pneumoniae*
- *Streptococcus pneumoniae*
- Pulmonary embolism
- Pneumothorax

Submit answer

Reference ranges

Score: **0%**

1 -
2 -
3 -
4 -

5	-
6	-
7	-
8	-
9	-
10	-
11	-
12	-
13	-
14	-
15	-
16	-
17	-
18	-
19	-
20	-
21	-
22	-

All contents of this site are © 2024 Passmedicine Limited

A 72-year-old man is admitted to hospital for an elective knee replacement. The surgery is completed successfully and induction, maintenance and emergence of anaesthesia proceeds without any problem. Several hours after the operation however, the patient's saturations start to drop, reaching a level of 91% when the patient is started on oxygen via face mask. He also starts coughing up small mucous plugs.

His background history includes mild COPD that is treated with tiotropium and hypertension which is treated with ramipril and amlodipine. There is no relevant family history and he has smoked 15 cigarettes a day for 30 years.

What is the most likely diagnosis?

Basal atelectasis	78%
Pneumococcus pneumoniae	1%
Streptococcus pneumoniae	4%
Pulmonary embolism	13%
Pneumothorax	4%

The most likely diagnosis in this scenario is basal atelectasis - a condition where mucous trapped in the bronchial tree results in small airway obstruction. There is often segmental lung collapse due to the basal atelectasis. Management is with chest physiotherapy and saline nebulisers to encourage production of the mucous.

Discuss (4) Improve

Next question

Atelectasis

Atelectasis is a common postoperative complication in which basal alveolar collapse can lead to respiratory difficulty. It is caused when airways become obstructed by bronchial secretions.

Features

- it should be suspected in the presentation of dyspnoea and hypoxaemia around 72 hours postoperatively

Management

- positioning the patient upright
- chest physiotherapy: breathing exercises

+ Q 123

Next question

Textbooks

High-yield textbook

Extended textbook

Score: **8.7%**

1 ✓
2 ✗
3 ✗
4 ✗
5 ✗
6 ✗
7 ✗

8	✗
9	✗
10	✗
11	✗
12	✗
13	✗
14	✗
15	✓
16	✗
17	✗
18	✗
19	✗
20	✗
21	✗
22	✗
23	✗

All contents of this site are © 2024 Passmedicine Limited

Back to top

A 40-year-old male smoker presents with a 10-day history of shortness of breath and pleuritic chest pain. He has been acutely short of breath for the last 24 hours. His respiratory rate is 34 breaths per minute and his blood pressure is 80/45 mmHg. His oxygen saturations are 84% on arrival in triage. Initial blood results and chest-x-ray are as below.

Hb	118 g/L	Male: (135-180)
Platelets	564 * 10^9/L	(150 - 400)
WBC	24 * 10^9/L	(4.0 - 11.0)
Na^+	136 mmol/L	(135 - 145)
K^+	5.6 mmol/L	(3.5 - 5.0)
Urea	11 mmol/L	(2.0 - 7.0)
Creatinine	154 µmol/L	(55 - 120)
CRP	250 mg/L	(< 5)

© Image used on license from Radiopaedia

What is his risk of mortality based on a scoring system used in the management of this condition?

- 10%
- 15%
- 3%

- 30%
- <3%

Submit answer

Reference ranges

Score: **0%**

1 -
2 -
3 -
4 -
5 -
6 -
7 -
8 -
9 -
10 -
11 -
12 -
13 -
14 -
15 -
16 -
17 -
18 -
19 -
20 -
21 -
22 -
23 -

All contents of this site are © 2024 Passmedicine Limited

A 40-year-old male smoker presents with a 10-day history of shortness of breath and pleuritic chest pain. He has been acutely short of breath for the last 24 hours. His respiratory rate is 34 breaths per minute and his blood pressure is 80/45 mmHg. His oxygen saturations are 84% on arrival in triage. Initial blood results and chest-x-ray are as below.

Hb	118 g/L	Male: (135-180)
Platelets	564 * 10^9/L	(150 - 400)
WBC	24 * 10^9/L	(4.0 - 11.0)
Na^+	136 mmol/L	(135 - 145)
K^+	5.6 mmol/L	(3.5 - 5.0)
Urea	11 mmol/L	(2.0 - 7.0)
Creatinine	154 µmol/L	(55 - 120)
CRP	250 mg/L	(< 5)

© Image used on license from Radiopaedia

What is his risk of mortality based on a scoring system used in the management of this condition?

- 10% — 15%
- 15% — 38%
- 3% — 4%

30%	42%
<3%	2%

This patient has severe community-acquired pneumonia. The x-ray shows dense consolidation in a lobar distribution, affecting the left middle zone. His CURB-65 score is 3 (scoring for respiratory rate, urea, and blood pressure). This equates to an in-hospital mortality risk of greater than **15%**. These patients should be considered for referral to high dependency or intensive care.

<3% is incorrect. This is the mortality associated with a CURB-65 score of 0.

3% is incorrect . This is the mortality associated with a patient with a CURB-65 score of 1.

10% is incorrect. A CURB-65 score of 2 is associated with a mortality risk of 5-10%.

30% is incorrect. This is the mortality associated with a CURB-65 score of 5.

Discuss (1) Improve

Pneumonia: features

Pneumonia is a common inflammatory condition affecting the alveoli in the lungs. It occurs as a result of pathogens entering the lower respiratory tract and causing infection. Causative pathogens include:

- **Bacteria:** e.g *Streptococcus pneumoniae* - the most common cause of community acquired pneumonia (CAP)
- Virus
- Fungus (e.g. *Pneumocystis jiroveci*

Pathophysiology:

Once a pathogen has entered the lower respiratory tract an inflammatory cascade begins. Neutrophils migrate to the infected alveoli and release cytokines which activate an immune response and induce fever. This process leads to an accumulation of fluid and pus within the alveoli that impairs gaseous exchange, leading to a hypoxic state which is characteristic of pneumonia.

Risk factors:

- Aged under 5 or over 65-years-old
- Smoking
- Recent viral respiratory tract infection
- Chronic respiratory diseases: e.g. cystic fibrosis and COPD
- Immunosuppression: e.g. cytotoxic drug therapy and HIV
- Patients at risk of aspiration: e.g. those with neurological diseases such as Parkinson's disease or those with oesophageal obstruction
- IV drug users
- Other non-respiratory co-morbidities: e.g. diabetes and cardiovascular disease

Signs and symptoms:

Symptoms:

- A cough with purulent sputum (rust coloured/bloodstained)
- Dyspnoea
- Chest pain (may be pleuritic in nature)
- Fever
- Malaise

Signs:

- Signs of systemic infection: High temperature, tachycardia, hypotension, confusion
- Tachypnoea
- Low oxygen saturation (below 95% or below 88% in patients with COPD)
- On auscultation, there may be reduced breath sounds, bronchial breathing, and crepitations/crackles
- Dullness on percussion (fluid)

Assessment in a primary care setting

NICE recommends that patients should initially be assessed in primary care using the CRB65 criteria:

Criterion	Marker
C	Confusion (abbreviated mental test score <= 8/10)

Criterion	Marker
R	Respiration rate >= 30/min
B	Blood pressure: systolic <= 90 mmHg and/or diastolic <= 60 mmHg
65	Aged >= 65 years

Patients are stratified for risk of death as follows:

- 0: low risk (less than 1% mortality risk)
- 1 or 2: intermediate risk (1-10% mortality risk)
- 3 or 4: high risk (more than 10% mortality risk).

NICE recommend, in conjunction with clinical judgement:

- home-based care for patients with a CRB65 score of 0
- hospital assessment for all other patients, particularly those with a CRB65 score of 2 or more.

NICE also mention point-of-care CRP test. This is currently not widely available but they make the following recommendation with reference to the use of antibiotic therapy:

- CRP < 20 mg/L - do not routinely offer antibiotic therapy
- CRP 20 - 100 mg/L - consider a delayed antibiotic prescription
- CRP > 100 mg/L - offer antibiotic therapy

Assessment in a secondary care setting

Note that in hospital, once blood tests are available the CURB65, rather than the CRB65, can be used. This adds an extra criterion of urea > 7 mmol/L:

Criterion	Marker
C	Confusion (abbreviated mental test score <= 8/10)
U	urea > 7 mmol/L
R	Respiration rate >= 30/min
B	Blood pressure: systolic <= 90 mmHg and/or diastolic <= 60 mmHg

Criterion	Marker
65	Aged >= 65 years

NICE recommend, in conjunction with clinical judgement:

- consider home-based care for patients with a CURB65 score of 0 or 1 - low risk (less than 3% mortality risk)
- consider hospital-based care for patients with a CURB65 score of 2 or more - intermediate risk (3-15% mortality risk)
- consider intensive care assessment for patients with a CURB65 score of 3 or more - high risk (more than 15% mortality risk)

Investigations:

Chest X-ray

- typically shows consolidation (opacity on the X-ray film) in the area of infection
- may also show effusion

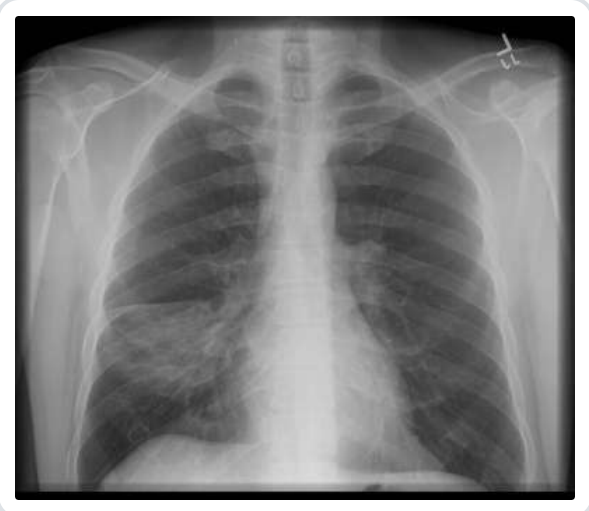

Bloods:

- FBC: raised white cell count indicates infection
- U&E: urea for the CURB-65 score
- CRP: raised in inflammation. Monitoring is recommend for admitted patients to help determine response to treatment
- Blood cultures

Sputum sample

- used to diagnose causative organism after culture

Legionella antibodies are recommended in intermediate ir high risk patients

123

Textbooks

High-yield textbook

Extended textbook

Links

NICE 4 1

2014 Pneumonia in adults: diagnosis and management

MDCalc 3 0

CURB-65 Score for Pneumonia Severity

Suggest link Report broken link

Score: **8.7%**

1 ✓
2 ✗
3 ✗
4 ✗
5 ✗
6 ✗

7	✗
8	✗
9	✗
10	✗
11	✗
12	✗
13	✗
14	✗
15	✓
16	✗
17	✗
18	✗
19	✗
20	✗
21	✗
22	✗
23	✗

All contents of this site are © 2024 Passmedicine Limited

Back to top